Superior View of the Skull)Norma Verticalis(

Anteriorly
the frontal bone articulates with the two parietal bones

AT THE CORONAL SUTURE

The two parietal bones articulate in the midline

AT THE SAGITTAL SUTURE

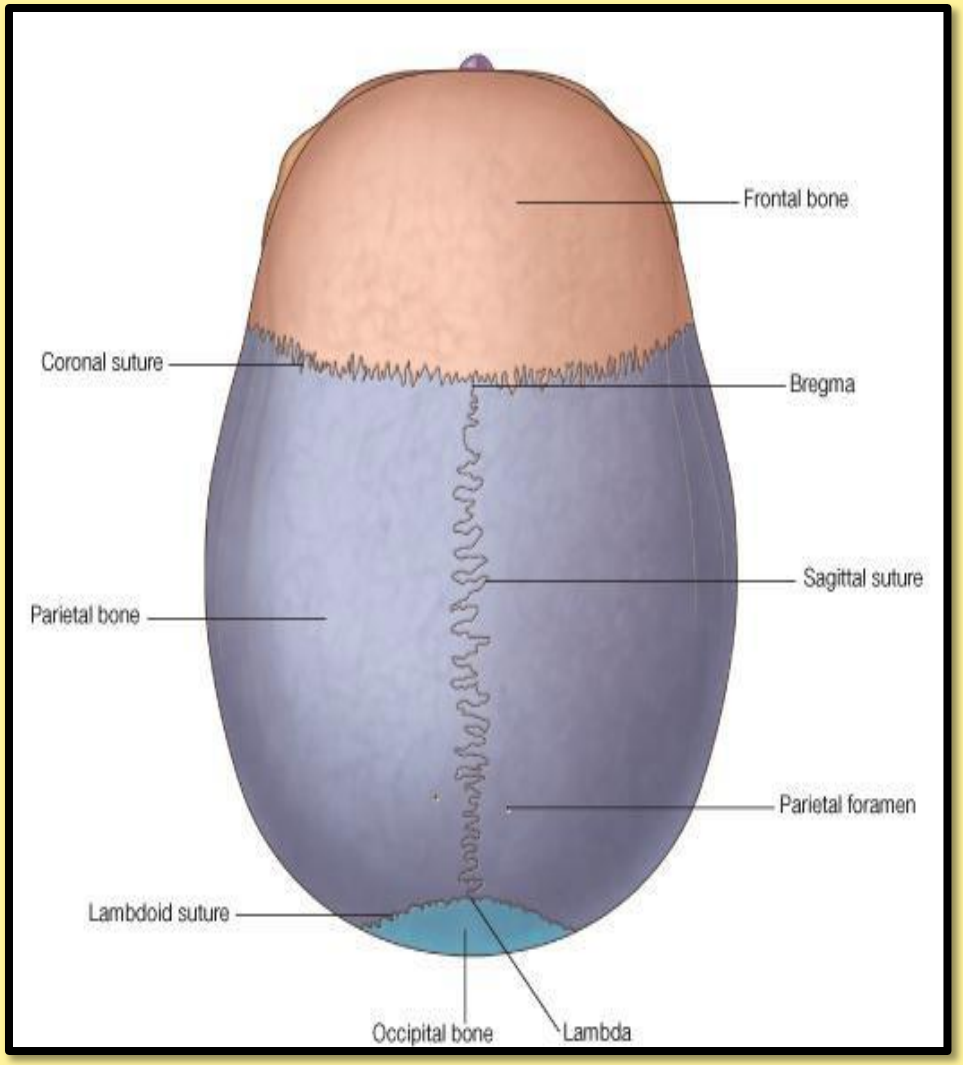

lambdoid sutures

To assist one in memorizing the names of the five layers of the scalp, use each letter of the word SCALP to denote the layer of the scalp.

S—skin
C—connective tissue
A—aponeurosis
L—loose connective tissue
P—periosteum.

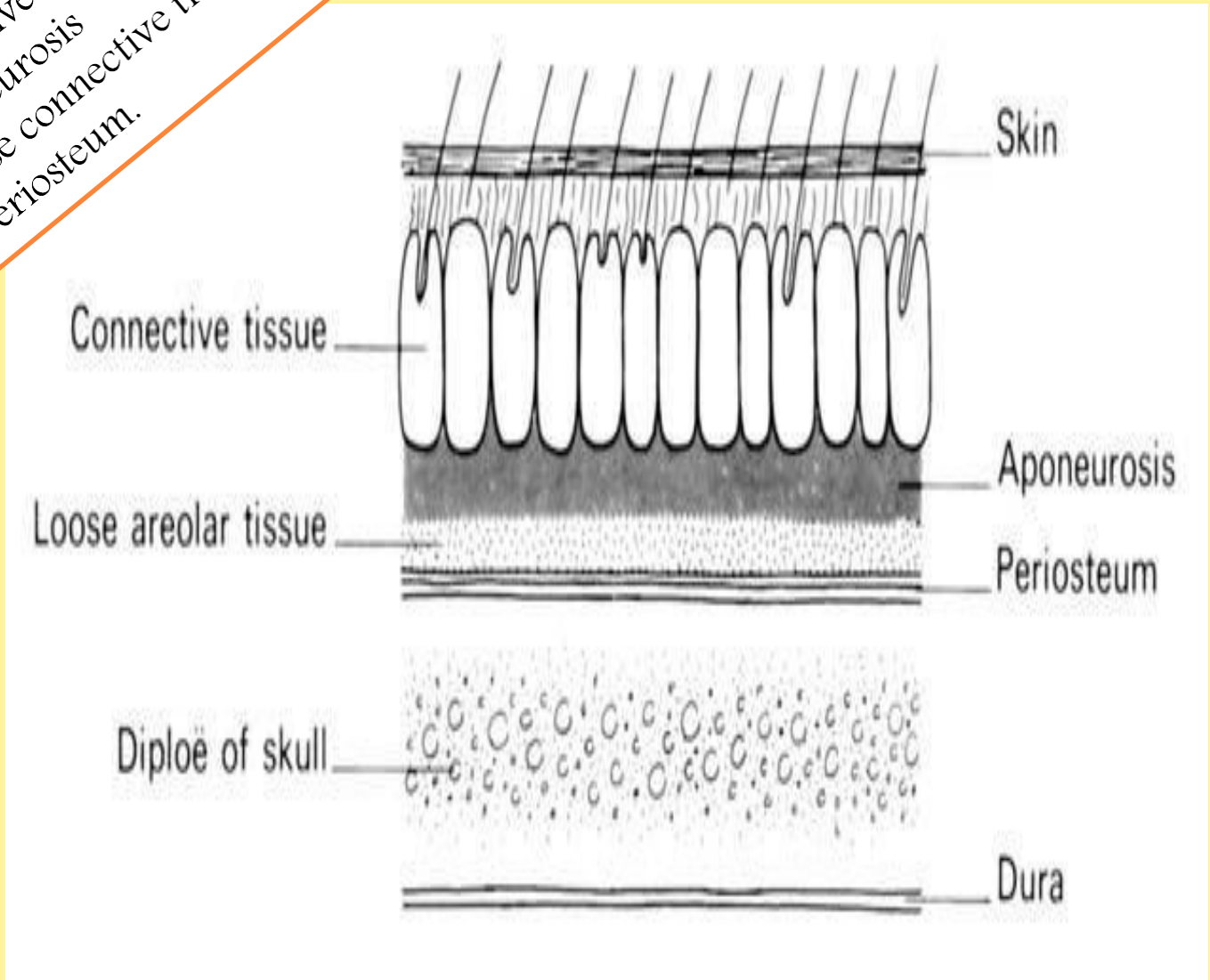

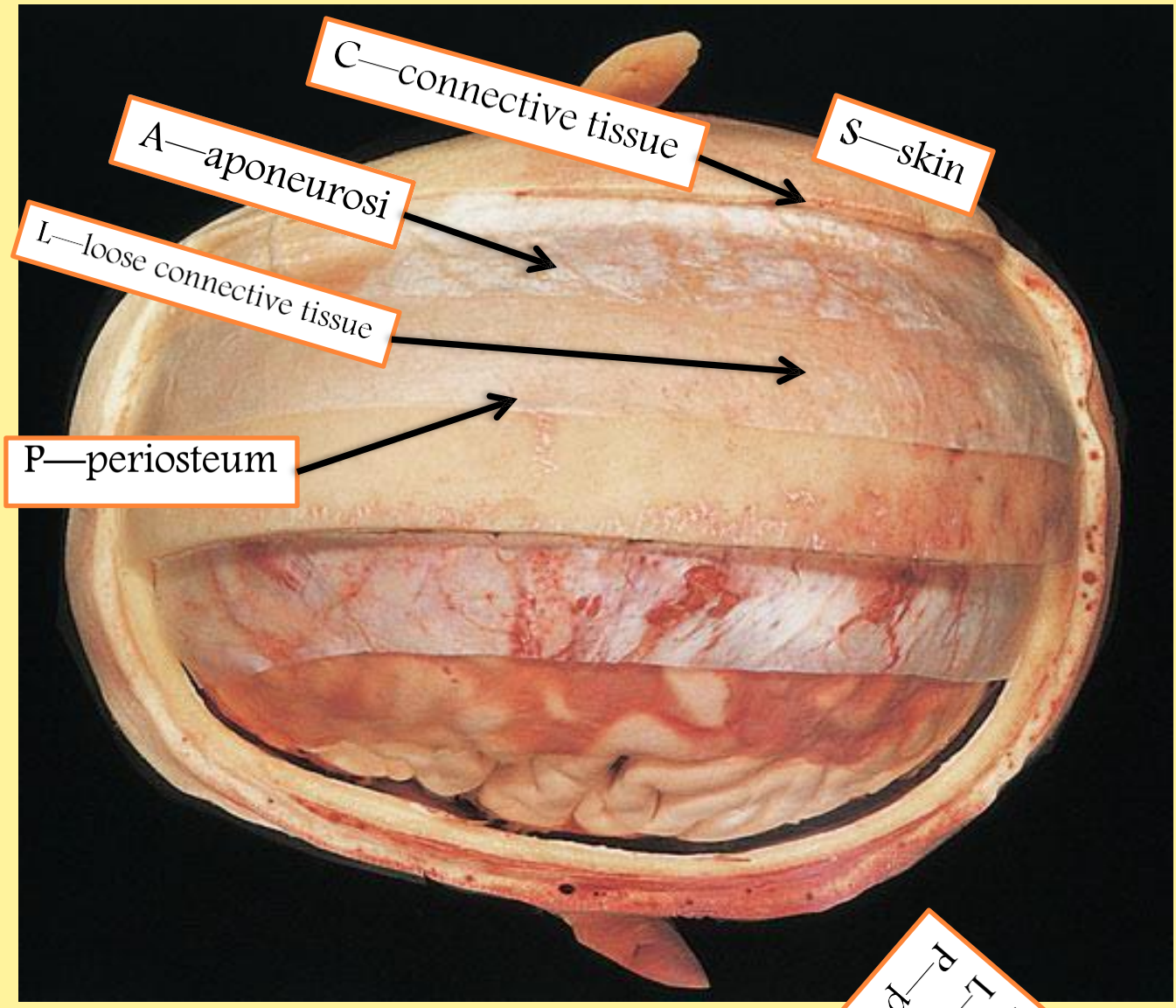

S—skin
C—connective tissue
A—aponeurosis
L—loose connective tissue
P—periosteum.

The Scalp

The scalp consists of **FIVE LAYERS**

S-skin

C-connective tissue (dense(

A-aponeurotic layer

L-loose connective tissue

P-pericranium

The first three of which are intimately bound together and move as a unit

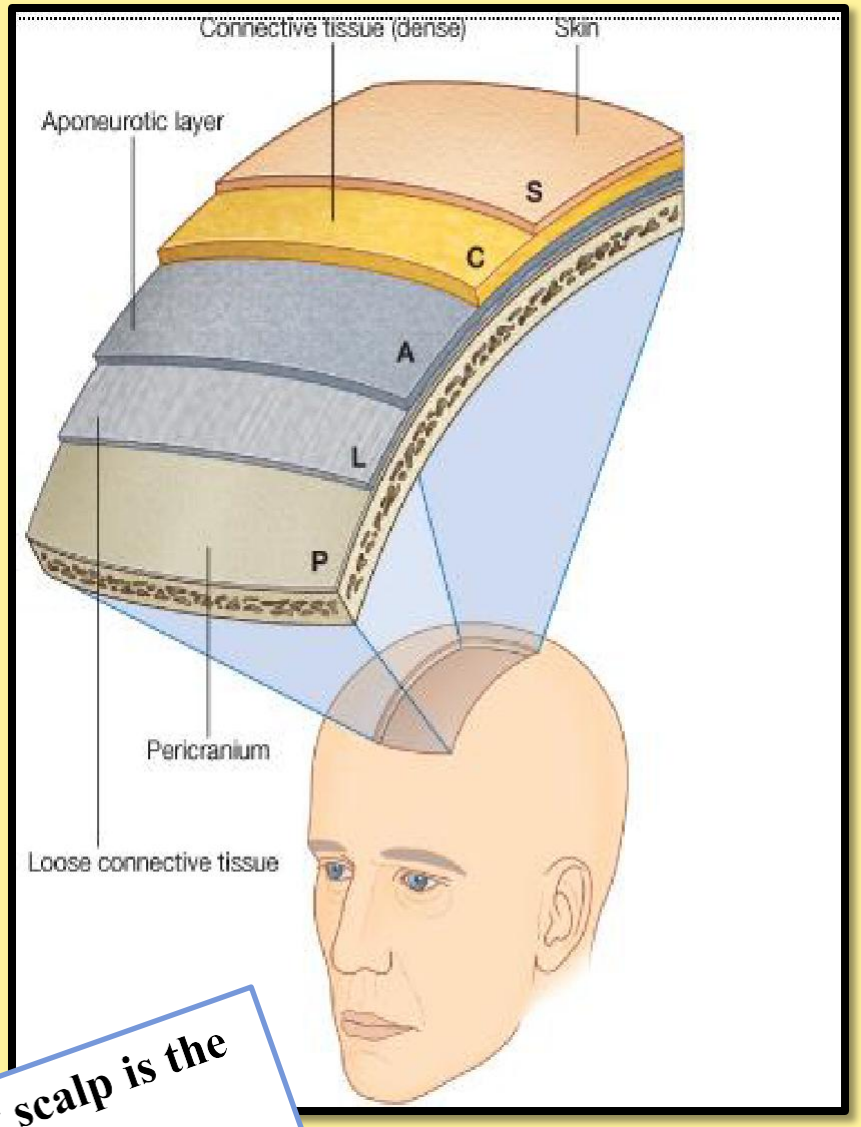

-1Skin

is thick contains hair and contains numerous **sebaceous glands**

Remember that scalp is the common site for sebaceous cyst

Sebaceous cyst

-2Connective tissue

➢Made of fibrous fascia and

septa

which unite the skin to the underlying aponeurosis of the occipitofrontalis muscle

➢Contains

numerous arteries and veins!!!

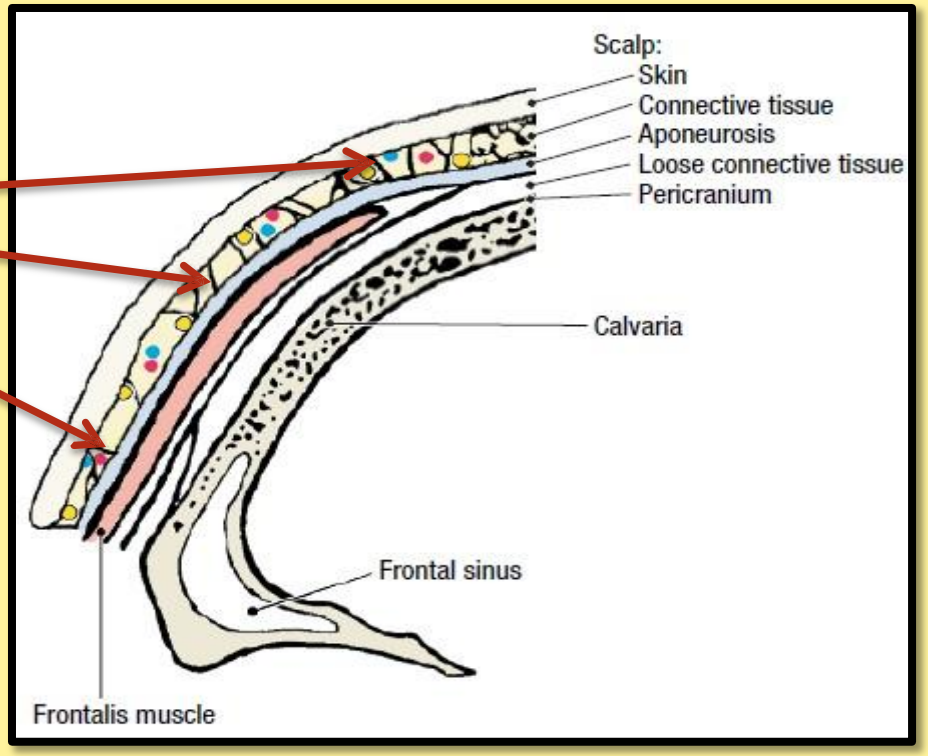

It is often difficult to stop the bleeding of a scalp wound because the arterial walls

are attached to fibrous septa

in the subcutaneous tissue

and are unable to contract or retract to allow blood clotting to take place

Local pressure applied to the scalp is the only satisfactory method of stopping the bleeding

3-Aponeurosis (epicranial),

is a thin, tendinous sheet that unites the **occipital and frontal bellies** of the **occipitofrontalis** muscle

➢ ***Epicranail aponeurosis***

The lateral margins of the aponeurosis are attached to the temporal fascia. The subaponeurotic space is the potential space beneath the epicranial aponeurosis.

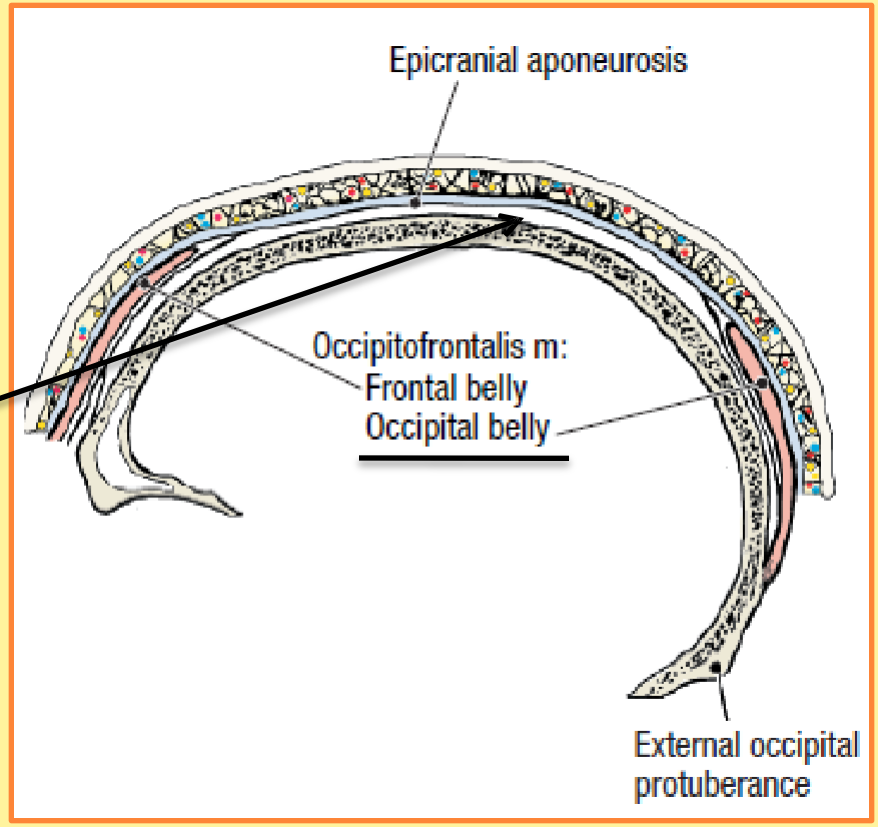

It is limited in front and behind by the origins of the occipitofrontalis muscle, and it extends laterally as far as the attachment of the aponeurosis to the temporal fascia

The tension of the epicranial aponeurosis, produced by the tone of the occipitofrontalis muscles, is important in all deep wounds of the scalp. If the aponeurosis has been divided, the wound will gape open. For satisfactory healing to take place, the opening in the aponeurosis must be closed with sutures

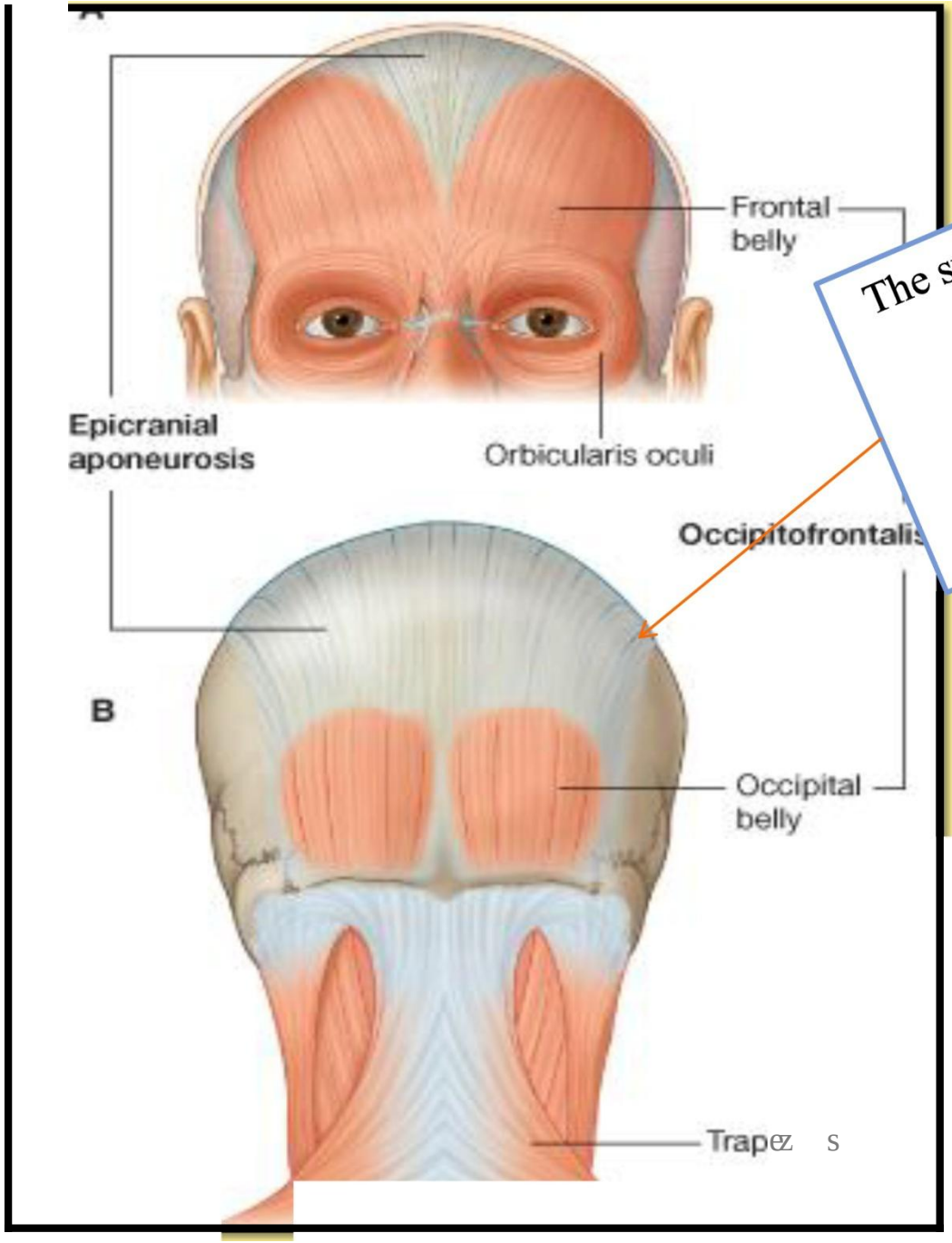

The subaponeurotic space
Is under the aponeurosis of occipitofrontalis muscle

-4Loose areolar tissue

Also called the dangerous area
Of the scalp

➢Occupies the subaponeurotic space and ***extends anteriorly to the eyelids*** Therefore, any blood collection in this layer may extend to the root of the nose and the eyelids causing Black eye

Black eyes .....think of head trauma

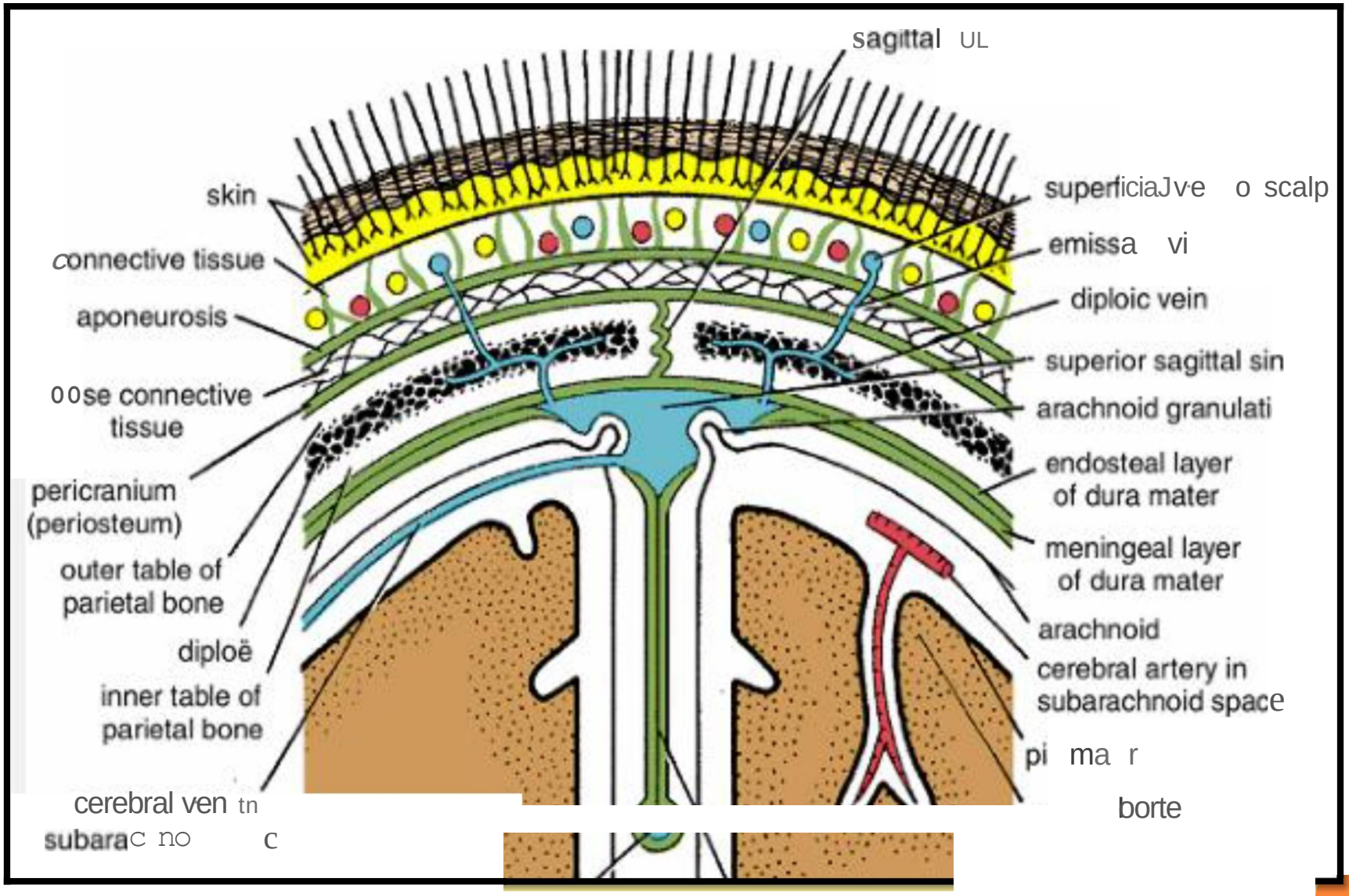
sagittal UL
skin
connective tissue
aponeurosis
00se connective tissue
pericranium (periosteum)
outer table of parietal bone
diploë
inner table of parietal bone
cerebral ven tn
subara c no c
superficiaJv·e o scalp
emissa vi
diploic vein
superior sagittal sin
arachnoid granulati
endosteal layer of dura mater
meningeal layer of dura mater
arachnoid
cerebral artery in subarachnoid space
pi ma r
borte

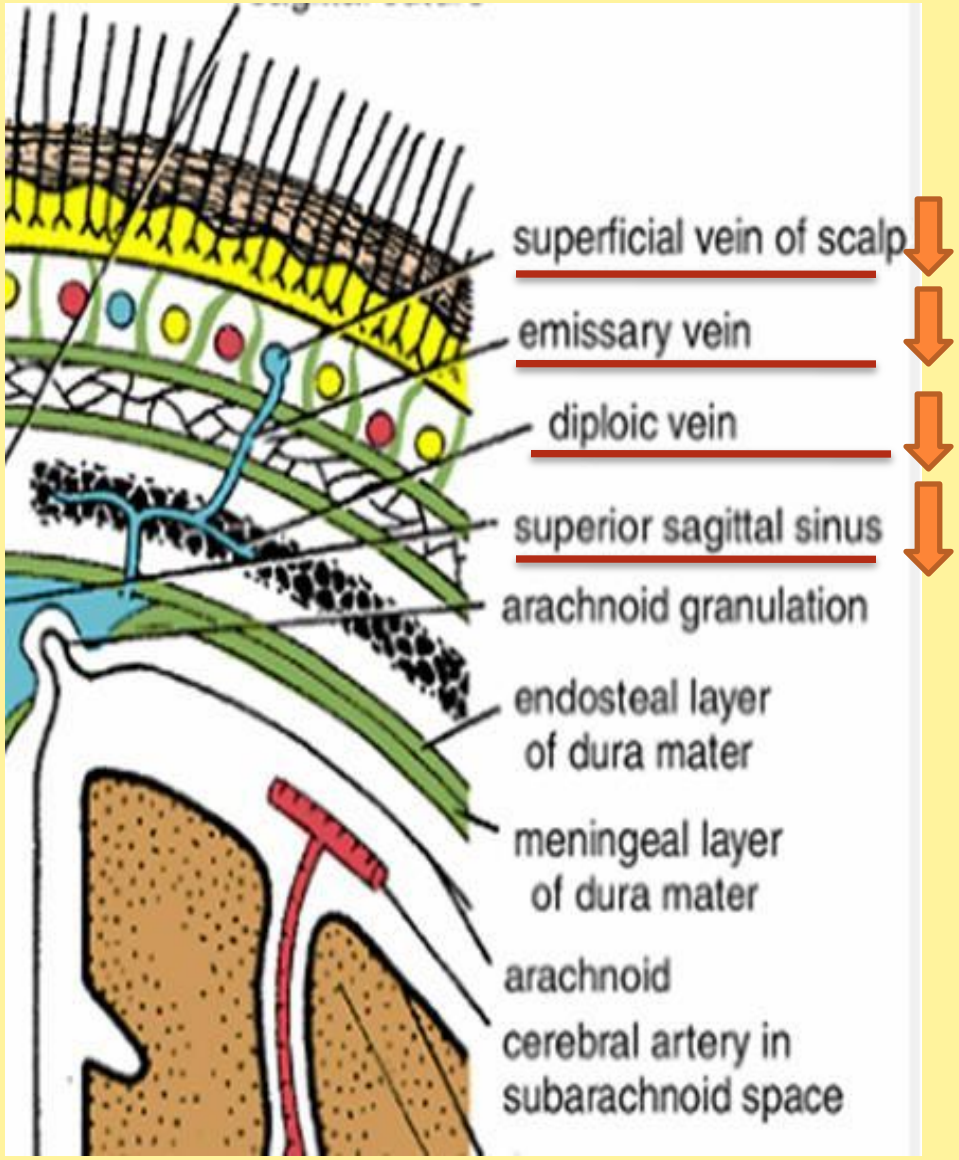

- Made of loose areolar tissue which contains **important emissary veins.**

The emissary veins are **valveless** and connect

The superficial veins of the scalp with the diploic veins of the skull bones

Causing

Osteomyelitis

Infected blood in the diploic veins may travel by the emissary veins farther into the venous sinuses and produce venous sinus thrombosis

5-Pericranium

is the periosteum covering the outer surface of the skull bones. The sutures between individual skull bones, the periosteum on the outer surface of the bones becomes continuous with the periosteum on the inner surface of the skull bones . THEREFORE if there is any fluid collection beneath the pericranium (Cephalhaematoma) it will take the shape of the related bone

A right parietal cephalhematoma was first noted on this -2week-old girl 2days after her birth. Caused by bleeding under the **outer periosteum of a newborn's skull bone, usually the parietal bone**, swelling becomes evident by day 2 or 3after delivery.
The swelling is confined to the involved bone and does not extend beyond the suture lines or the midline of the skull

Treatment with **needle aspiration is contraindicated** because of the possibility of introducing an infection

Muscles of the Scalp

Occipitofrontalis

The origin

Insertion

nerve supply

action

The frontal bellies of the occipitofrontalis can raise the eyebrows in expressions of surprise or horror.

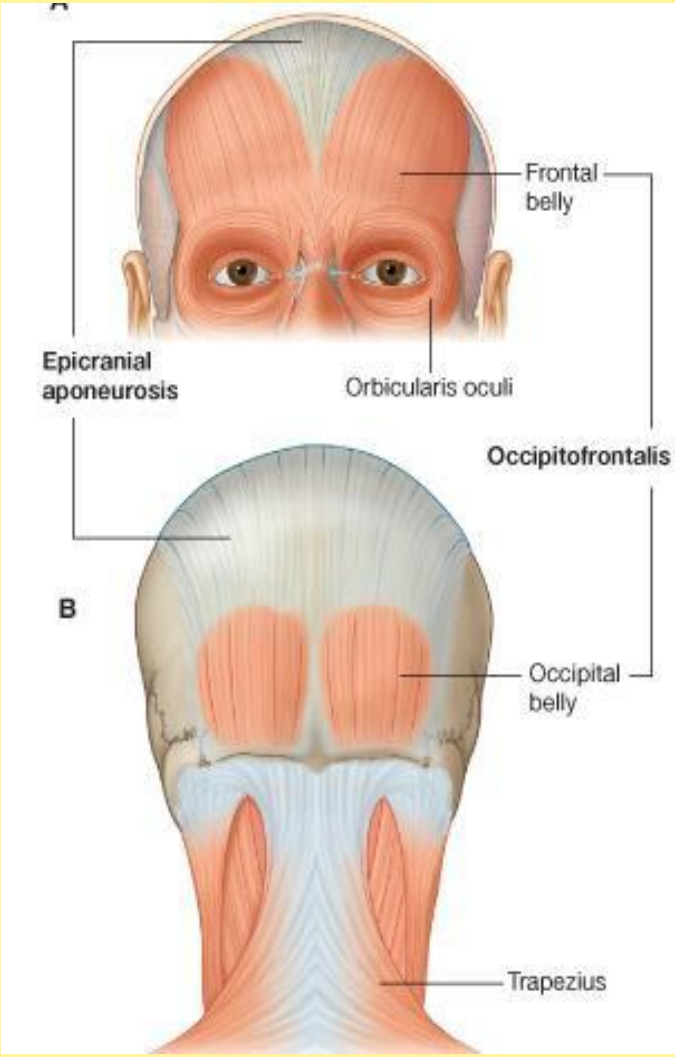

Arterial Supply of the Scalp

The arteries lie in the superficial fascia.

A-Branches of the ophthalmic artery

-1The supratrochlear

-2The supraorbital

B-Branch of the external carotid arter

y **The superficial temporal artery The posterior auricular artery**

The occipital artery

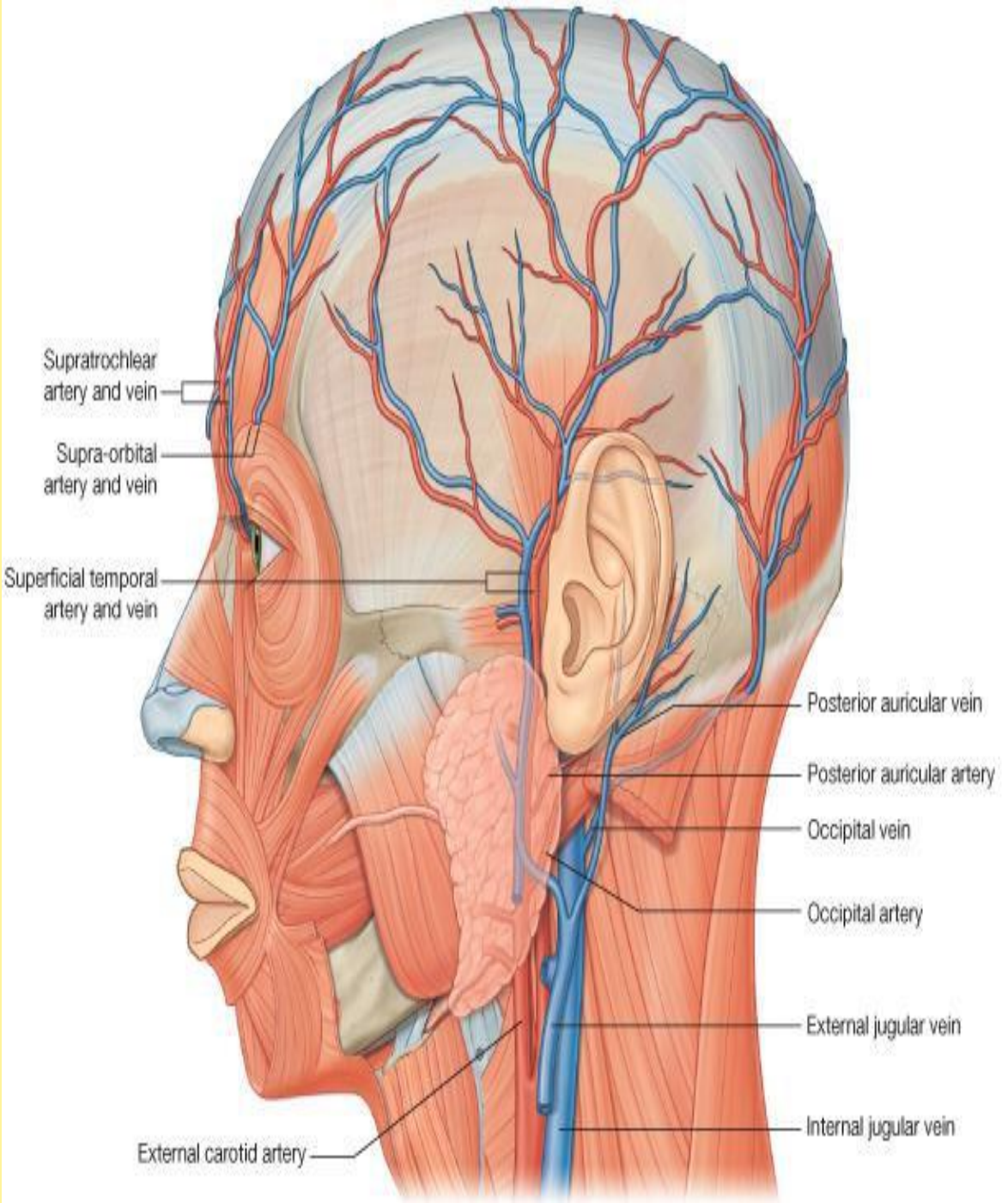

Anatomically, it is useful to remember in an emergency that

all the superficial arteries supplying the scalp

ascend from the face and the neck.

Thus, in an emergency situation, **encircle the head just above the ears and eyebrows** with a tie, shoelaces, or even a piece of string and tie it tight. Then insert a pen, pencil, or stick into the loop and rotate it so that the tourniquet exerts pressure on the arteries

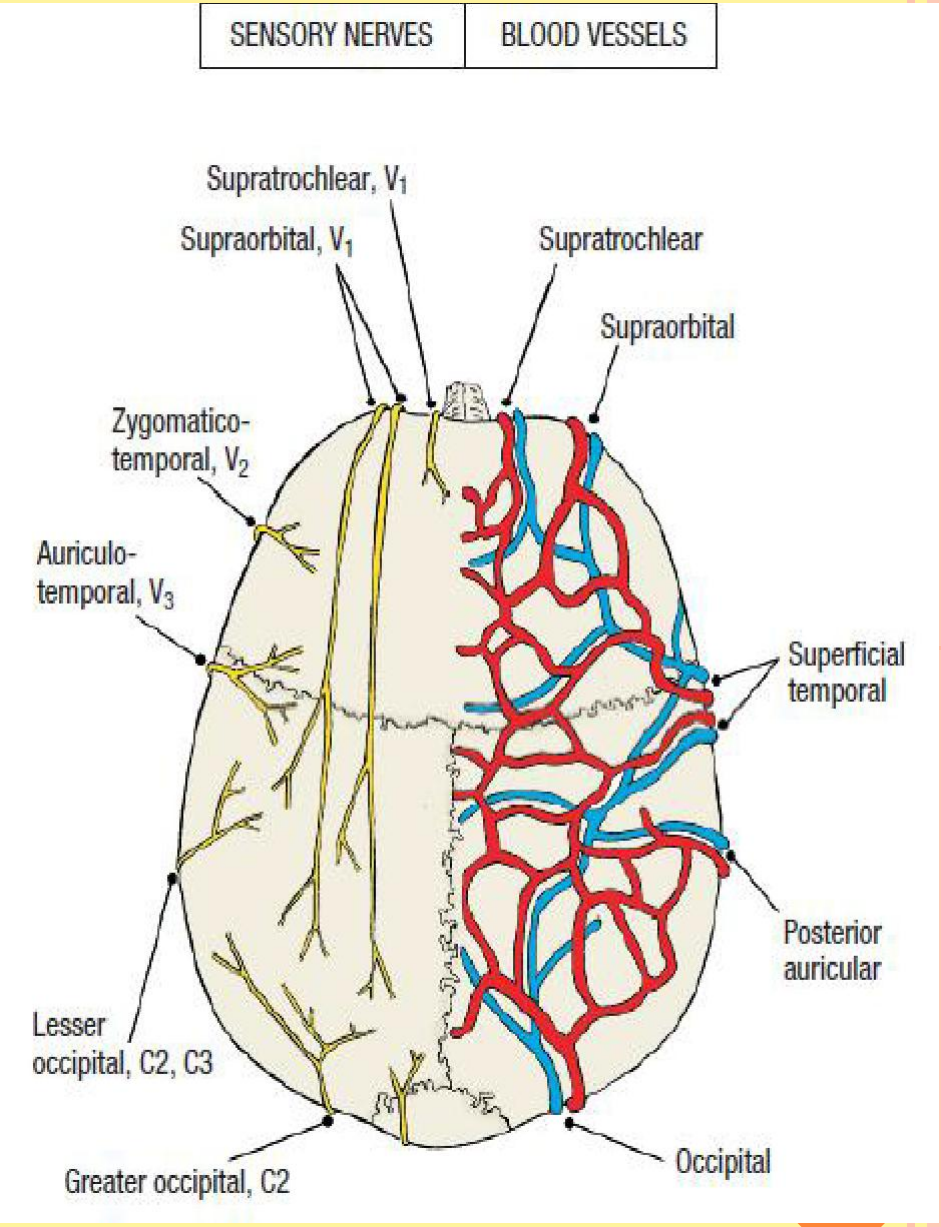

The facial artery

➢Arises from ***the external carotid artery***

Ascends ***over the submandibular salivary gland***

➢It curves around the inferior margin of the body of **the mandible**

➢Passes on and in front of the anterior border of the masseter muscle (pulse|(

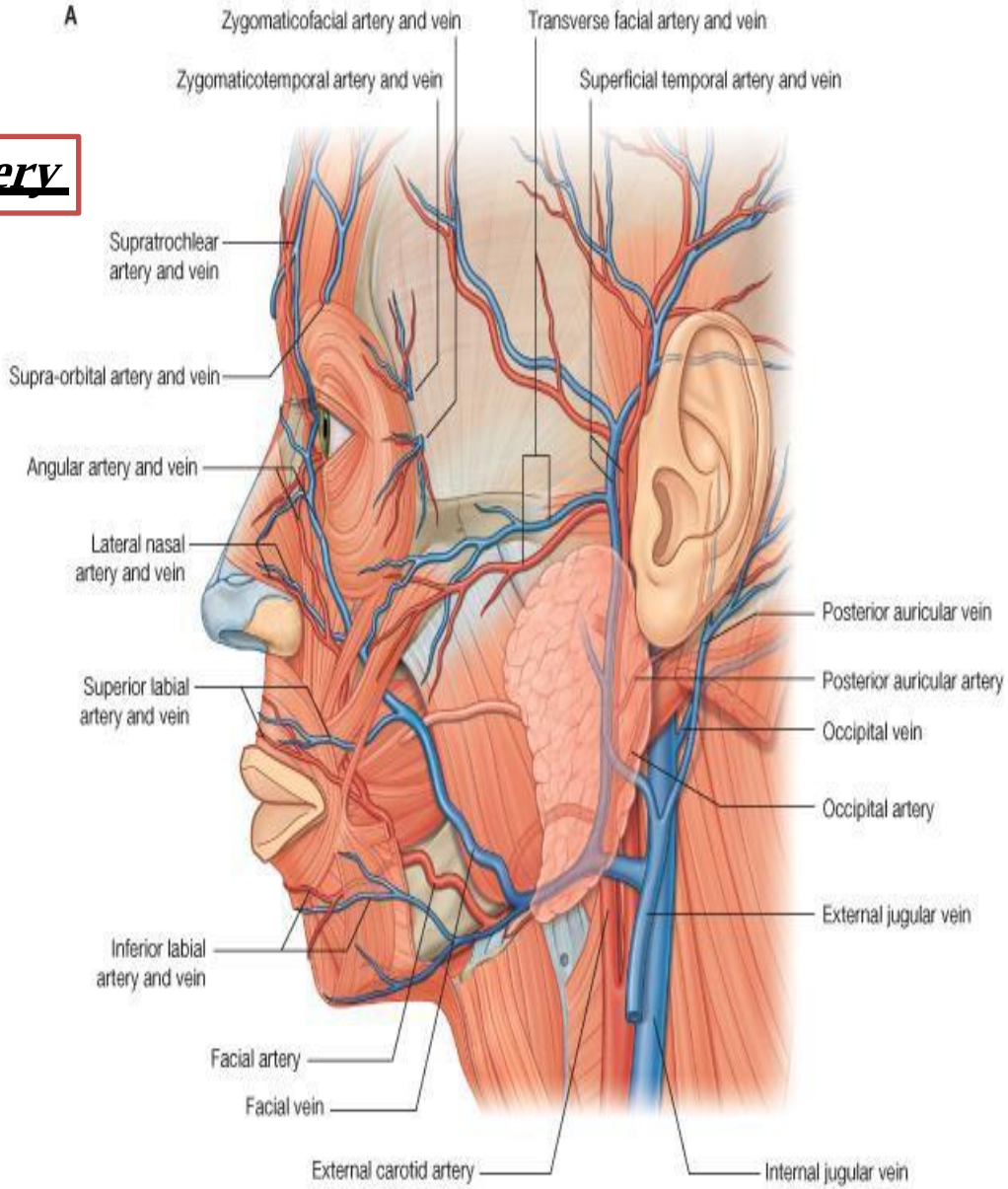

➢It runs upward **in a tortuous** course toward the angle of the mouth

➢It then ascends deep to the zygomaticus muscles and runs along ***the side of the nose to the medial angle of the eye,*** where it anastomoses with the terminal branches of ***the ophthalmic artery***

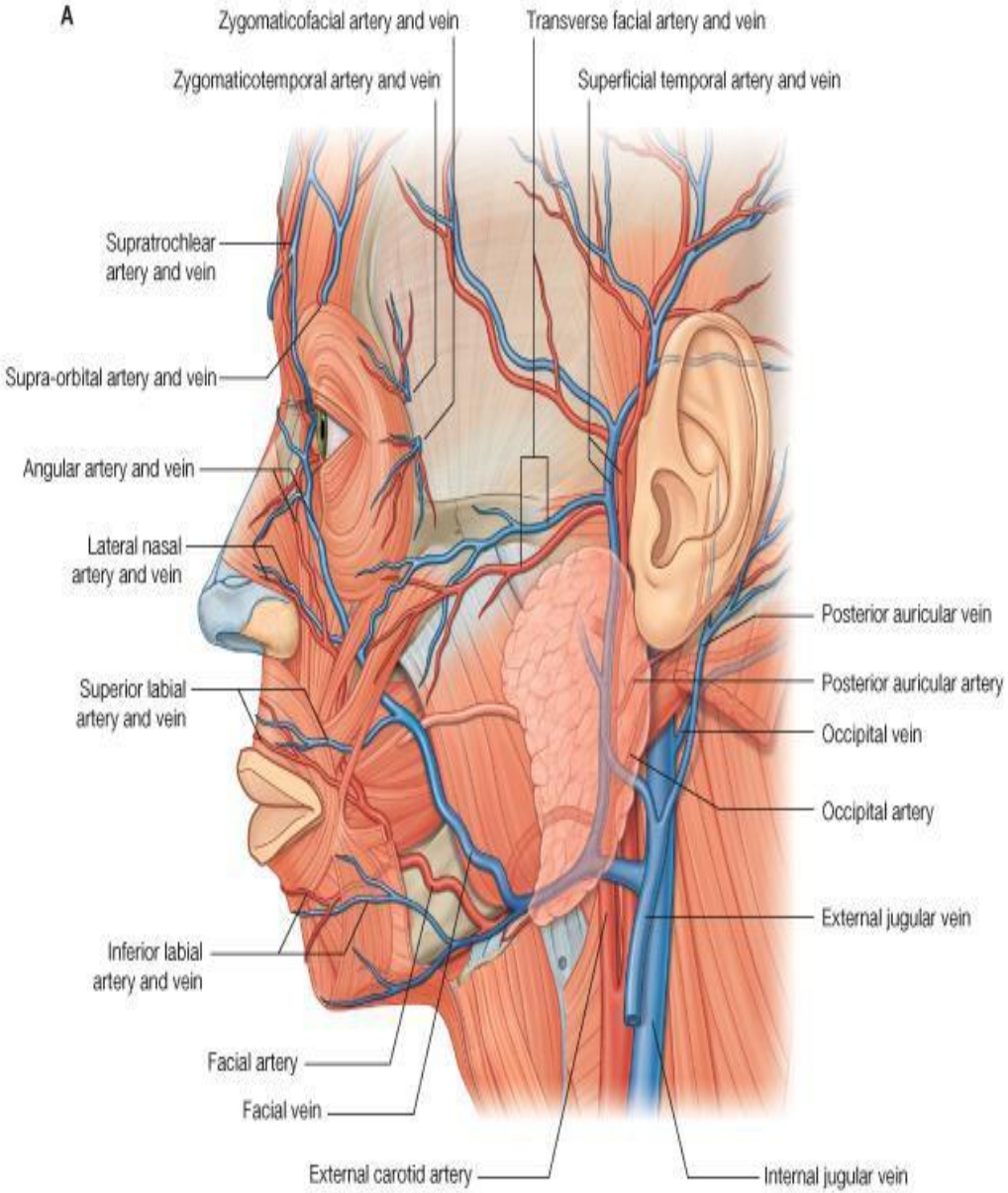

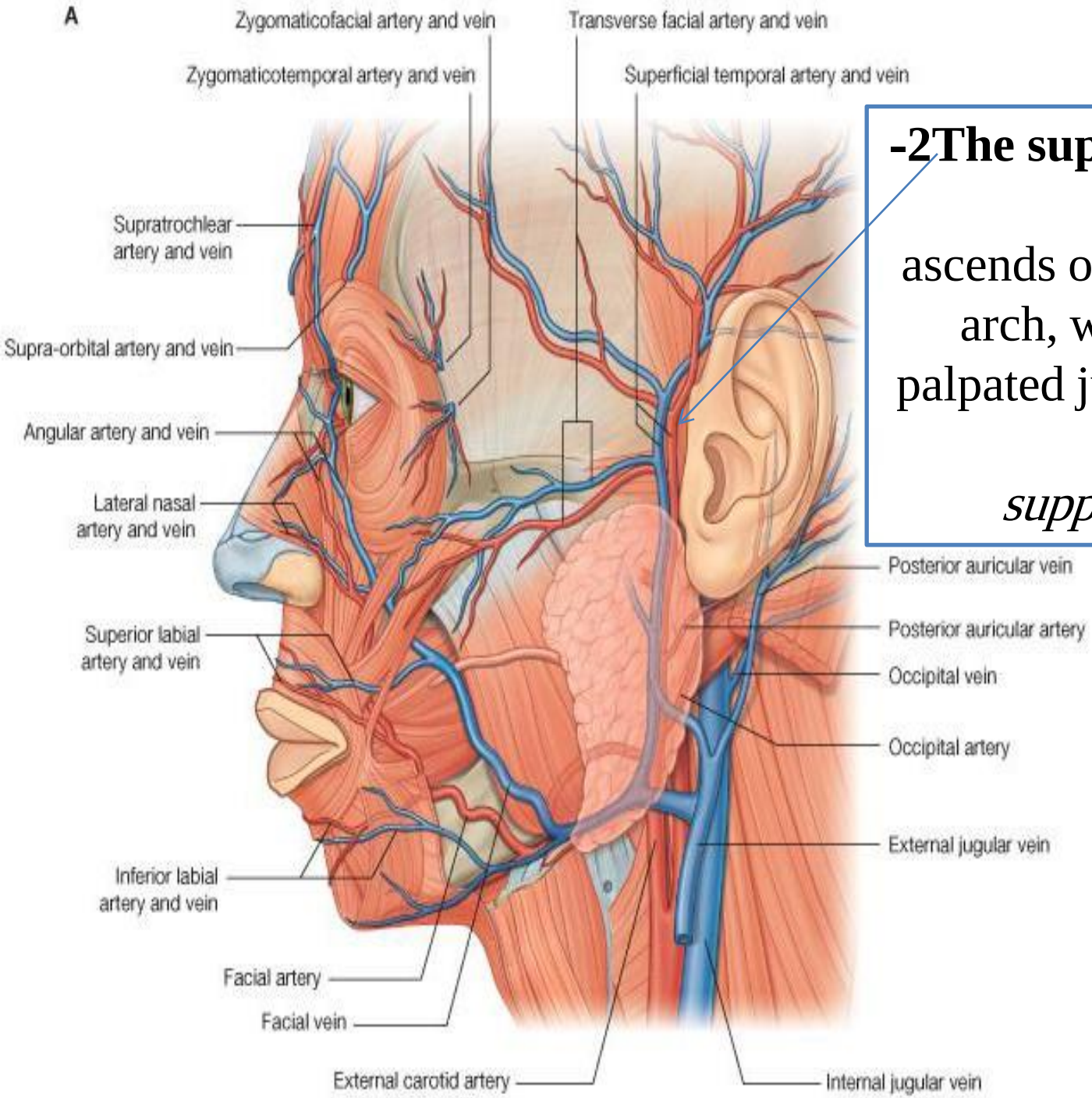

-2The superficial temporal artery

ascends over the zygomatic arch, where it may be palpated just **in front of the auricle،**

supplies the scalp

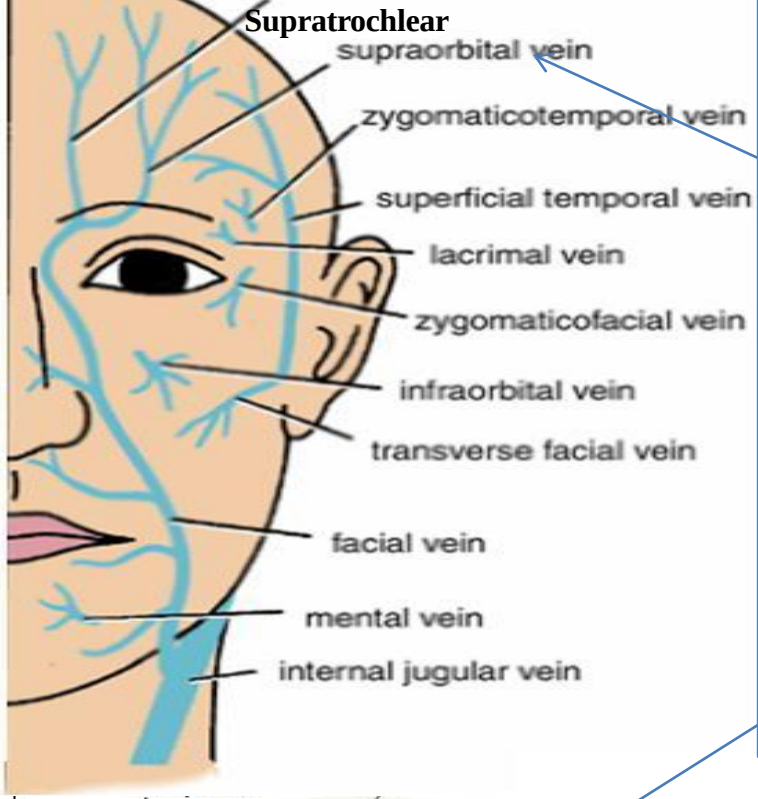

Venous Drainage of the Face

The facial vein is formed at the medial angle of the eye by the union of

The Supraorbital and Supratrochlear veins

The facial vein descends behind the facial artery to the **lower margin of the body of the mandible**

It crosses superficial to the submandibular gland and is joined by the *anterior division of*

The retromandibular vein.

The facial vein ends by draining into

The internal jugular vein.

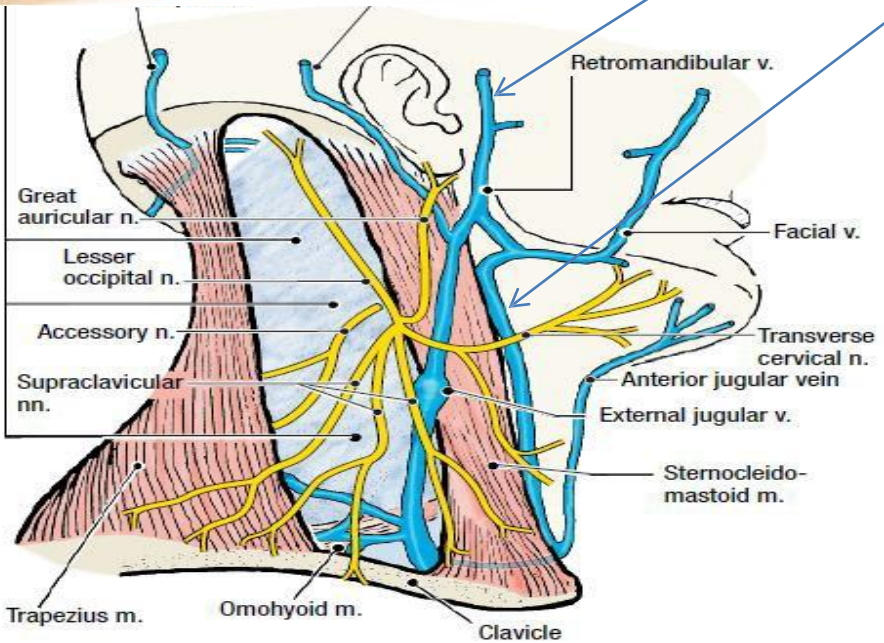

Important communications

It communicates with the pterygoid venous plexus **<u>by the deep facial vein</u>**

It communicates with the cavernous sinus by the **<u>superior ophthalmic vein</u>**

It is connected to ***the superior ophthalmic vein*** directly through the supraorbital vein. By means *of the superior ophthalmic vein,* the facial vein is connected to

The cavernous sinus

this connection is of a great clinical importance because it provides

a pathway for the spread of infection from DANGEROUS AREA OF THE FACE

)THE LOWER PART OF THE NOSE AND THE UPPER LIP(

to the cavernous sinus

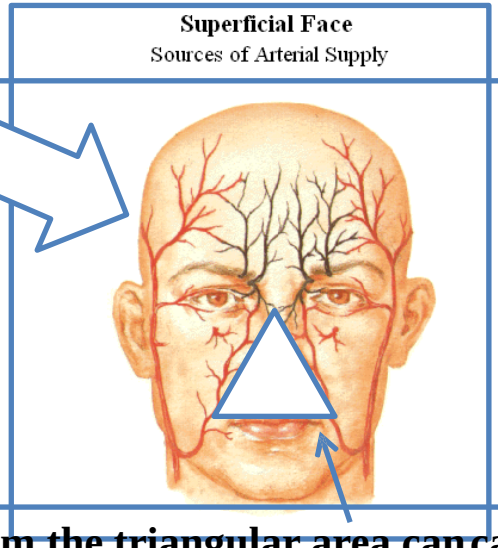

Infection from the triangular area can cause

Thrombosis of the cavernous sinus

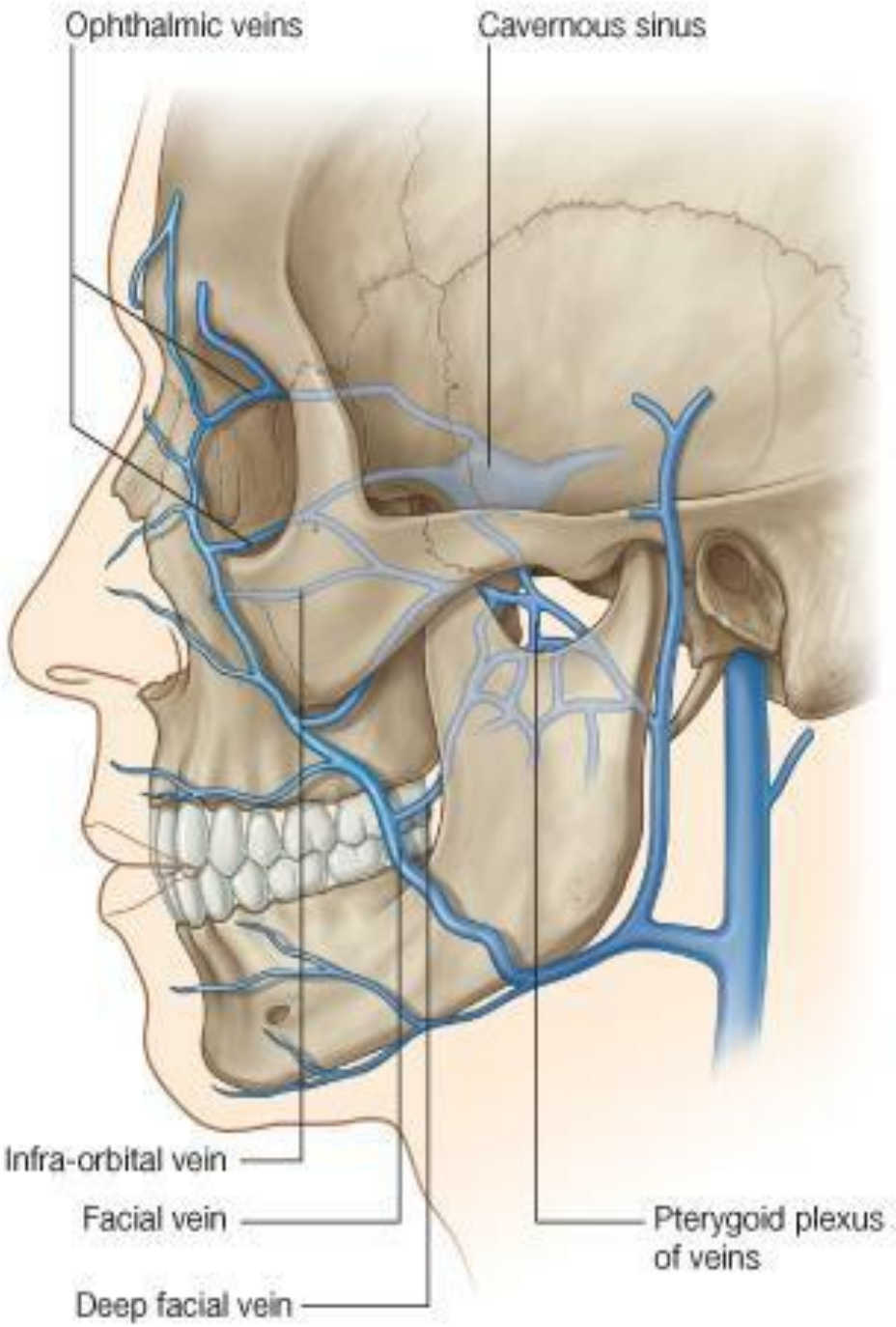

Arterial Supply of the Scalp

The arteries lie in the superficial fascia.

A-Branches of the ophthalmic artery

1 The supratrochlear

2 The supraorbital

B-Branch of the external carotid artery

The superficial temporal artery

The posterior auricular artery

The occipital artery

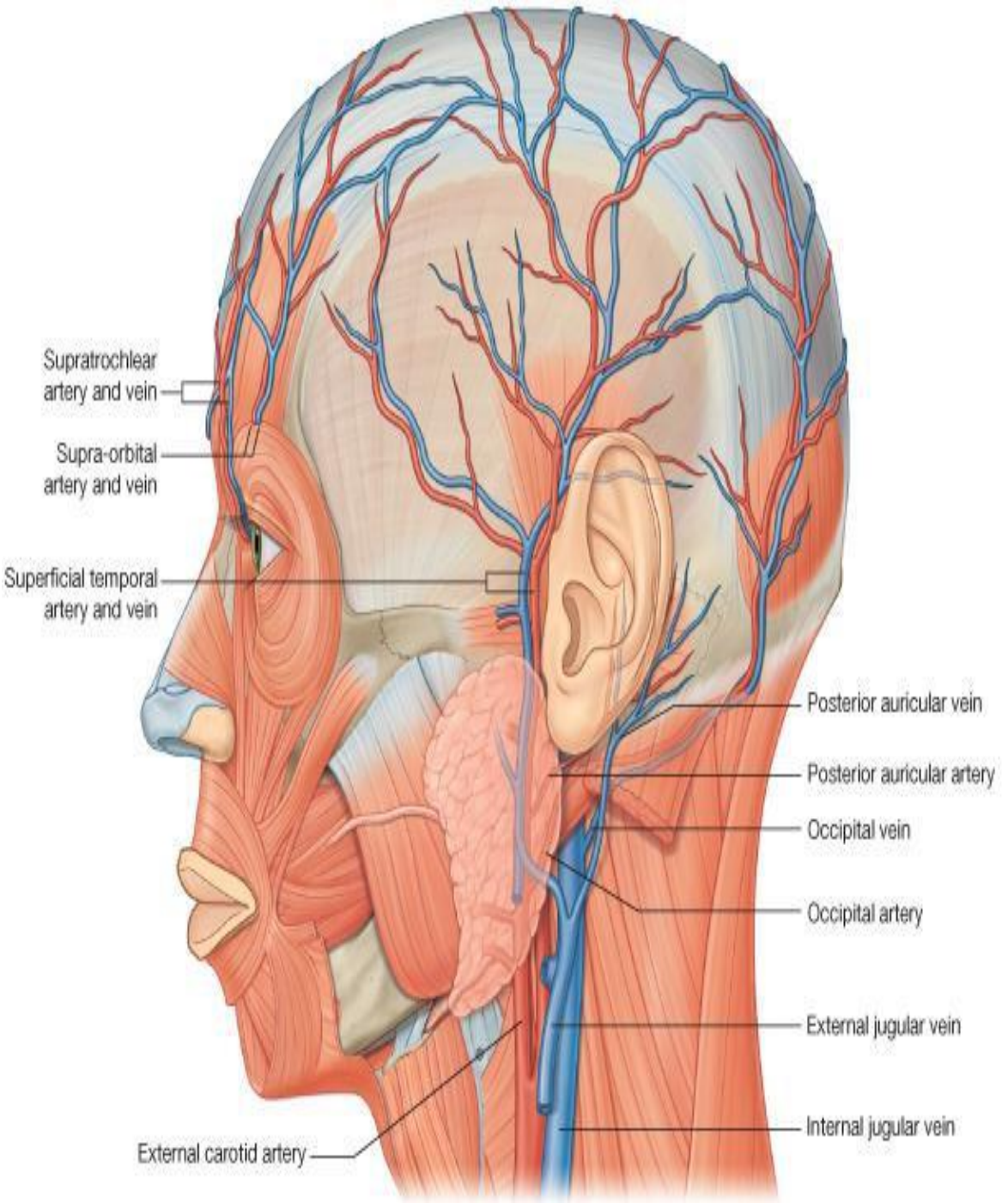

Anatomically, it is useful to remember in an emergency that

all the superficial arteries supplying the scalp

ascend from the face and the neck.

Thus, in an emergency situation، **encircle the head just above the ears and eyebrows** with a tie, shoelaces, or even a piece of string and tie it tight. Then insert a pen, pencil، or stick into the loop and rotate it so that the tourniquet exerts pressure on the arteries