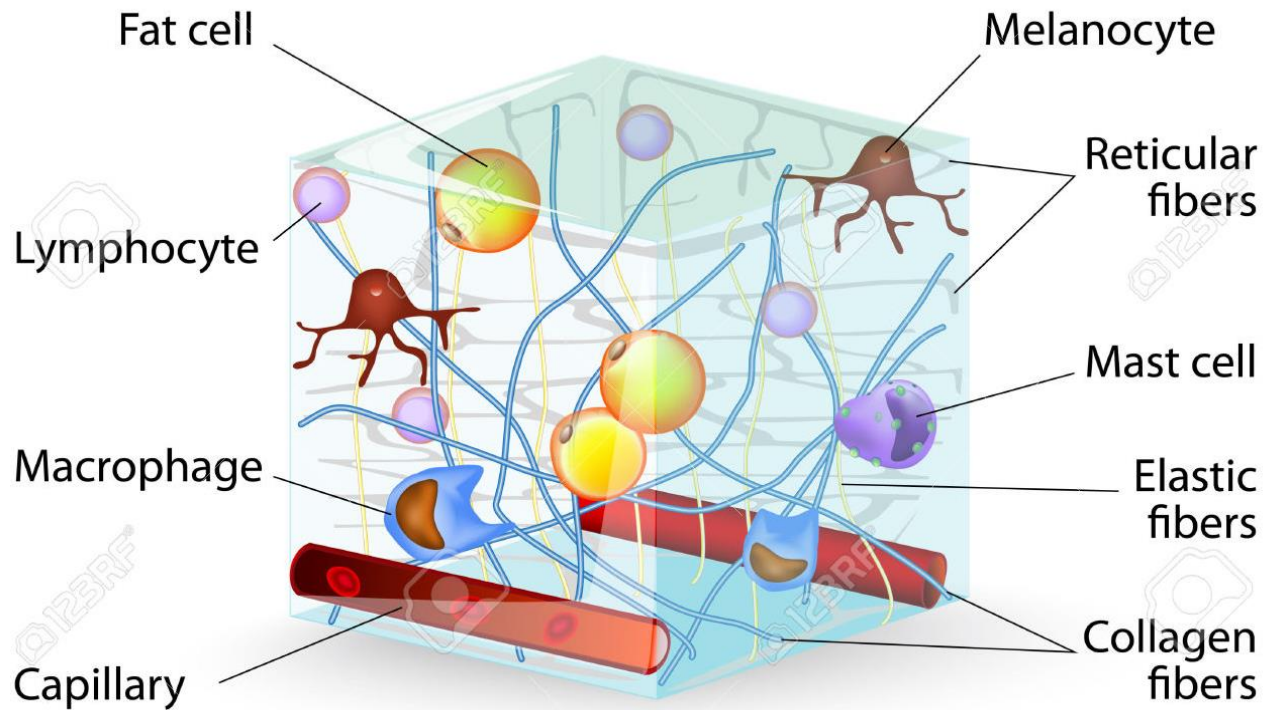


Connective Tissue



General Features



Originates from the mesoderm (Except some parts of the head and neck).

Composed of cells (fixed and wandering), fibres and ground substance.

Variable vascularity.

Variable regenerative power.

Functions of connective tissue

Structural framework for body.

Transportation of fluids and dissolved substances.

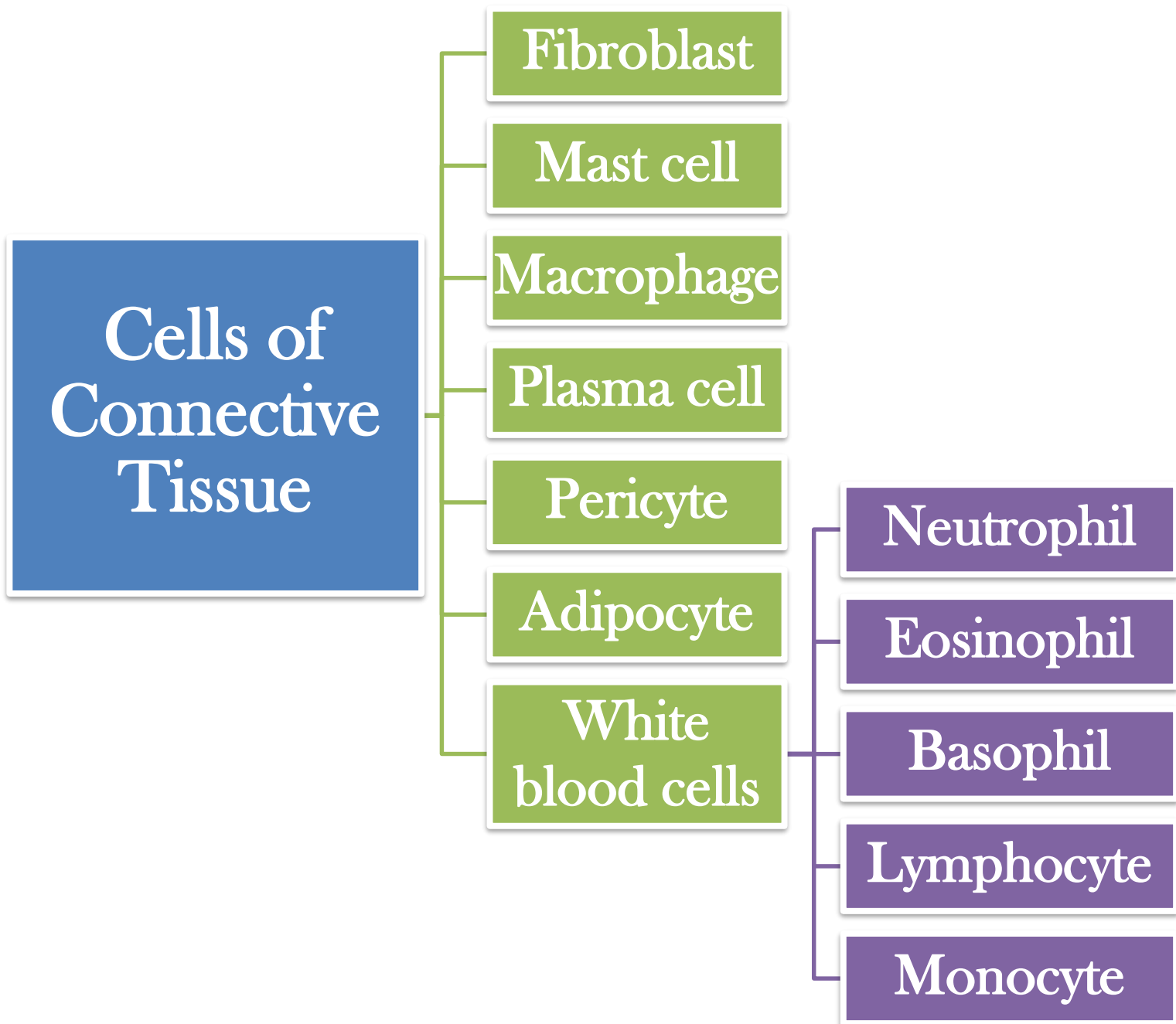
Protection of delicate organs.

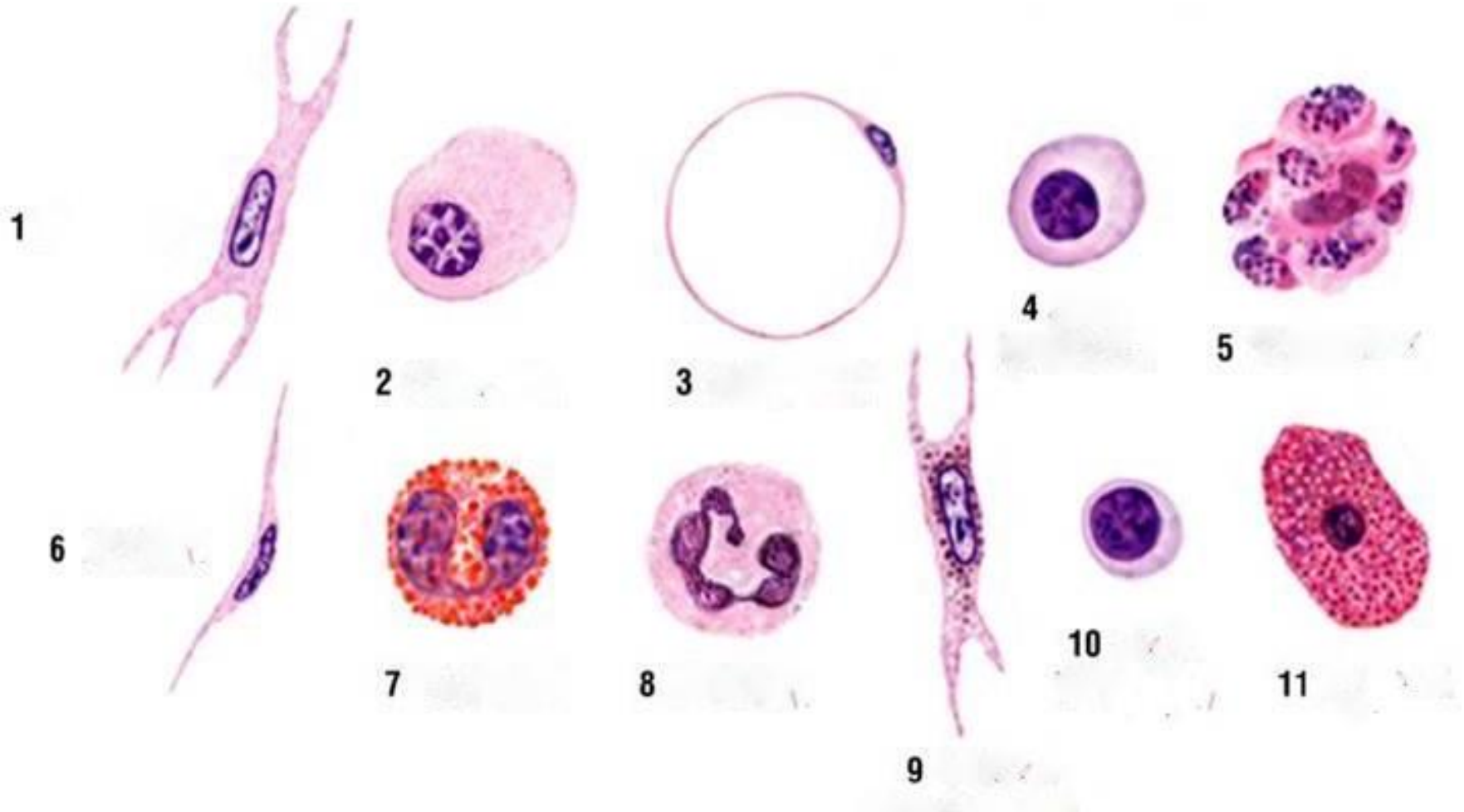
Supports, surrounds, and connects other tissues.

Storage of energy in the form of lipids.

Defend the body against microorganisms.

Cellular Components of connective tissue





- | | | | |
|--------------------------------|----------------|----------------------|---------------------|
| 1. Fibroblast | 2. Plasma cell | 3. Adipocyte | 4. large lymphocyte |
| 5. Macrophage | 6. Fibrocyte | 7. Eosinophil | 8. Neutrophil |
| 9. Cell with pigment granulaes | | 10. Small lymphocyte | |
| 11. Mast cell | | | |

Connective tissue cells

Fibroblasts: Secrete both fibers and ground substance of the matrix.


Macrophages: Phagocytes that develop from Monocytes

Plasma Cells: Antibody secreting cells that develop from B Lymphocytes

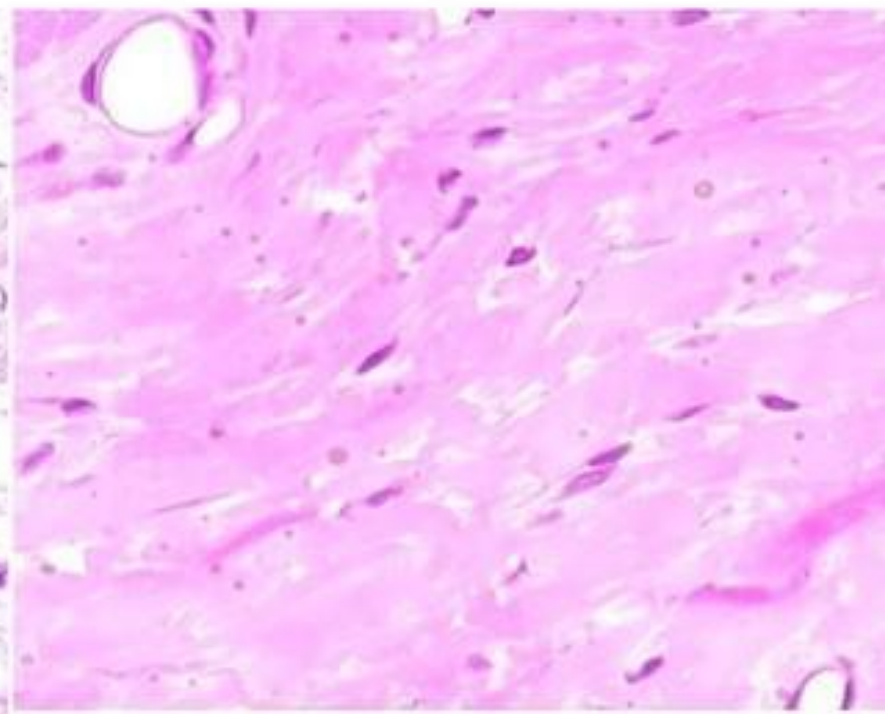
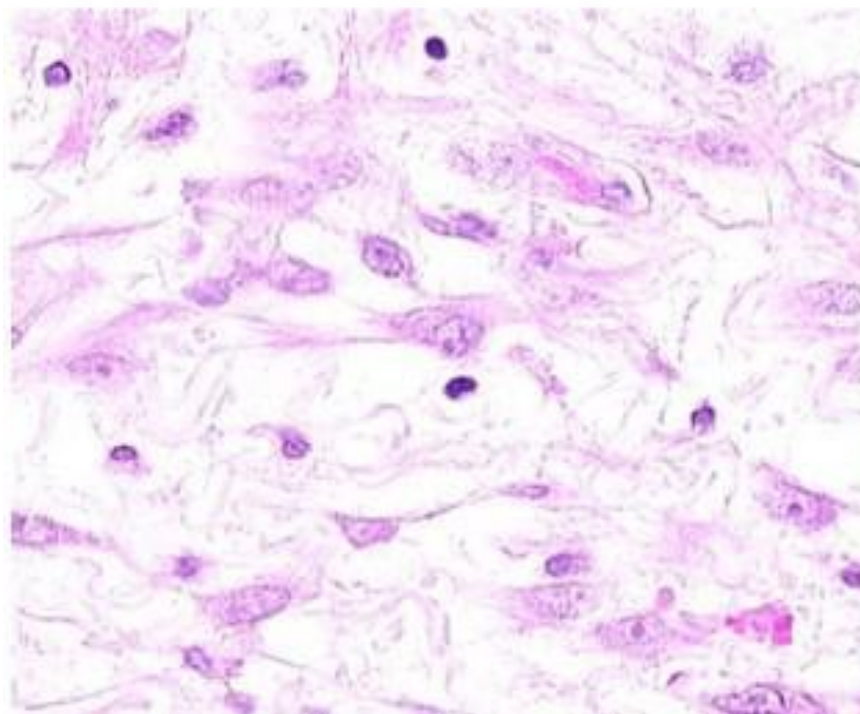
Mast Cells: Produce histamine that helps dilate small blood vessels in reaction to injury.

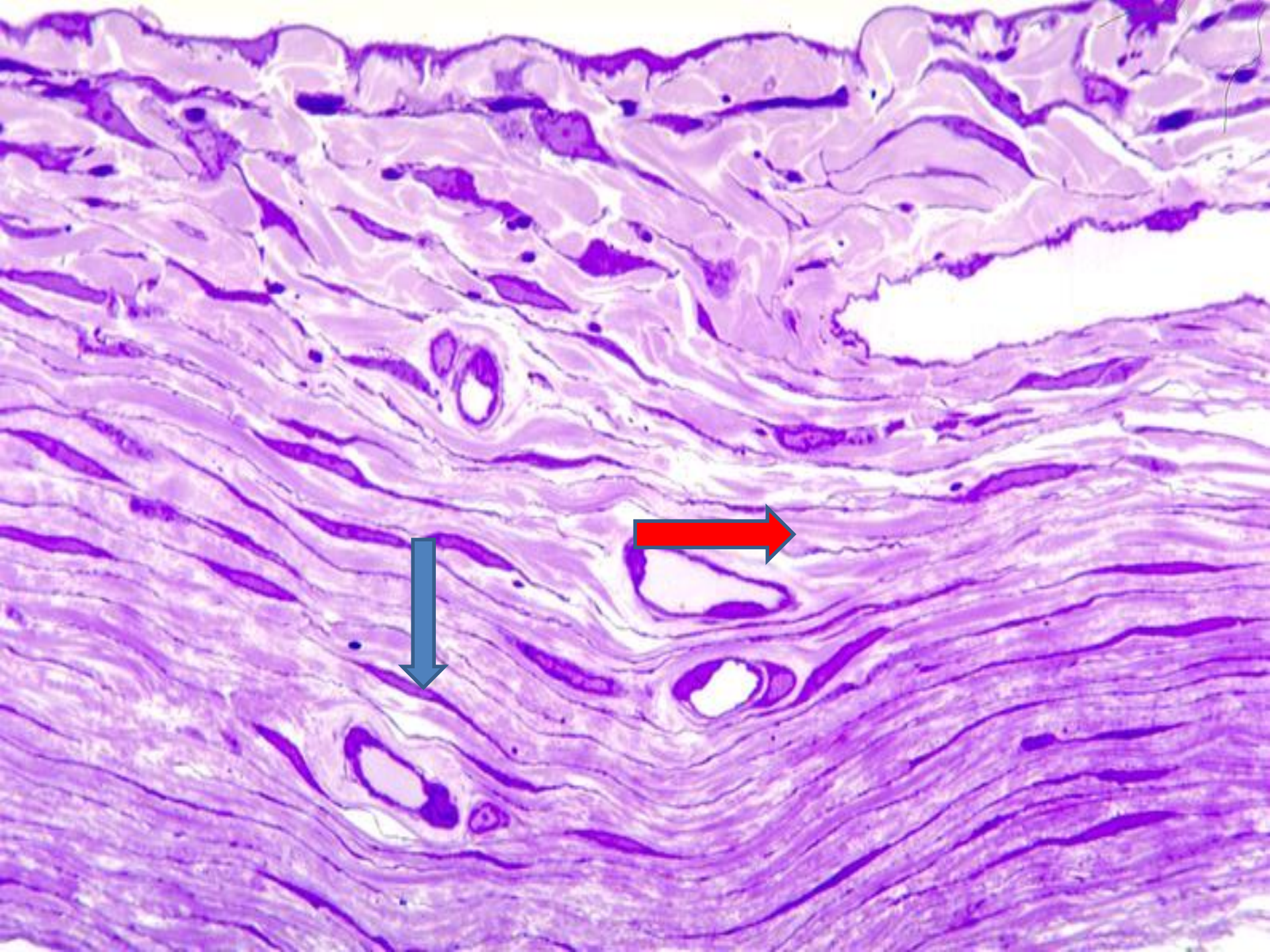
Adipocytes: Fat cells that store triglycerides, support, protect and insulate.

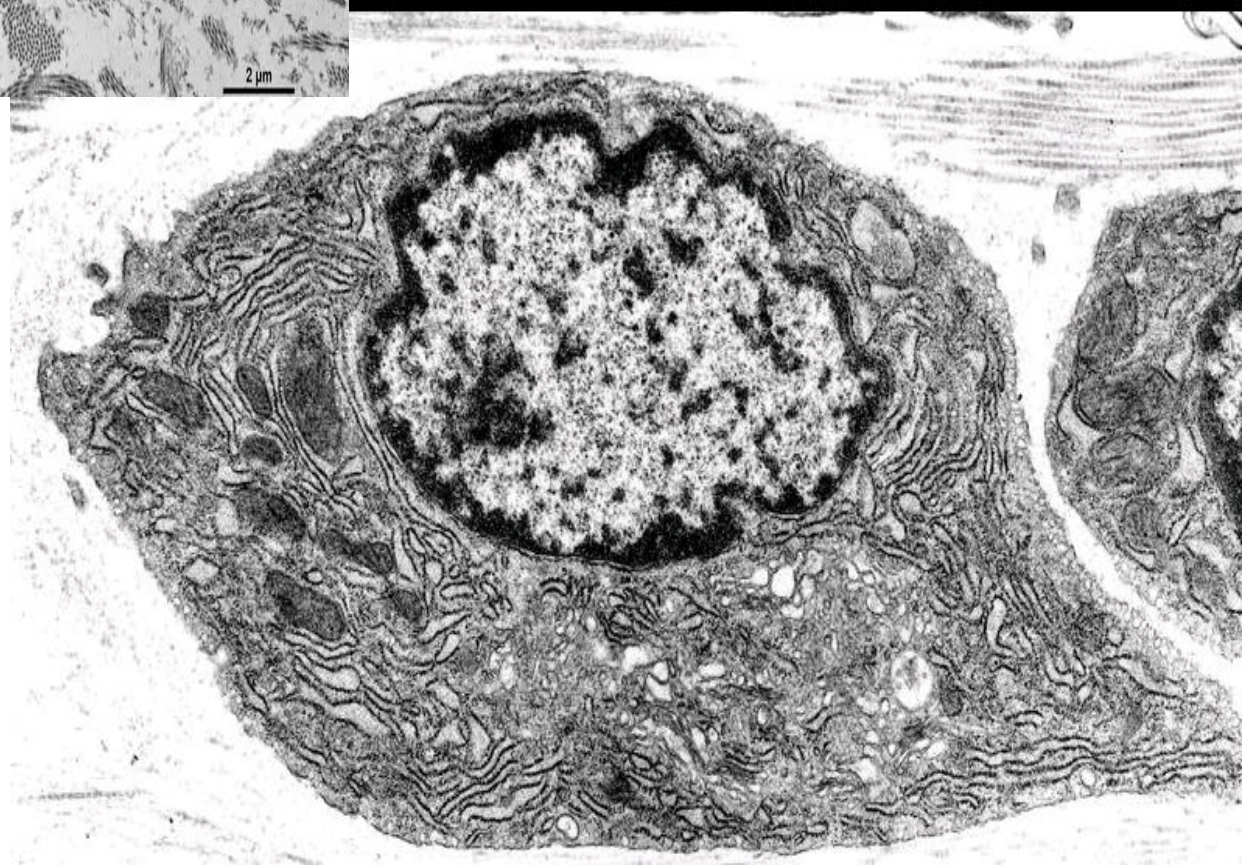
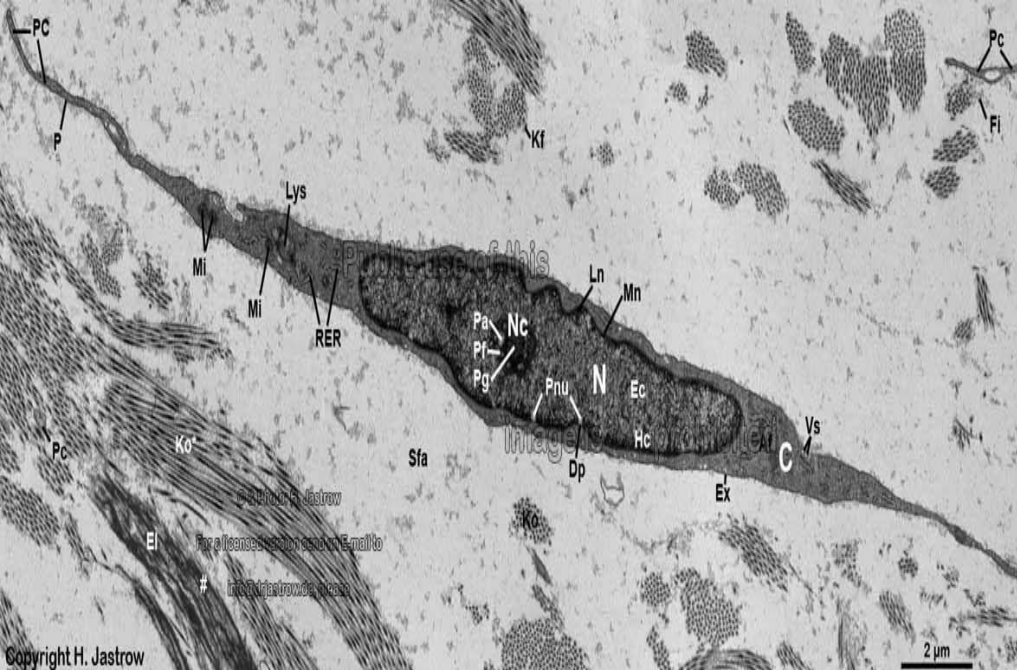**Fibroblast /
Fibrocyte**



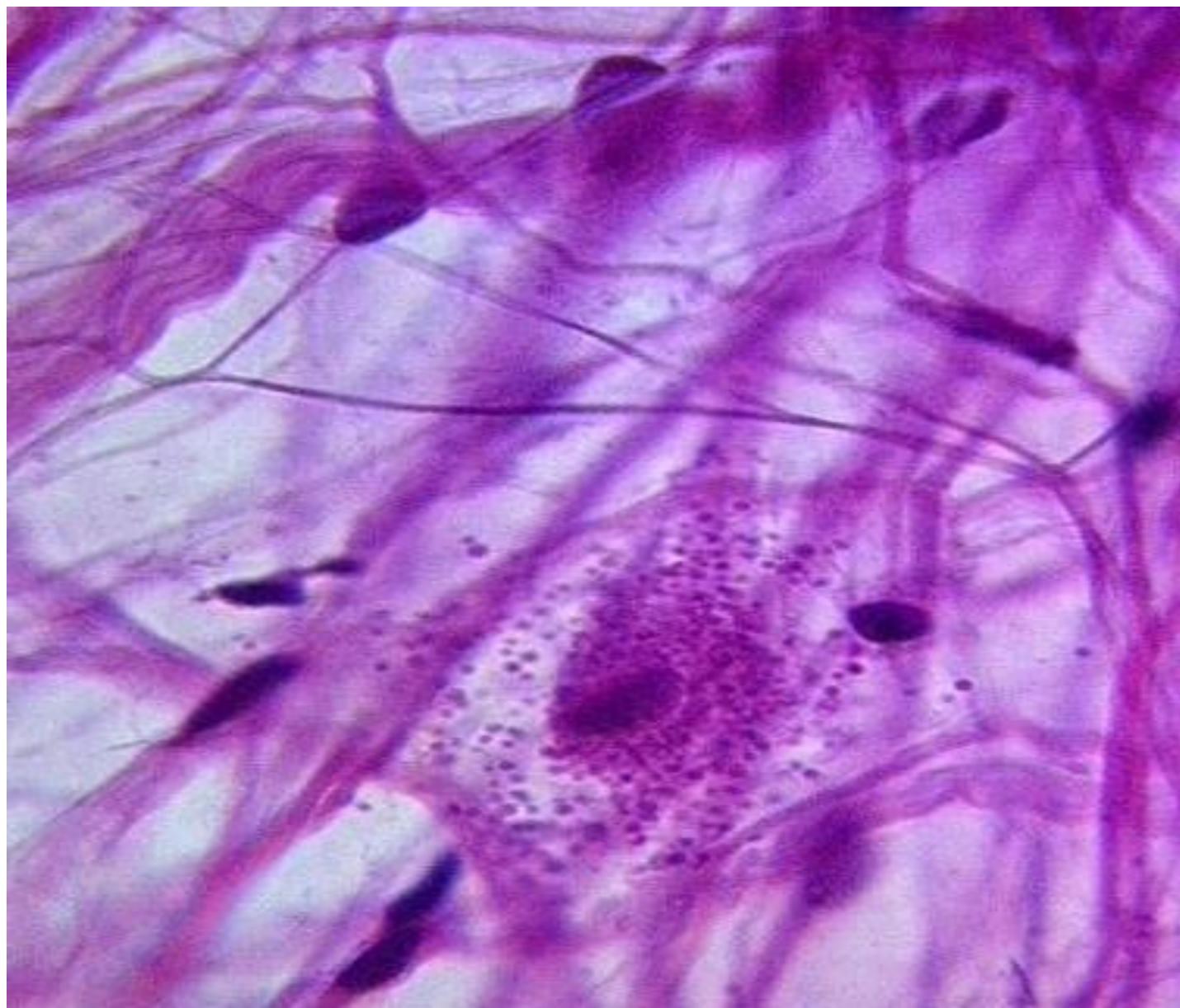
<http://www.servier.com/Powerpoint-image-bank>

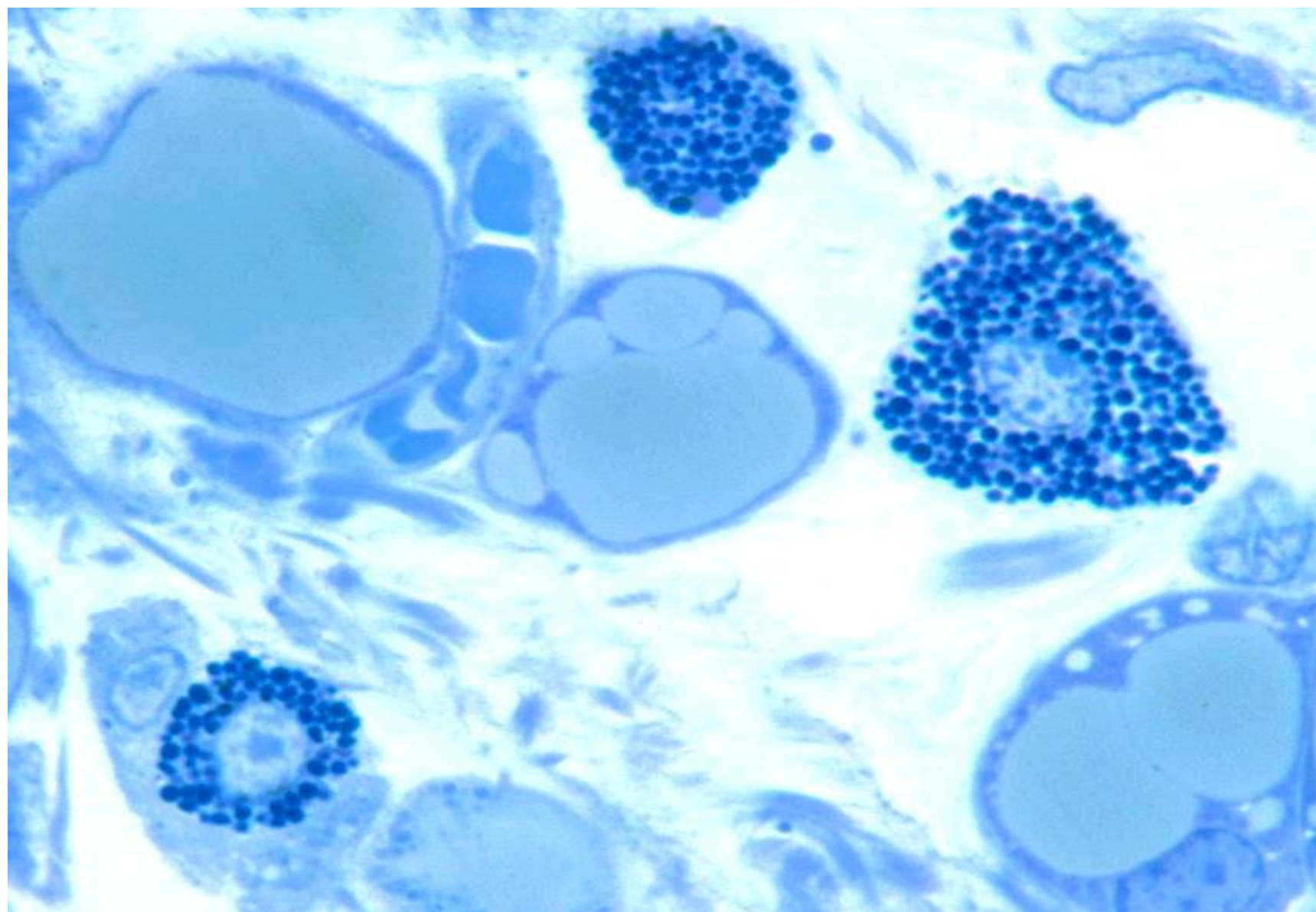


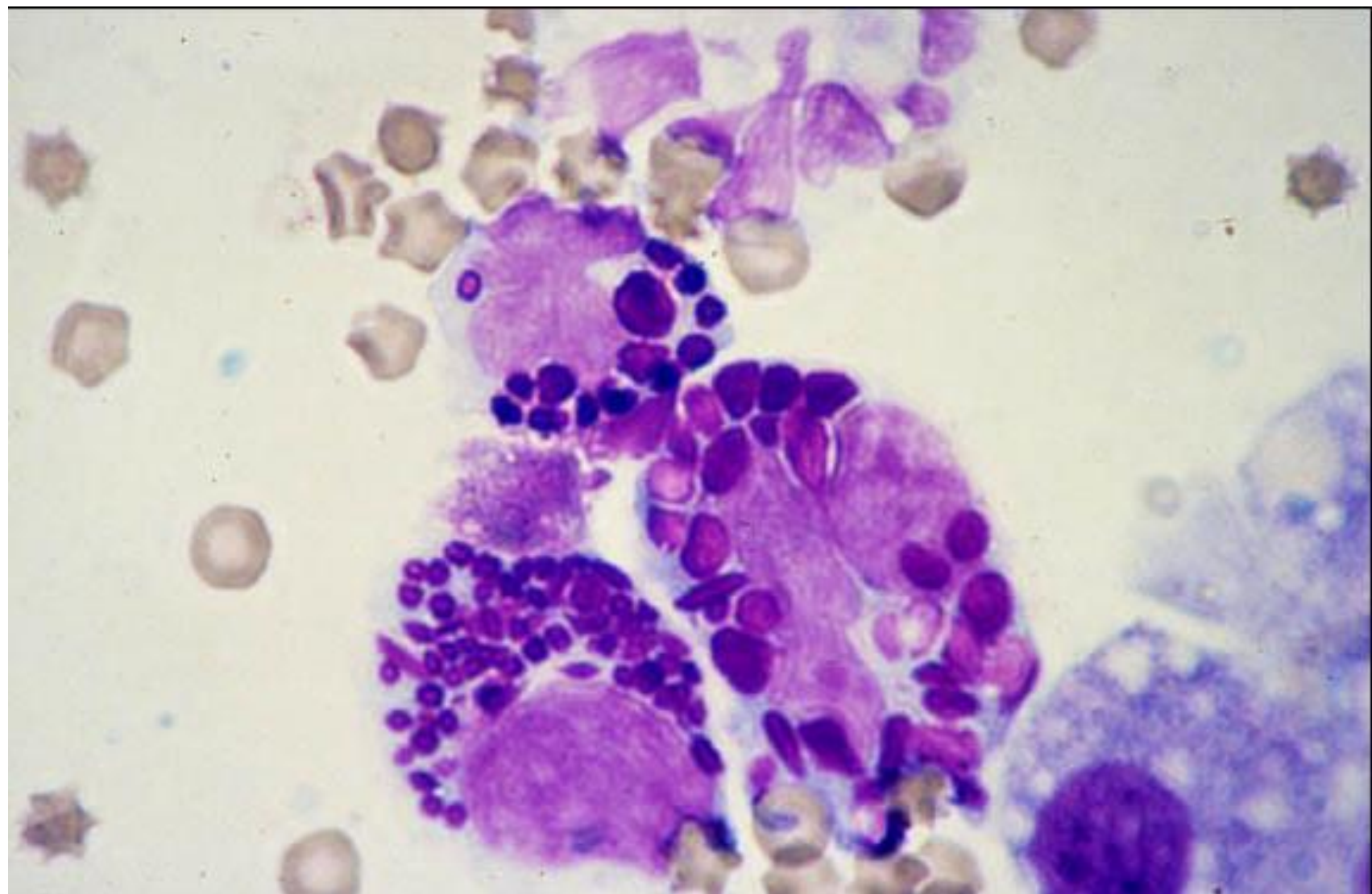


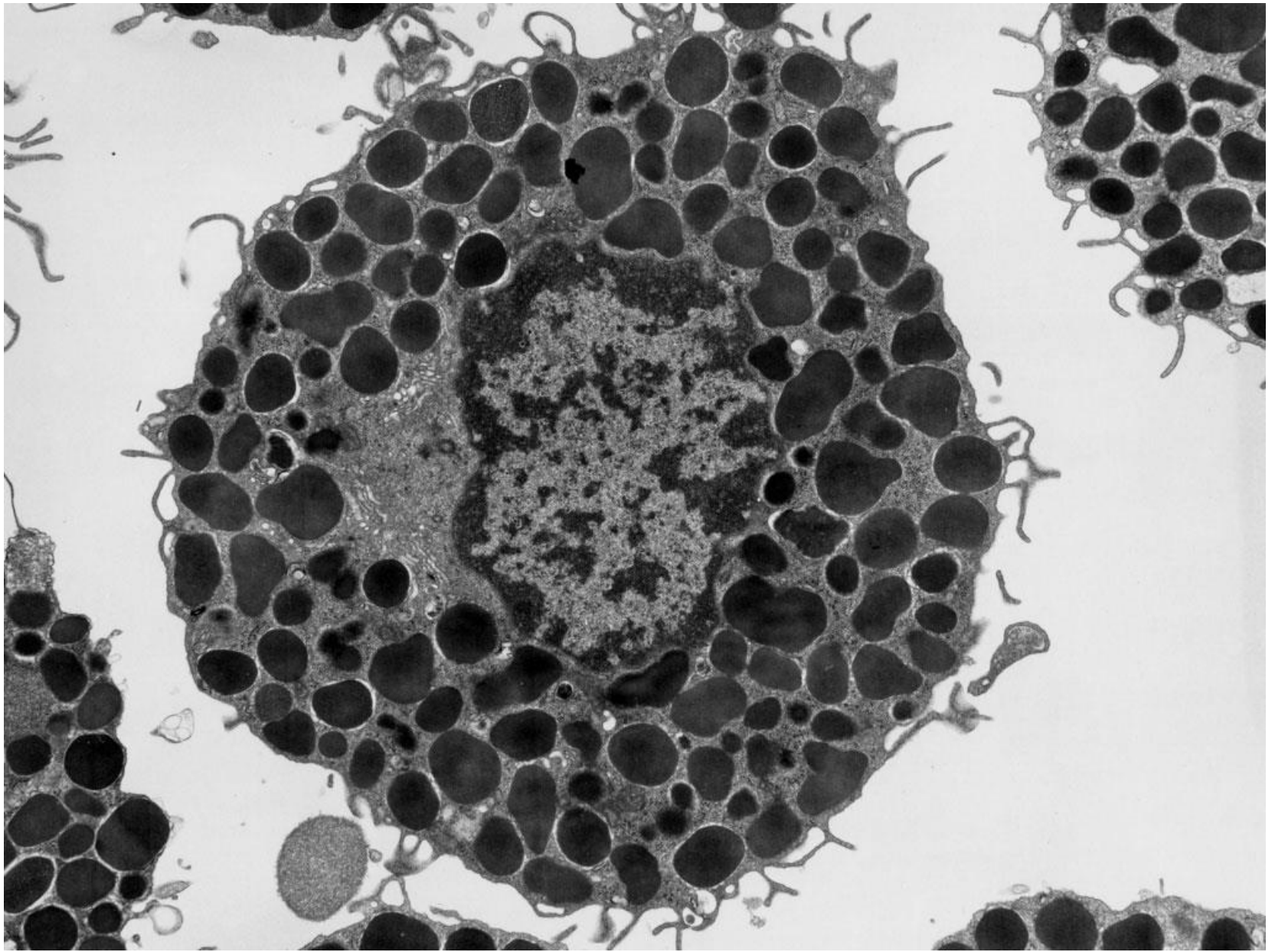


Mast cell



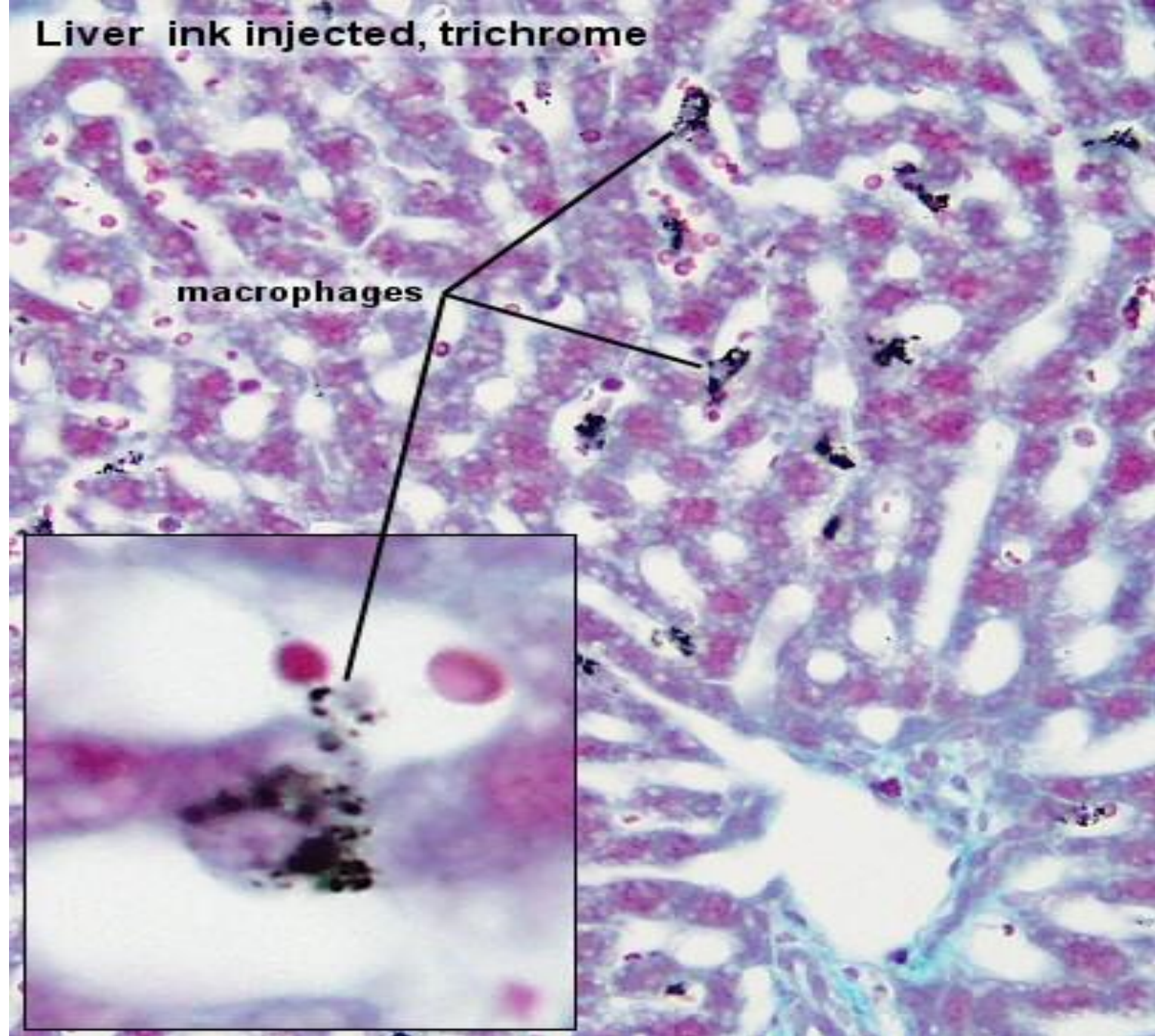


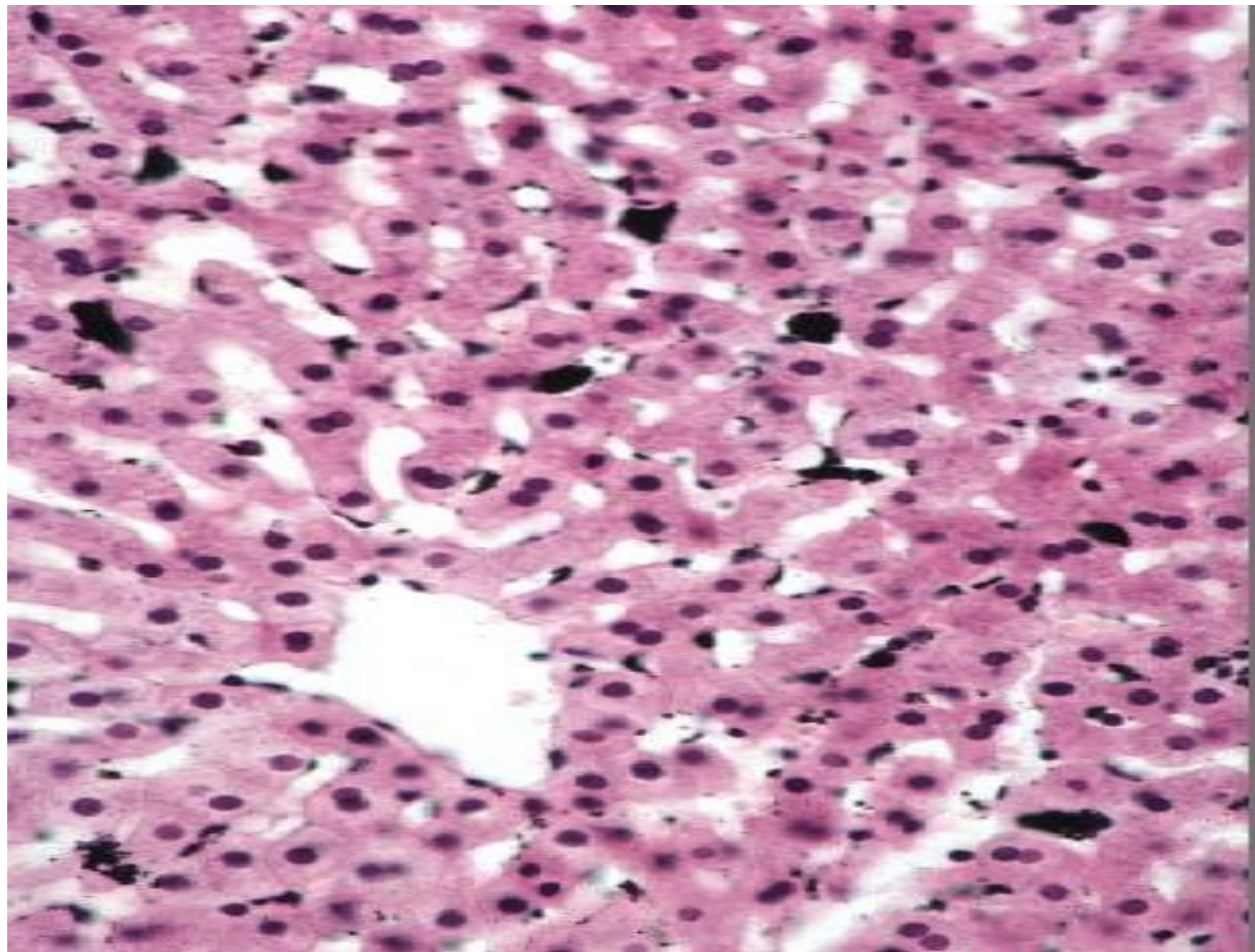


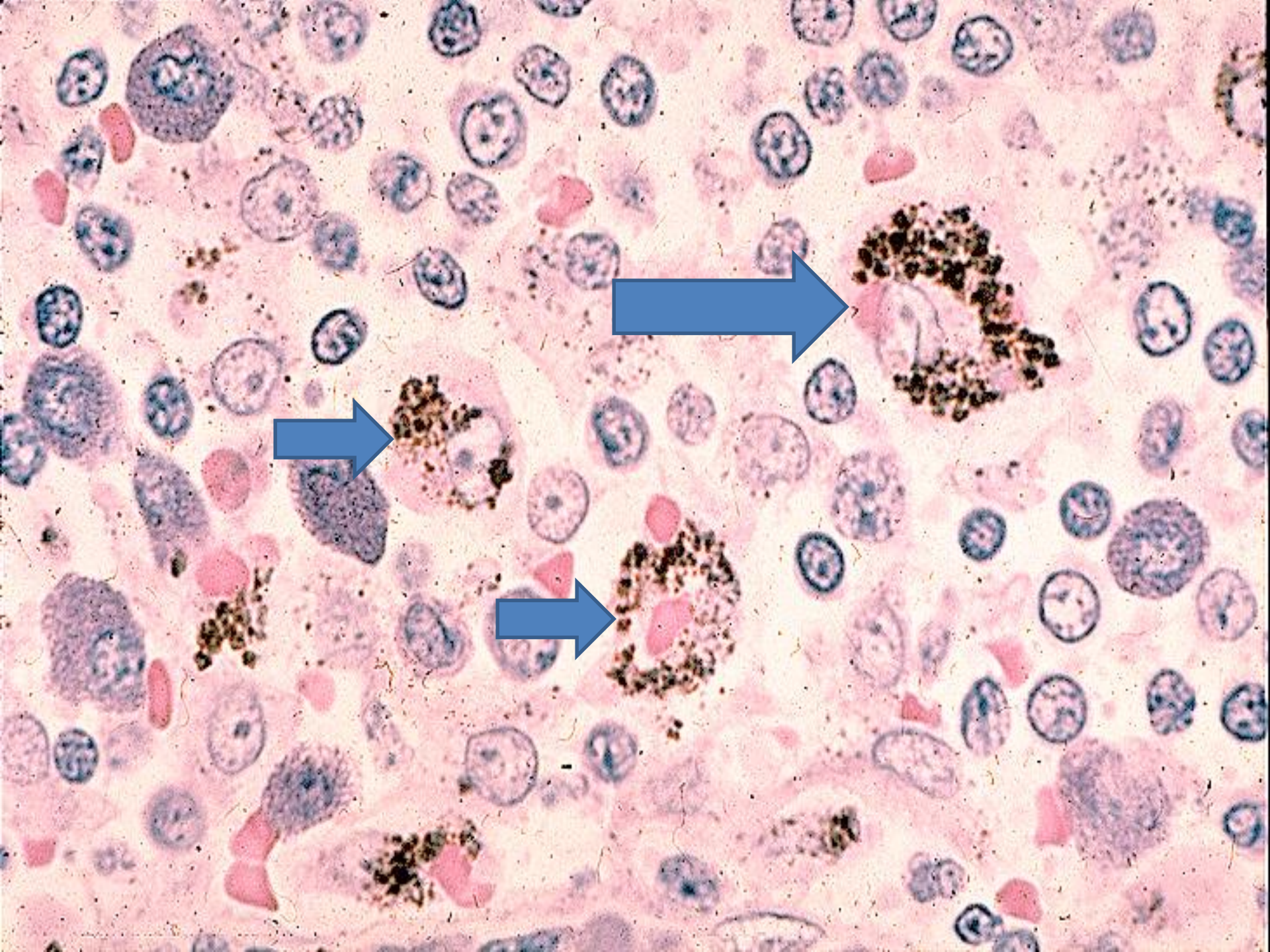


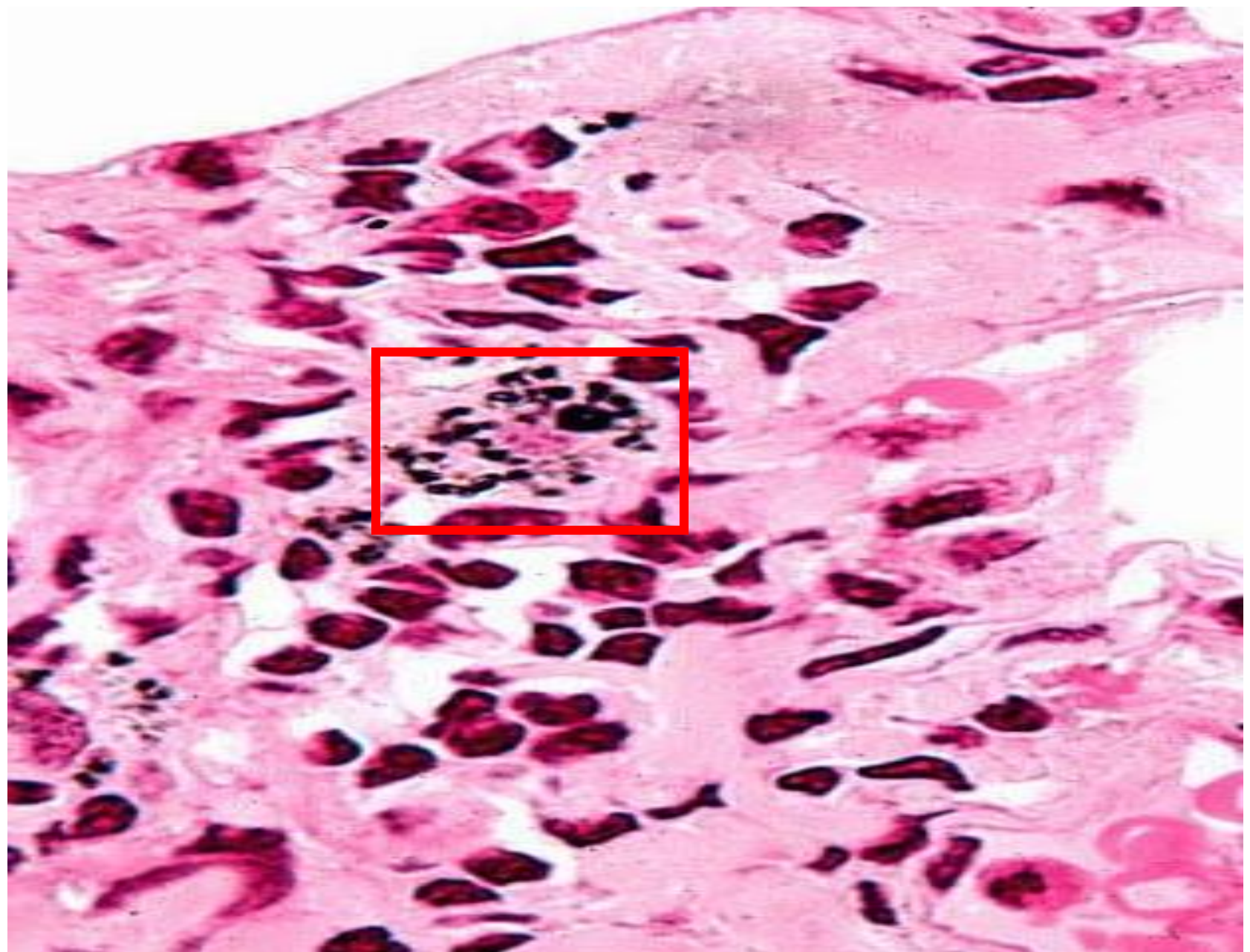
Macrophage

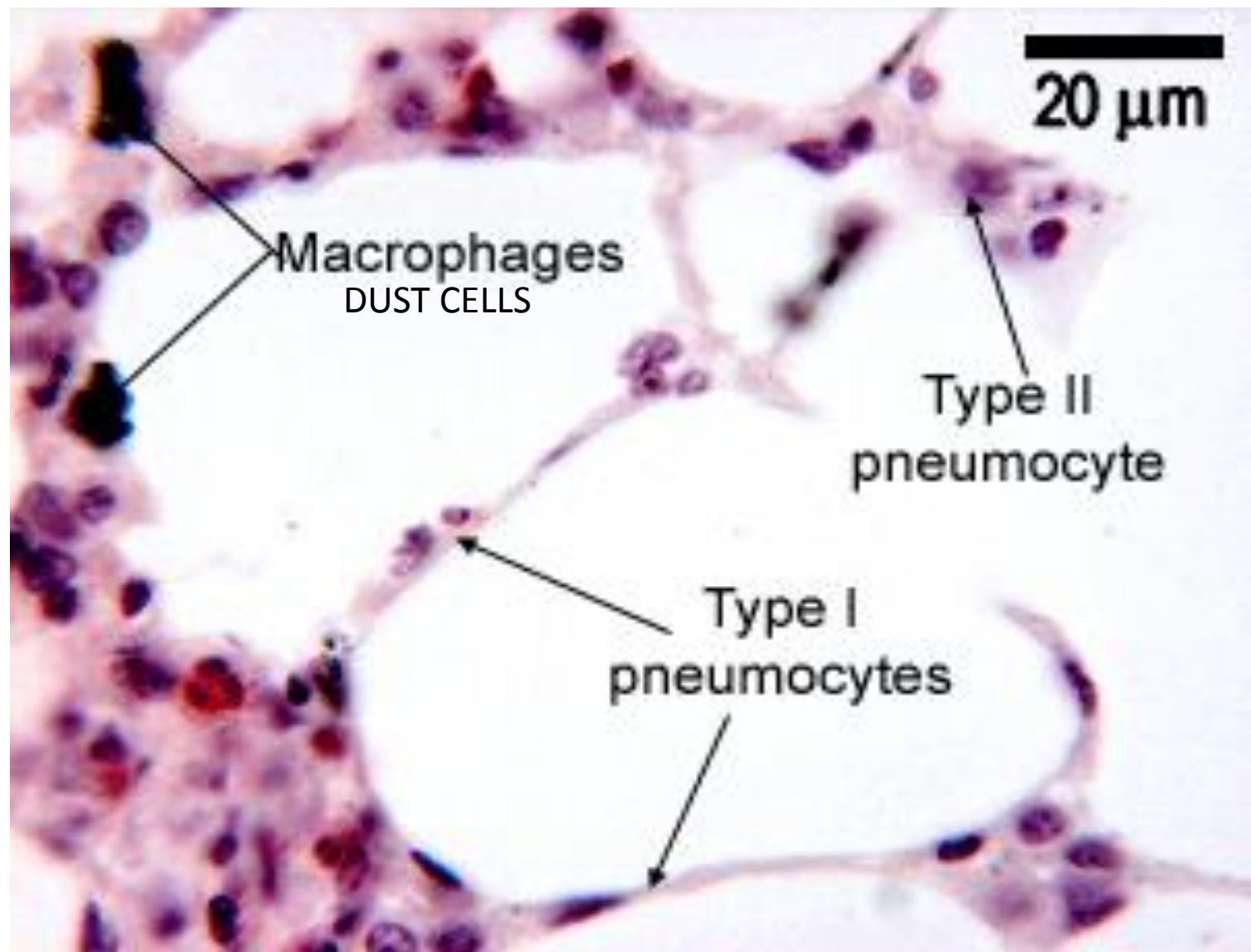
Liver ink injected, trichrome

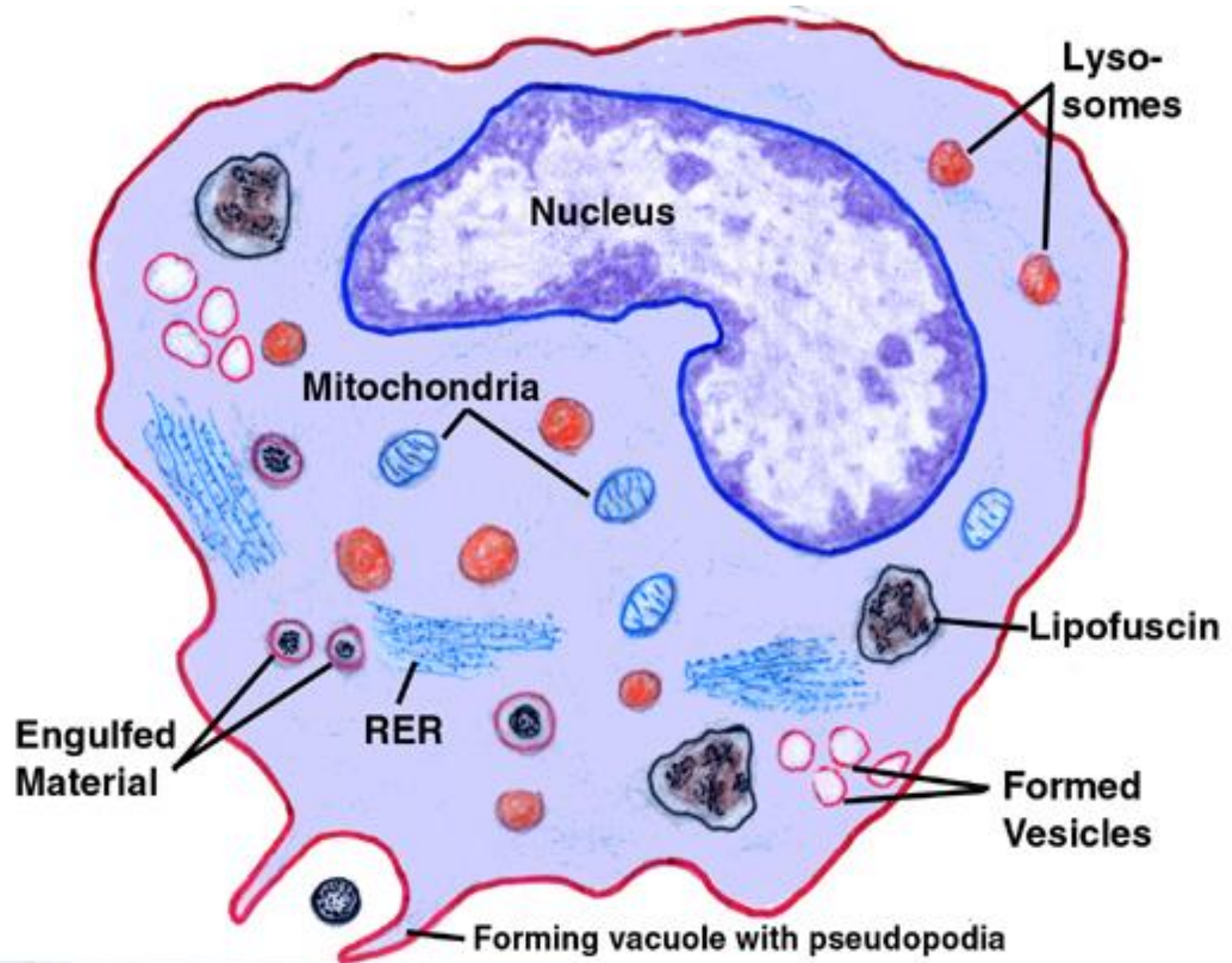


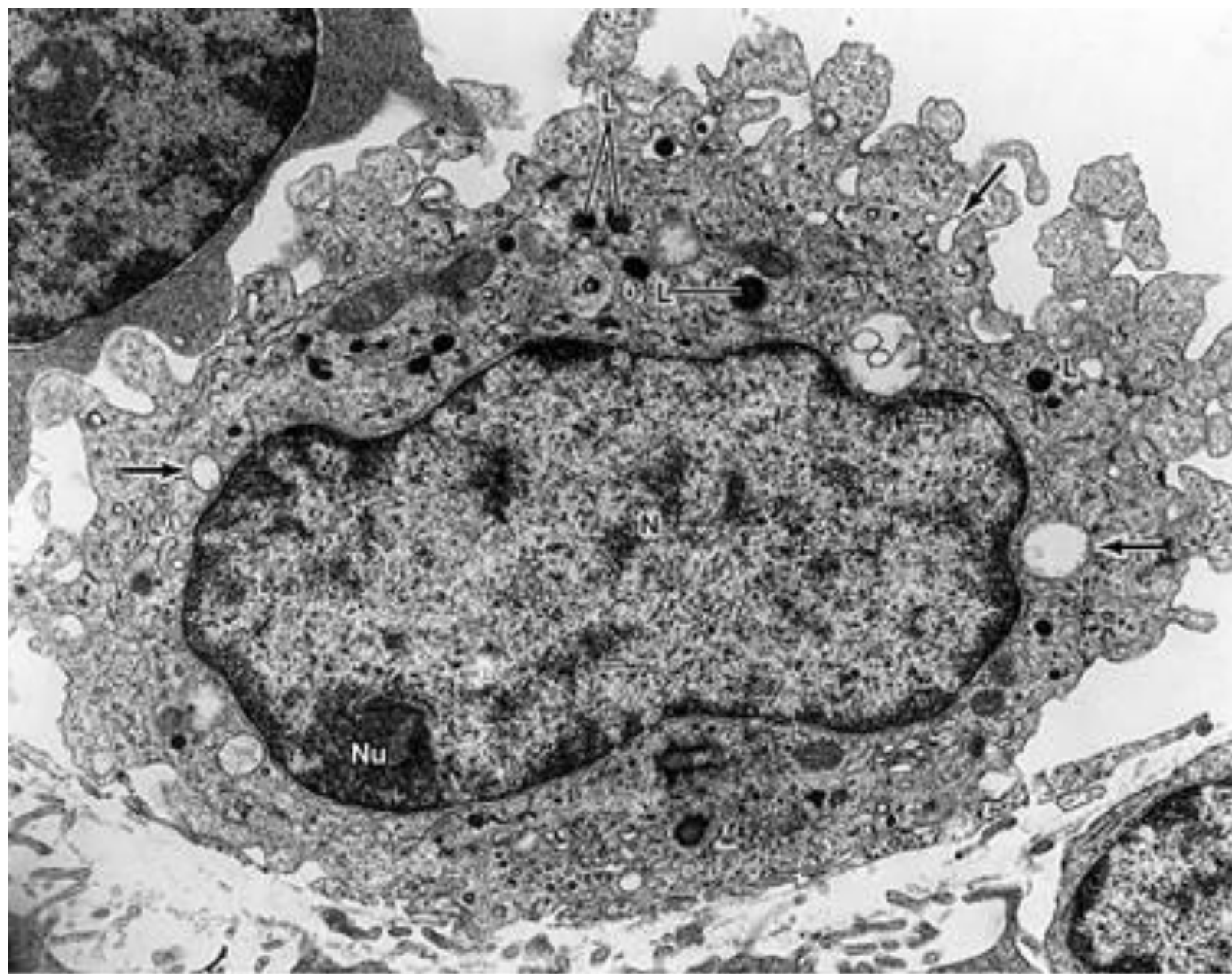




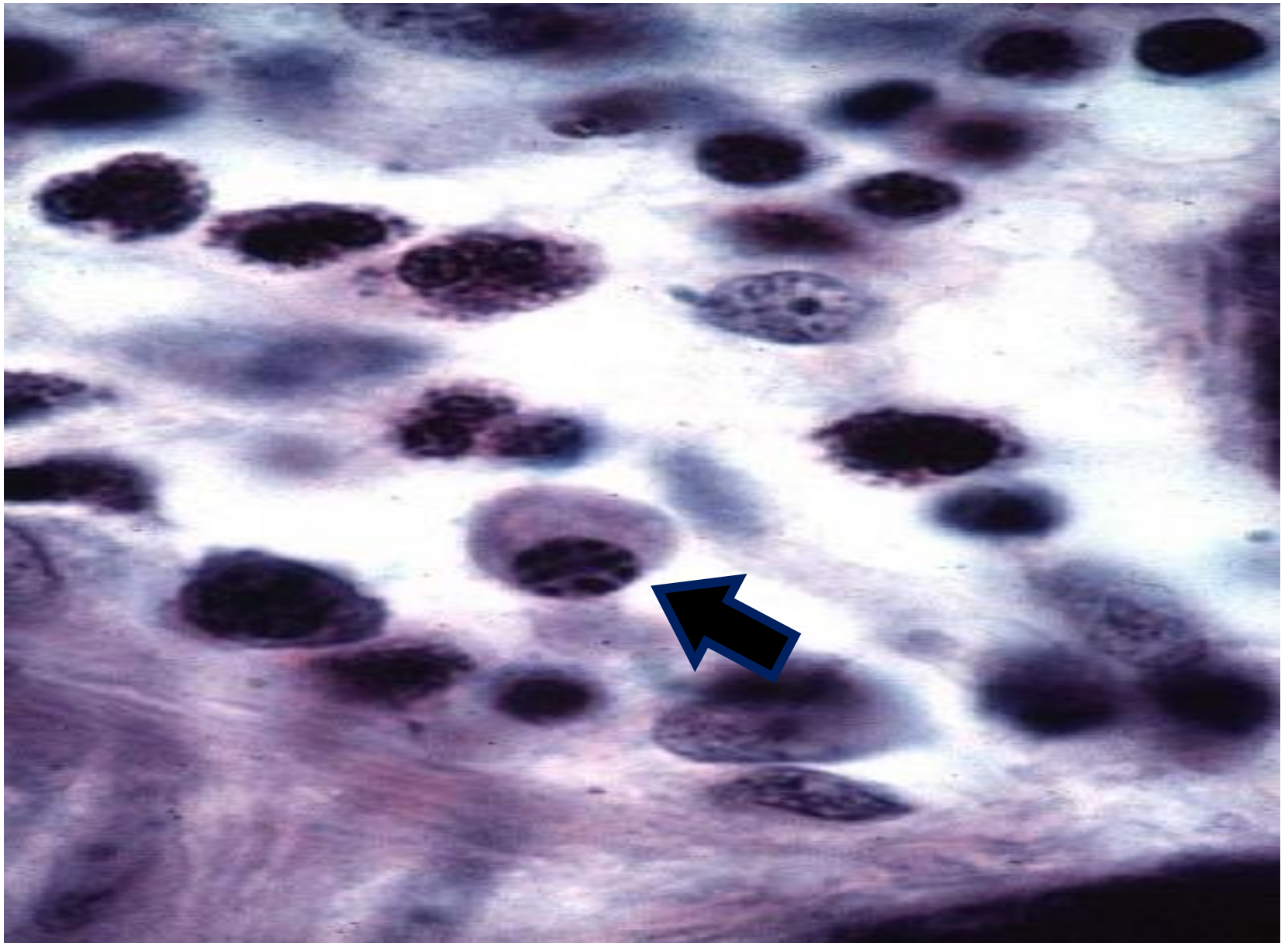


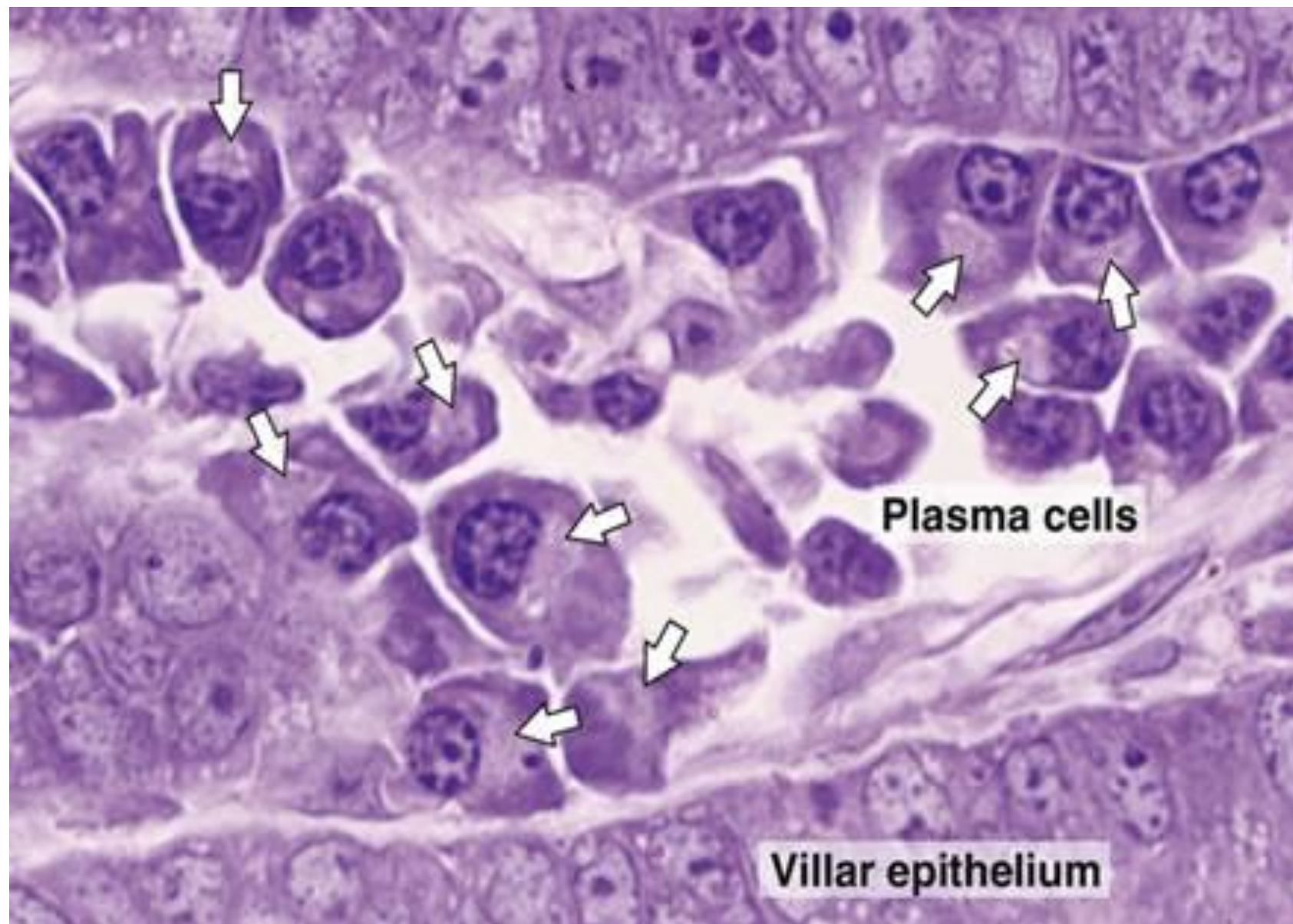


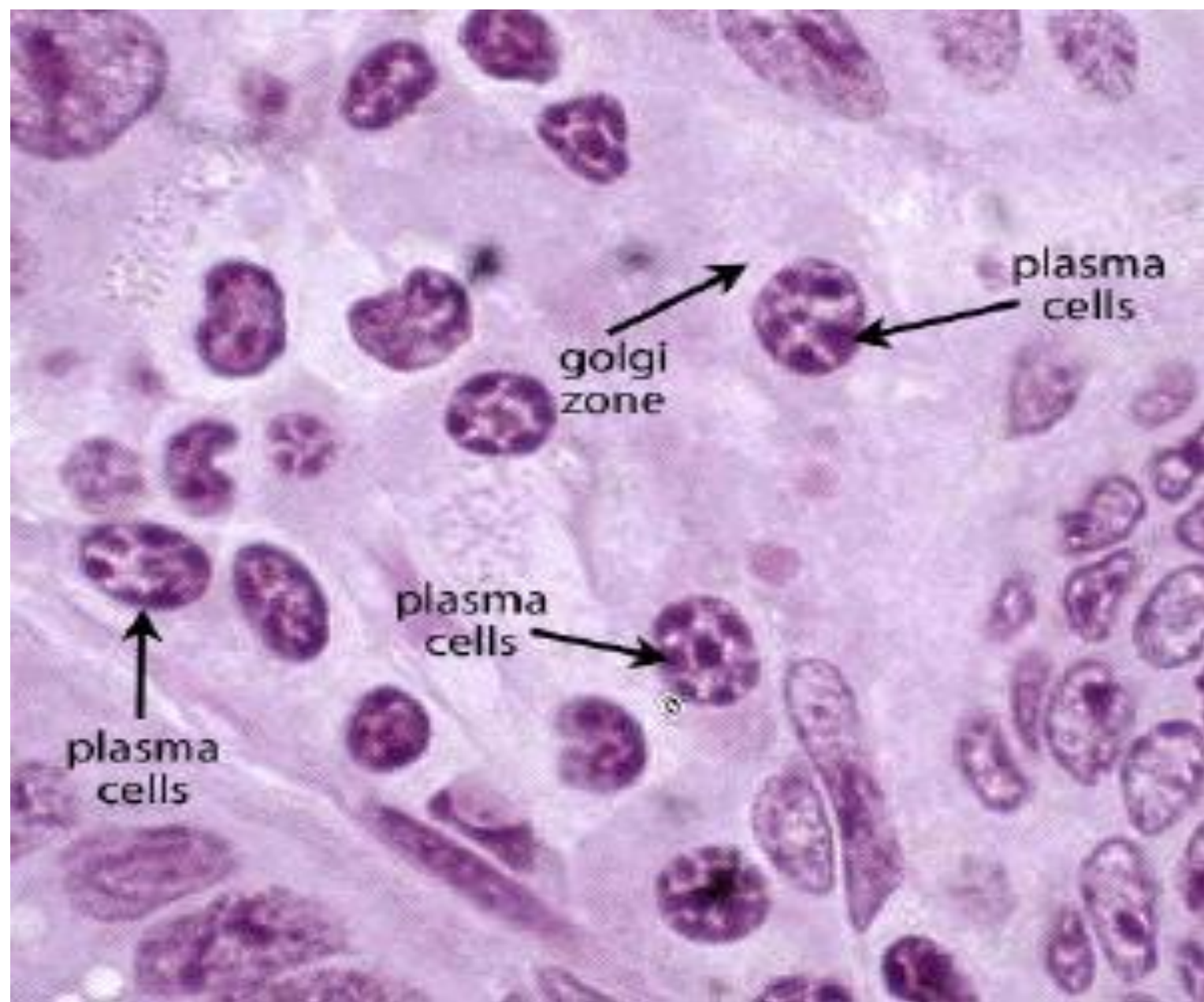


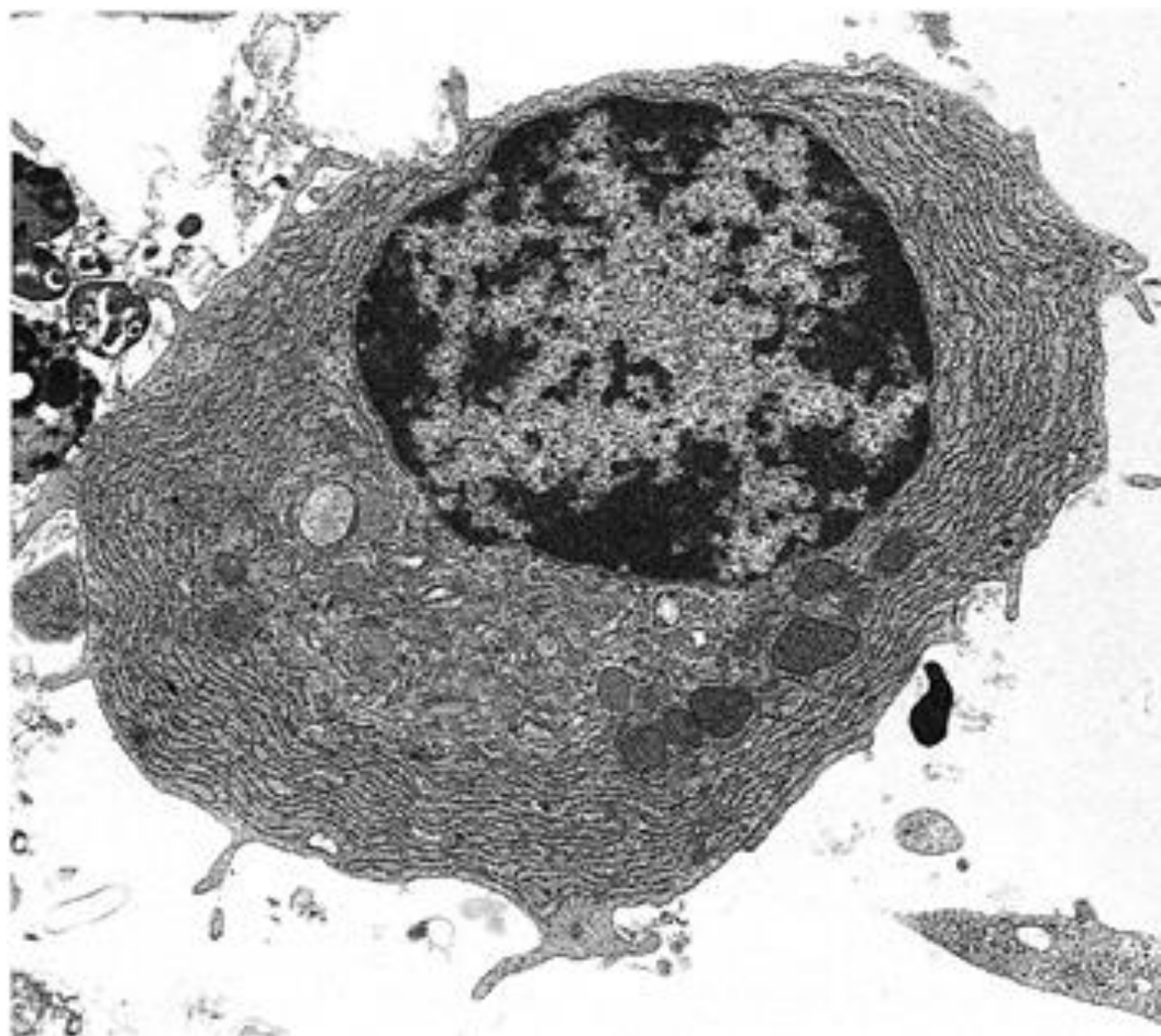


Plasma cell





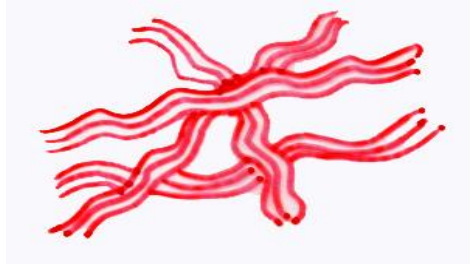




Connective Tissue Fibers

Collagenous Fibers

(bundles)



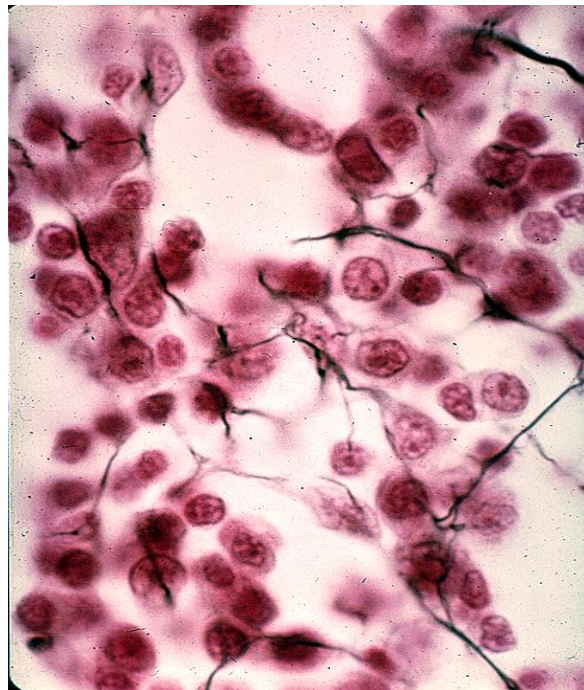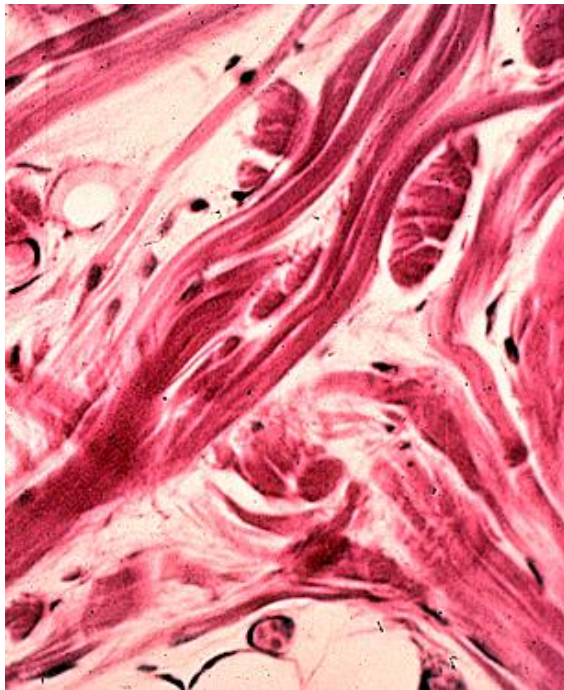
Reticular Fibers

(networks)



Elastic Fibers

(anastomosing bundles)



Connective Tissue Fibres

Collagen

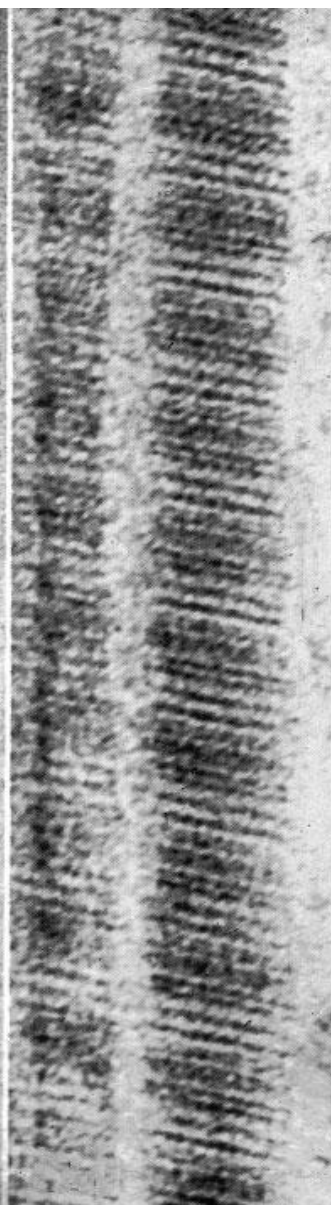
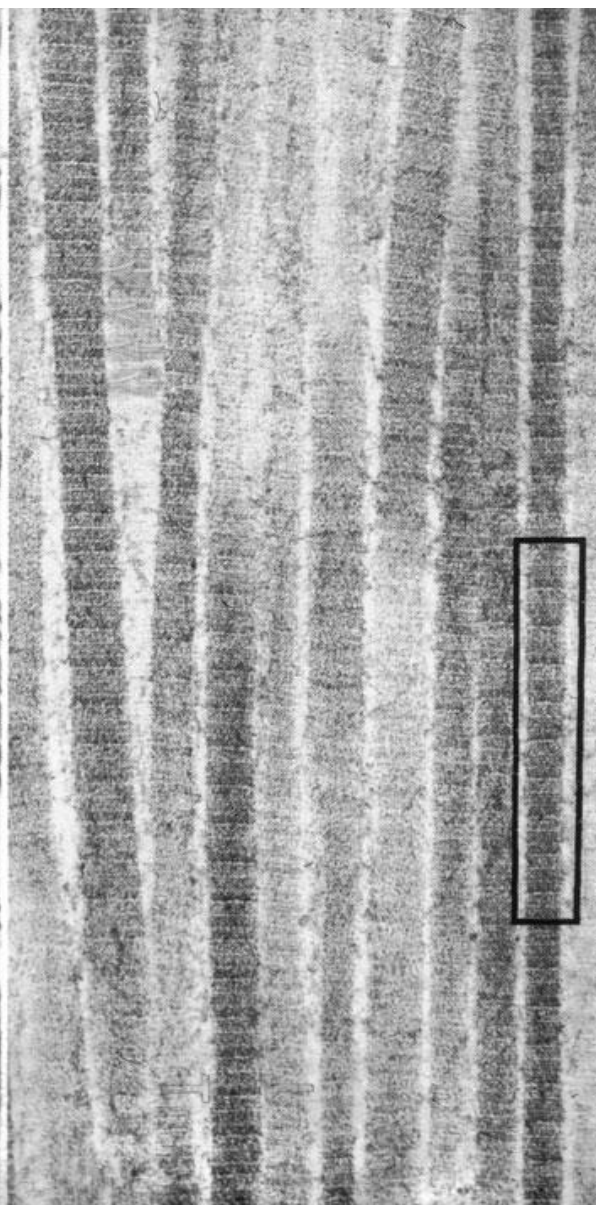
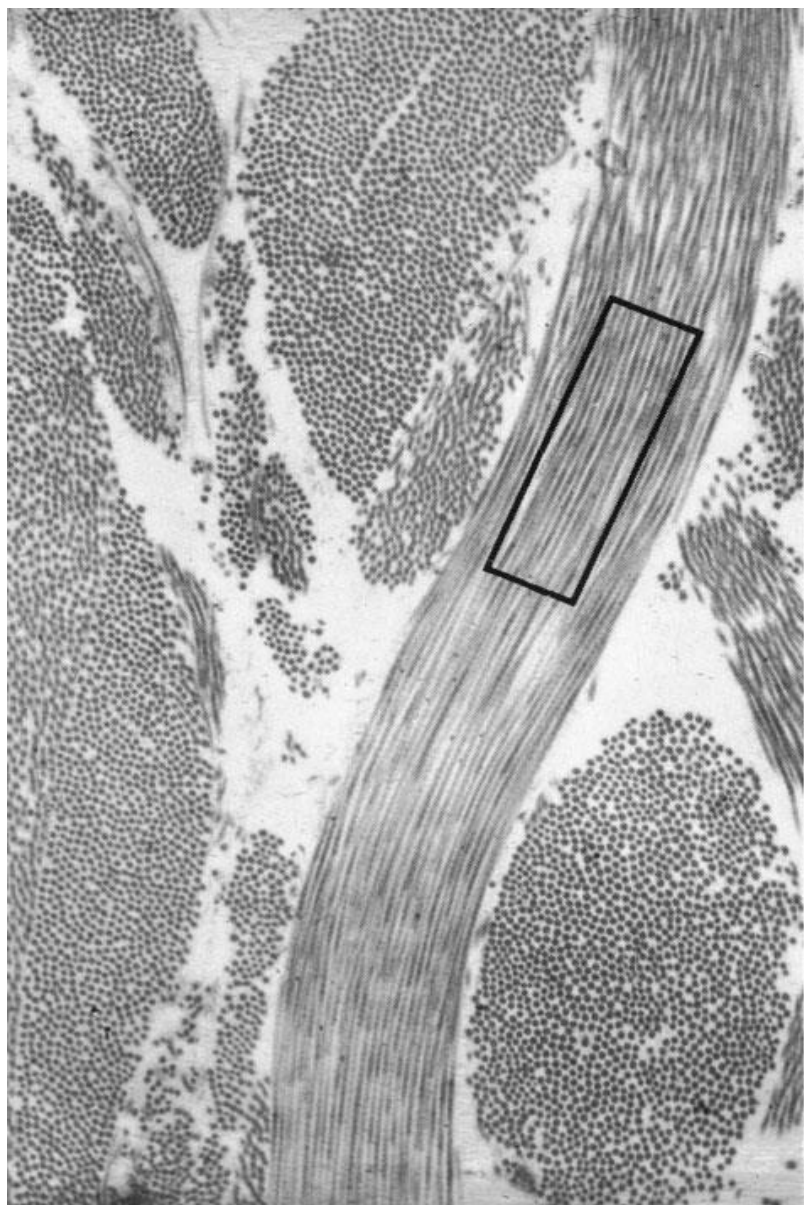
Undulating course of longitudinally striated bundles, form meshwork of variable texture, stain pink-red in H&E. Nonextensible.

Elastic

Forms sheets or lamina, Unstained in H & E. Reversibly extensible. Stains brown-black in Orcein or Resorcin Fuchsin.

Reticular

Delicate network, Unstained in H & E. Reversibly extensible. PAS +ve, stains black in AgNO₃ (Argyrophilic).



Classification of Connective Tissue

Connective tissue

```
graph TD; CT[Connective tissue] --> ECT[Embryonic connective tissue]; CT --> CTP[connective tissue proper]; CT --> CTS[Connective tissue Special]; ECT --> Mes[Mesenchyme]; ECT --> Muc[Mucous]; CTP --> LTC[Loose (areolar) connective tissue]; CTP --> DCT[Dense connective tissue]; DCT --> Reg[Regular]; DCT --> Irr[Irregular]; CTS --> Elastic[Elastic]; CTS --> Reticular[Reticular]; CTS --> Adipose[Adipose]; CTS --> Bone[Bone]; CTS --> Cartilage[Cartilage]; CTS --> Blood[Blood];
```

Embryonic connective tissue

Mesenchyme

Mucous

connective tissue proper

Loose (areolar) connective tissue

Dense connective tissue

Regular

Irregular

Connective tissue Special

Elastic

Reticular

Adipose

Bone

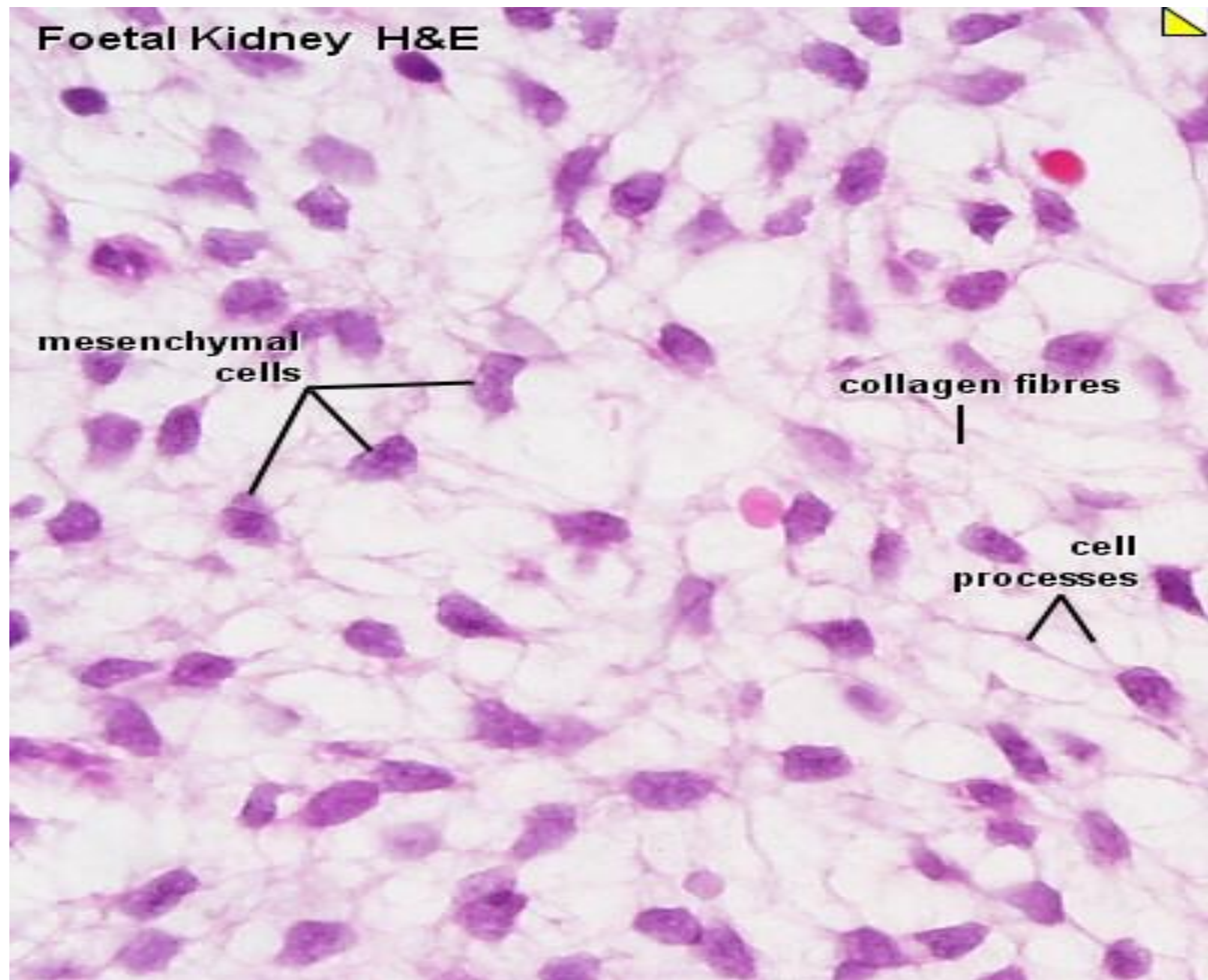
Cartilage

Blood

Embryonic connective tissue

Mesenchyme
connective tissue

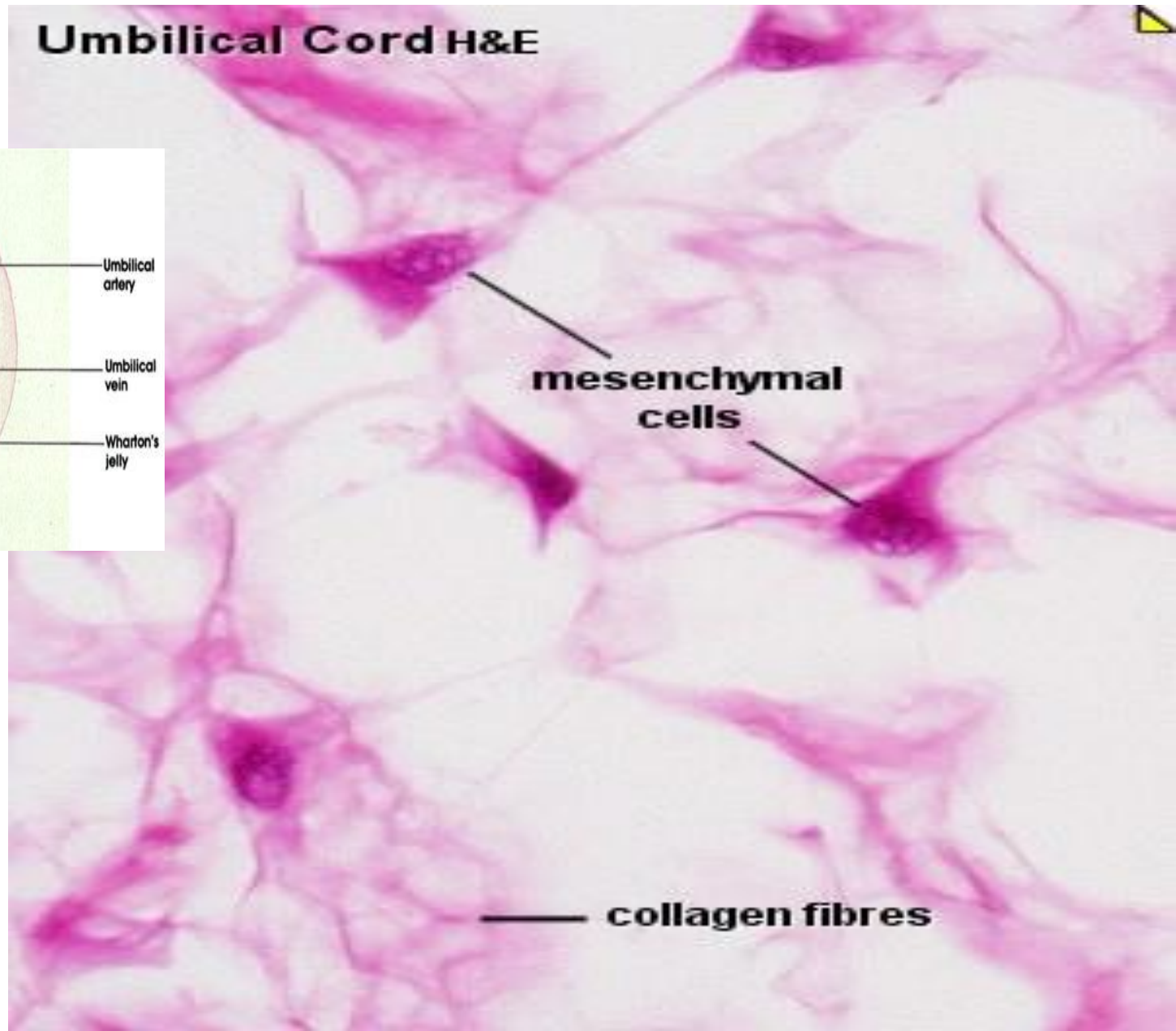
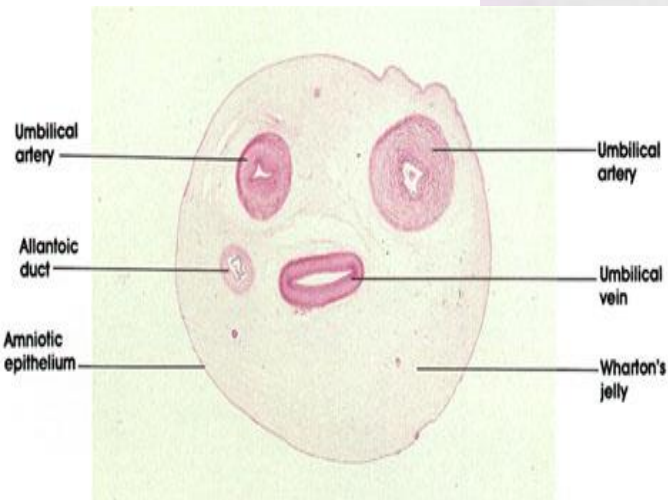
Foetal Kidney H&E

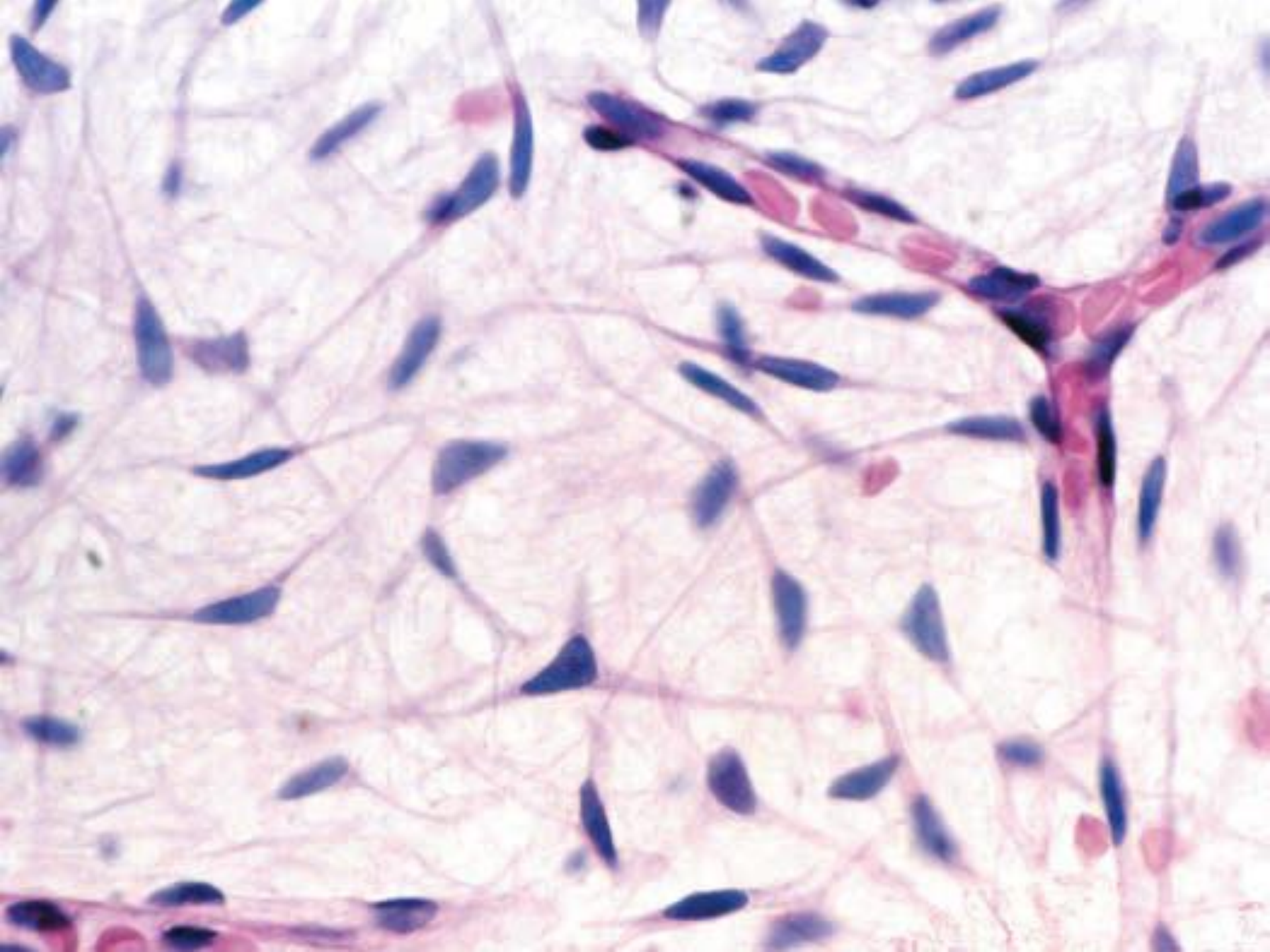


Embryonic connective tissue

Mucous connective
tissue

Umbilical Cord H&E





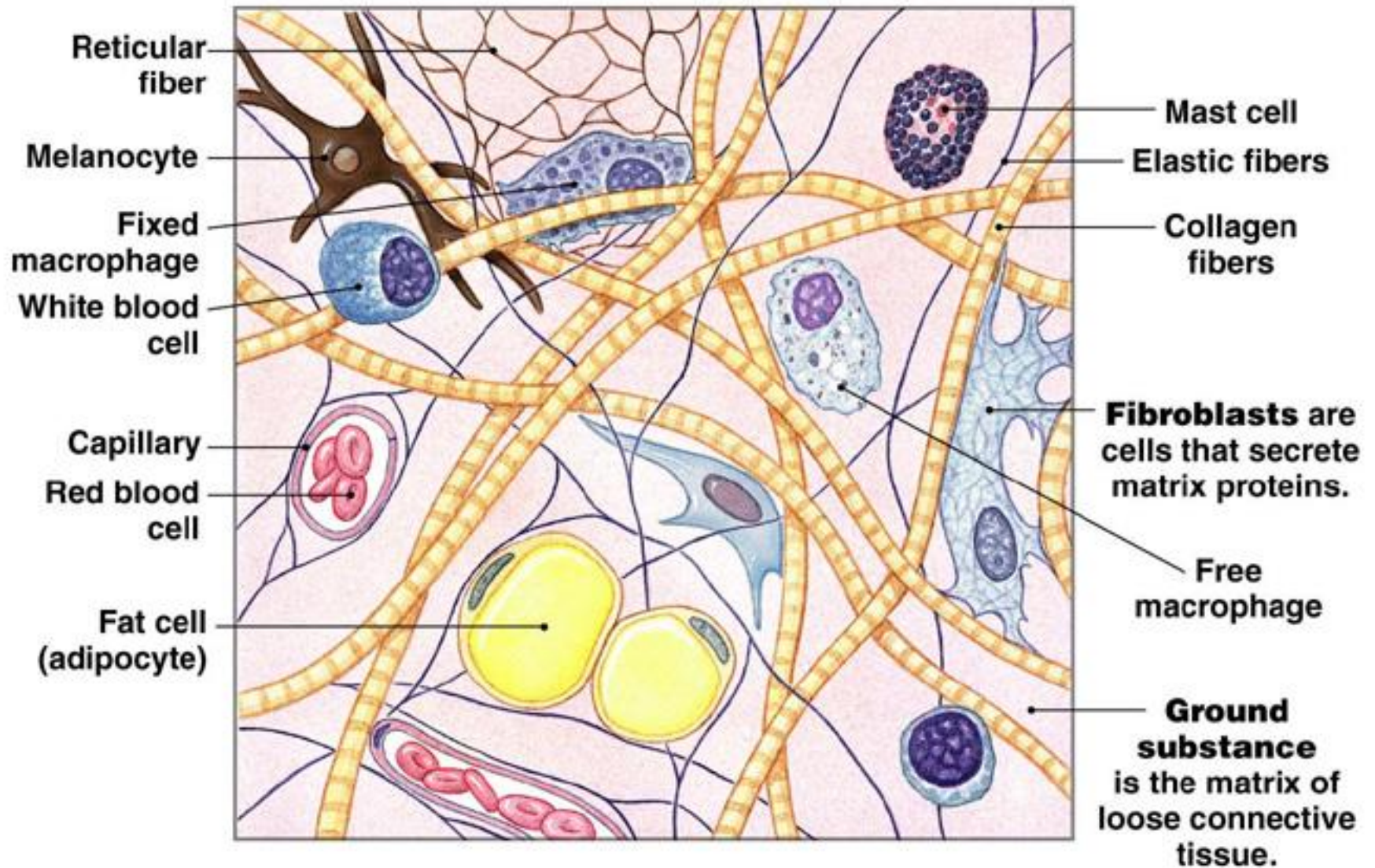
Connective tissue

Proper

Loose (areolar) connective
tissue

LOOSE (Areolar) CT

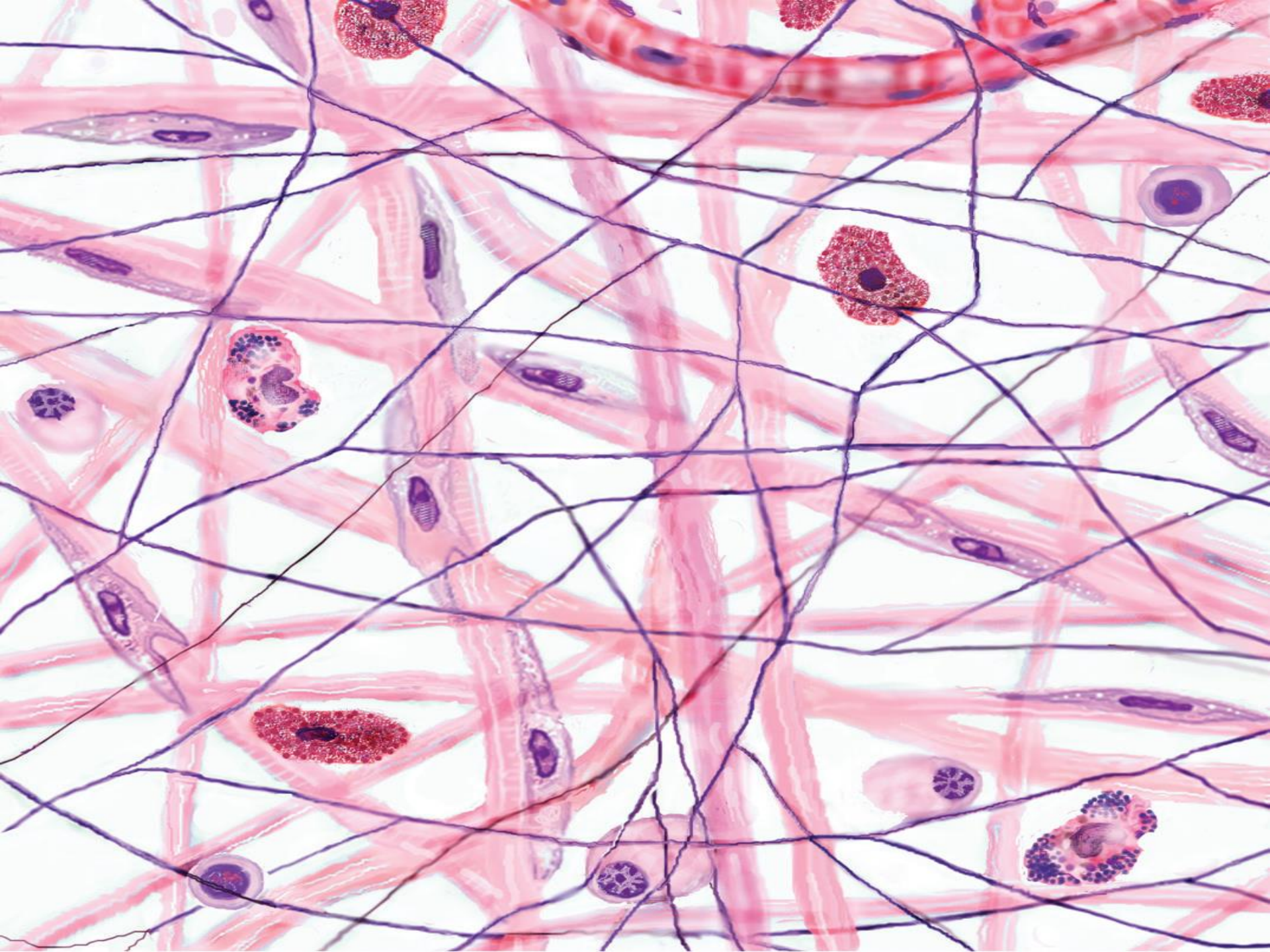
- Consists of all 3 types of fibers, several types of cells, and semi-fluid ground substance. (MORE CELLS AND GROUND SUBSTANCE THAN FIBERS)
- Supports epithelium (subcutaneous layer and lamina propria)
- surrounds capillaries
- Fills spaces between muscles and nerves
- Flexible but not very much resistant to stress

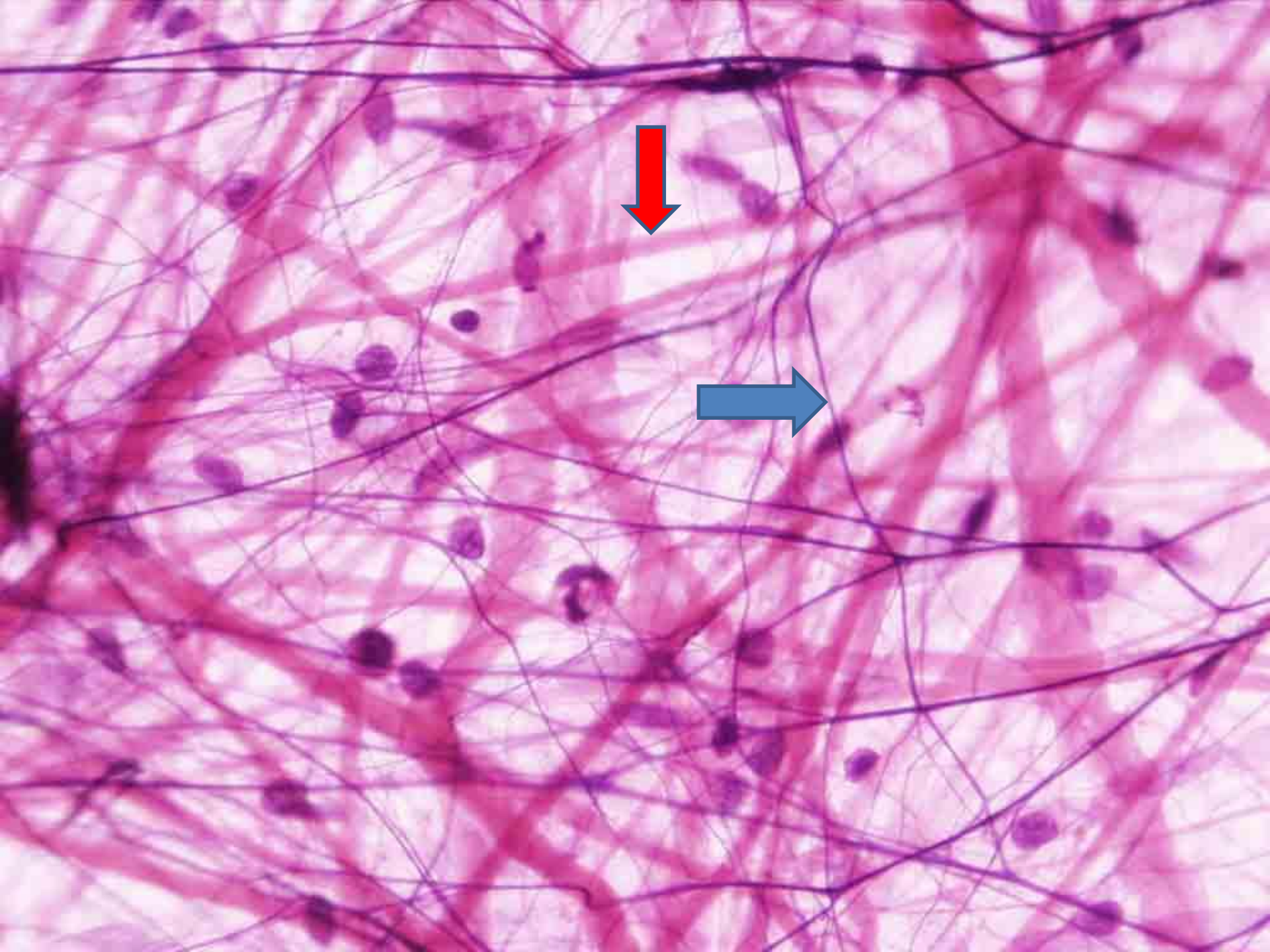


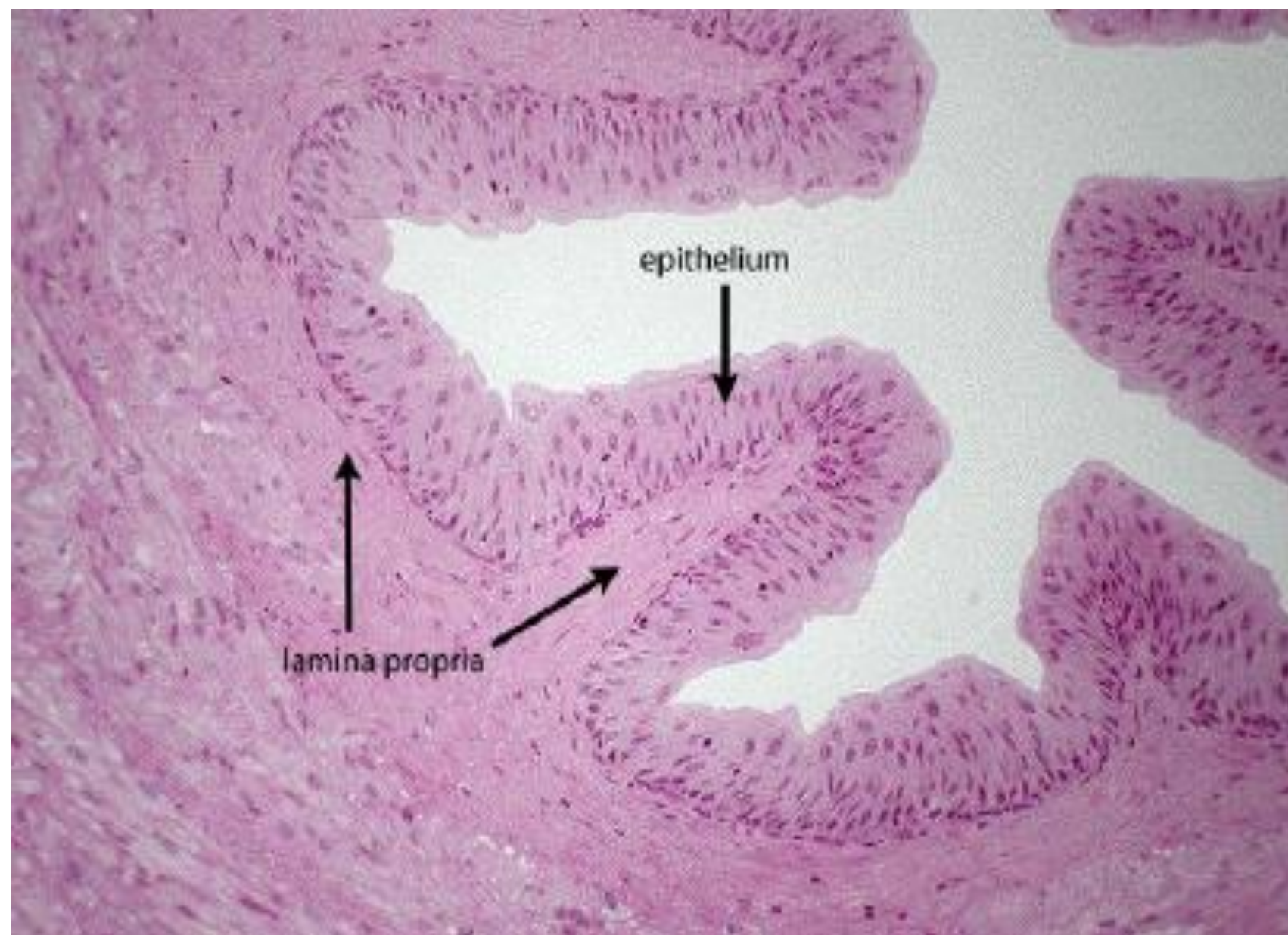
Loose connective tissue

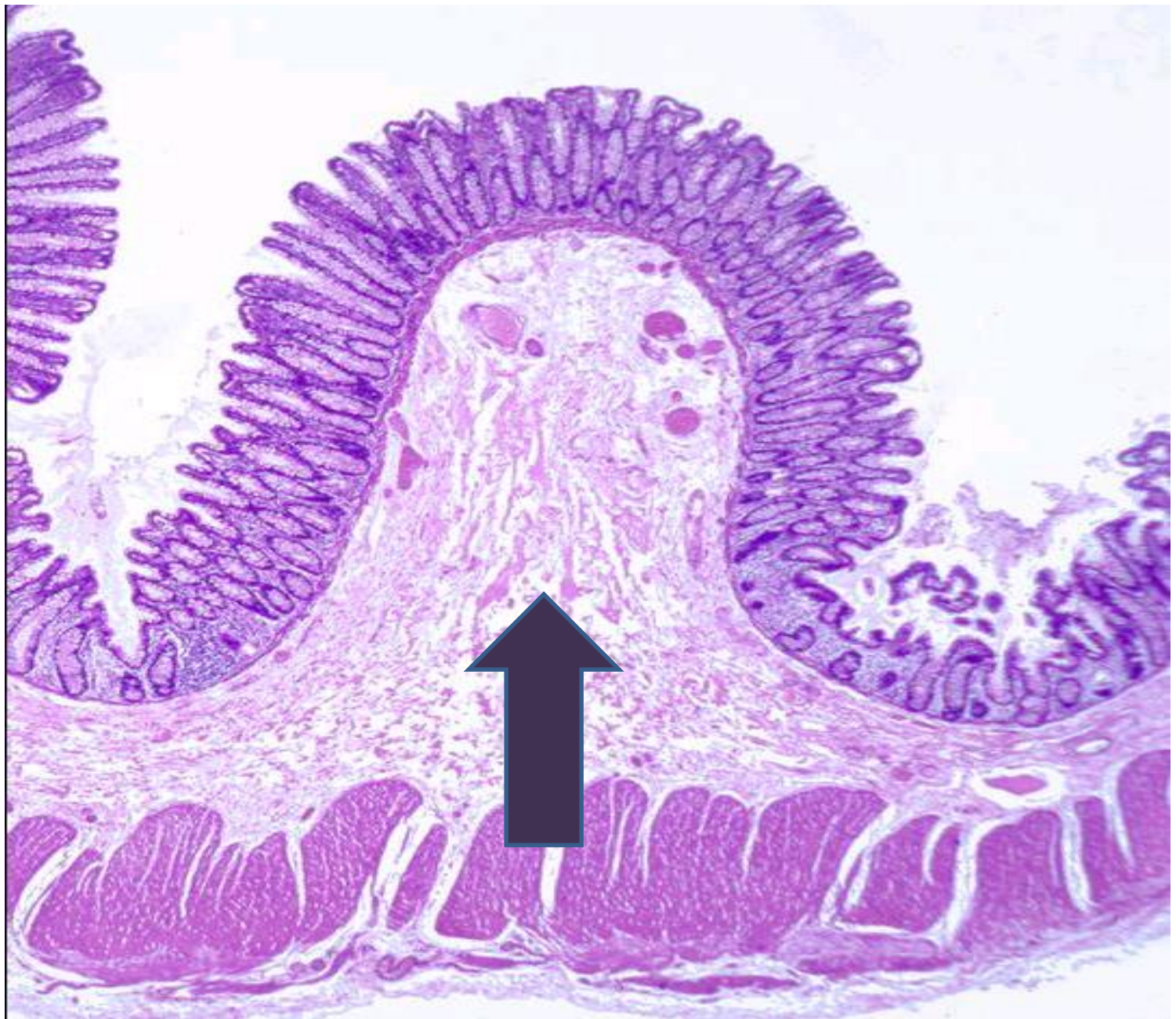
Copyright © 2007 Pearson Education, Inc., publishing as Benjamin Cummings.

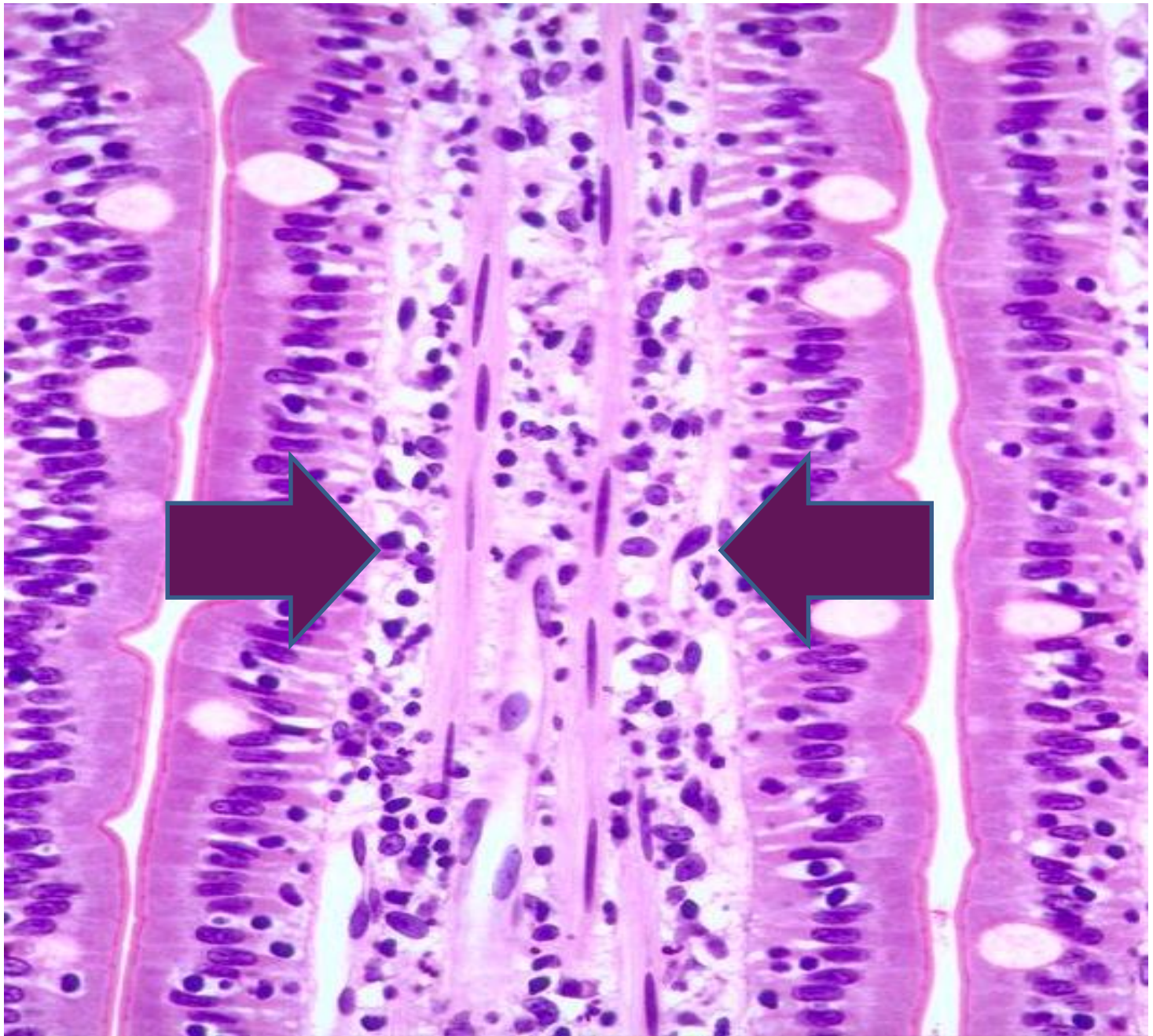
Fig. 3-29

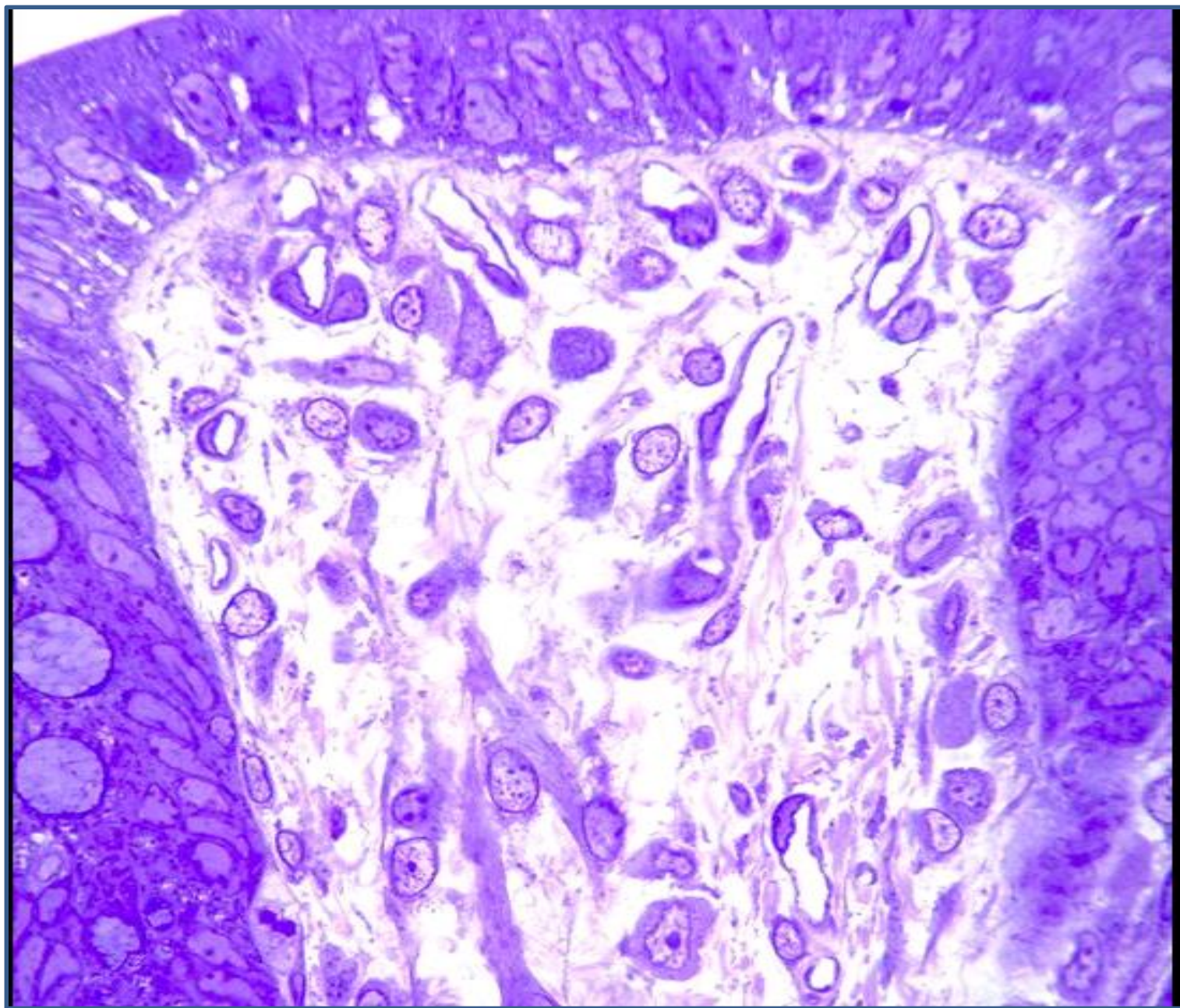












Connective tissue Proper

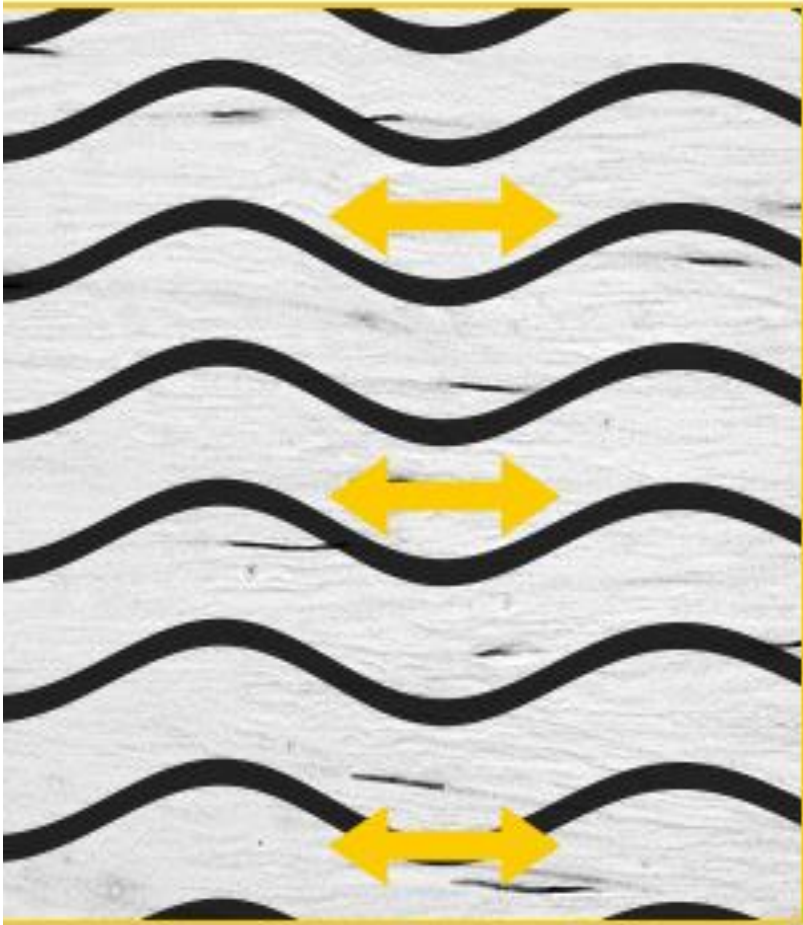
Dense connective tissue

Dense Connective Tissue


Contains more numerous and thicker fibers and far fewer cells than loose CT.

- a. **Dense regular connective tissue**
Tendons and ligaments
- b. **Dense irregular connective tissue**
Dermis of skin

Direction of Dense Connective Tissue Fibers



Dense Regular




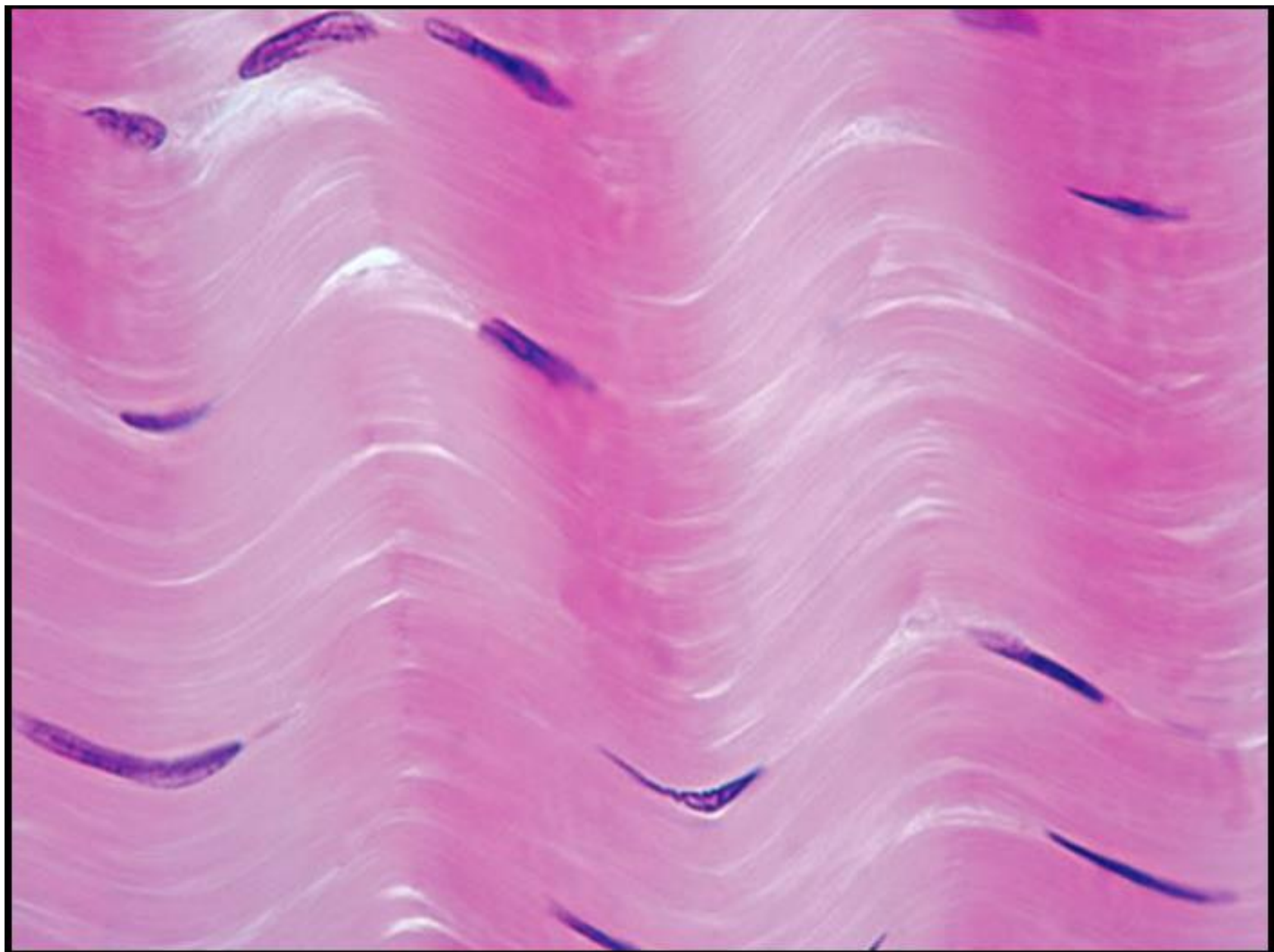
Dense Irregular

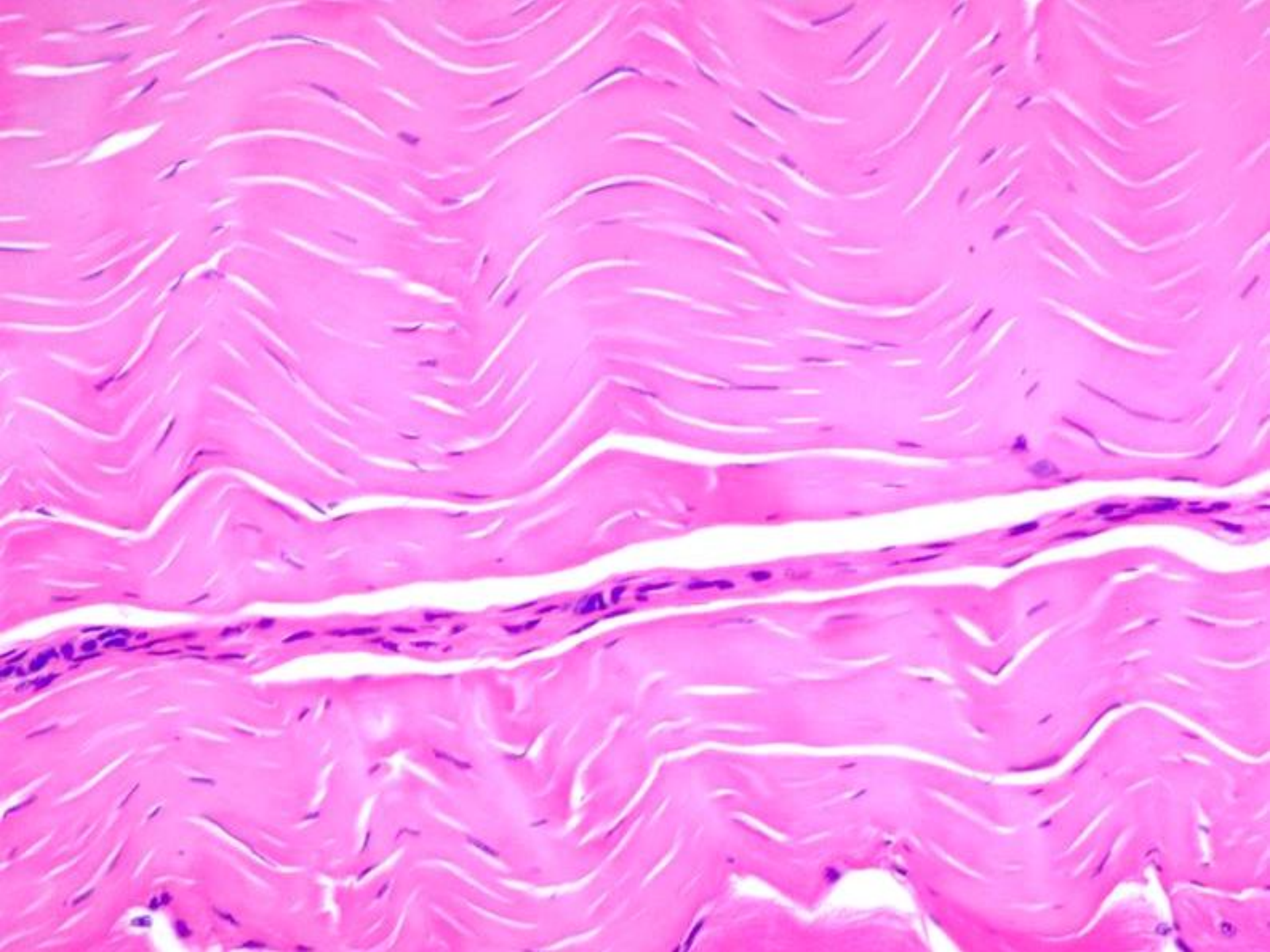
Regular Dense connective tissue

Dense regular Connective Tissue

- Consists of bundles of collagen fibers and fibrocytes.
- Forms tendons, ligaments.
- Function = provide strong attachment between various structures.



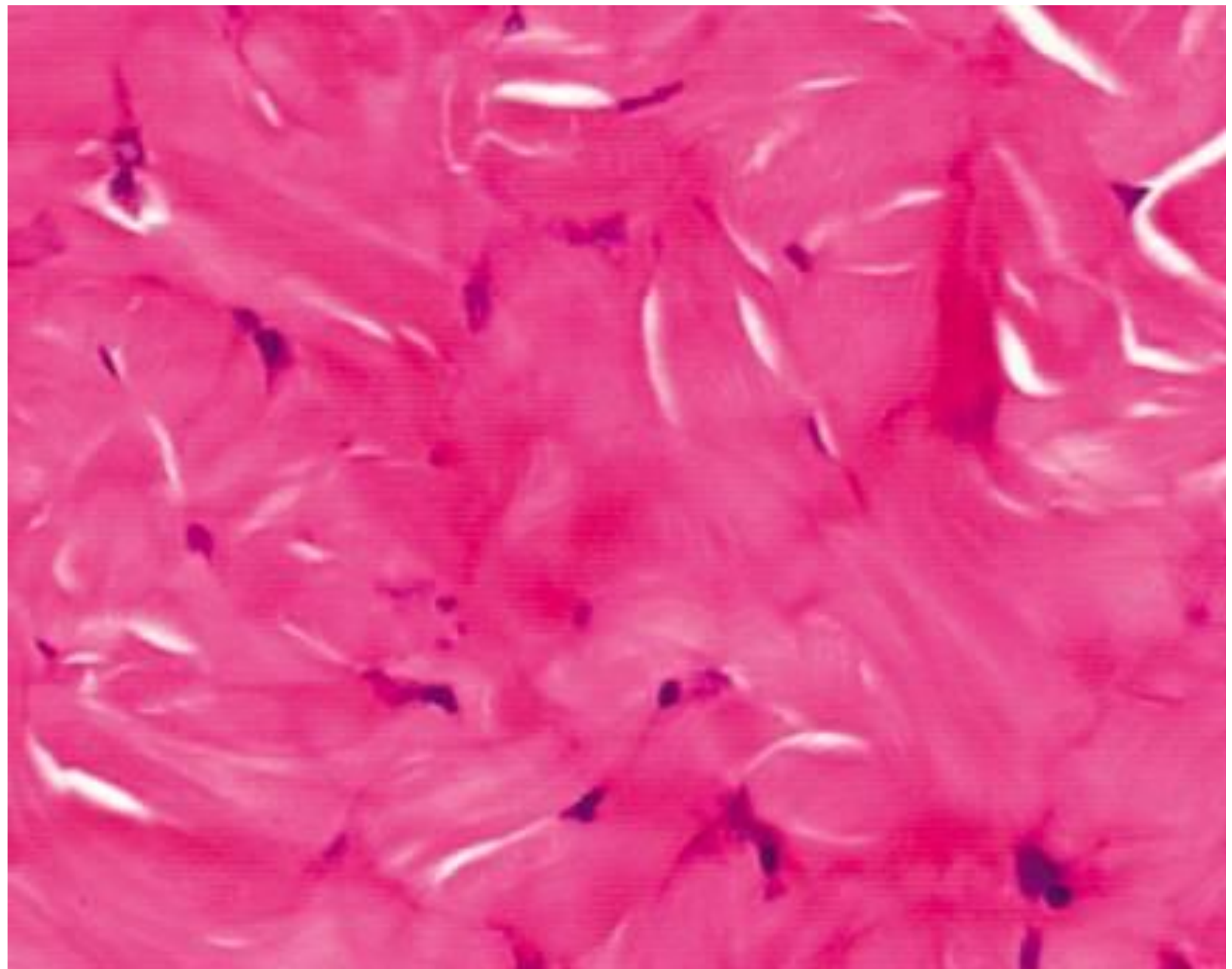


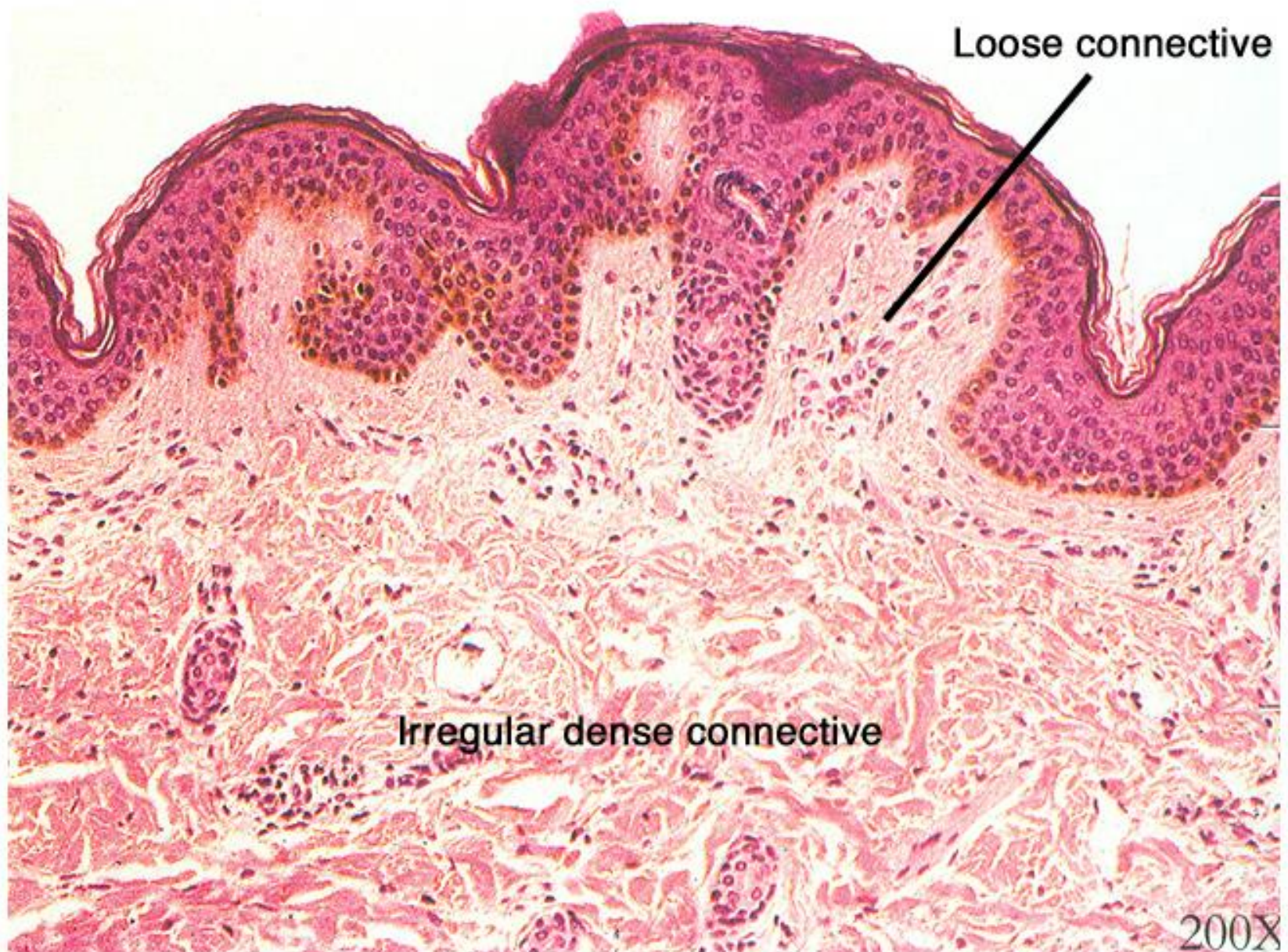


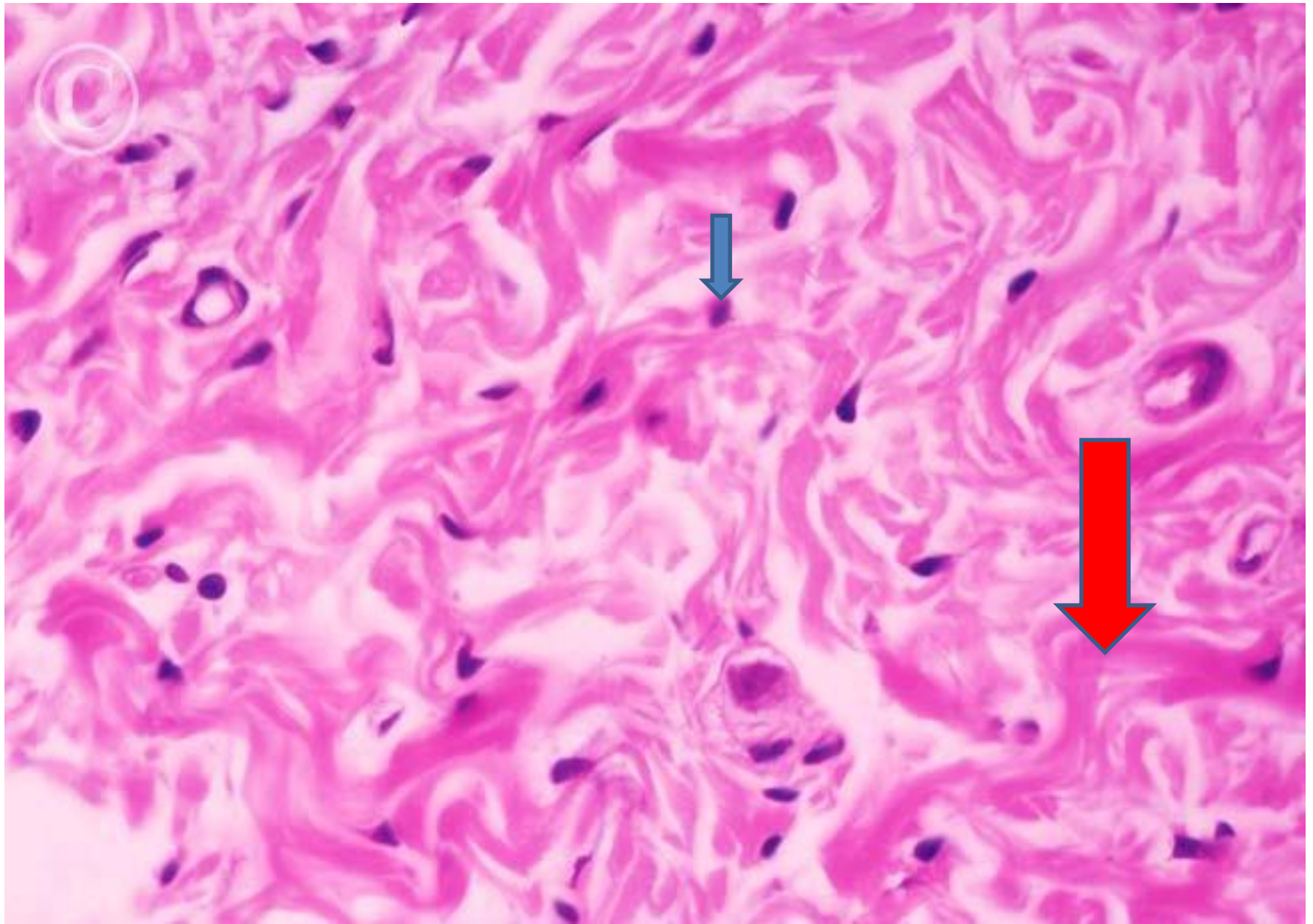
Irregular Dense connective tissue

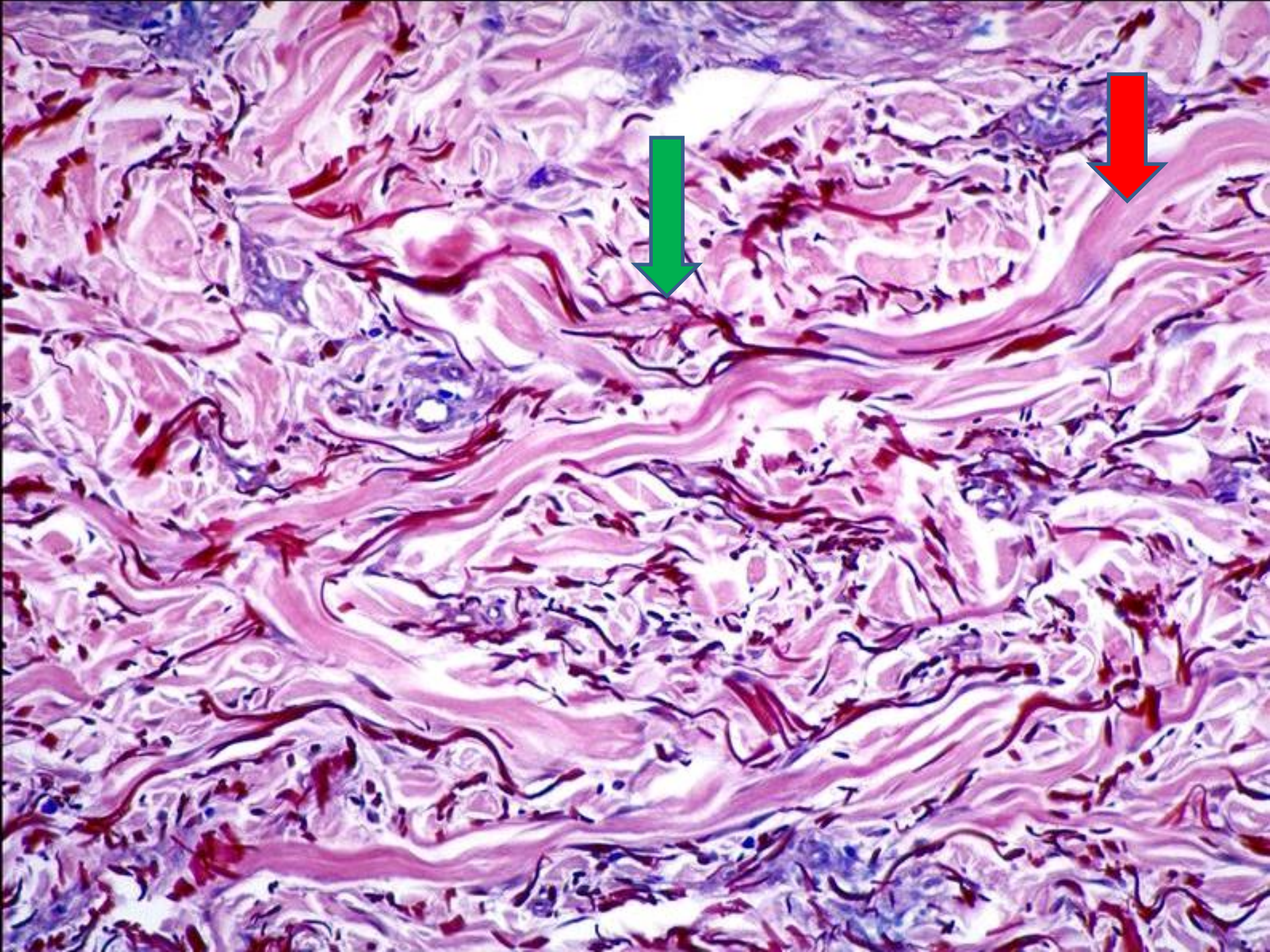
Dense Irregular CT

- Consists of randomly-arranged collagen fibers and a few fibrocytes.
- Found in dermis of skin
- Function = provide strength



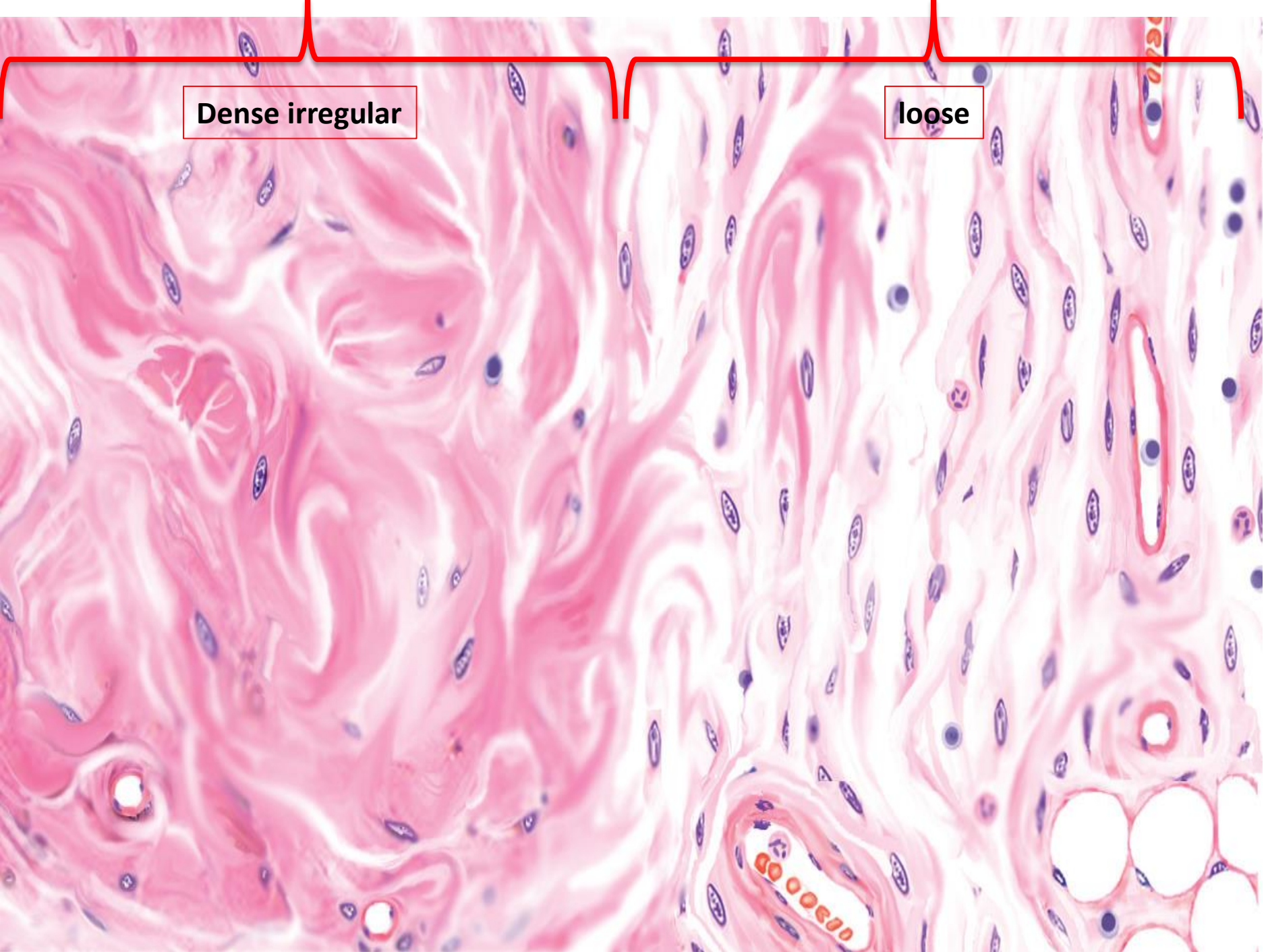






Dense irregular

loose



Specialized Connective tissue

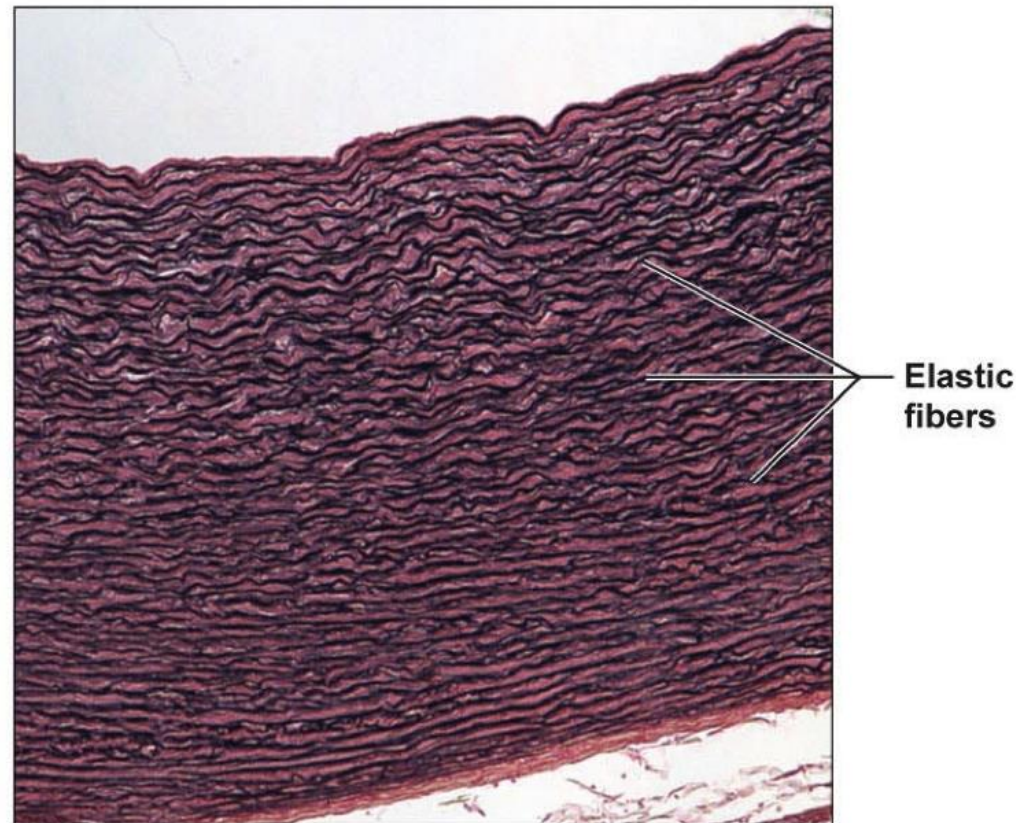
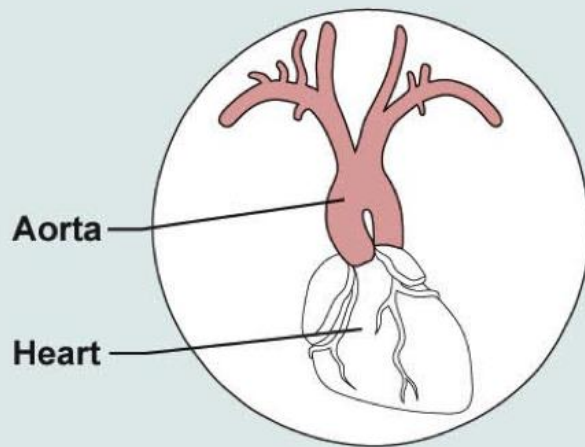
Elastic connective tissue

(g) Connective tissue proper: dense connective tissue, elastic

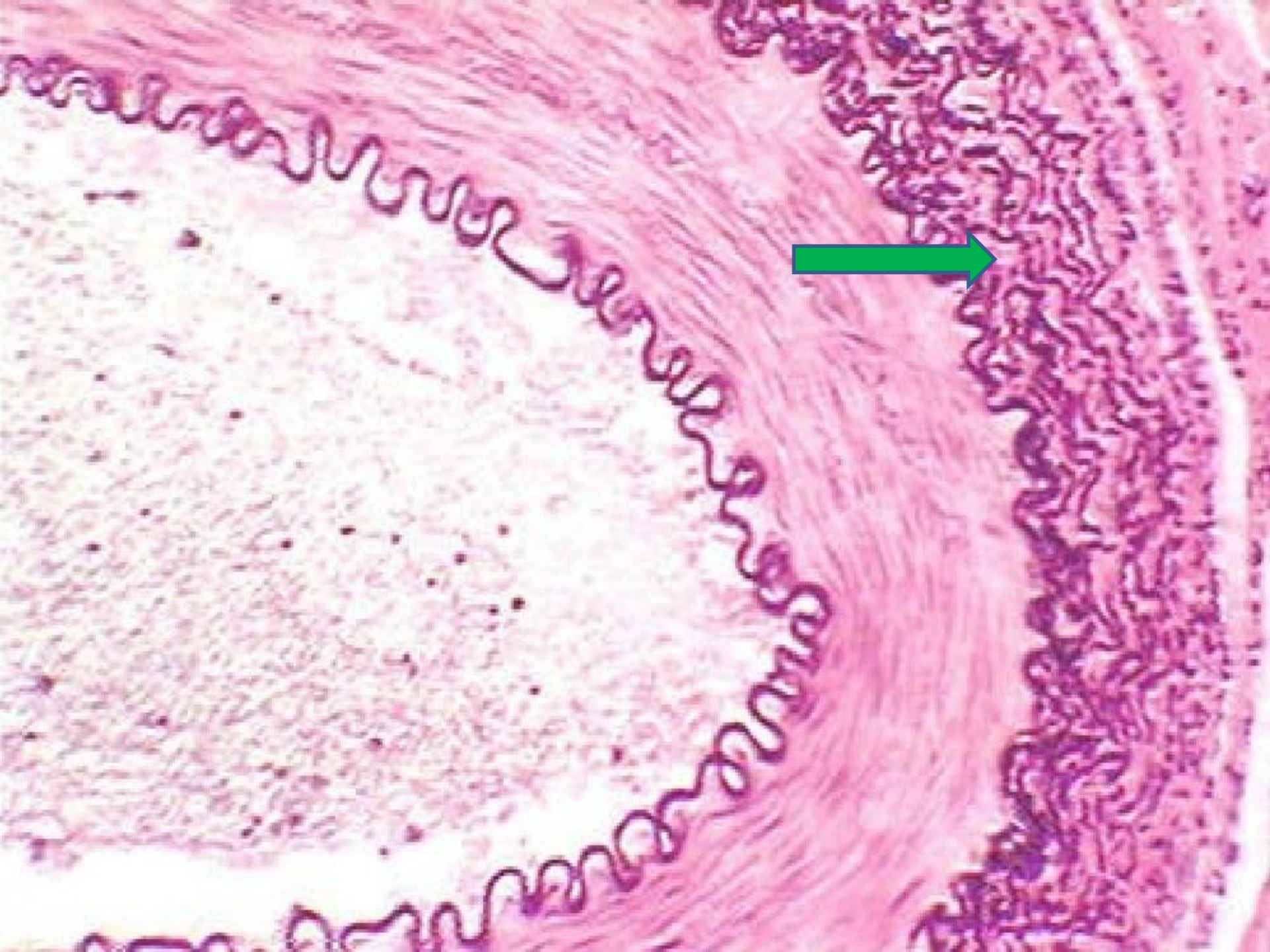
Description: Dense regular connective tissue containing a high proportion of elastic fibers.

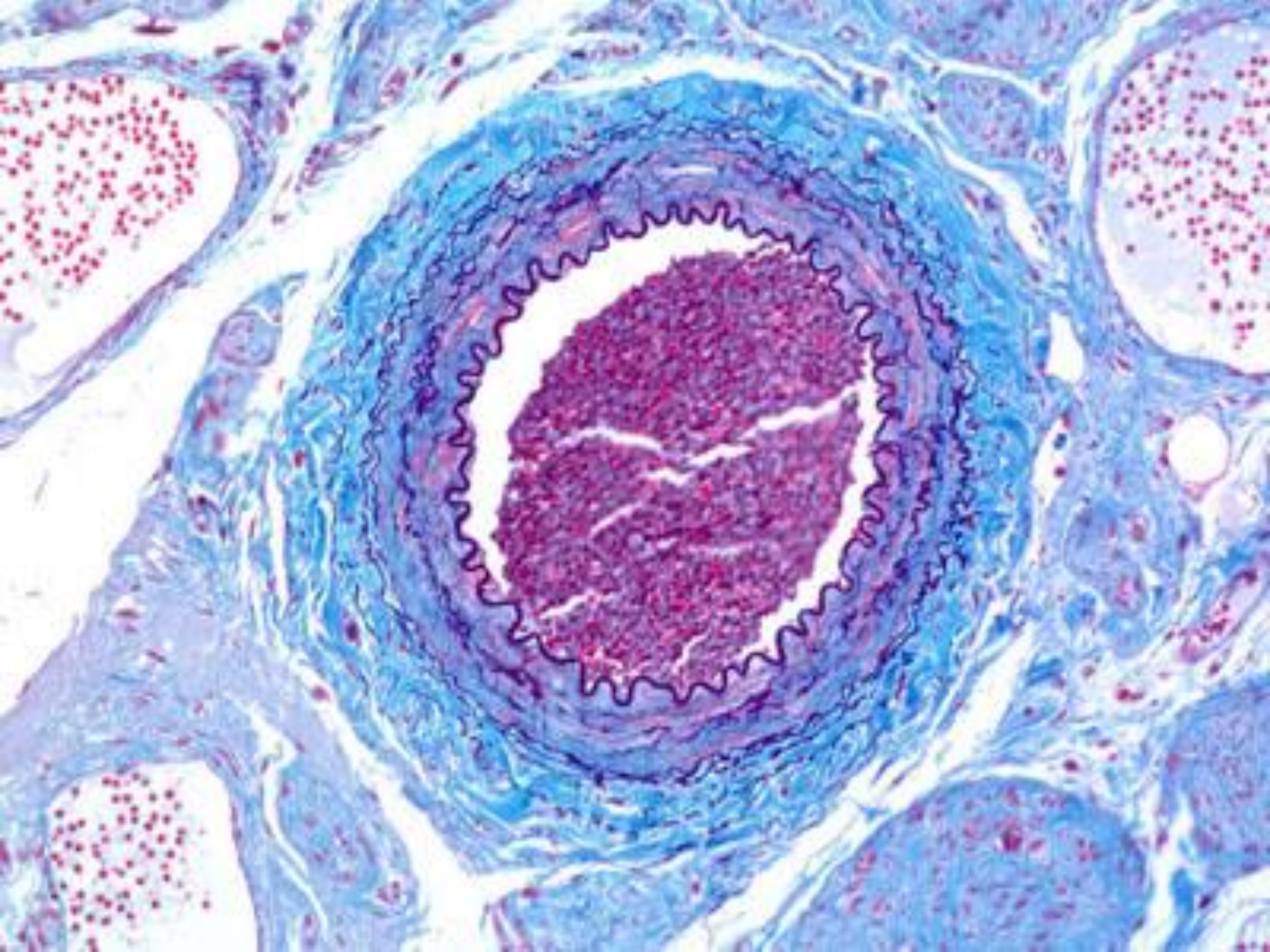
Function: Allows recoil of tissue following stretching; maintains pulsatile flow of blood through arteries; aids passive recoil of lungs following inspiration.

Location: Walls of large arteries; within certain ligaments associated with the vertebral column; within the walls of the bronchial tubes.

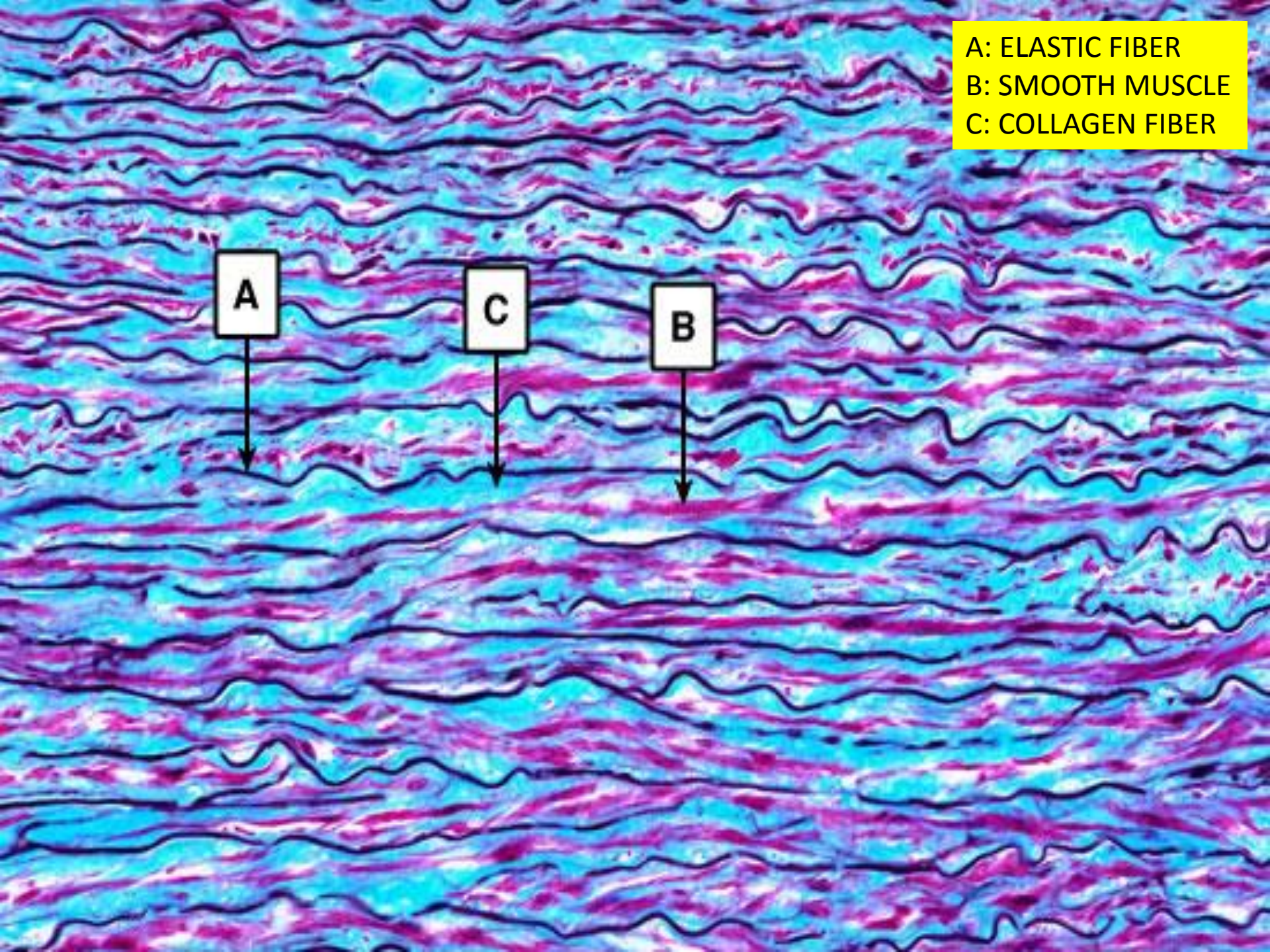


Photomicrograph: Elastic connective tissue in the wall of the aorta (85 \times).





A: ELASTIC FIBER
B: SMOOTH MUSCLE
C: COLLAGEN FIBER



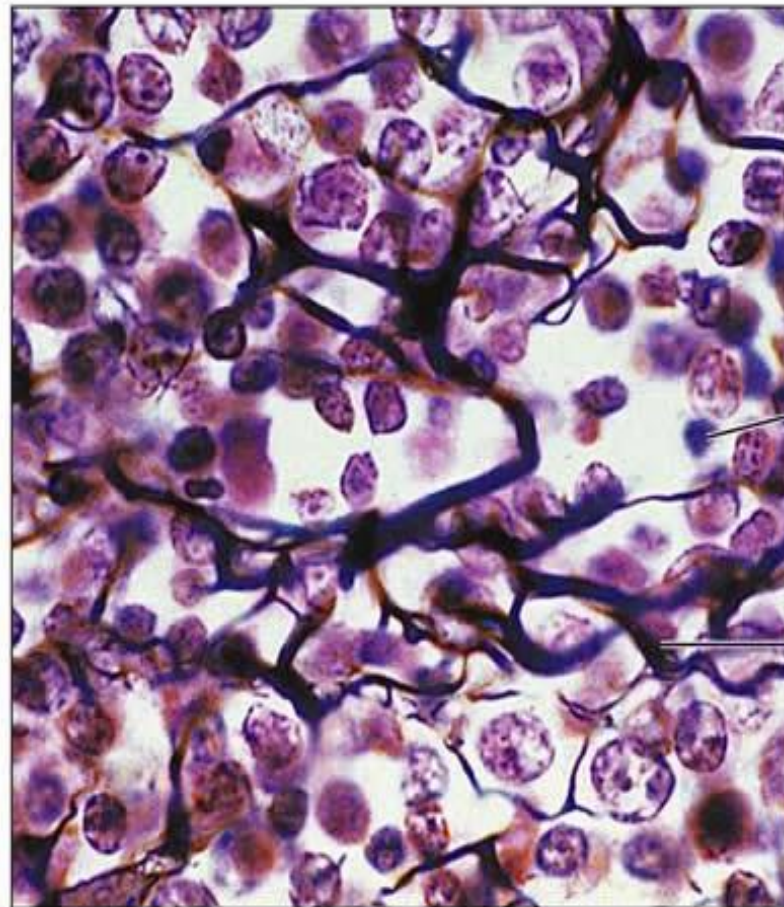
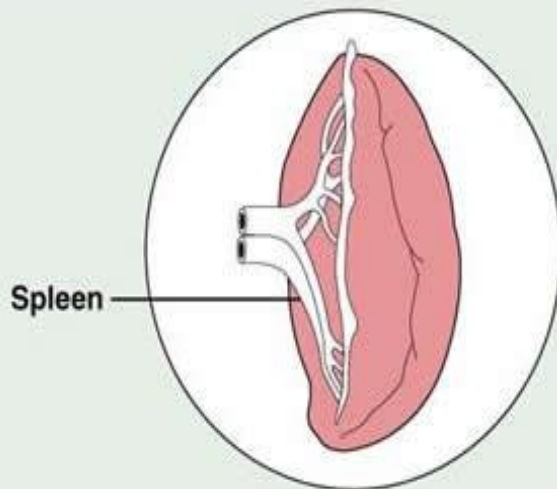
Reticular connective tissue

(c) Connective tissue proper: loose connective tissue, reticular

Description: Network of reticular fibers in a typical loose ground substance; reticular cells lie on the network.

Function: Fibers form a soft internal skeleton (stroma) that supports other cell types including white blood cells, mast cells, and macrophages.

Location: Lymphoid organs (lymph nodes, bone marrow, and spleen).



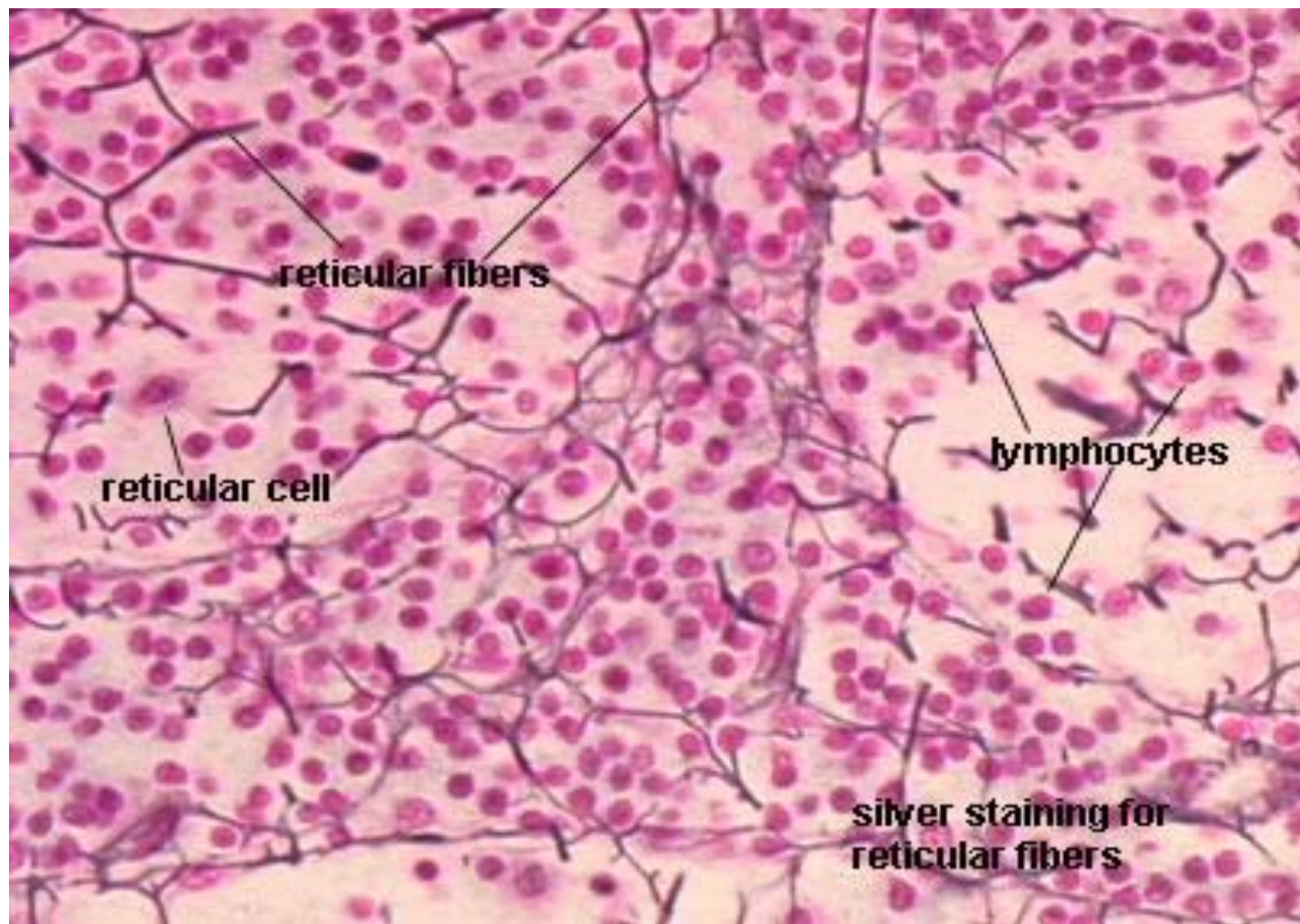
White blood cell
(lymphocyte)

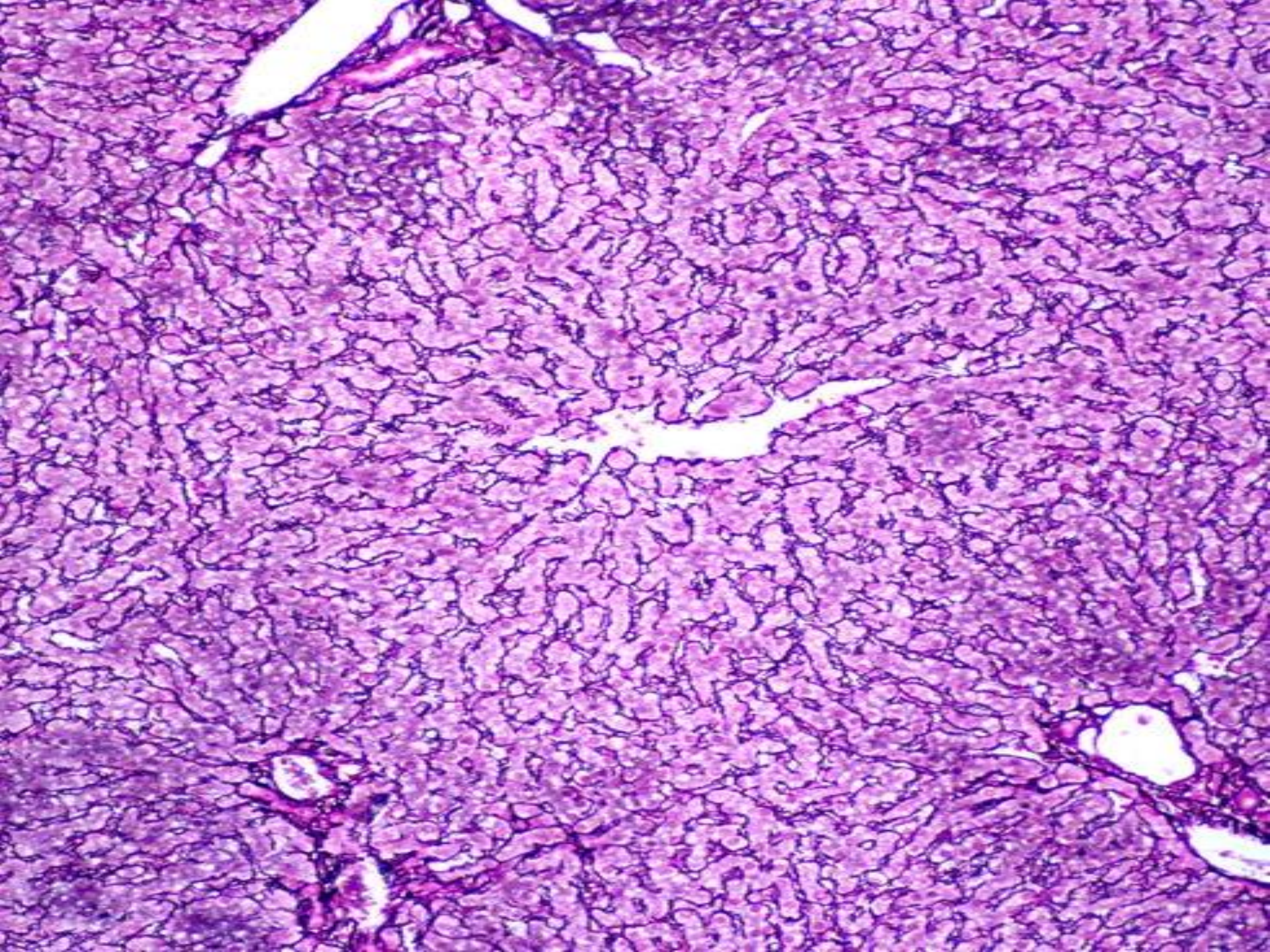
Reticular
fibers

Photomicrograph: Dark-staining network of reticular connective tissue fibers forming the internal skeleton of the spleen (350 \times).

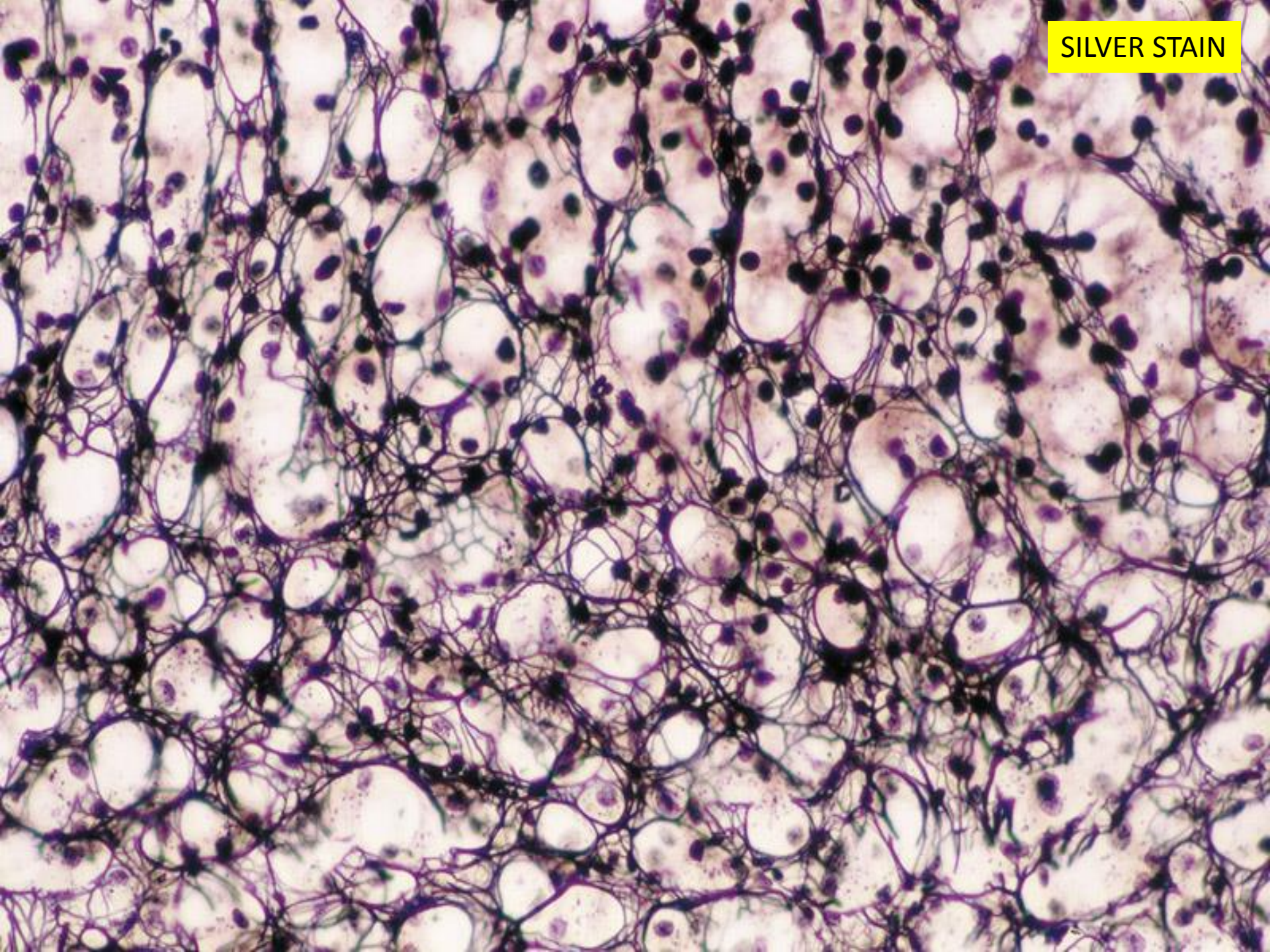
Reticular CT

- Consists of fine interlacing reticular fibers and reticular cells.
- Found in liver, spleen and lymph nodes.
- Function = forms the framework (stroma) of organs





SILVER STAIN



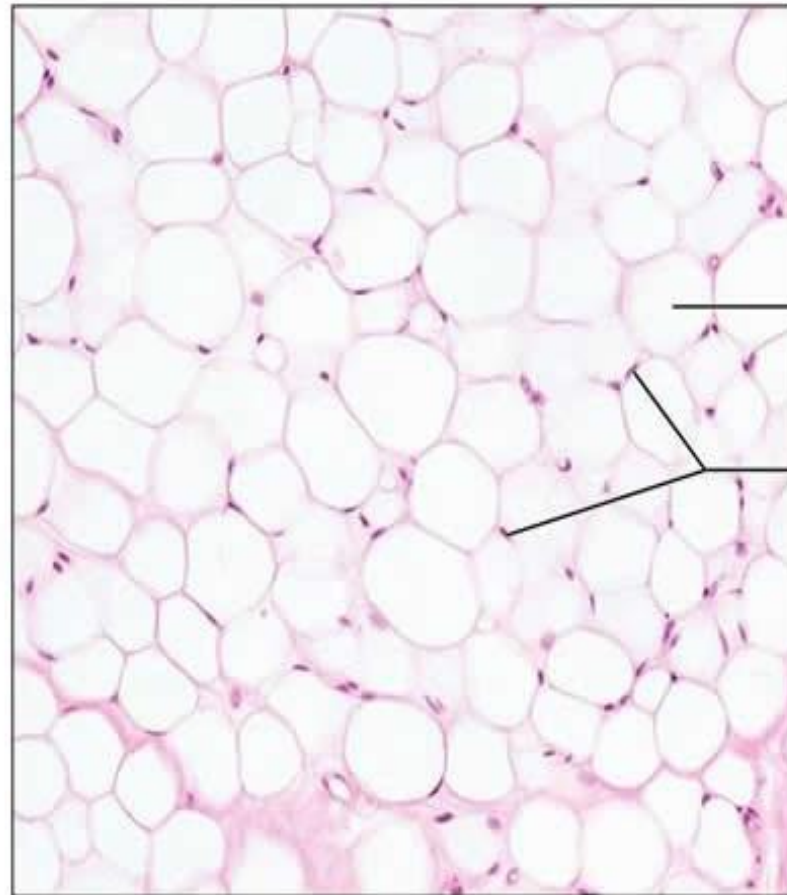
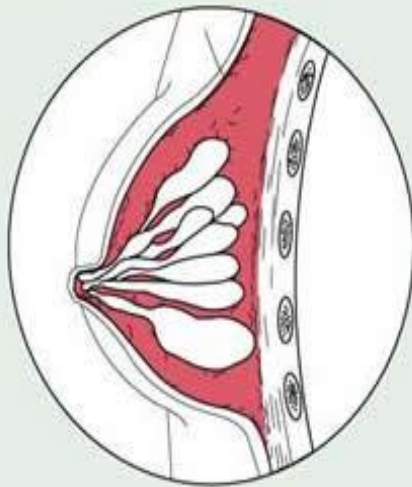
Adipose connective tissue

(b) Connective tissue proper: loose connective tissue, adipose

Description: Matrix as in areolar, but very sparse; closely packed adipocytes, or fat cells, have nucleus pushed to the side by large fat droplet.

Function: Provides reserve food fuel; insulates against heat loss; supports and protects organs.

Location: Under skin; around kidneys and eyeballs; within abdomen; in breasts.



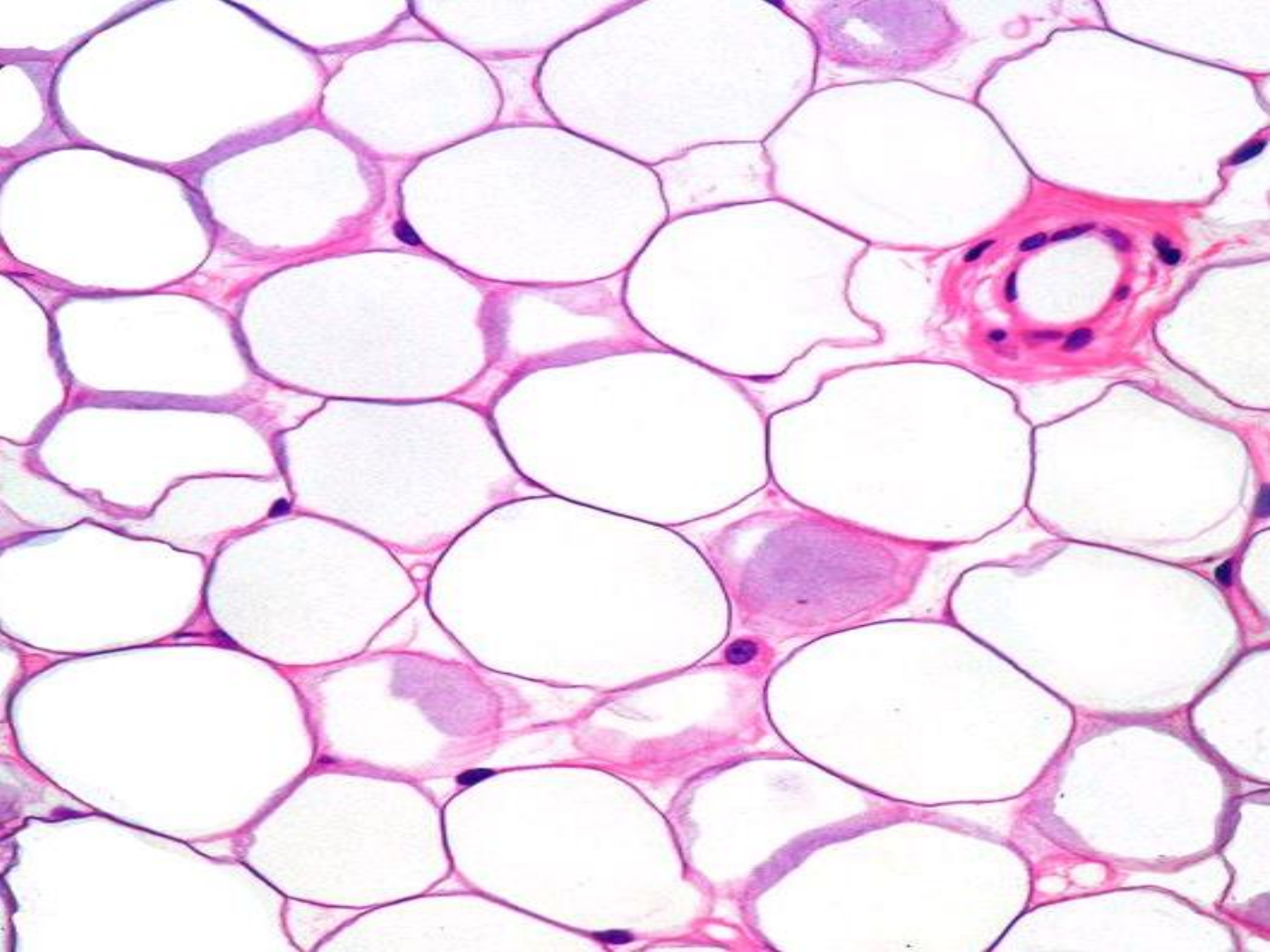
Vacuole
containing
fat droplet

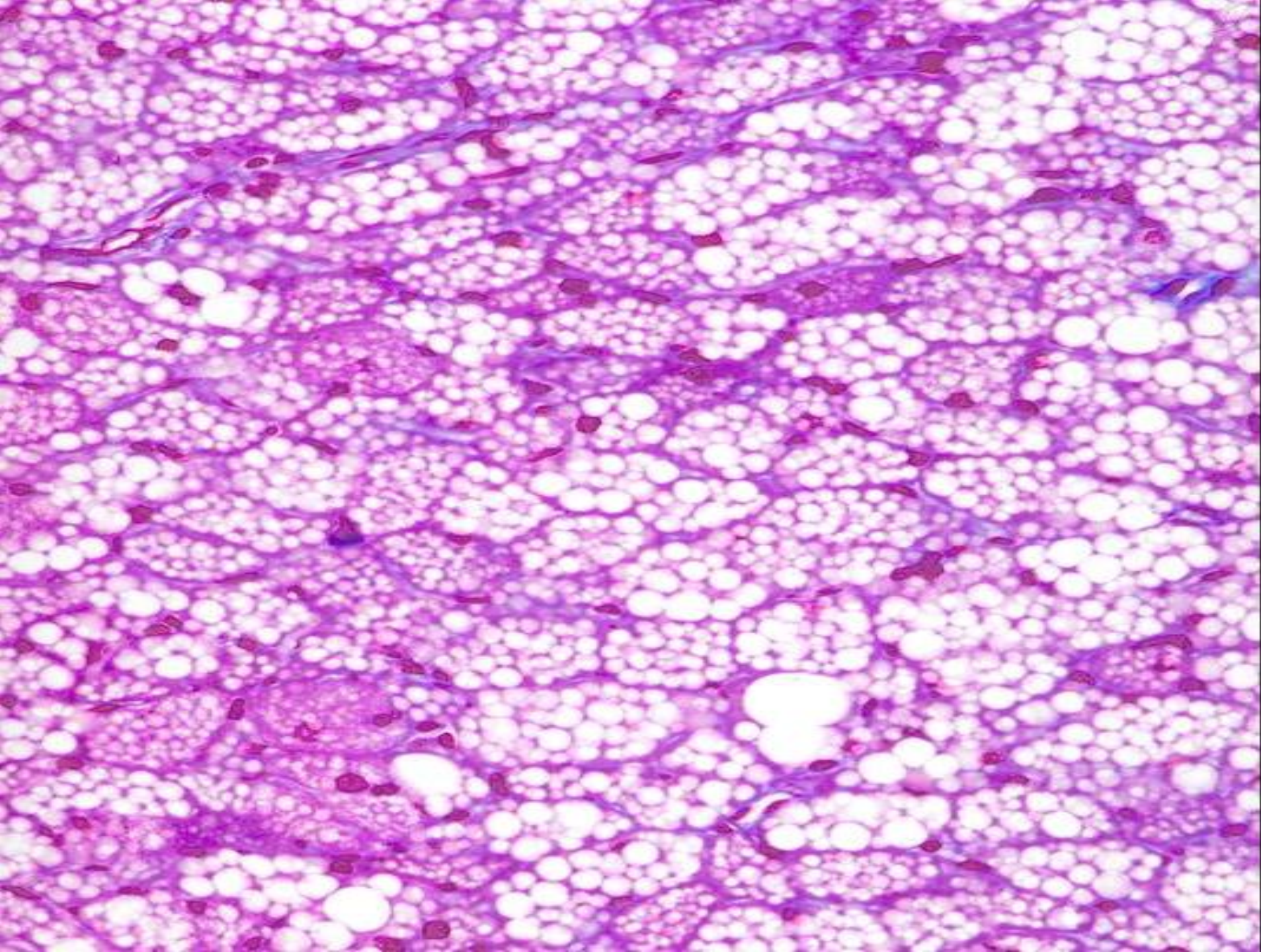
Nuclei of
fat cells

Photomicrograph: Adipose tissue from the subcutaneous layer under the skin (450 \times).

Adipose tissue

- Consists of adipocytes; "signet ring" appearing fat cells. They store energy in the form of triglycerides (lipids).
 - Found in subcutaneous layer, around organs and in the yellow marrow of long bones.
 - Function = supports, protects and insulates, and serves as an energy reserve.
- Types:
 - Yellow or white – found in most of the bulk of the human body
 - Brown fat cells – concerned with heat production, particularly important in newborn



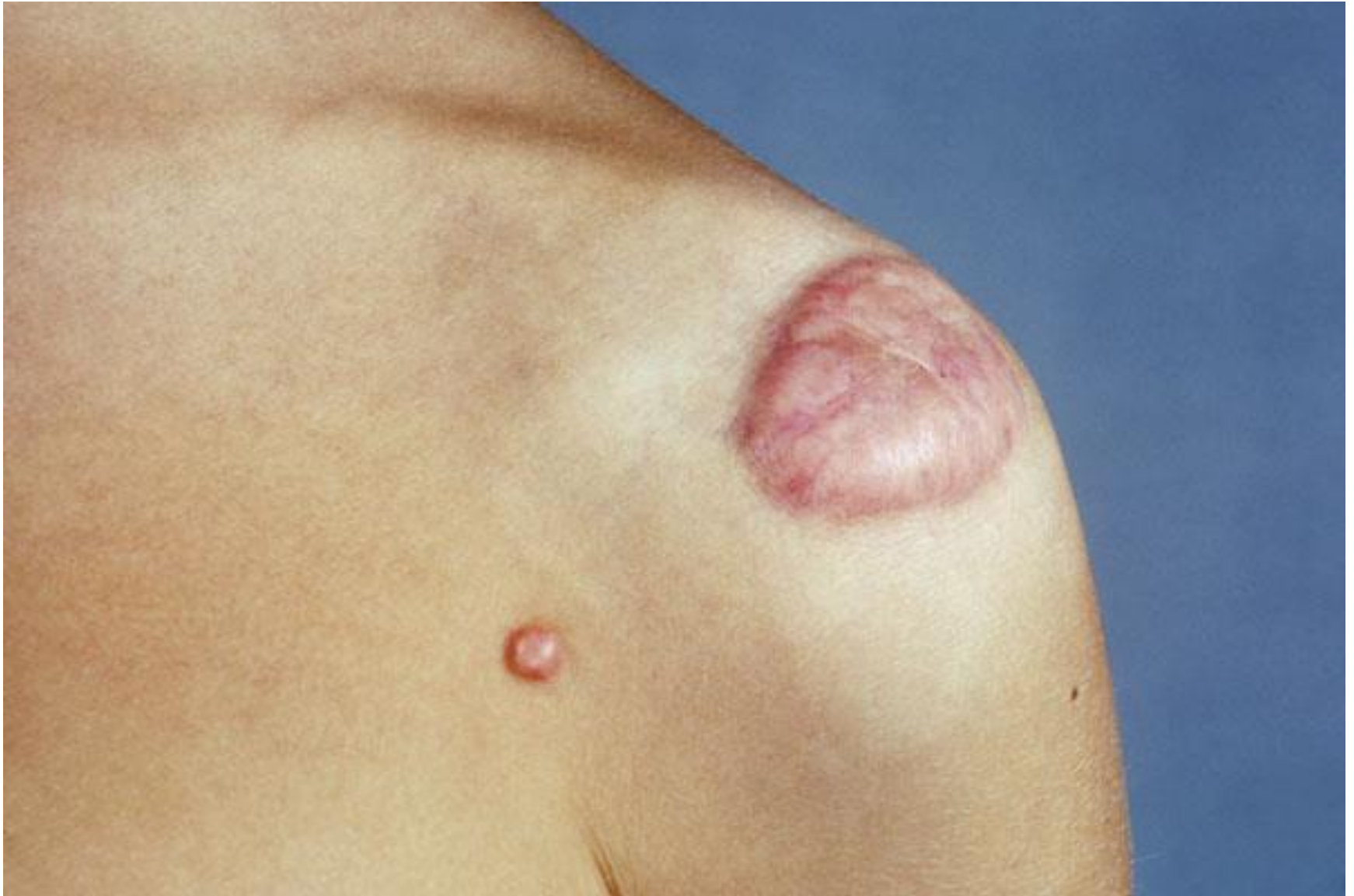

Clinical Applications

Keloid

Is a local swelling caused by abnormally large amounts of collagen that form in scars of the skin.

It occurs most often in individuals of African descent.



Keloids

Is the excessive accumulation of water in the extracellular spaces of connective tissue

Edema

