WEEK 4EMBRYO

General features



The most important feature in the development of the head and neck is the
Formation of
THE **PHARYNGEAL OR BRANCHIALARCHES**

Is it branchial or is it pharyngeal arch؟

development of pharyngeal arches resembles formation of **gills in fish**

However, in the human embryo **real gills)branchia) are never** formed. Therefore, the term **pharyngeal arches has been adopted for the human embryo.**

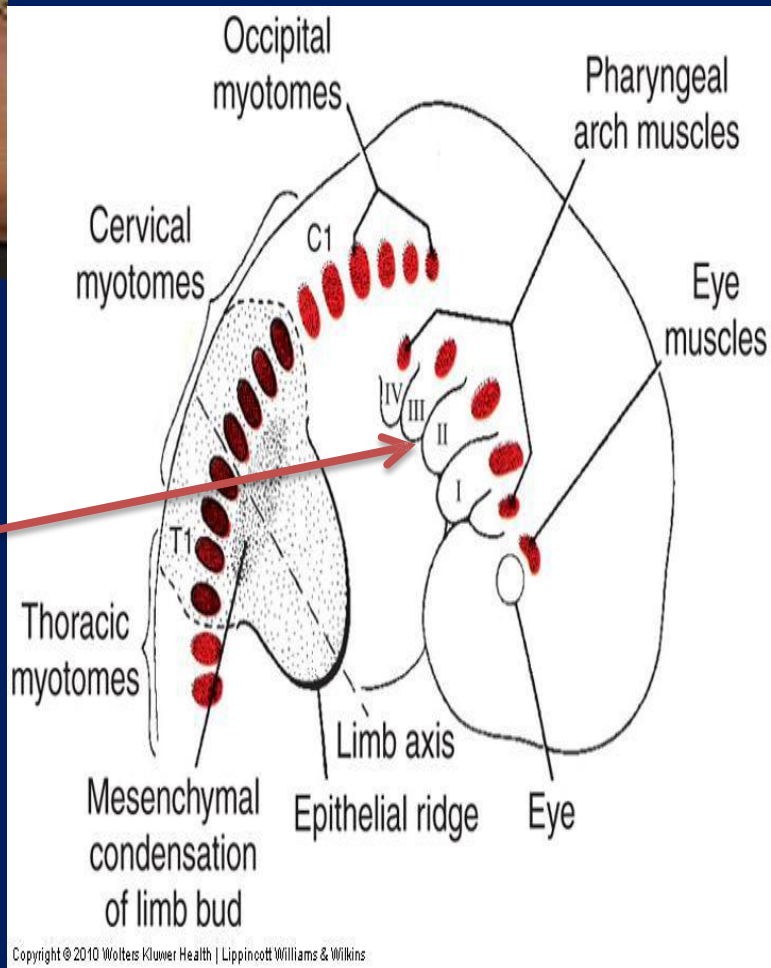

When they appear?

THE **PHARYNGEALARCHES**
appear
in the fourth and fifth
weeks of development

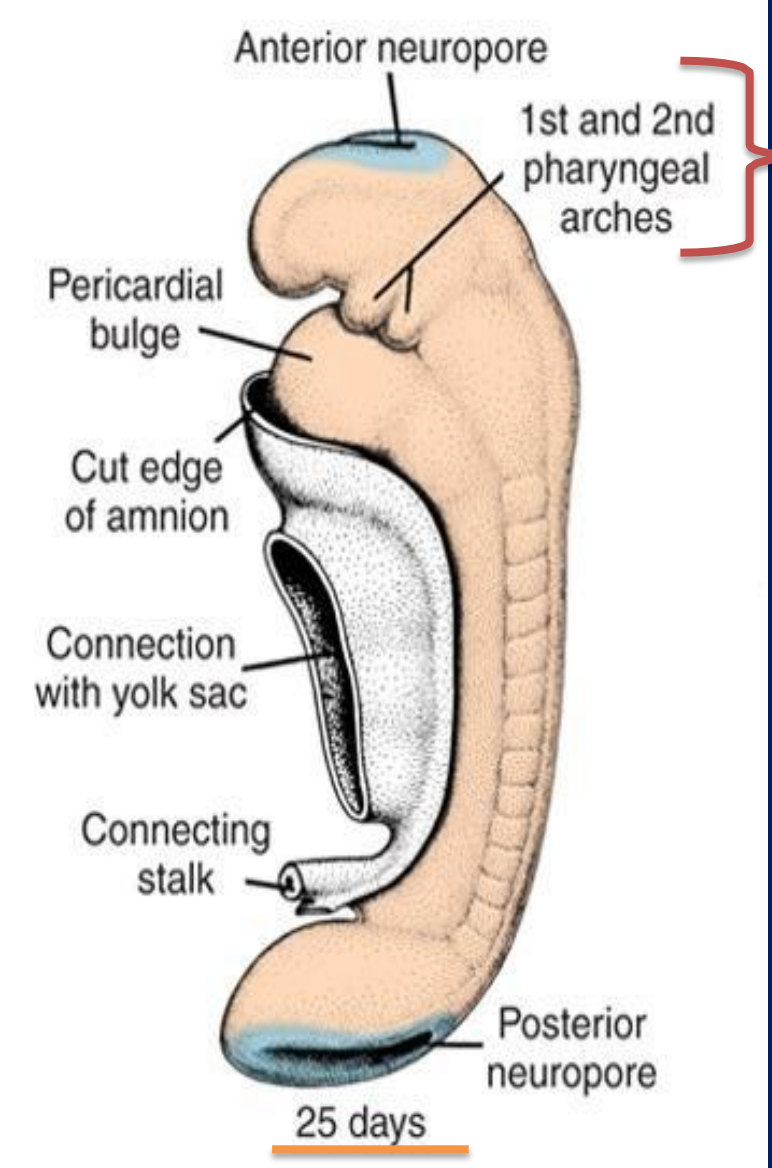

In a cross section of the embryo in the area of the head and neck

The following can be noticed

THE **PHARYNGEALARCHES**

THE **PHARYNGEALARCHES**
are separated
by deep clefts known as

PHARYNGEAL CLEFTS

with development of the arches and clefts،
a number of outpocketings،

The pharyngeal pouches appear

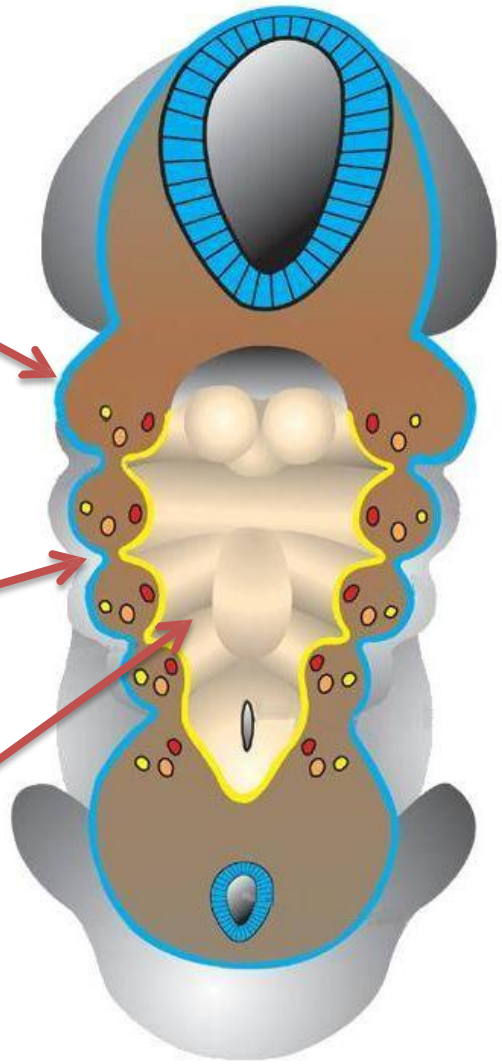

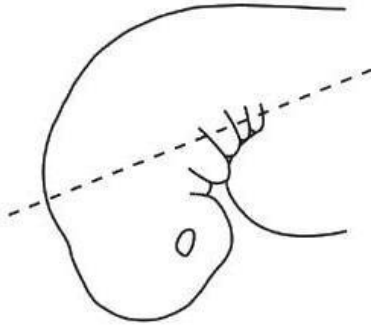

Why the appear؟

Migration of cells from

-1PARAXIAL MESODERM
-2LATERAL PLATE MESODERM
-3NEURAL CREST

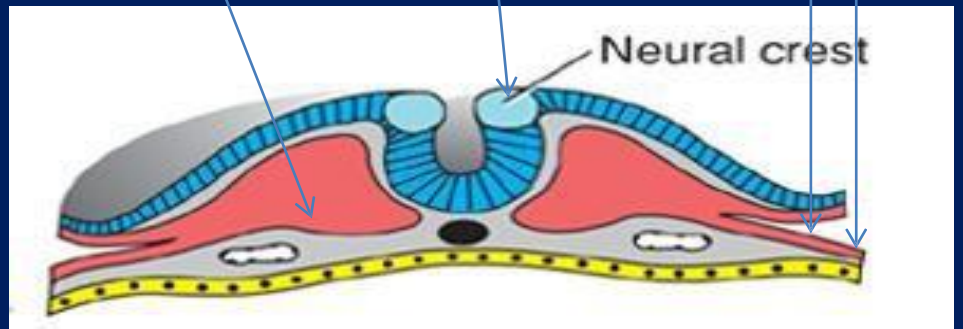

Migration of the cells from the occipital Myotomes into the future mouth to form the tongue

This is an explanation to how the arches appear…. as a result of migration of the cells from the medial mesoderm (somites) into the regions of the future head and neck.

As we mentioned there are other reasons

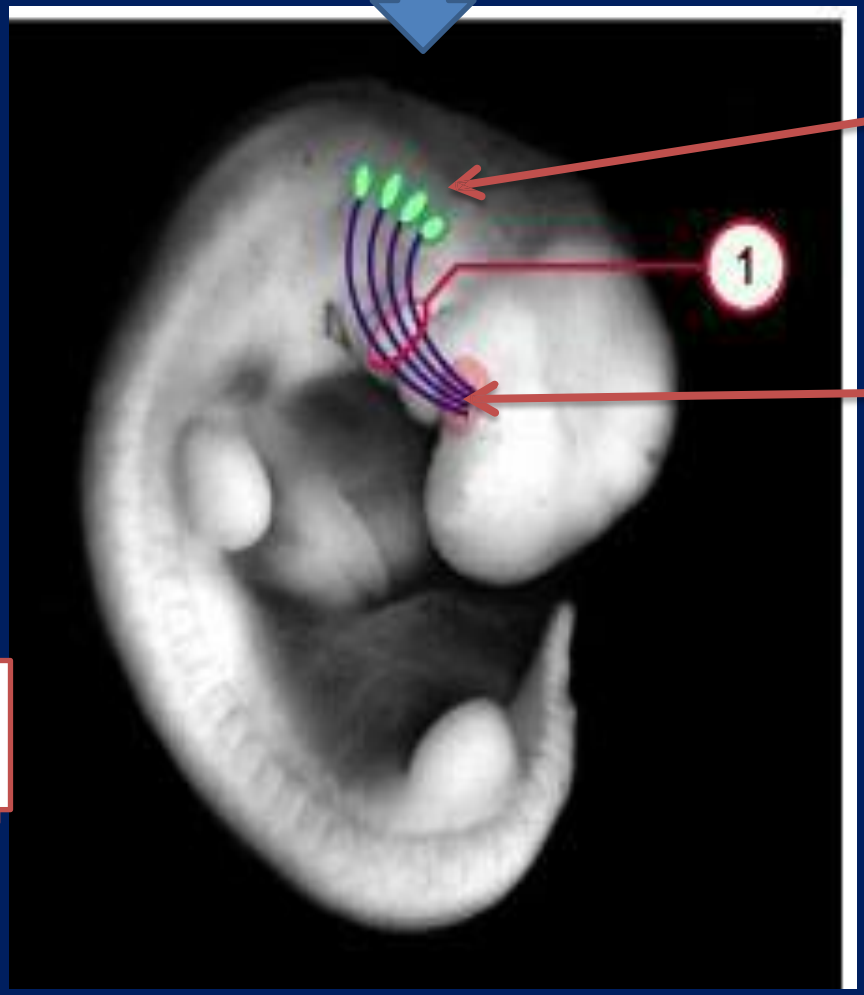

Occipital somites

tongue

-1 PHARYNGEAL ARCHS

How many arches?

6

However, The fifth and sixth arches are rudimentary and are not visible on the surface of the embryo

They are numbered in craniocaudal sequence

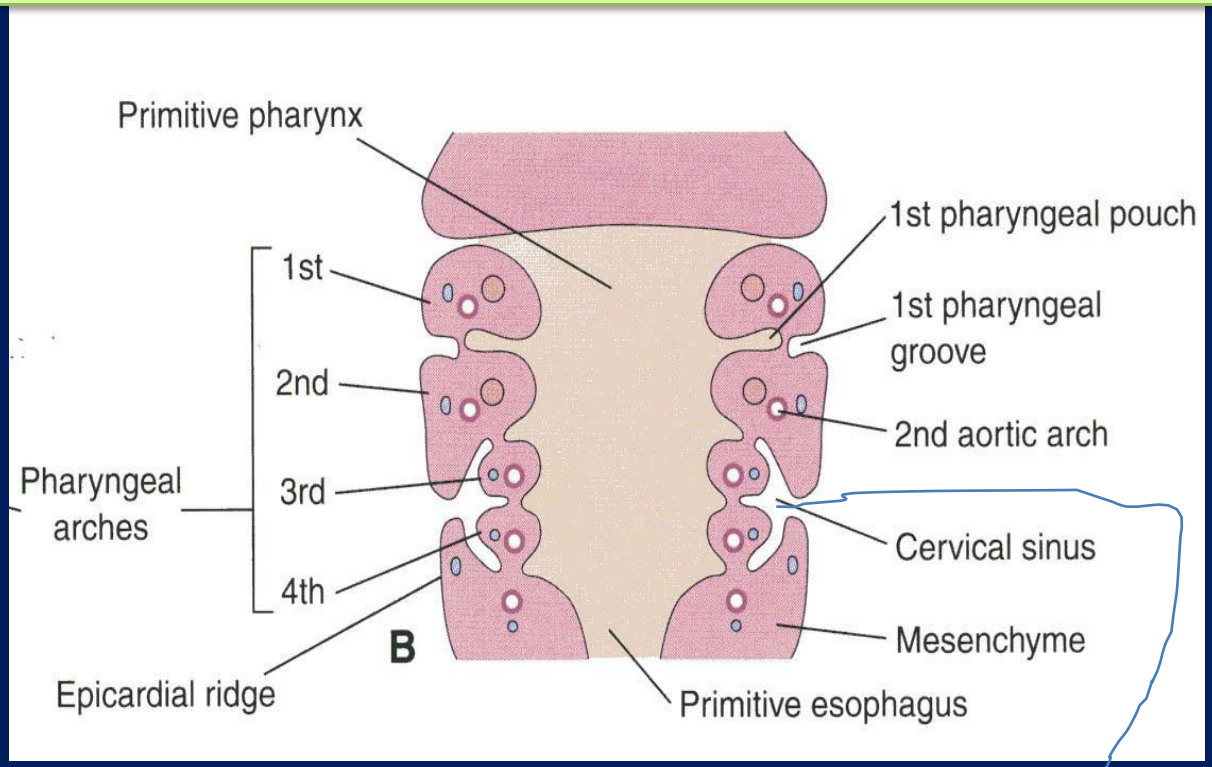

note

<u>During the fifth week,</u> the second pharyngeal arch enlarges and overgrows the third and fourth arches, forming the ectodermal depression called **<u>cervical sinus</u>**

Each pharyngeal arch consists of:

-1surface ECTODERM
-2a core of MESENCHYMAL tissue
-3epithelium of ENDODERMAL origin

Each pharyngeal arch contains:

1- An artery that arises from the primordial heart

A. cartilaginous rod, forms the skeleton of the arch

3. Muscular component *gives the* muscles in the head and neck
)each arch has its own cranial nerve and wherever the muscle cells migrate, they carry their nerve component with them(

4. Nerve, supplies the mucosa and muscles derived from the arch

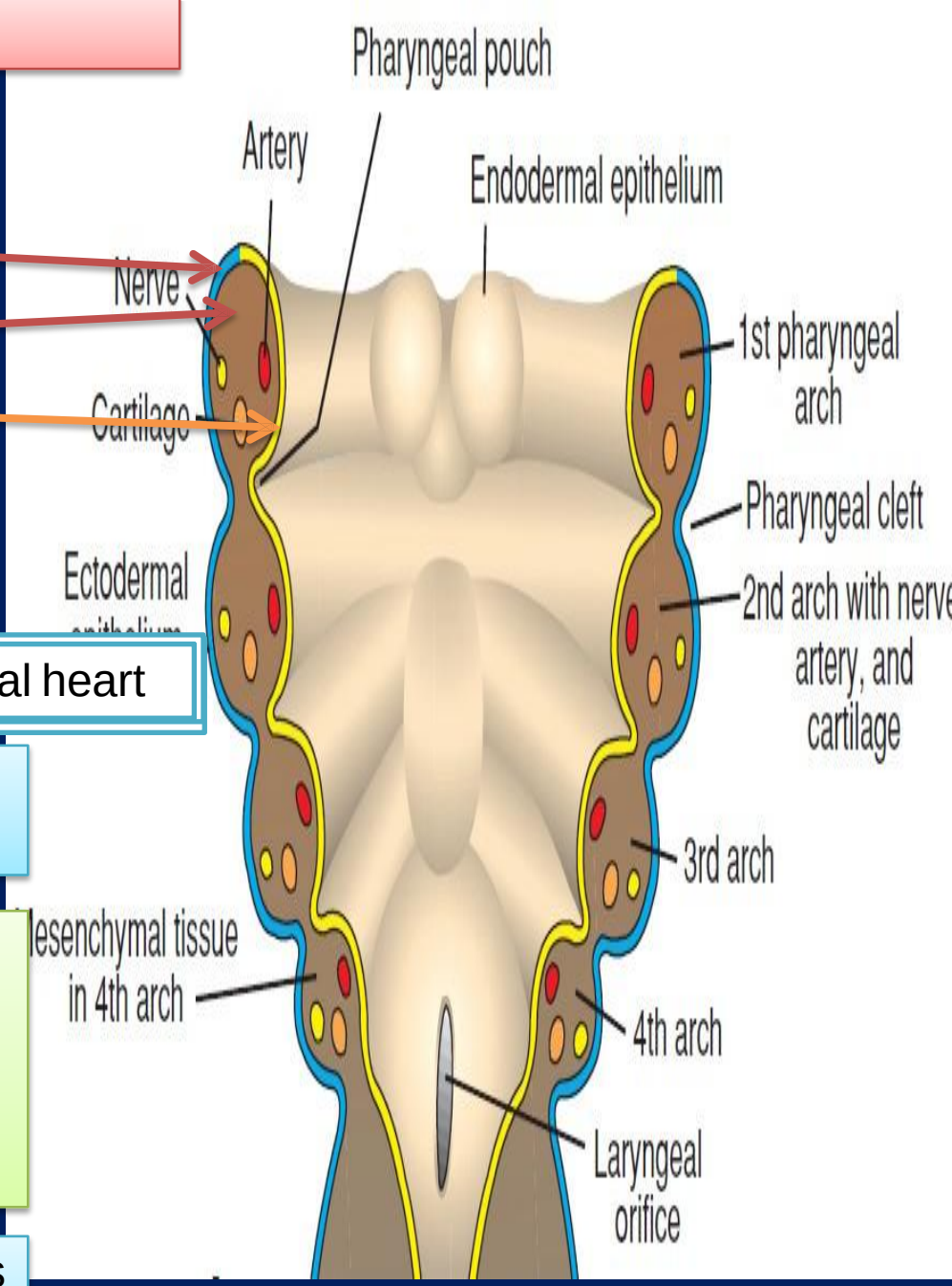

What are the bones and cartilages of the head and neck?

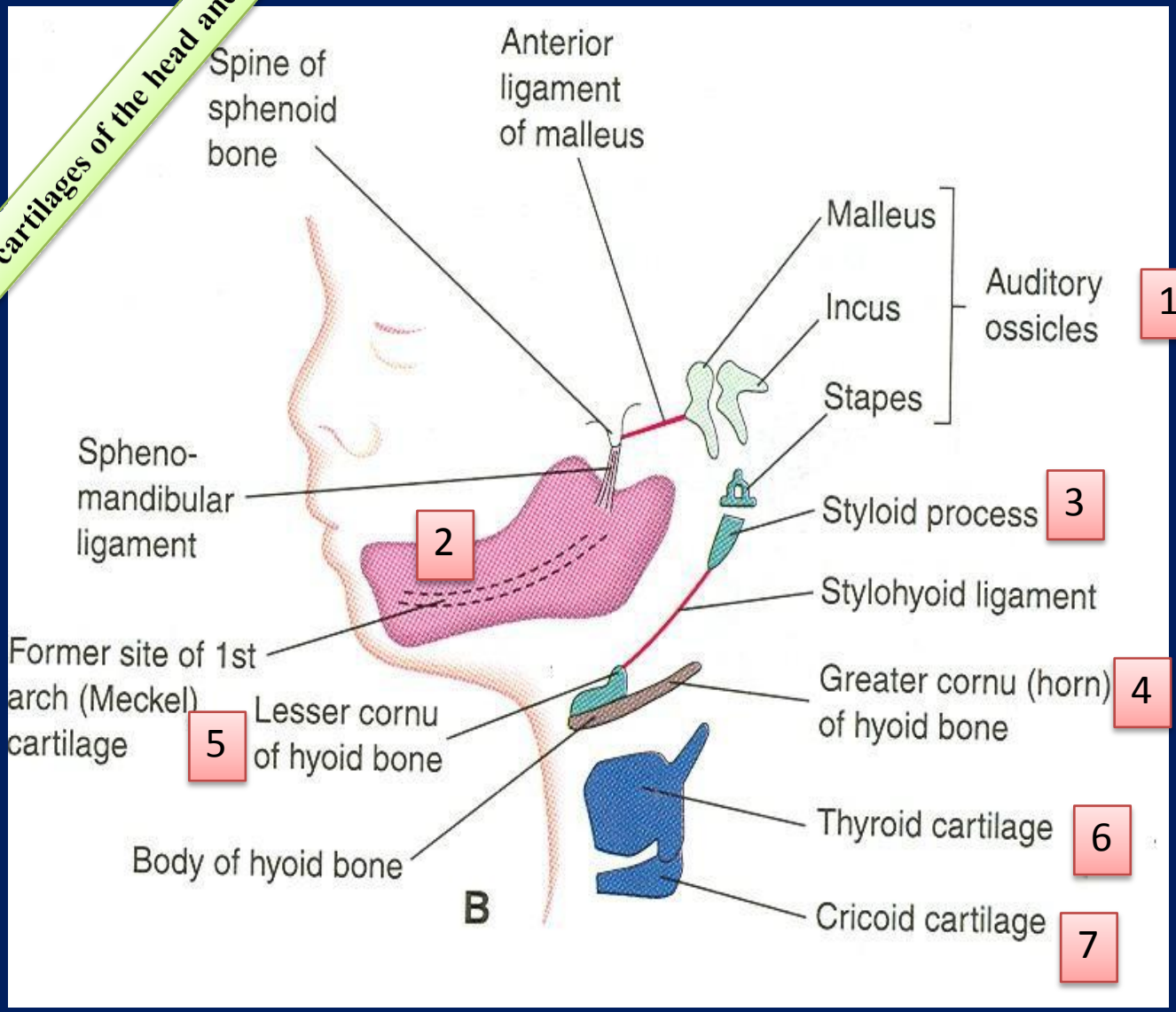

What are the muscles of the head?

1 **Muscles of facial expression**
2 **Muscles of mastication**

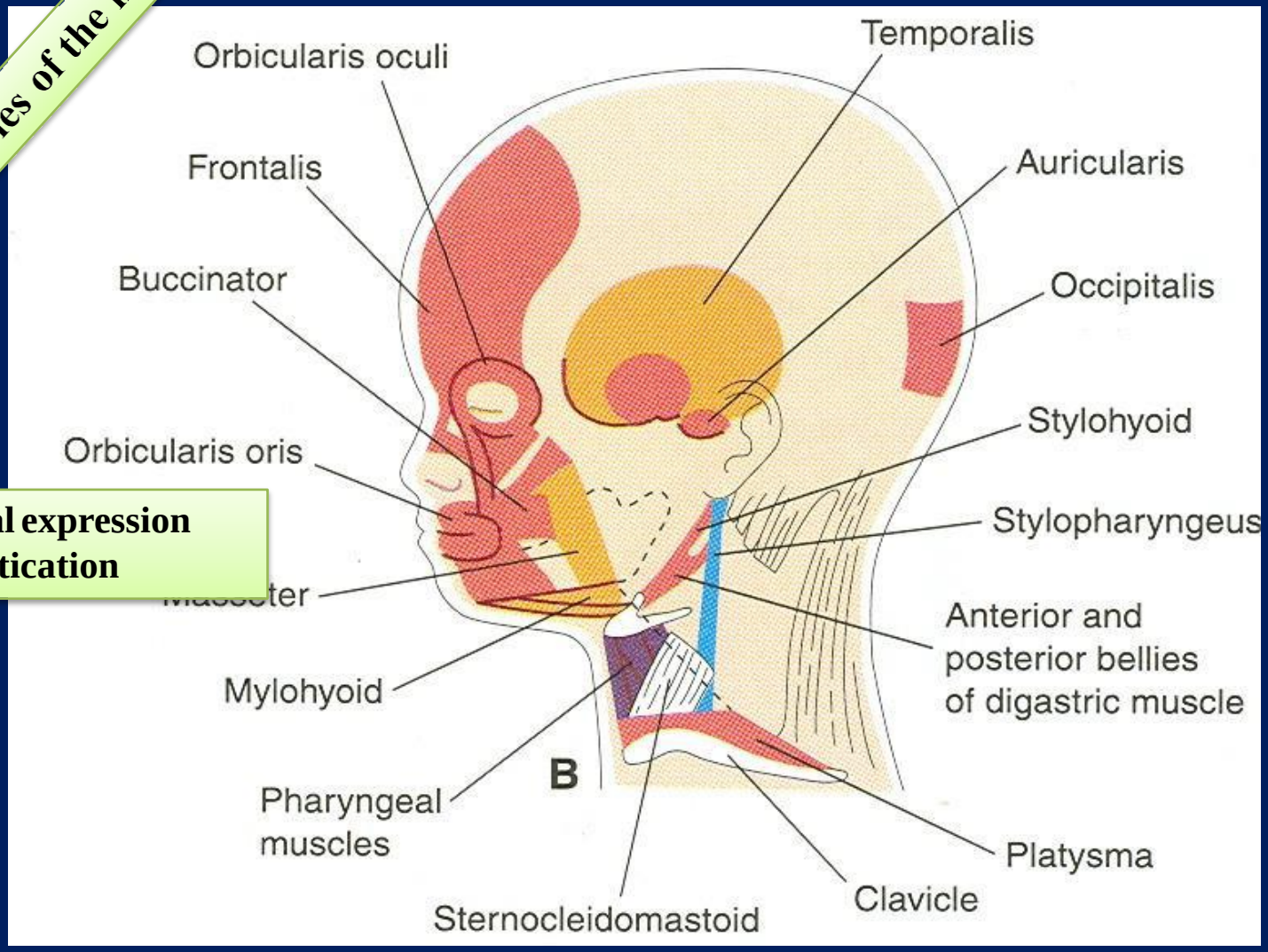

Nerves of the head and neck?

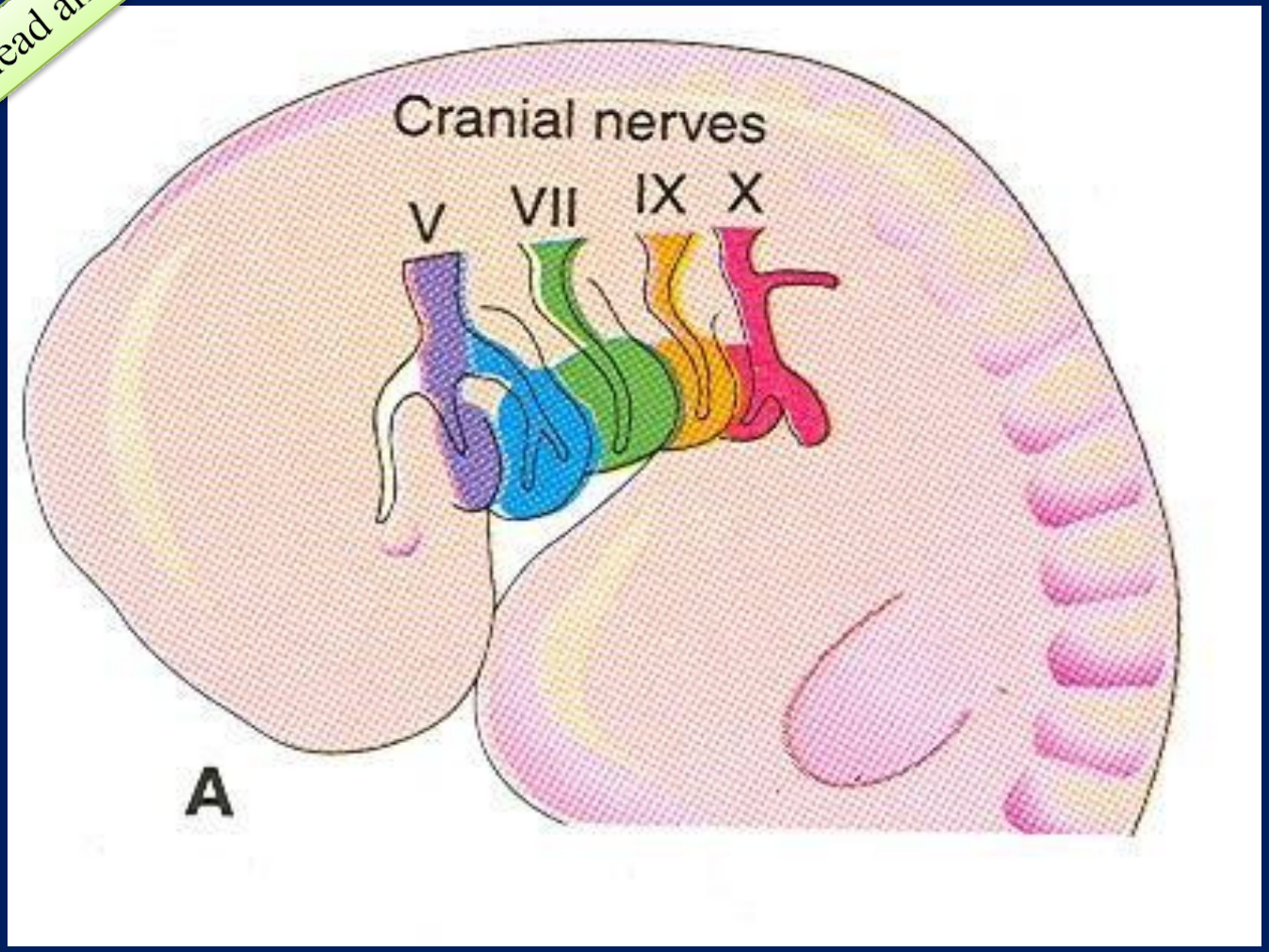

What are the organs of the head and neck?

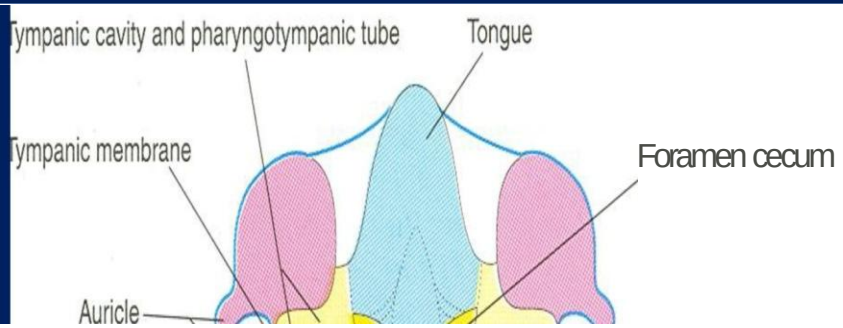

Palatine tonsil

Superior parathyroid gland

Tonsillar sinus

Inferior parathyroid gland

FIRST PHARYNGEAL ARCH

The **first pharyngeal arch consists of**
1- A DORSAL PORTION
THE MAXILLARY PROCESS
and
-2A VENTRAL PORTION
THE **MANDIBULAR PROCESS**
which contains <u>Meckel's cartilage</u>

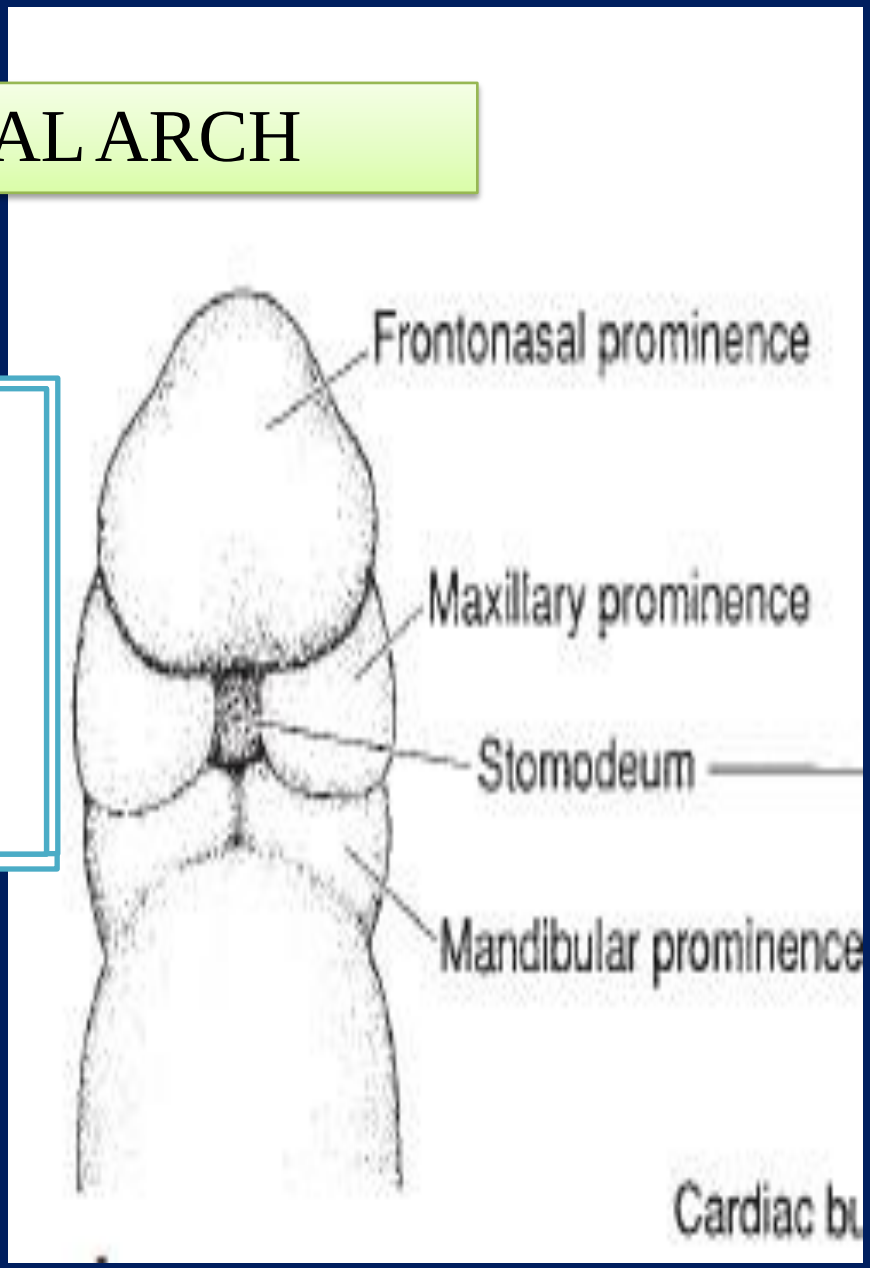

Cartilaginous derivatives of the first pharyngeal arch

-1The dorsal end of first arch cartilage **(Meckel cartilage)** ossifies to form malleus and incus

-2The middle part of cartilage forms anterior ligament of malleus sphenomandibular ligament

-3Ventral part of the first arch cartilages form primordium of the mandible. The cartilage disappears as mandible develops around it

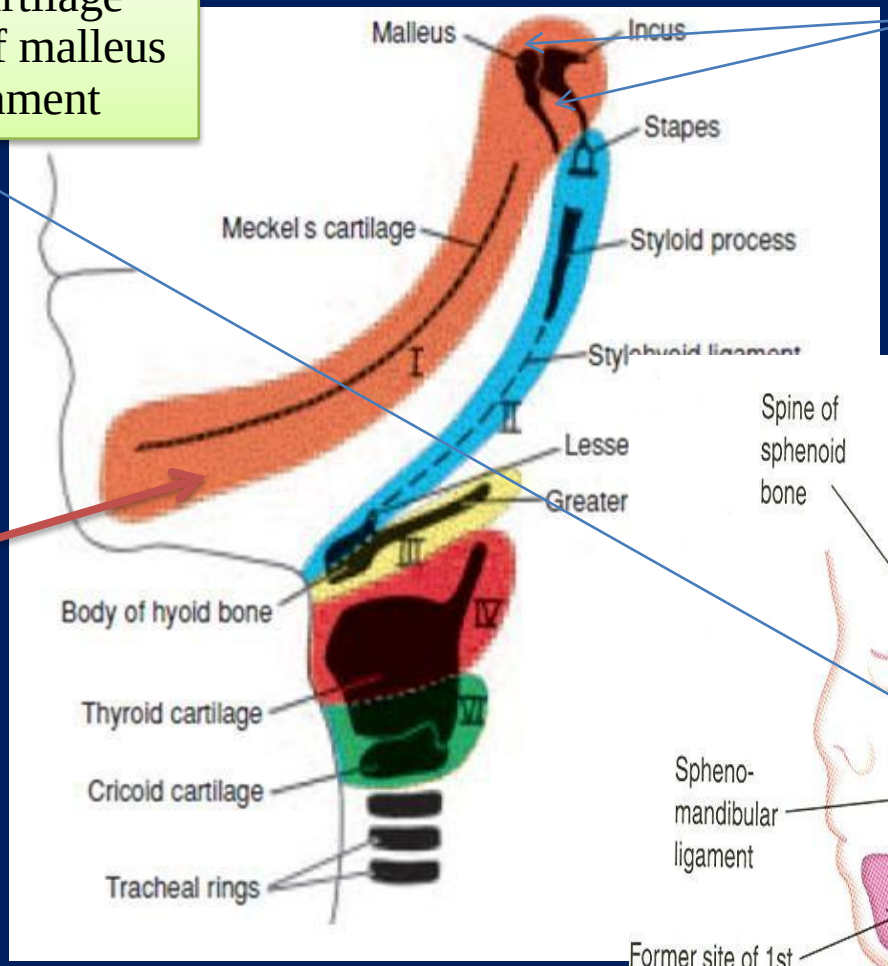

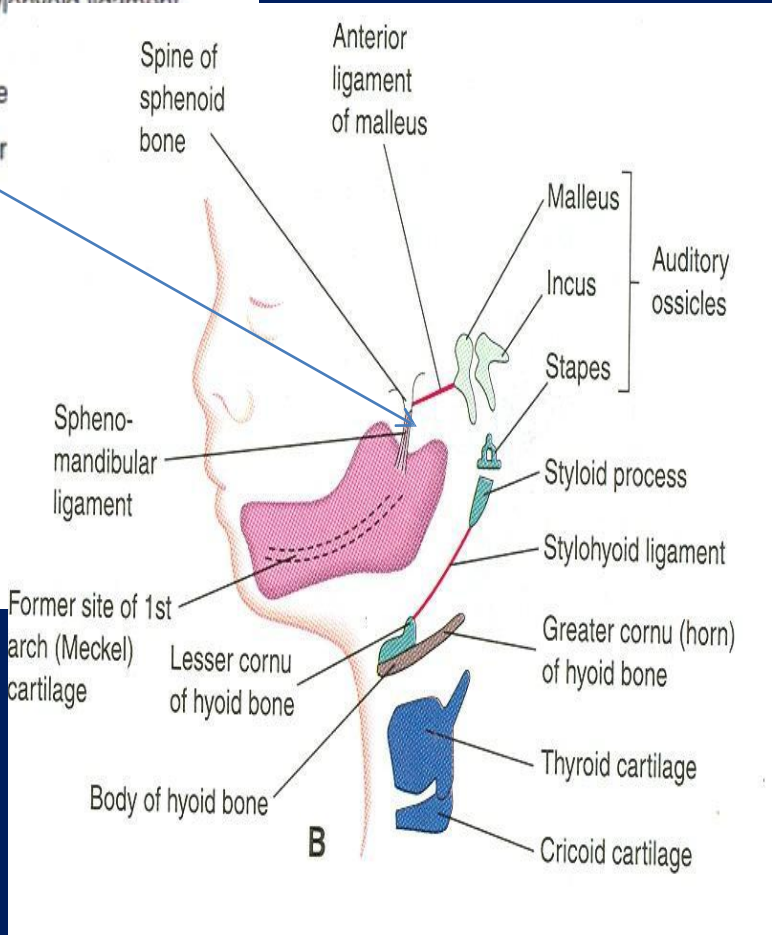

Muscular Derivatives of first Pharyngeal Arch

-1The **muscles of mastication**
)temporalis, masseter, and pterygoids‹(
-2**Anterior belly of the digastric**
-3mylohyoid
-4tensor tympani, and tensor palatini

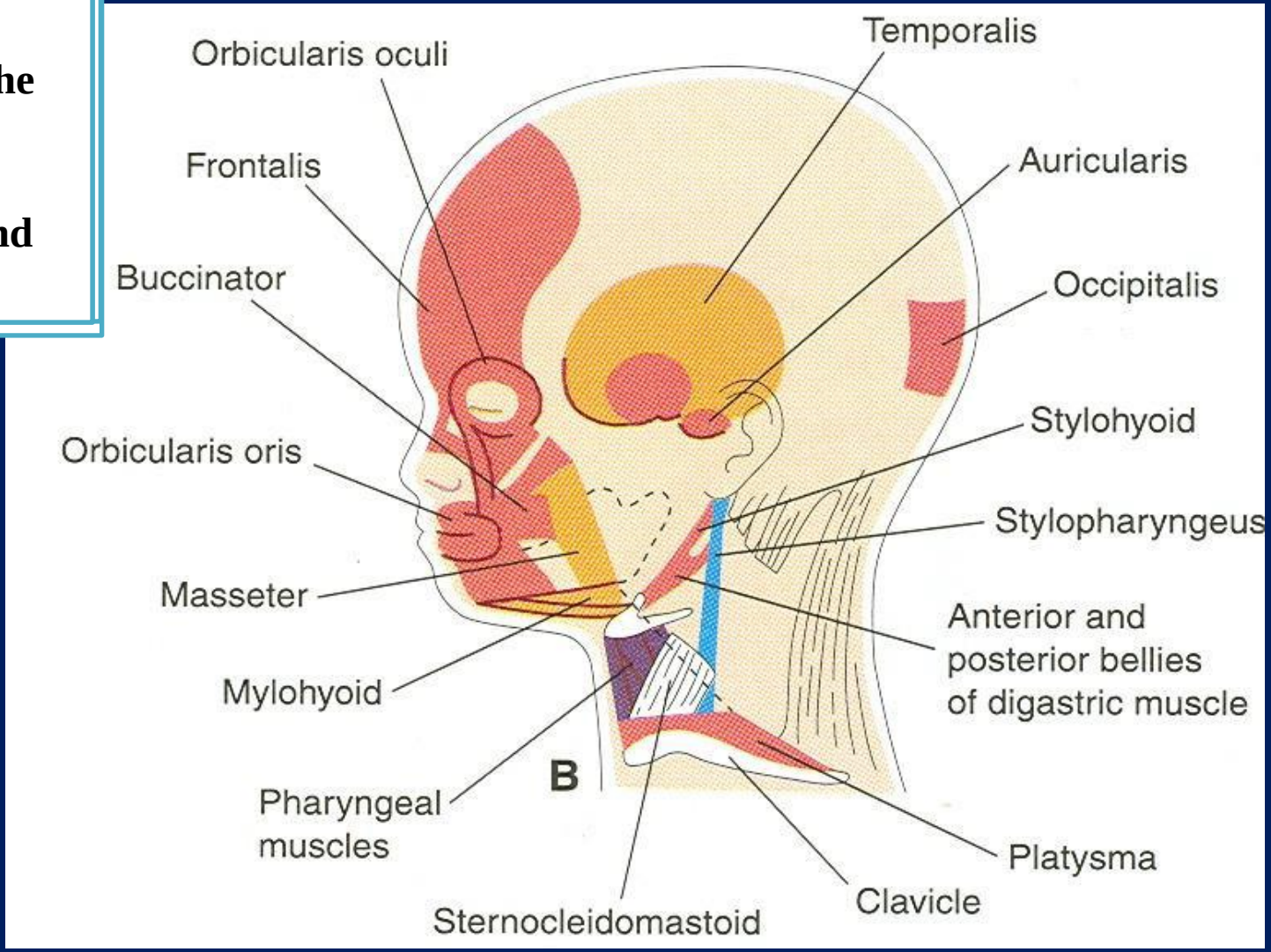

The nerve supply to the muscles of
the first arch is provided by
the **mandibular branch of the trigeminal nerve**

Since mesenchyme from the first arch also contributes
to the dermis of the face،
sensory supply to the skin of the face
is provided by
ophthalmic, maxillary, and mandibular branches of the trigeminal nerve.

SECOND PHARYNGEAL ARCH)**HYOID ARCH**(

➢The cartilage of the **second or hyoid arch (Reichert's cartilage)** gives rise to:

1 The stapes

2 Styloid process of the temporal bone

3 Stylohyoid ligament

4 The lesser horn and the upper part of the body of the hyoid bone

Muscles of the hyoid arch are:

1- The stapedius

2 Stylohyoid

3 Posterior belly of the digastric

4 Auricular, and

5 muscles of facial expression

The nerve of the second arch IS

The **facial nerve, supplies all of these muscles**

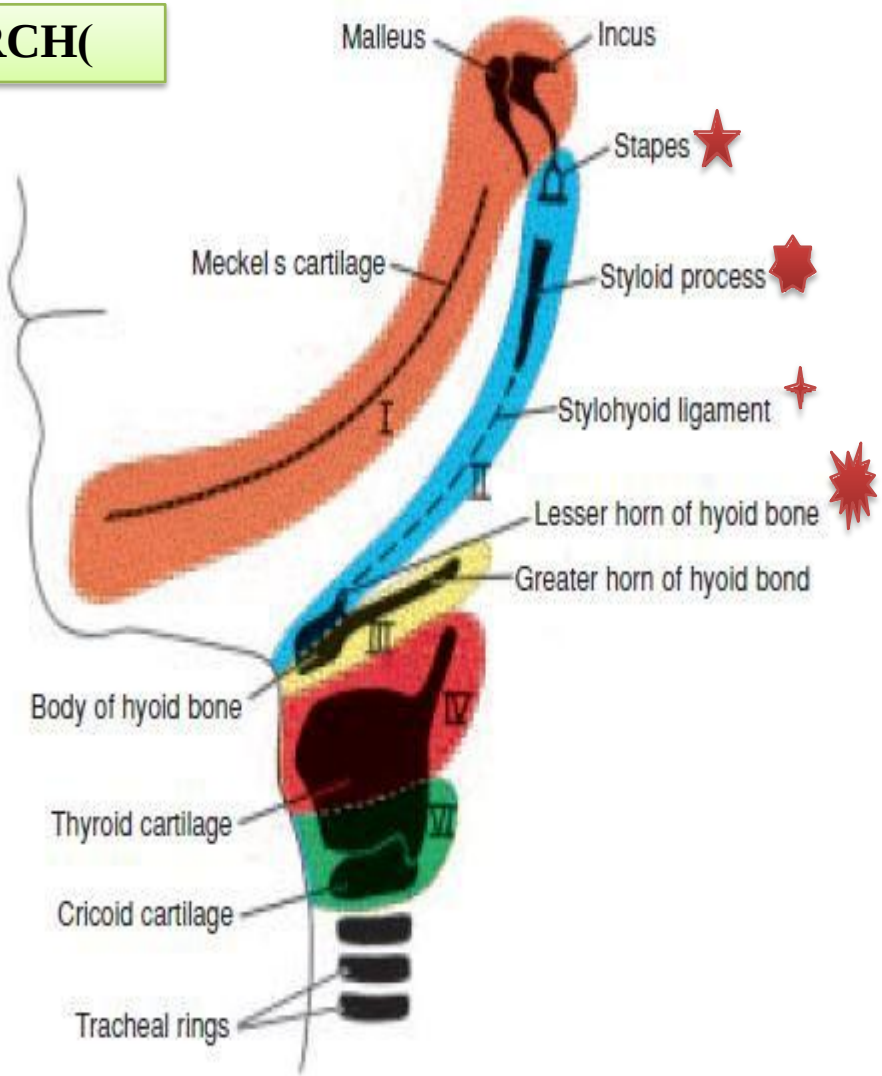

Figure 15.9 Definitive structures formed by the cartilaginous components of the various pharyngeal arches.

of the **larynx** (Fig. 15.9). **Muscles** of the fourth arch (**cricothyroid, levator palatini,** and **constrictors of the pharynx**) are innervated by the **superior laryngeal branch of the vagus,** the nerve of the fourth arch. Intrinsic muscles

THIRD PHARYNGEAL ARCH

The **cartilage of the third pharyngeal arch produces:**

-1The lower part of the body and greater horn of the hyoid bone

-2The musculature is
limited to the **stylopharyngeus muscles**

These muscles are innervated by the
GLOSSOPHARYNGEAL NERVE
the nerve of the third arch

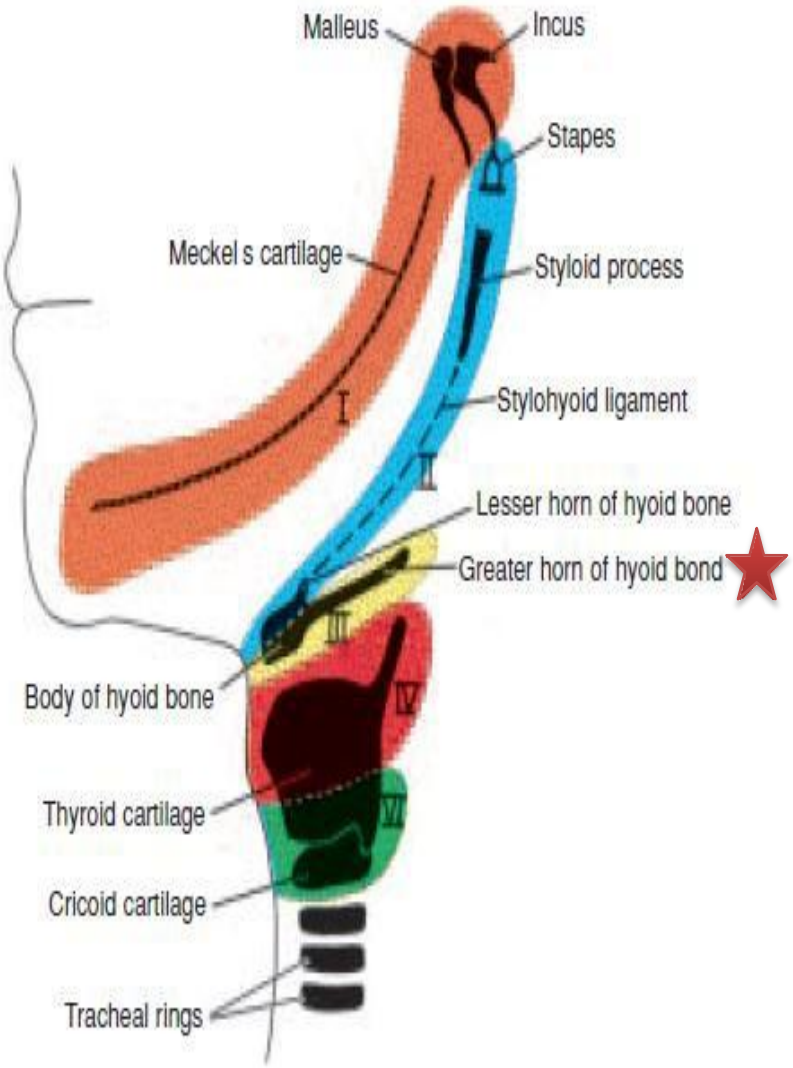

Figure 15.9 Definitive structures formed by the cartilaginous components of the various pharyngeal arches.

of the **larynx** (Fig. 15.9). **Muscles** of the fourth arch (**cricothyroid, levator palatini,** and **constrictors of the pharynx**) are innervated by the **superior laryngeal branch of the vagus,** the nerve of the fourth arch. Intrinsic muscles

FOURTH AND SIXTH PHARYNGEAL ARCHES

Cartilaginous components of the fourth and sixth pharyngeal arches fuse to form

-1THE THYROID
2 CRICOID
3 ARYTENOID
4 CORNICULATE
5 CUNEIFORM

CARTILAGES

The cartilages of the LARYNX

Pharyngeal Arch	Nerve	Muscles	Skeleton
4–6	X. Vagus · Superior laryngeal branch (nerve to fourth arch) · Recurrent laryngeal branch (nerve to sixth arch)	Cricothyroid; levator palatine; constrictors of pharynx Intrinsic muscles of larynx	Laryngeal cartilages (thyroid, cricoid, arytenoid, corniculate, cuneiform)

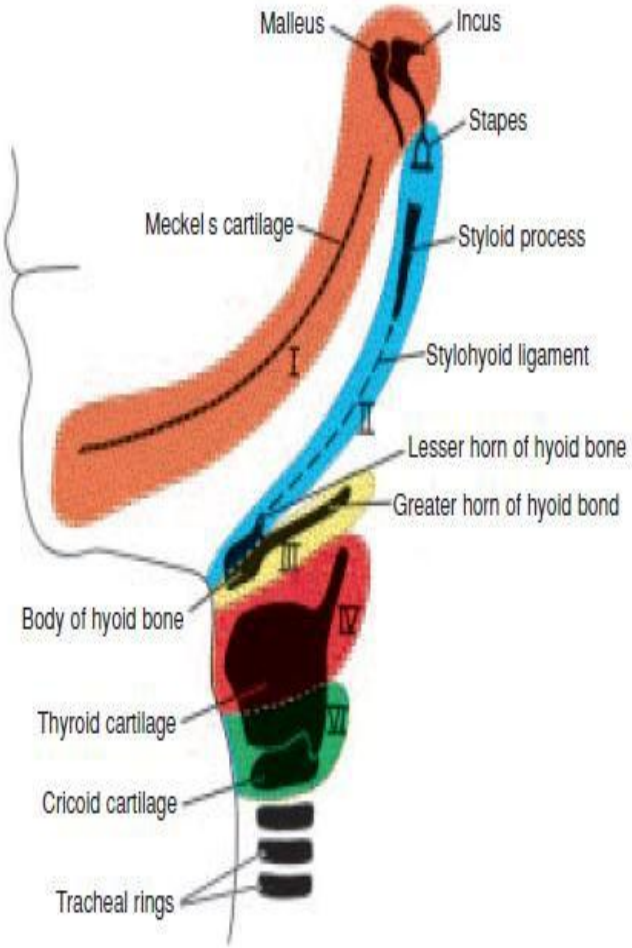

Figure 15.9 Definitive structures formed by the cartilaginous components of the various pharyngeal arches.

of the **larynx** (Fig. 15.9). **Muscles** of the fourth arch (**cricothyroid, levator palatini,** and **constrictors of the pharynx**) are innervated by the **superior laryngeal branch of the vagus,** the nerve of the fourth arch. Intrinsic muscles

-2PHARYNGEAL POUCHES

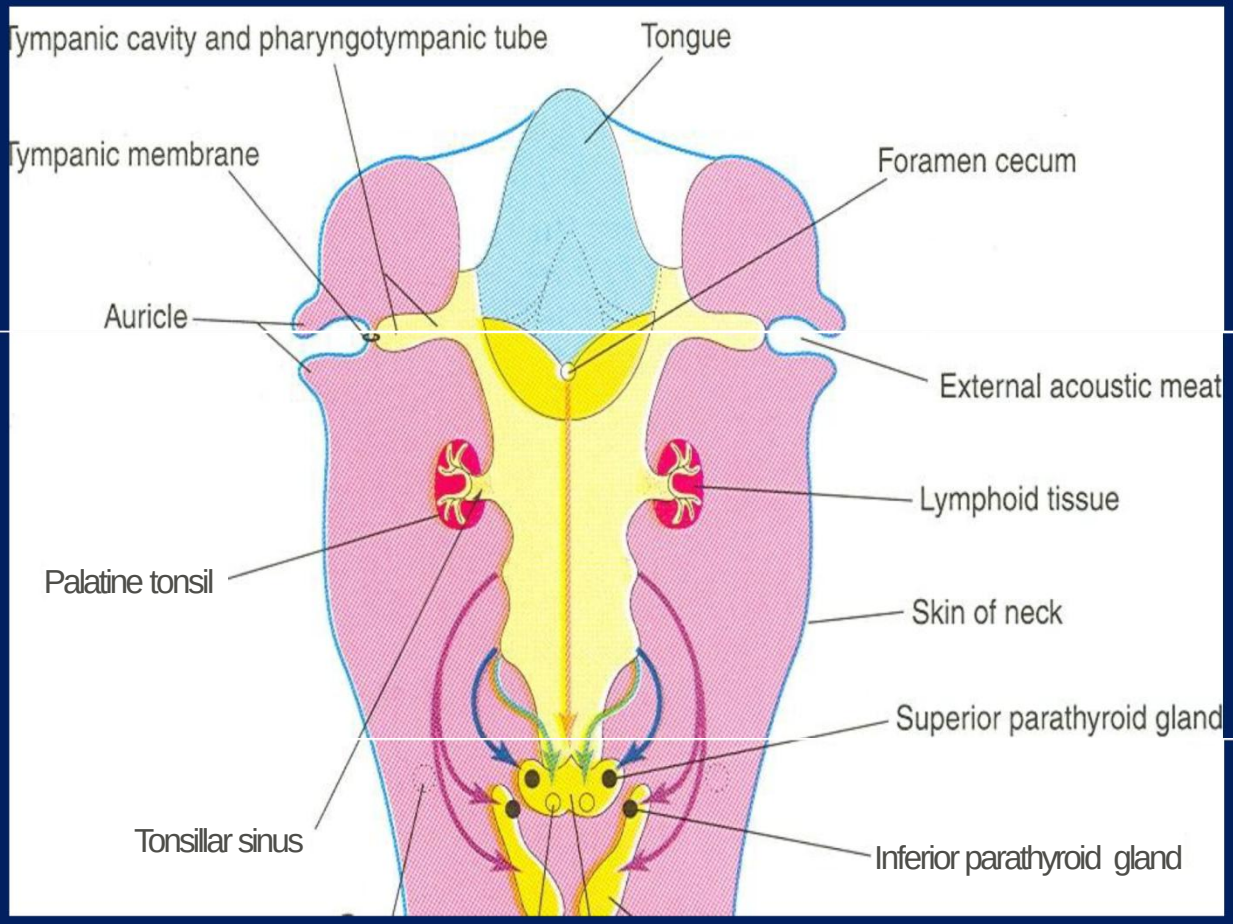
Tympanic cavity and pharyngotympanic tube
Tongue
Tympanic membrane
Foramen cecum
Auricle
External acoustic meat
Lymphoid tissue
Palatine tonsil
Skin of neck
Superior parathyroid gland
Tonsillar sinus
Inferior parathyroid gland

The human embryo has
FIVE PAIRS
of pharyngeal pouches
❖**<u>The last</u>** one of these is atypical and often considered as part of the fourth

FIRST PHARYNGEAL POUCH forms a diverticulum called the *<u>tubotympanic recess</u>*

<u>The FIRST PHARYNGEAL POUCH</u>
comes in contact with the epithelial lining of the first pharyngeal cleft
the future
EXTERNAL AUDITORY MEATUS

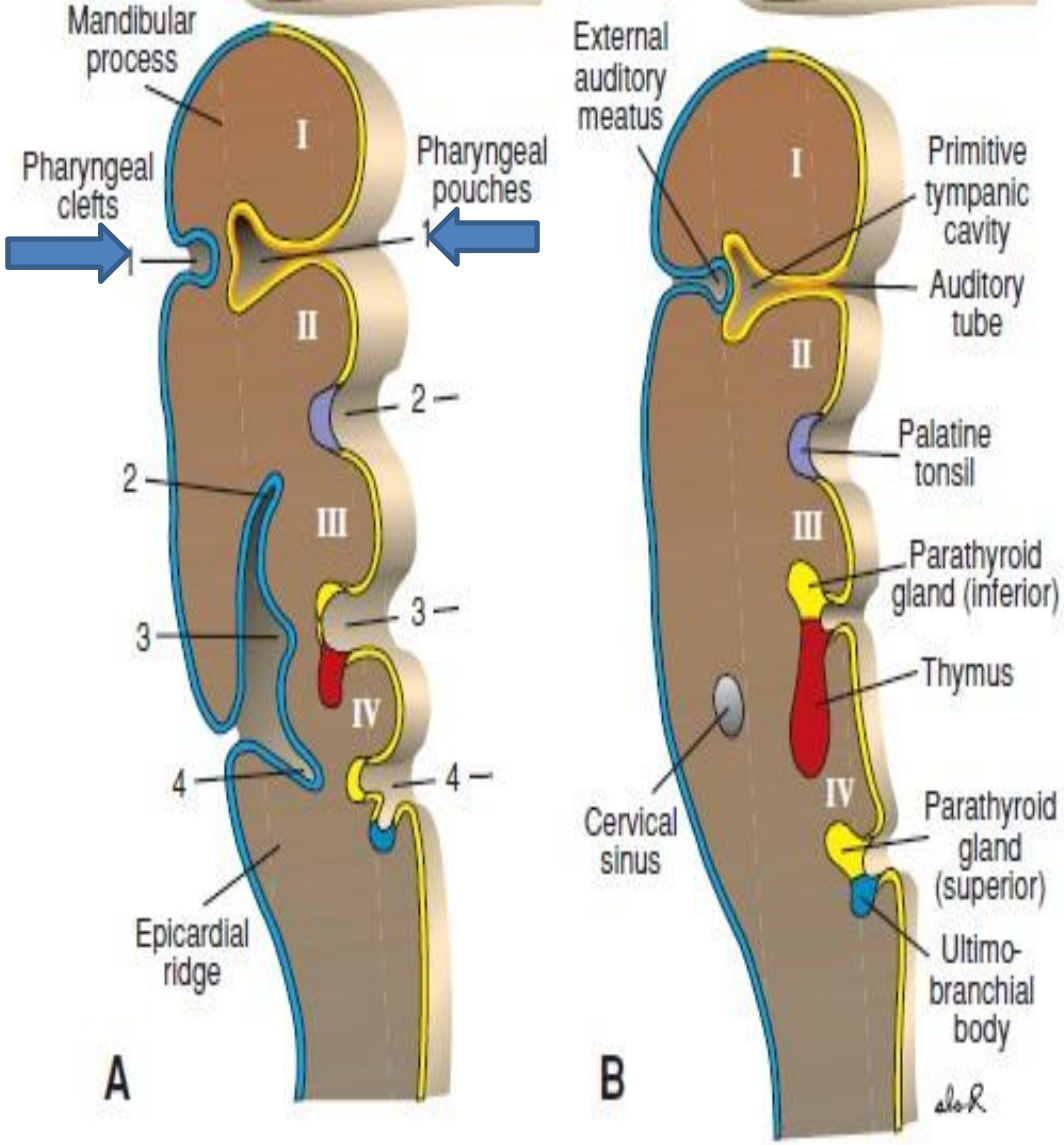

Figure 15.10 A. Development of the pharyngeal clefts and pouches. The second arch grows over the third and fourth arches, burying the second, third, and fourth pharyngeal clefts. **B.** Remnants of the second, third, and fourth pharyngeal clefts form the cervical sinus, which is normally obliterated. Note the structures formed by the various pharyngeal pouches.

The **distal** portion of the diverticulum widens into a saclike structure
the primitive tympanic or

MIDDLE EAR CAVITY

and the **proximal** part remains narrow, forming

THE AUDITORY

)Eustachian) tube

The lining of the tympanic cavity later aids in formation of the tympanic membrane or eardrum

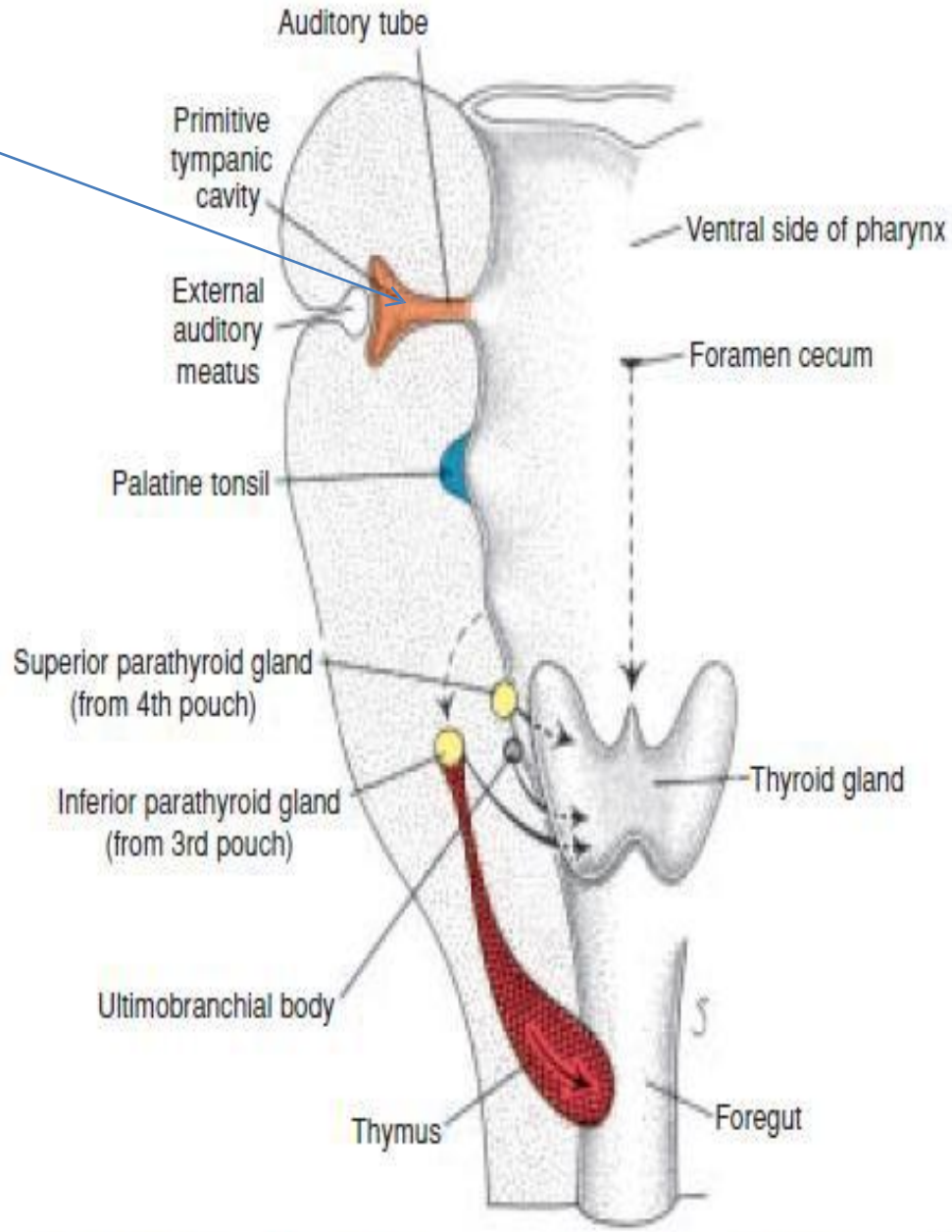

Figure 15.11 Migration of the thymus, parathyroid glands, and ultimobranchial body. The thyroid gland originates in the midline at the level of the foramen cecum and descends to the level of the first tracheal rings.

SECOND PHARYNGEAL POUCH

The epithelial lining of the second pharyngeal pouch proliferates and forms

THE PRIMORDIUM OF THE PALATINE TONSIL

During the third and fifth months, the tonsil is infiltrated by lymphatic tissue

Part of the pouch remains and is found in the adult as the

TONSILLAR FOSSA

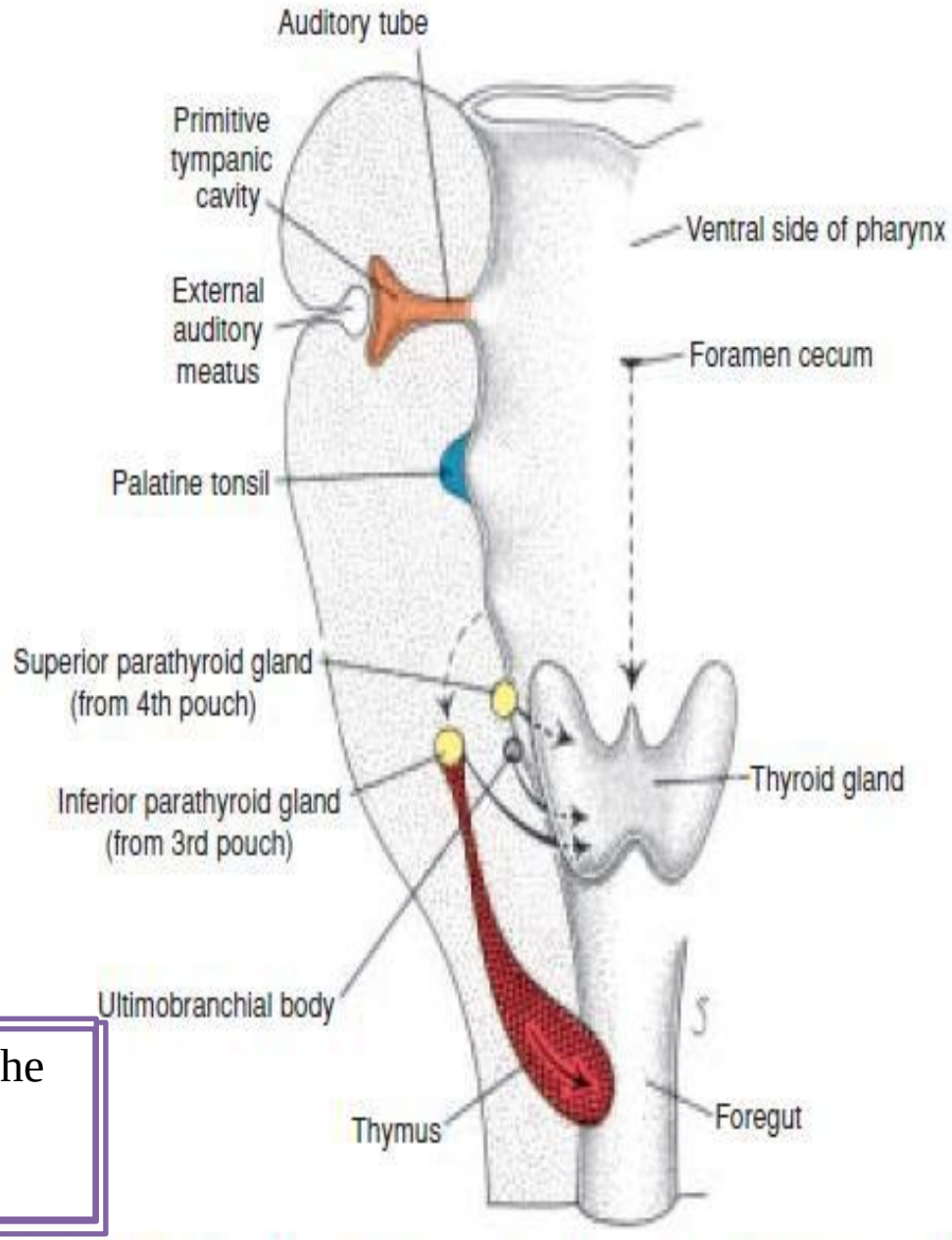

Figure 15.11 Migration of the thymus, parathyroid glands, and ultimobranchial body. The thyroid gland originates in the midline at the level of the foramen cecum and descends to the level of the first tracheal rings.

THIRD PHARYNGEAL POUCH

In the fifth week, epithelium
of the dorsal wing
of the third pouch differentiates into
INFERIOR PARATHYROID GLAND
while
the ***ventral wing***
forms
THE THYMUS
Both gland primordia lose their connection with the pharyngeal wall, and the thymus then migrates in a caudal and a medial direction, pulling the **inferior parathyroid with it**

- Growth and development of the thymus continue until puberty
- In the young child, the thymus occupies considerable space in the thorax and lies behind the sternum and anterior to the pericardium and great vessels
- In older it is atrophied and replaced by fatty tissue

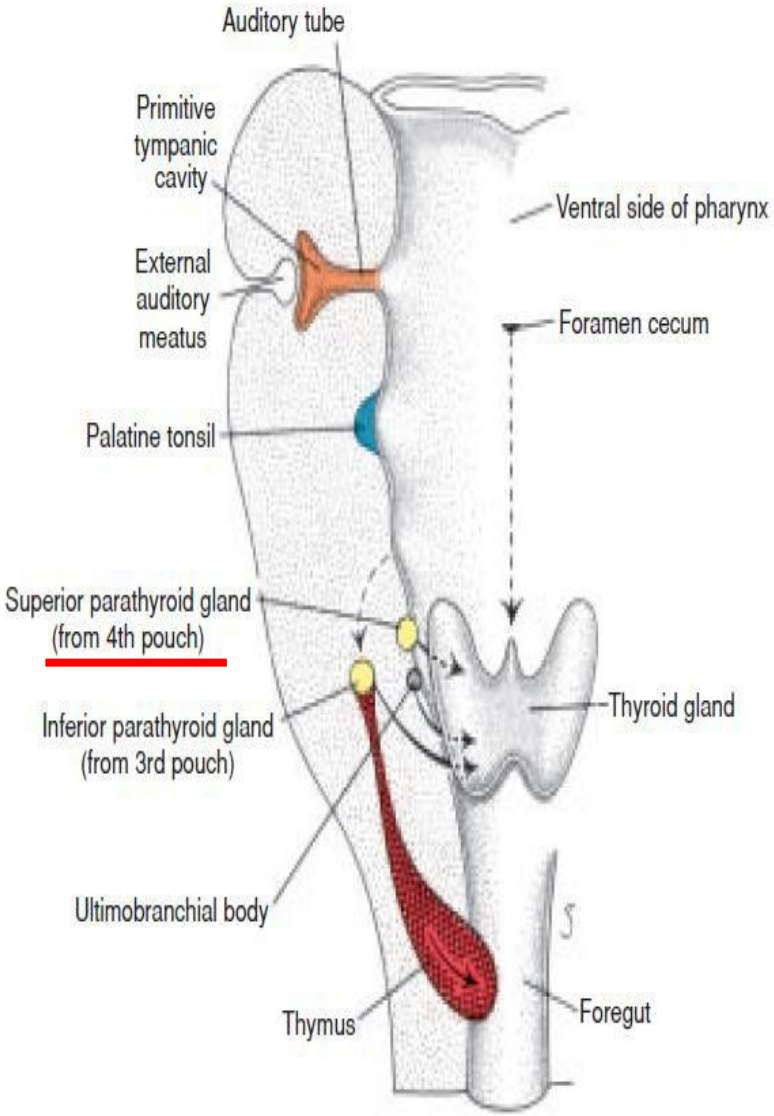

Figure 15.11 Migration of the thymus, parathyroid glands, and ultimobranchial body. The thyroid gland originates in the midline at the level of the foramen cecum and descends to the level of the first tracheal rings.

FOURTH PHARYNGEAL POUCH

Epithelium **of *the dorsal wing* of the fourth pharyngeal pouch forms**

THE SUPERIOR PARATHYROID GLAND

When the parathyroid gland loses contact with the wall of the pharynx, it attaches itself to the dorsal surface of the caudally migrating *thyroid* as the superior parathyroid gland

FIFTH PHARYNGEAL POUCH

the last to develop, is usually considered to be a part of the fourth pouch.
It gives rise to the **ultimobranchial body which is** later incorporated into the thyroid gland. Cells of the ultimobranchial body give rise to the **parafollicular, or C, cells of the thyroid gland. These cells secrete calcitonin, a hormone involved in regulation of the calcium level in the blood.**

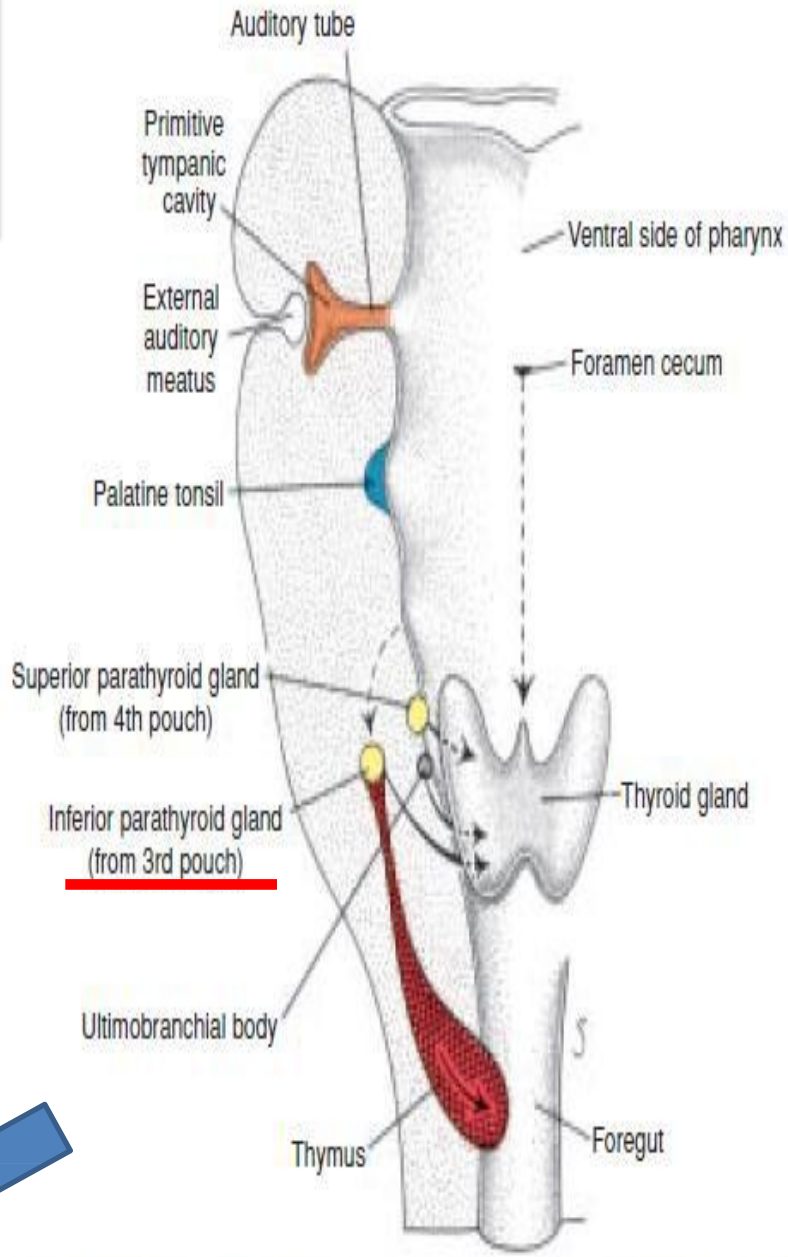

Figure 15.11 Migration of the thymus, parathyroid glands, and ultimobranchial body. The thyroid gland originates in the midline at the level of the foramen cecum and descends to the level of the first tracheal rings.

-3PHARYNGEAL CLEFTS

-3Pharyngeal Clefts

The 5-week embryo is characterized by the presence of four pharyngeal clefts of which only one contributes to the definitive structure of the embryo

- The dorsal part of the first cleft penetrates the underlying mesenchyme and gives rise to the **external auditory meatus**
- The epithelial lining at the bottom of the meatus participates in formation of the **eardrum**
- Active proliferation of mesenchymal tissue in the second arch causes it to overlap the third and fourth arches. Finally, it merges with the **epicardial ridge** in the lower part of the neck and the second, third, and fourth clefts lose contact with the outside

The clefts form a cavity lined with ectodermal epithelium، the **cervical sinus**، **but with further development** this sinus disappears.

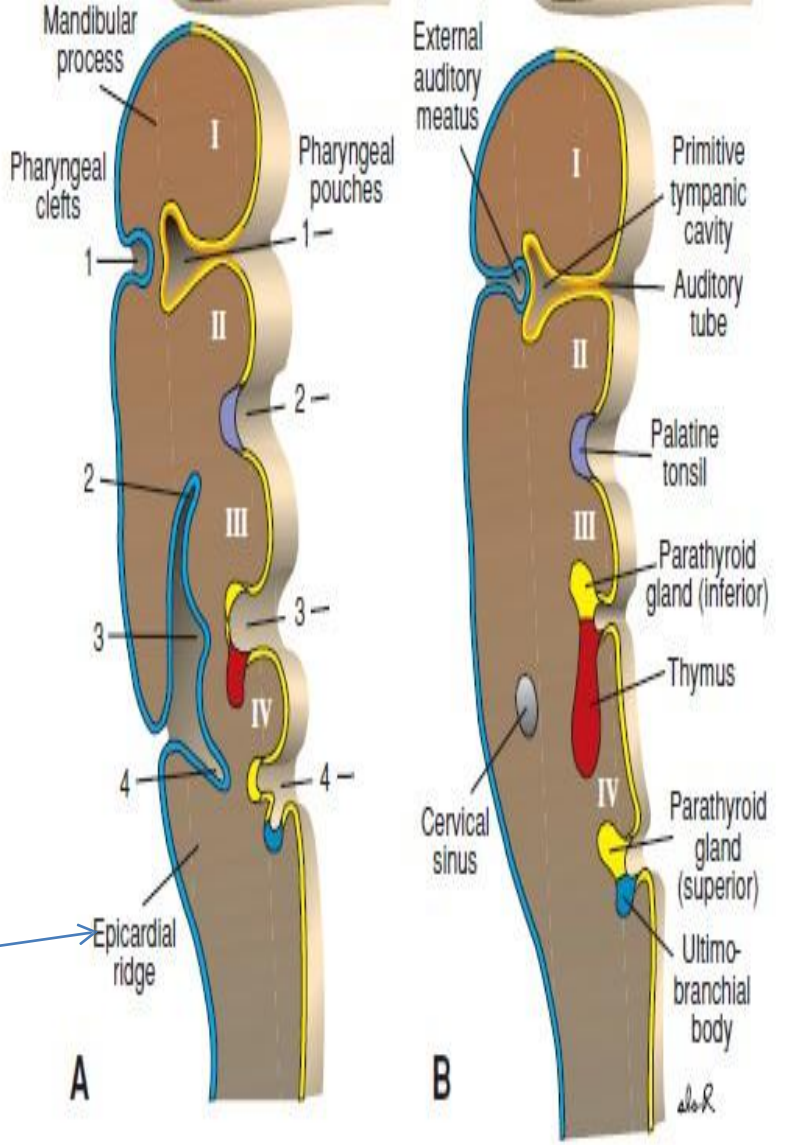

Figure 15.10 A. Development of the pharyngeal clefts and pouches. The second arch grows over the third and fourth arches, burying the second, third, and fourth pharyngeal clefts. **B.** Remnants of the second, third, and fourth pharyngeal clefts form the cervical sinus, which is normally obliterated. Note the structures formed by the various pharyngeal pouches.

DEVELOPMENT OF THE FACE

At the end of the fourth week،
facial prominences consisting primarily of neural crest-derived mesenchyme and formed mainly by the first pair of pharyngeal arches

<u>The frontonasal prominence</u>
formed by proliferation of mesenchyme ventral to the brain vesicles, **<u>constitutes the upper border of the stomodeum</u>**

<u>MAXILLARY prominences</u>
can be distinguished lateral to the stomodeum

<u>MANDIBULAR prominences</u>
can be distinguished caudal to the stomodeum

On both sides of the frontonasal prominence، local thickenings of the surface ectoderm, the
nasal placodes

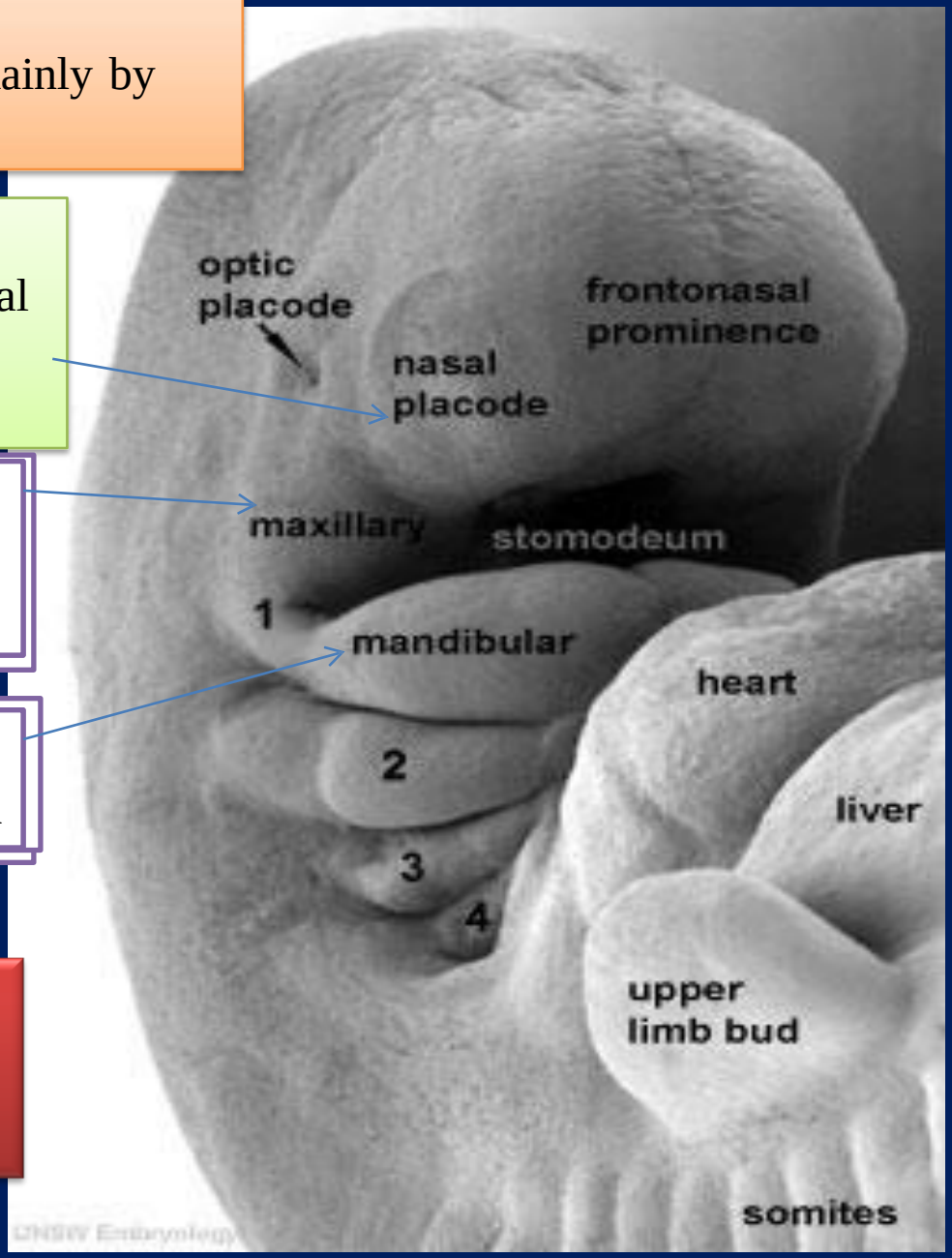

During the fifth week, the nasal placodes invaginate to form
NASAL PITS
In so doing, they create a ridge of tissue that surrounds each pit and forms
THE **NASAL PROMINENCES**

The prominences on the outer edge of the pits are:
THE MEDIAL NASAL PROMINENCES
THE LATERAL NASAL PROMINENCES

During the following 2weeks،
the **maxillary prominences** continue to increase in size
Simultaneously, they ***grow medially,***
compressing the medialnasal prominences toward the midline

Subsequently the cleft between the medial nasal prominence
and the maxillary prominence is lost،
and the two fuse

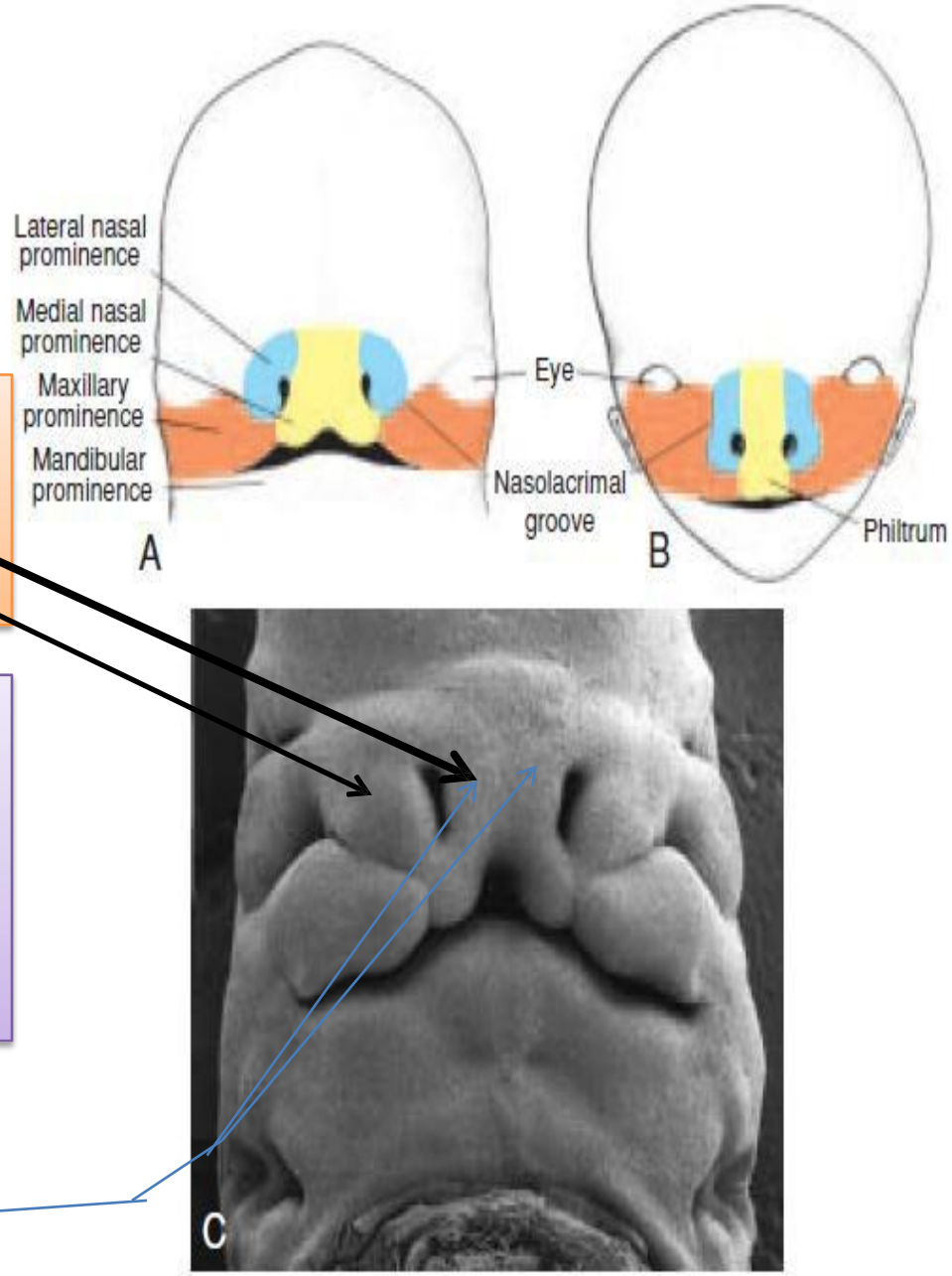

Figure 15.23 Frontal aspect of the face. **A.** 7-week embryo. Maxillary prominences have fused with the medial nasal prominences. **B.** 10-week embryo. **C.** Scanning electron micrograph of a human embryo at a stage similar to that of **A.**

Therefore, the upper lip is formed by
<u>THE TWO MEDIAL NASAL</u>
prominences
And
THE TWO MAXILLARY PROMINENCES

The lateral nasal prominences do not participate in formation of the upper lip

The lower lip and jaw
form from
the mandibular prominences
that merge across
the midline

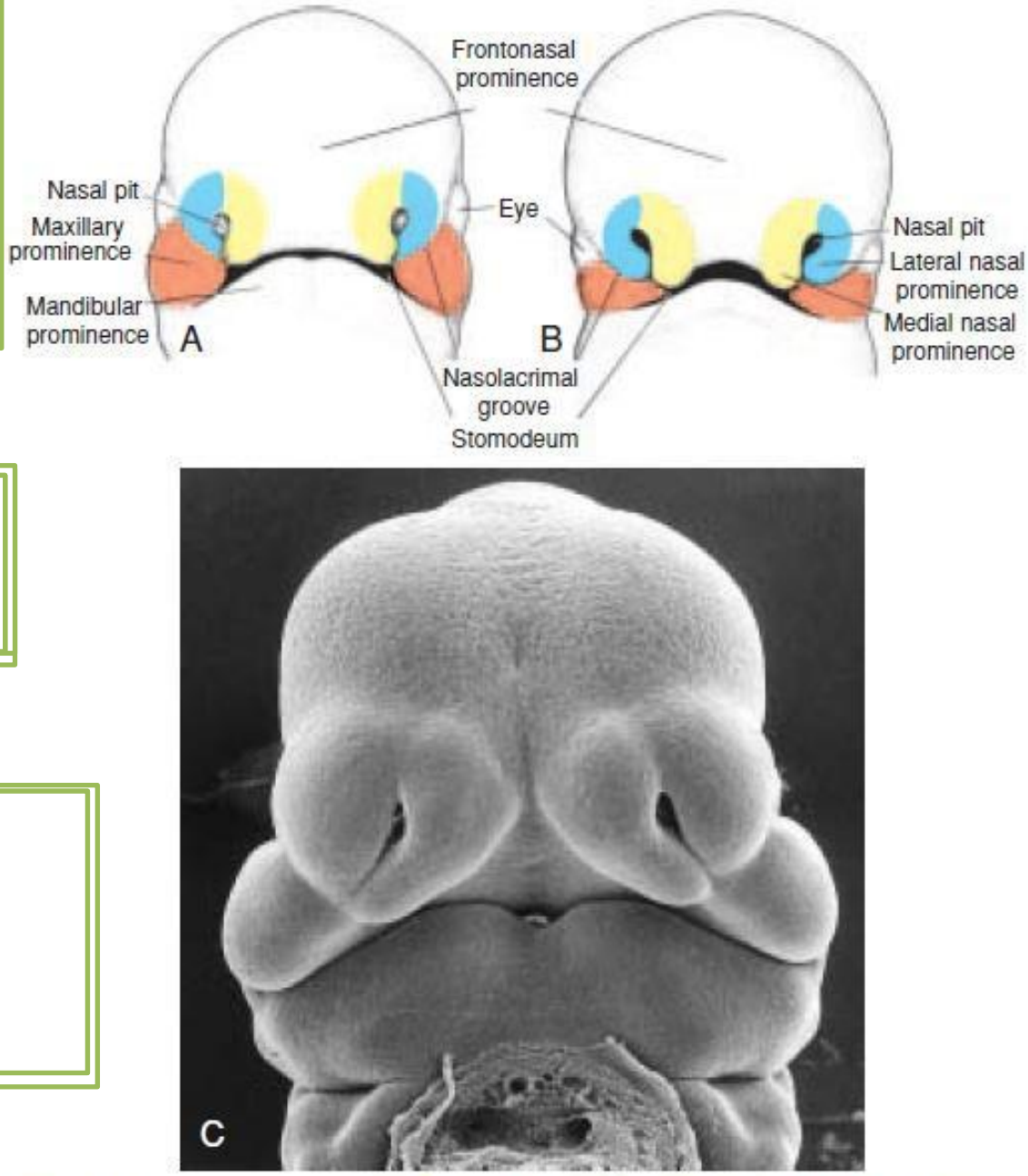

Figure 15.22 Frontal aspect of the face. **A.** 5-week embryo. **B.** 6-week embryo. The nasal prominences are gradually separated from the maxillary prominence by deep furrows. **C.** Scanning electron micrograph of a mouse embryo at a stage similar to that of **B.**

As a result of medial growth of the maxillary prominences
And the two medial nasal prominences merge
not only at the surface but also at a deeper level
The structure formed by the two merged prominences is
the **INTERMAXILLARY SEGMENT**

It is composed of:

(a) a labial component, which forms the philtrum of the upper lip

(b) an ***upper jaw component, which carries*** the four incisor teeth

(c) a ***palatal component, which forms the triangular*** primary palate

The intermaxillary segment is continuous
with the rostral portion of the
nasal septum،
which is formed by the frontal prominence

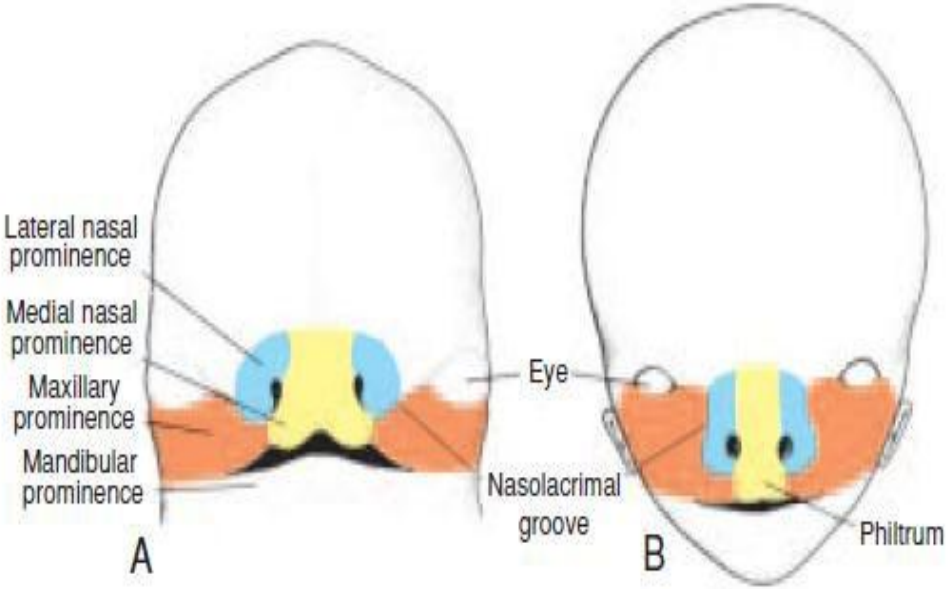

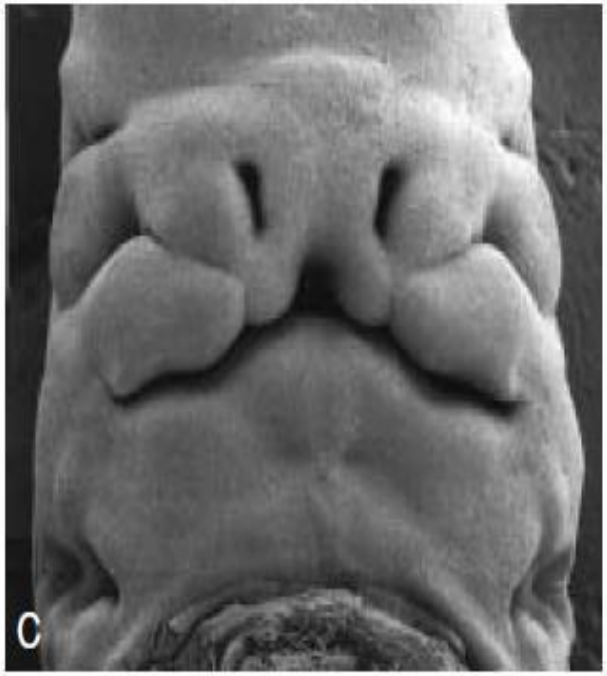

Figure 15.23 Frontal aspect of the face. **A.** 7-week embryo. Maxillary prominences have fused with the medial nasal prominences. **B.** 10-week embryo. **C.** Scanning electron micrograph of a human embryo at a stage similar to that of **A.**

Secondary Palate

Although the primary palate is derived from **the intermaxillary segment** the main part of the definitive palate is formed by two shelflike outgrowths from the maxillary prominences

Anteriorly, the shelves fuse with the triangular primary palate, and the **incisive foramen is the midline landmark between the primary and secondary** palates

At the same time as the palatine shelves fuse, the nasal

septum grows down and joins with the cephalic aspect of the newly formed palate

These outgrowths, the **palatine shelves, appear in the sixth week of development and are directed obliquely** downward on each side of the tongue

In the seventh week، however، the palatine shelves ascend to attain a horizontal position above the tongue and fuse, forming the **secondary palate**

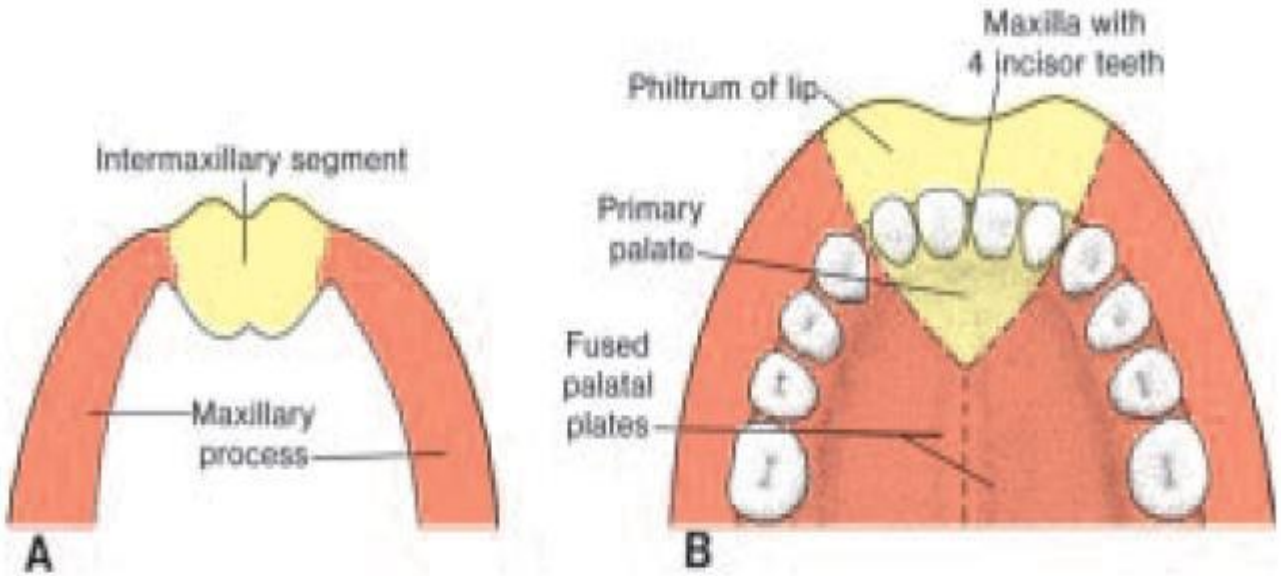

Figure 15.24 A. Intermaxillary segment and maxillary processes. **B.** The intermaxillary segment giving rise to the philtrum of the upper lip, the median part of the maxillary bone with its four incisor teeth, and the triangular primary palate.

Facial Clefts

Cleft lip and cleft palate are common defects that result in abnormal facial appearance and defective speech

.1Cleft lip

.2Cleft palate

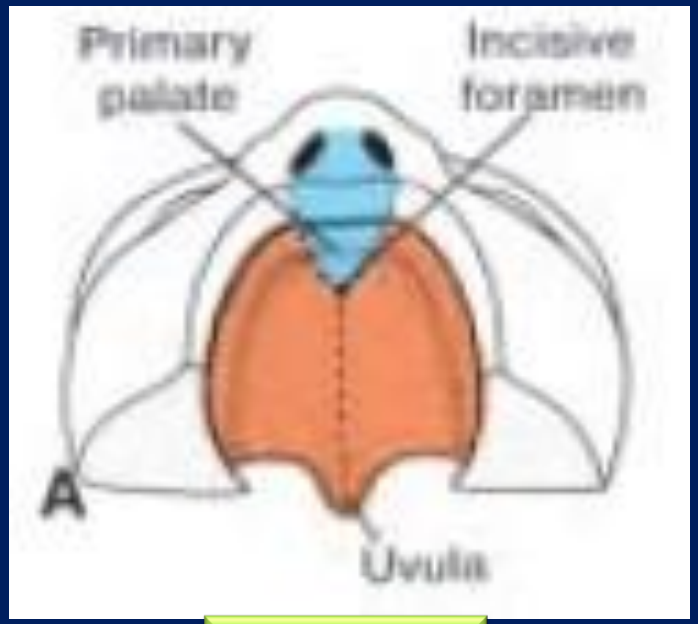

A. Normal.

Cleft lip

A. Unilateral cleft lip: results from failure of the maxillary prominence to merge with medial nasal prominence on the effected side

B. Bilateral cleft lip: results from failure of the maxillary prominences to merge with medial nasal prominence on both sides

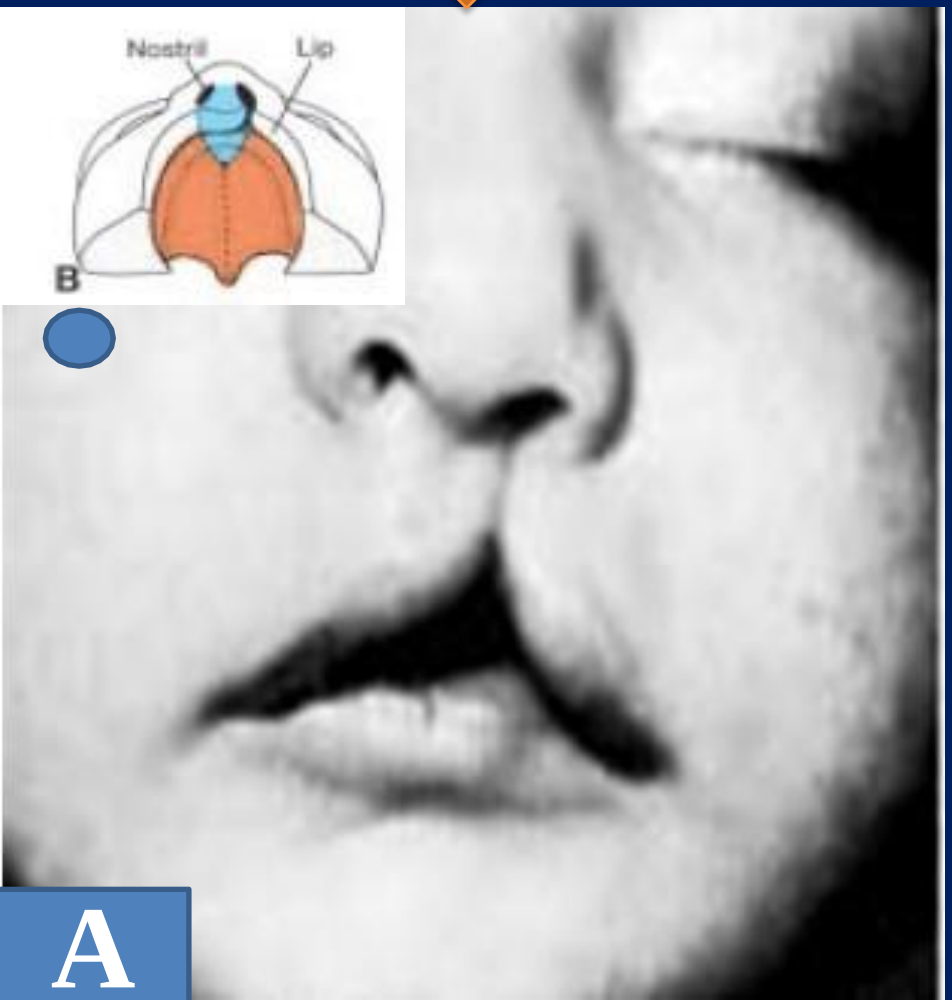

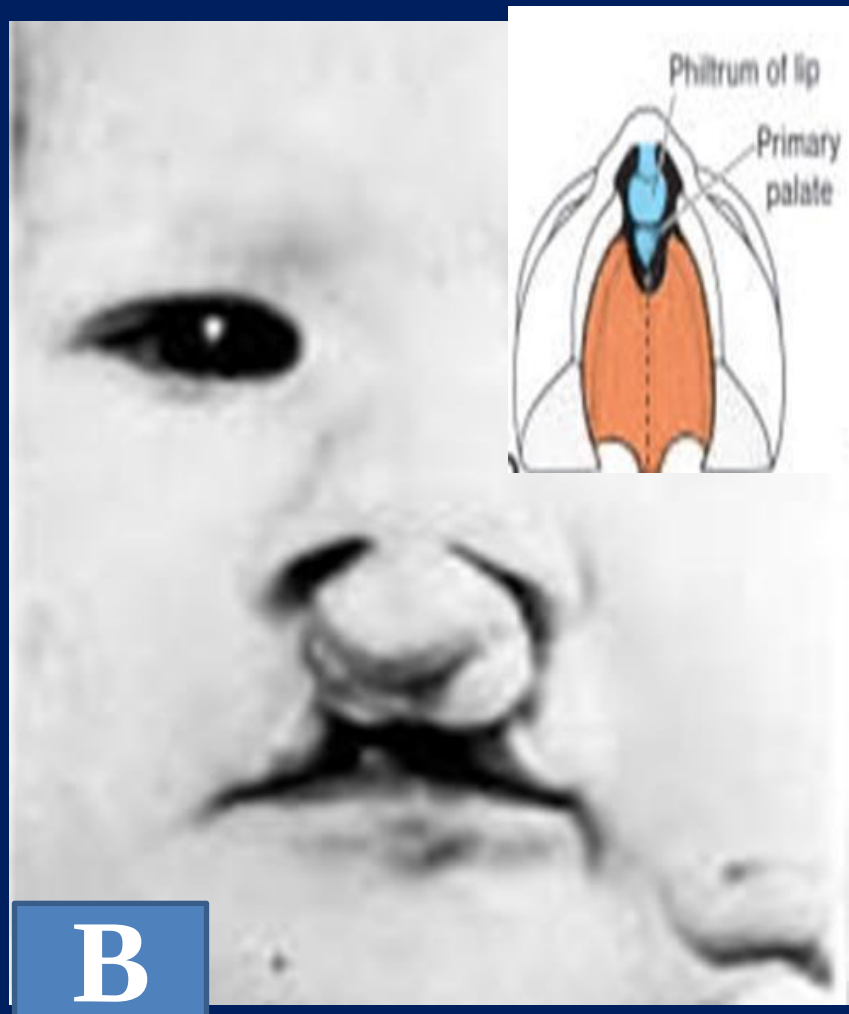

C. Median cleft lip: results from failure of the medial nasal prominences to merge and form the intermaxillary segment

D.Oblique facial cleft: failure of fusion between the maxillary prominence and the lateral nasal prominence .The nasolacrimal duct persist opened , usually associated with cleft lip on the same side

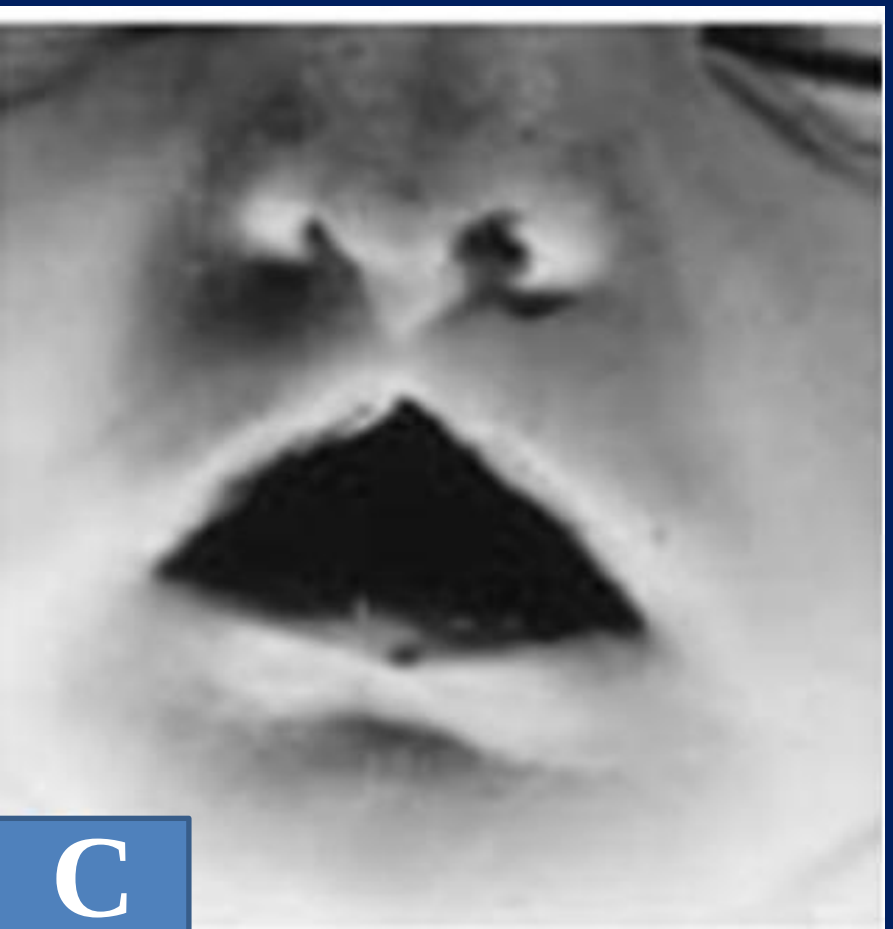

Cleft palate

The ***incisive foramen*** **is considered the dividing** landmark between the **anterior and posterior cleft deformities**

A- Cleft of the primary palate

Results from failure of the palatine shelves to fuse with the primary palate which takes place ***anterior to the incisive foramen therefore this type is anterior cleft palate***

Note that **Cleft of the primary palate is always anterior and can be unilateral and bilateral**

Primary Bilateral cleft)involving the lip and jaw(

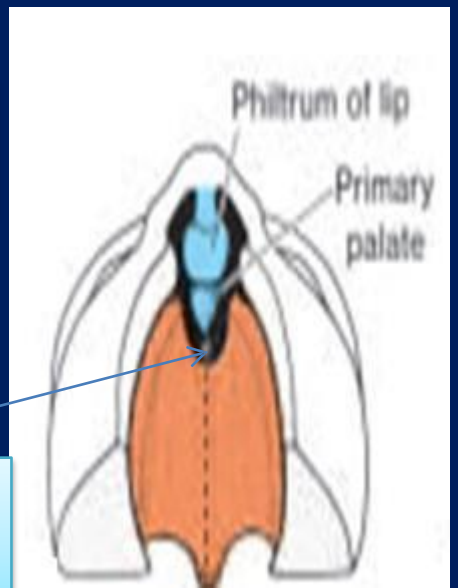

Note :It is anterior to the incisive foramen

Primary Unilateral Cleft palate (combined with unilateral cleft lip(

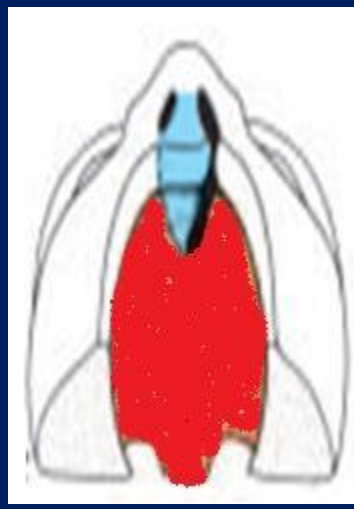

B. Cleft of the secondary palate

Results from failure of the palatine shelves to fuse with each other and with the primary palate which takes place ***posterior to the incisive foramen therefore this type is***

Posterior cleft palate

Note that **Cleft of the secondary palate is always posterior**

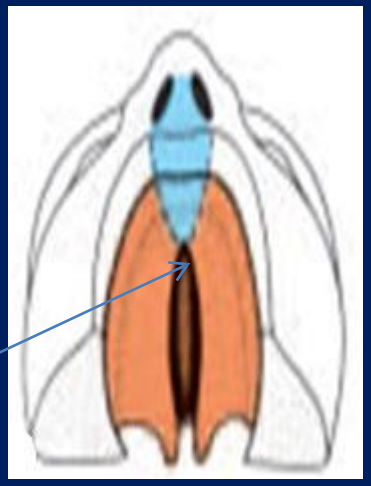

secondary cleft palate

Note it is located posterior to the ***incisive*** foramen

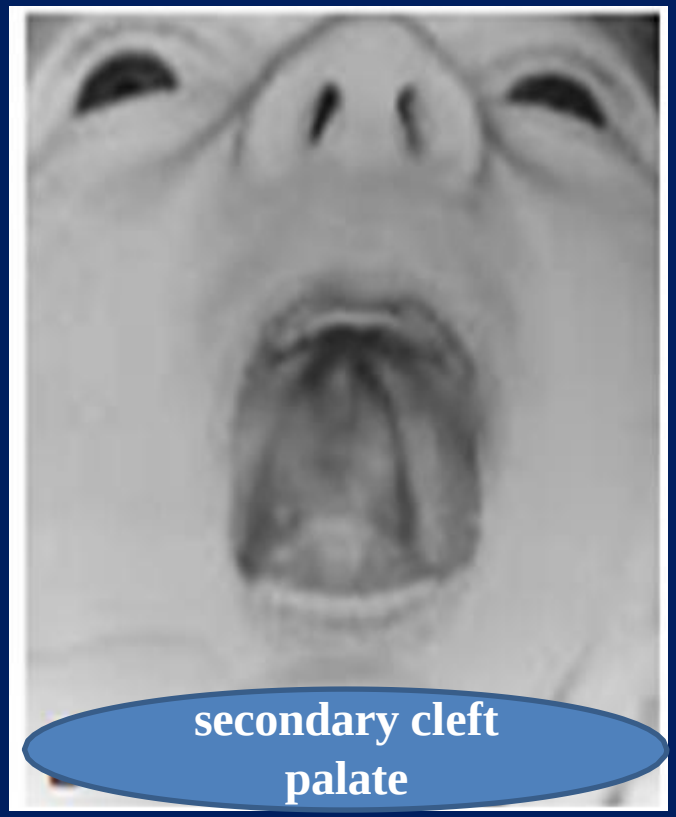

secondary cleft palate

Cleft of the primary and secondary palate

Results from failure of the palatine shelves to fuse with each other and with the primary palate which takes place ***anterior and posterior to the incisive foramen***

therefore this type is mixed anterior and posterior cleft palates

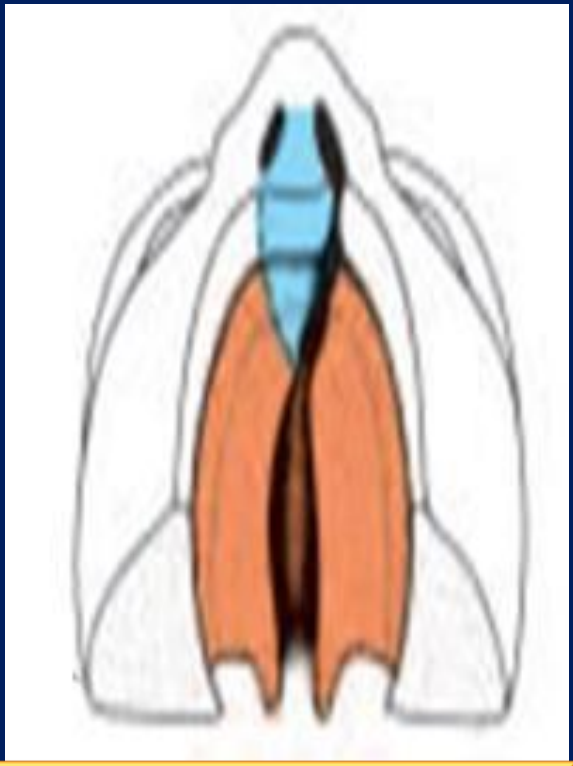

Primary and secondary Cleft palates combined with unilateral cleft lip

lateral

cervical cyst

Branchial Fistulas

Branchial fistulas occur when the second pharyngeal arch fails to grow caudally over the third and fourth arches, leaving remnants of the second, third.
and fourth clefts in contact with the surface by a narrow canal.
Such a fistula, found on the lateral aspect of the neck directly anterior to the **sternocleidomastoid muscle, usually provides drainage for a lateral cervical cyst** ***These cysts, remnants of the cervical sinus, are most often***
just below the angle of the jaw

Frequently a lateral cervical cyst is not visible at birth but becomes evident as it enlarges during childhood.

Patient with a lateral cervical cyst. These cysts are always on the ***lateral*** side of the neck in front of the sternocleidomastoid muscle. They commonly lie under the angle of the mandible and do not enlarge until later in life.

Tongue

The tongue appears in embryos of approximately 4 weeks in the form of:

- 1 **two** ***lateral lingual swellings***
- 2one medial swelling **the tuberculum impar**

These three swellings originate from the first pharyngeal arch.

A second median swelling,
the **copula, or hypobranchial eminence** is
formed by mesoderm of the second, third, and part of the fourth arch

a third median swelling, formed by the posterior part of the fourth arch.

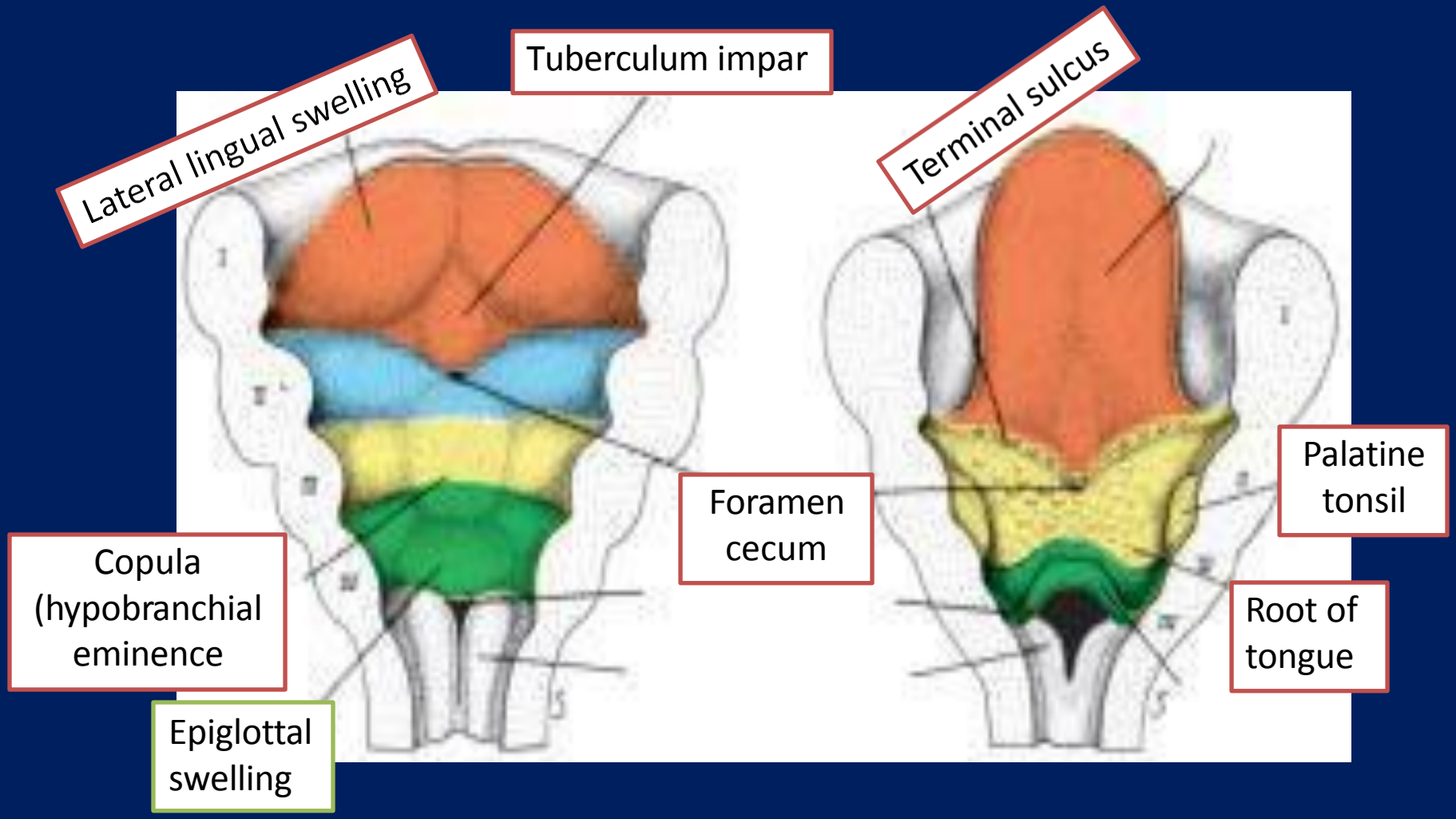
Lateral lingual swelling
Tuberculum impar
Terminal sulcus
Foramen cecum
Palatine tonsil
Copula (hypobranchial eminence
Root of tongue
Epiglottal swelling

-1 ***As the lateral lingual swellings*** increase in size, they overgrow ***the tuberculum impar and merge***, forming the **anterior two-thirds**, or body, of the tongue

Since the mucosa covering the body of the tongue originates from the first pharyngeal arch, **sensory innervation to this area is by** the **mandibular branch of the trigeminal nerve.**

The body of the tongue is separated from the posterior third by a V-shaped groove, the **terminal sulcus**

-2 **The posterior part, or root, of the tongue** originates from *the second, third, and part of the fourth pharyngeal arch*

The fact that **sensory innervation to** this part of the tongue is supplied by the **glossopharyngeal nerve indicates that** tissue of the third arch overgrows that of the second.

Some of the tongue muscles probably differentiate in situ, but most are derived from myoblasts originating in **occipital somites.**
Thus, tongue musculature is innervated by the **hypoglossal nerve.**

Tongue-Tie

In **ankyloglossia (tongue-tie) the tongue is not freed from the floor of the** mouth. Normally, extensive cell degeneration occurs, and the frenulum is the only tissue that anchors the tongue to the floor of the mouth. In the most common form of ankyloglossia, the frenulum extends to the tip of the tongue.