

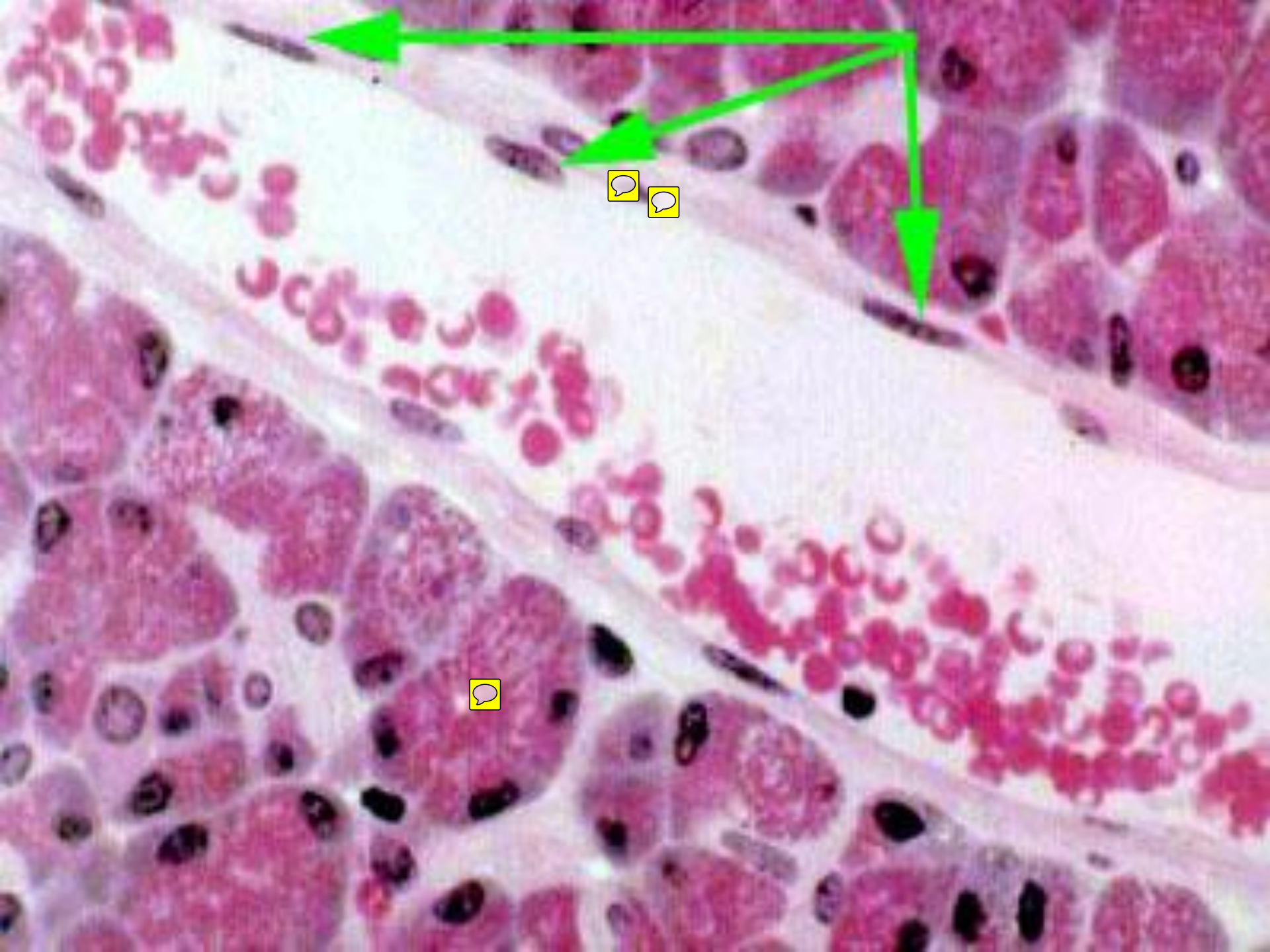
# Sections for practical exam

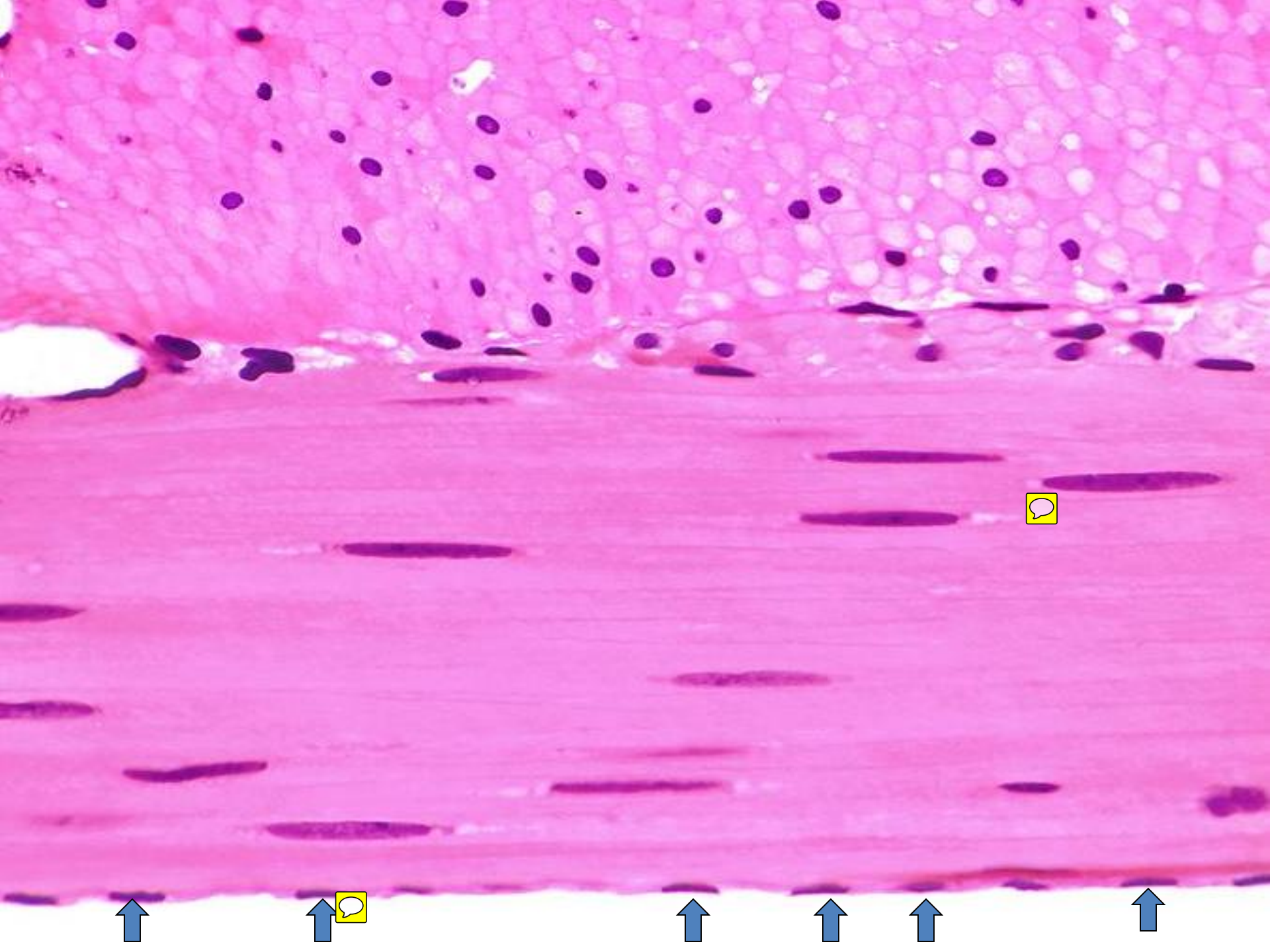
Introduction to Histology Course

First year Medical Students

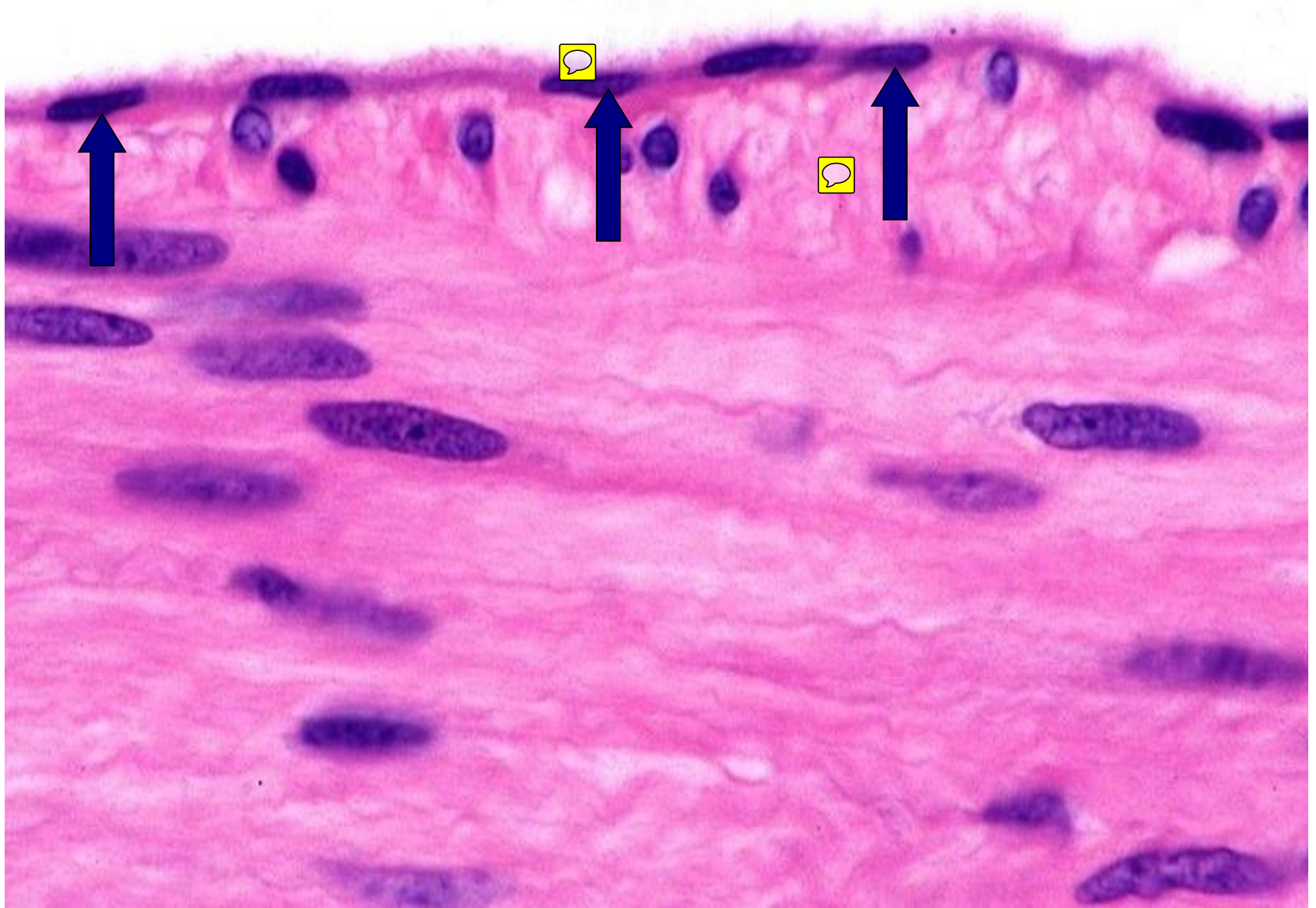
2015/2016

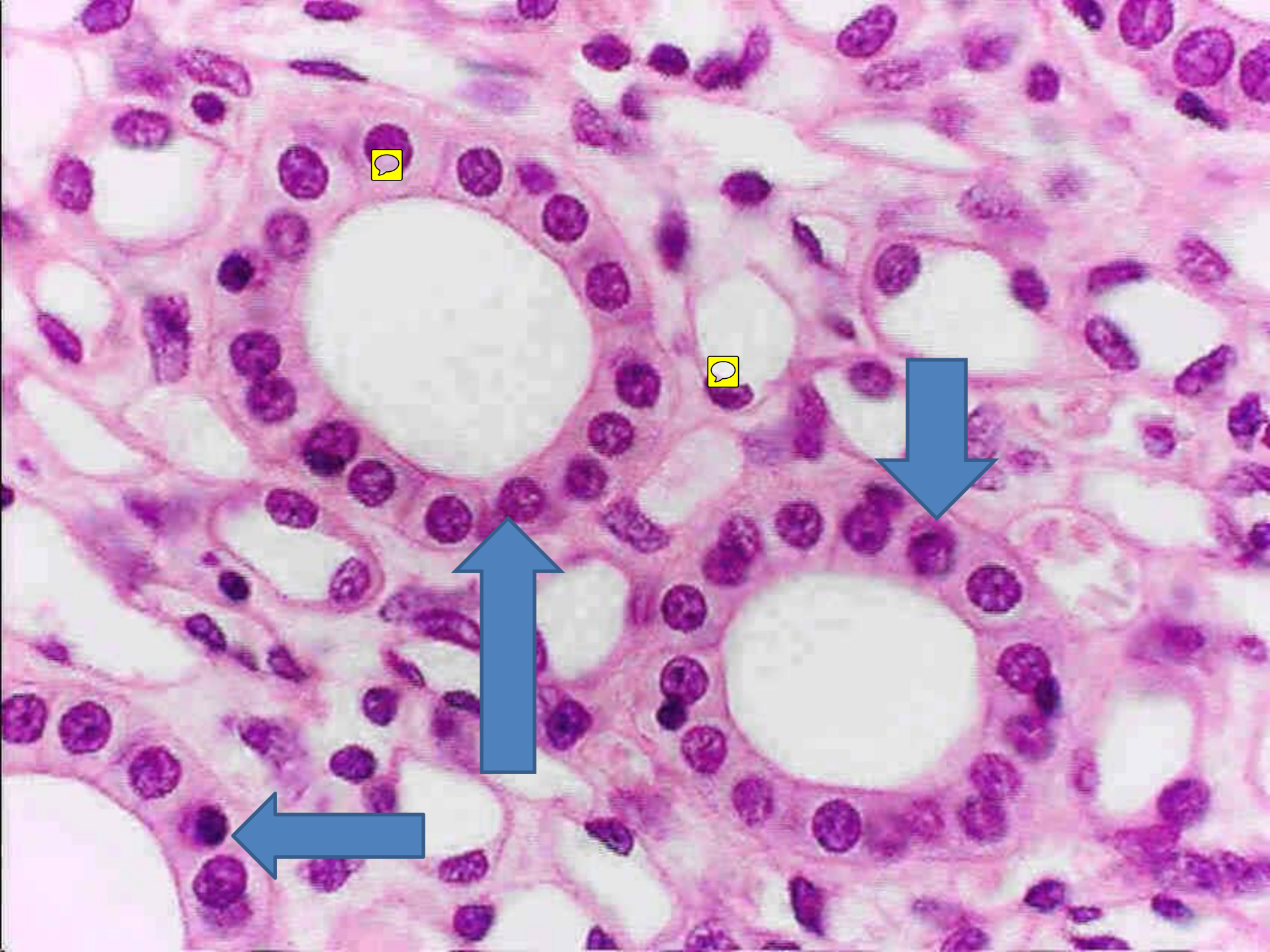
Epithelium



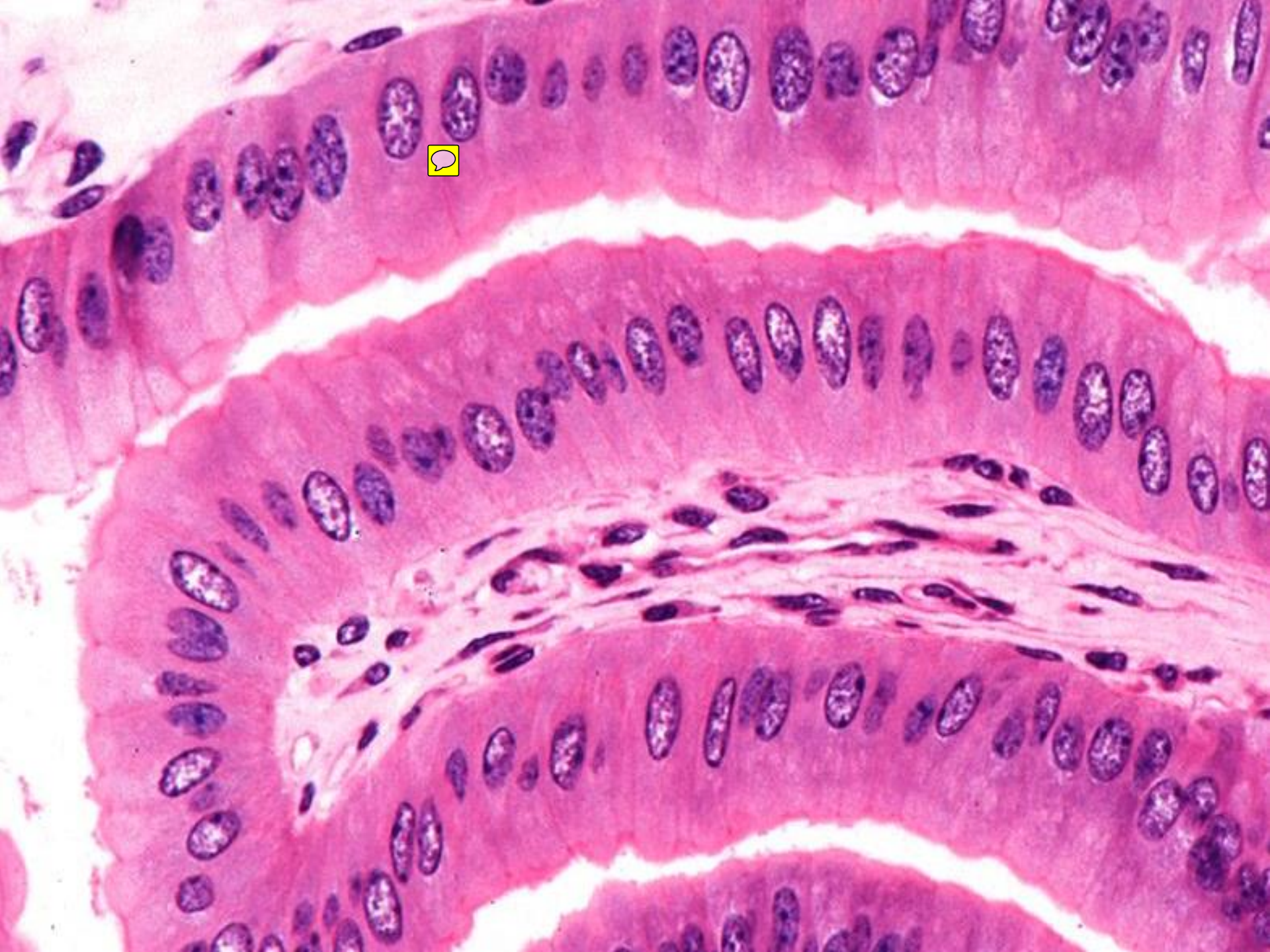



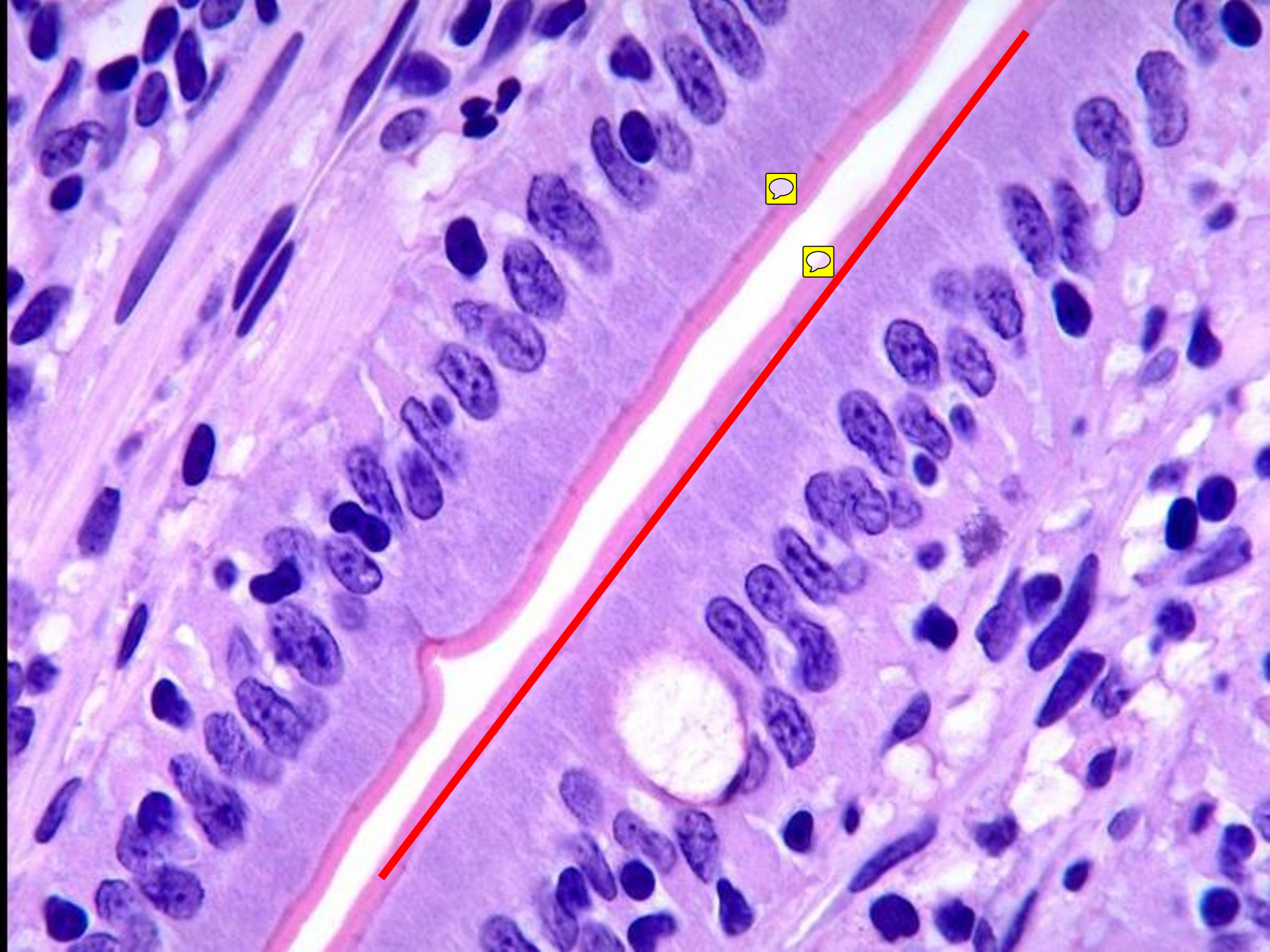




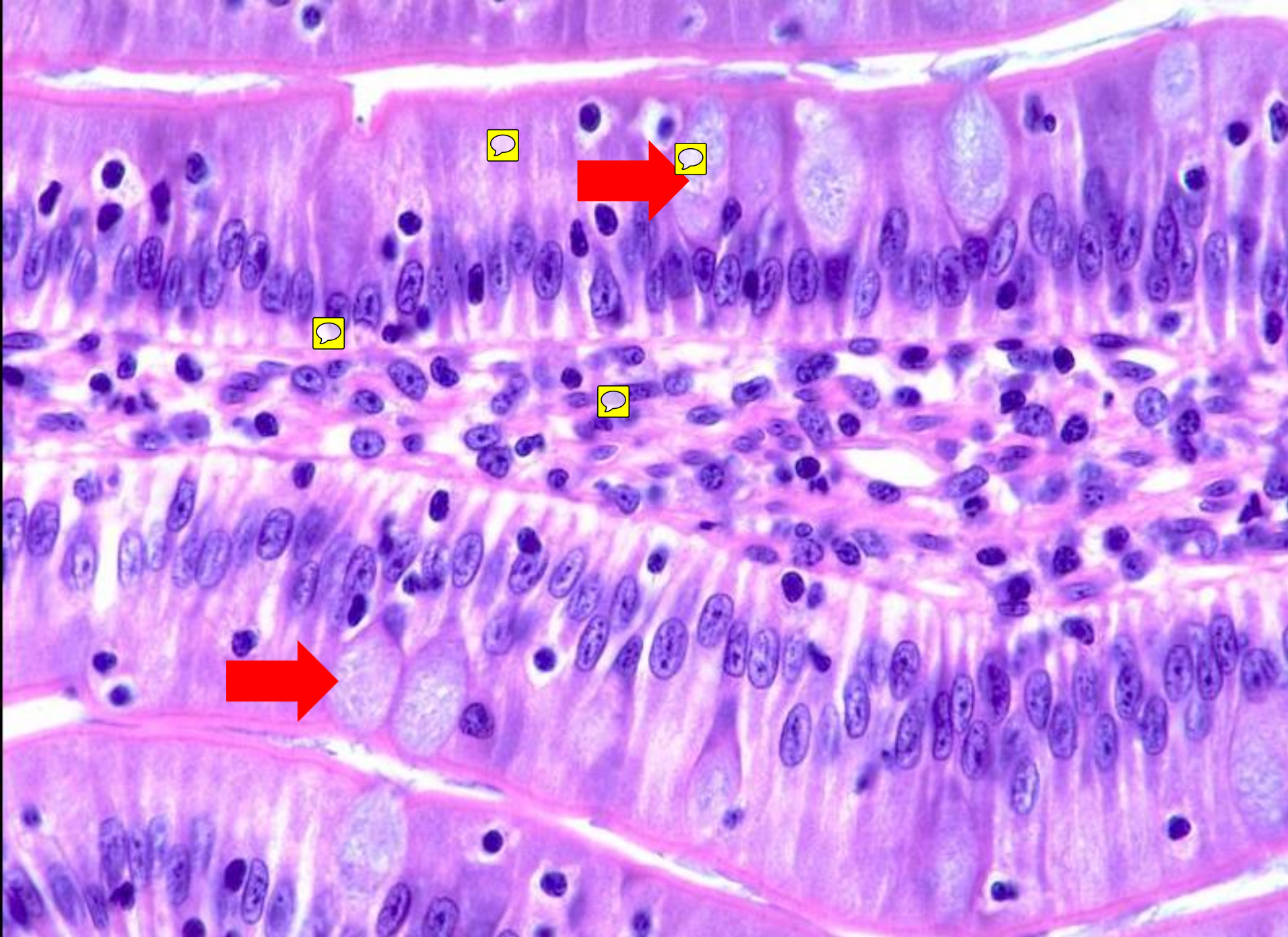





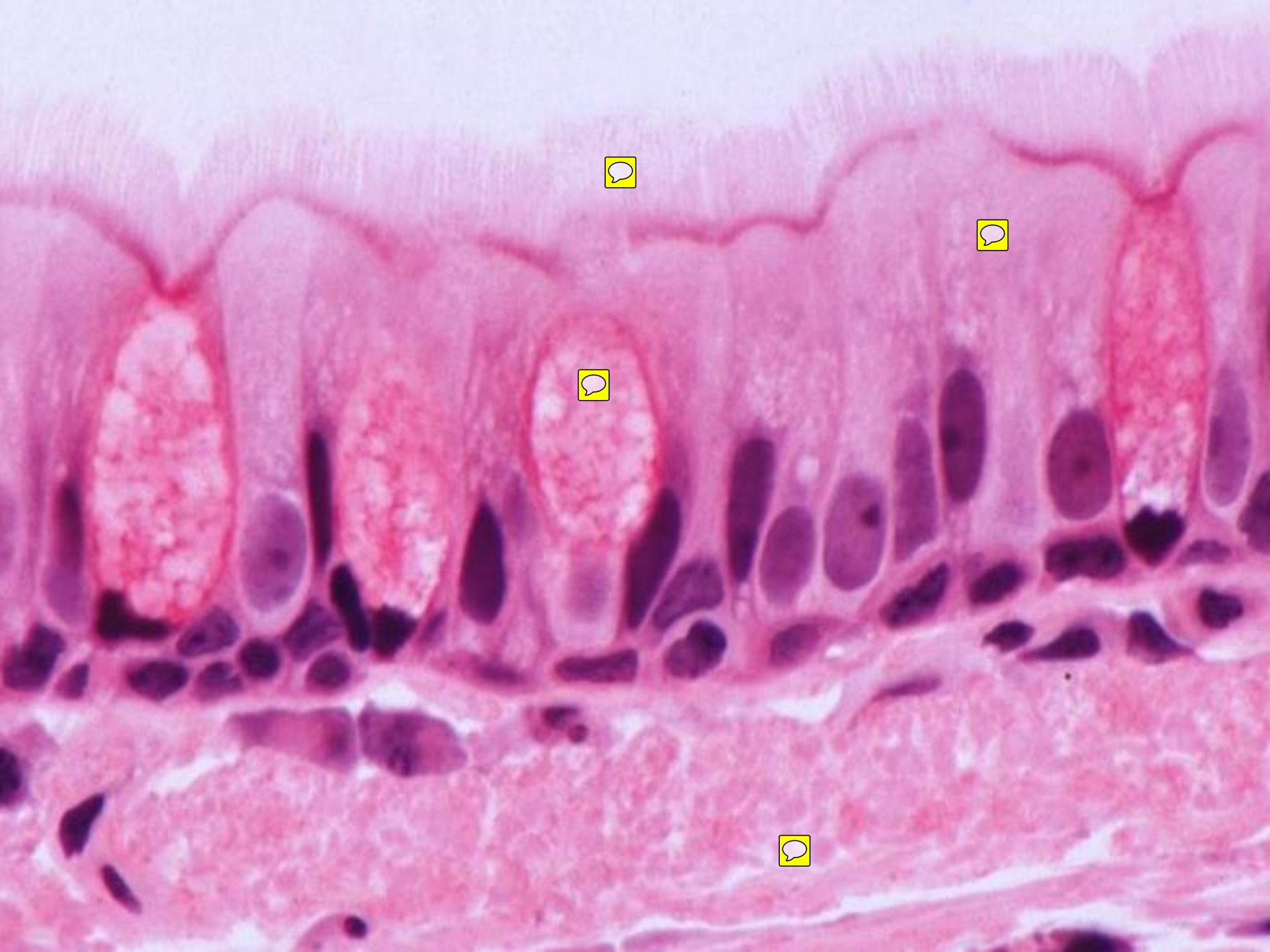


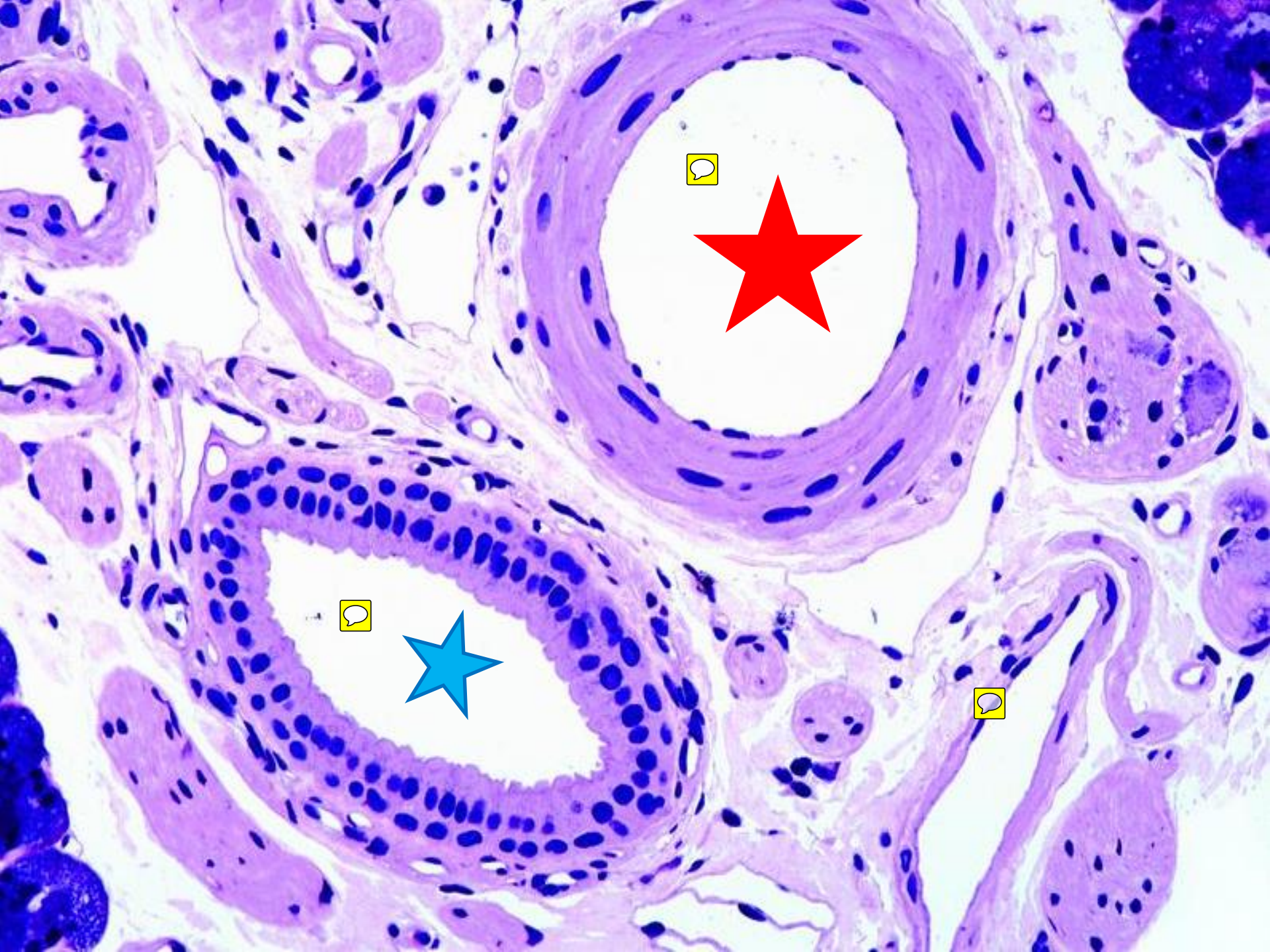




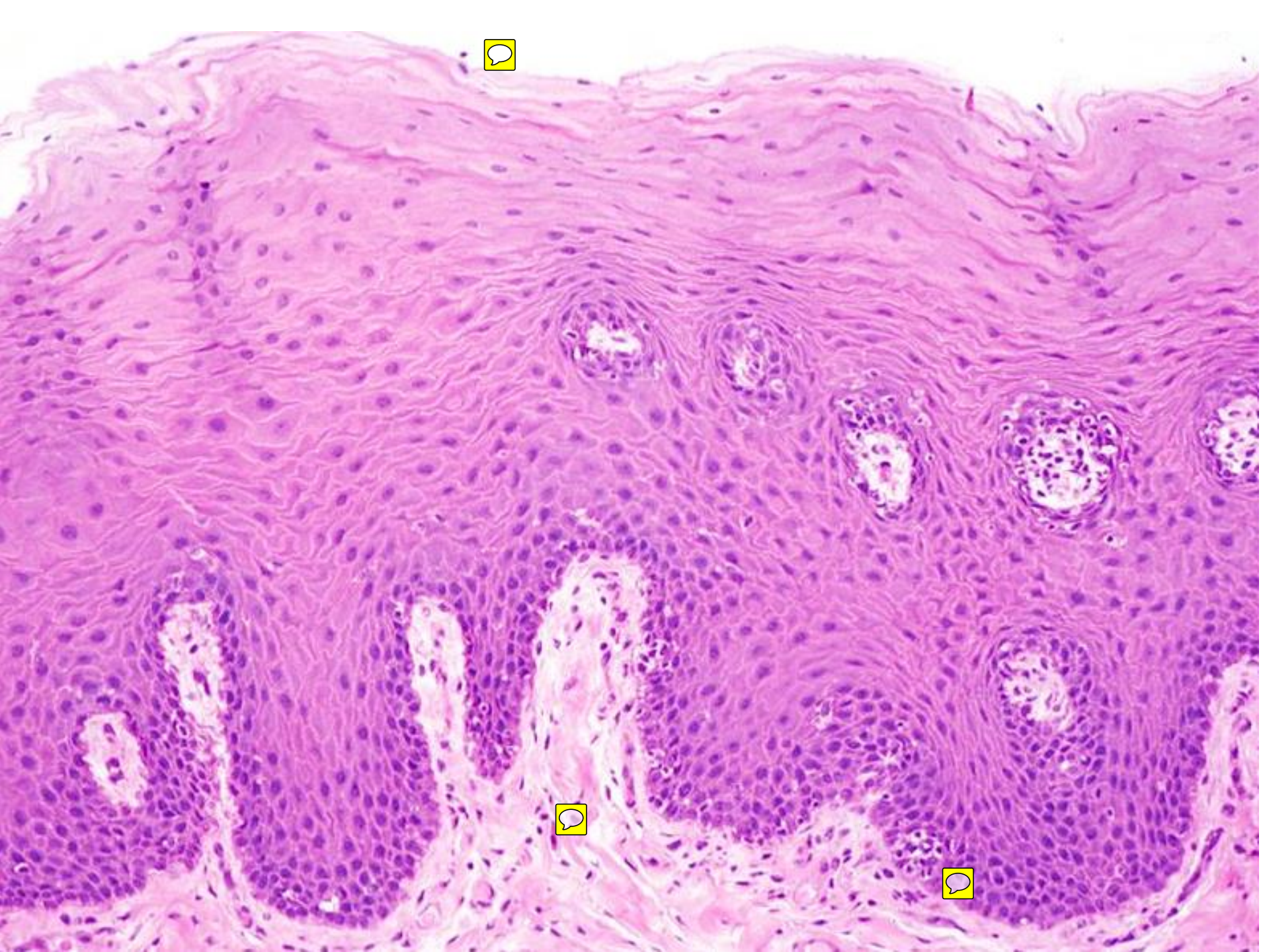




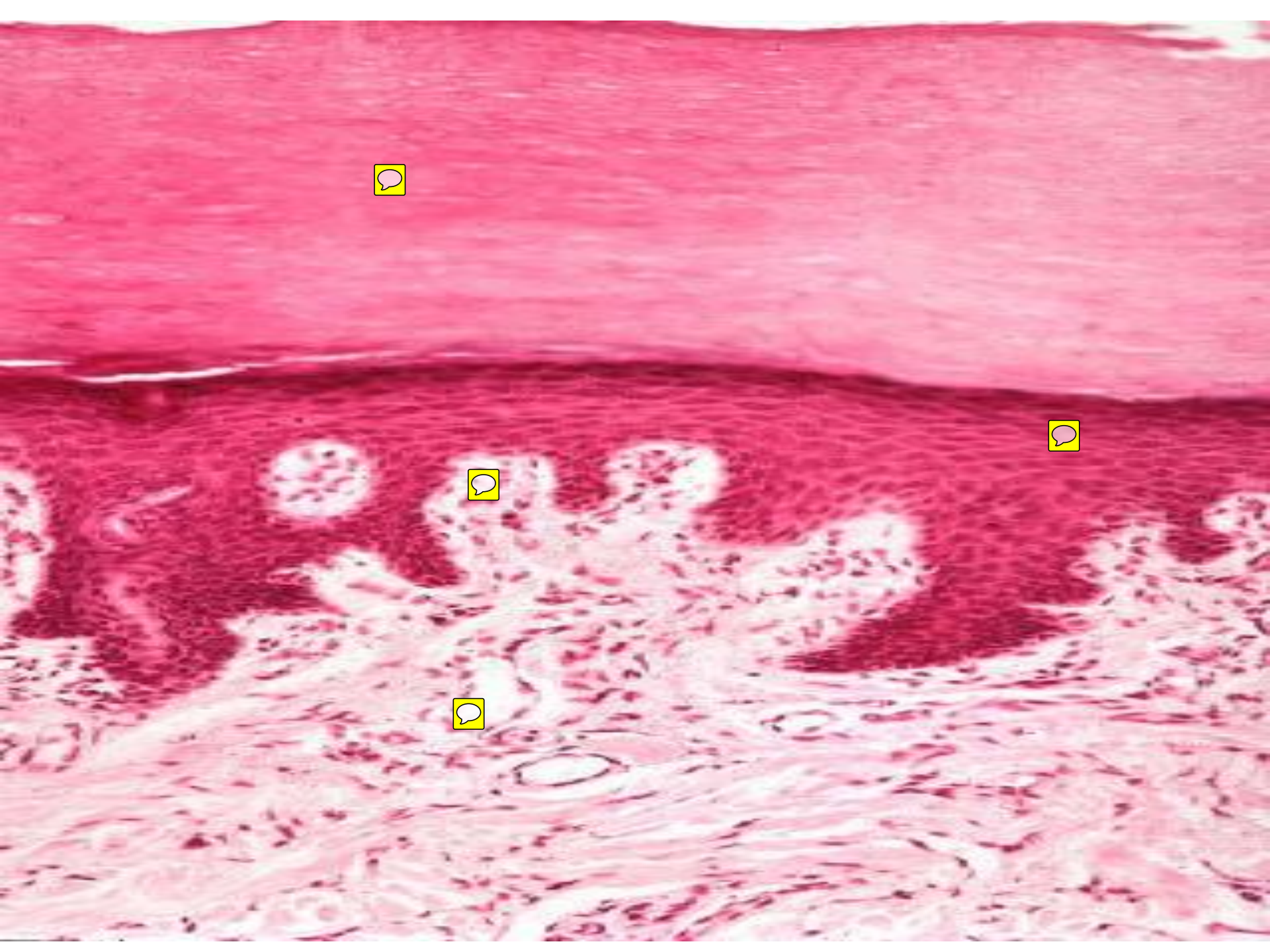


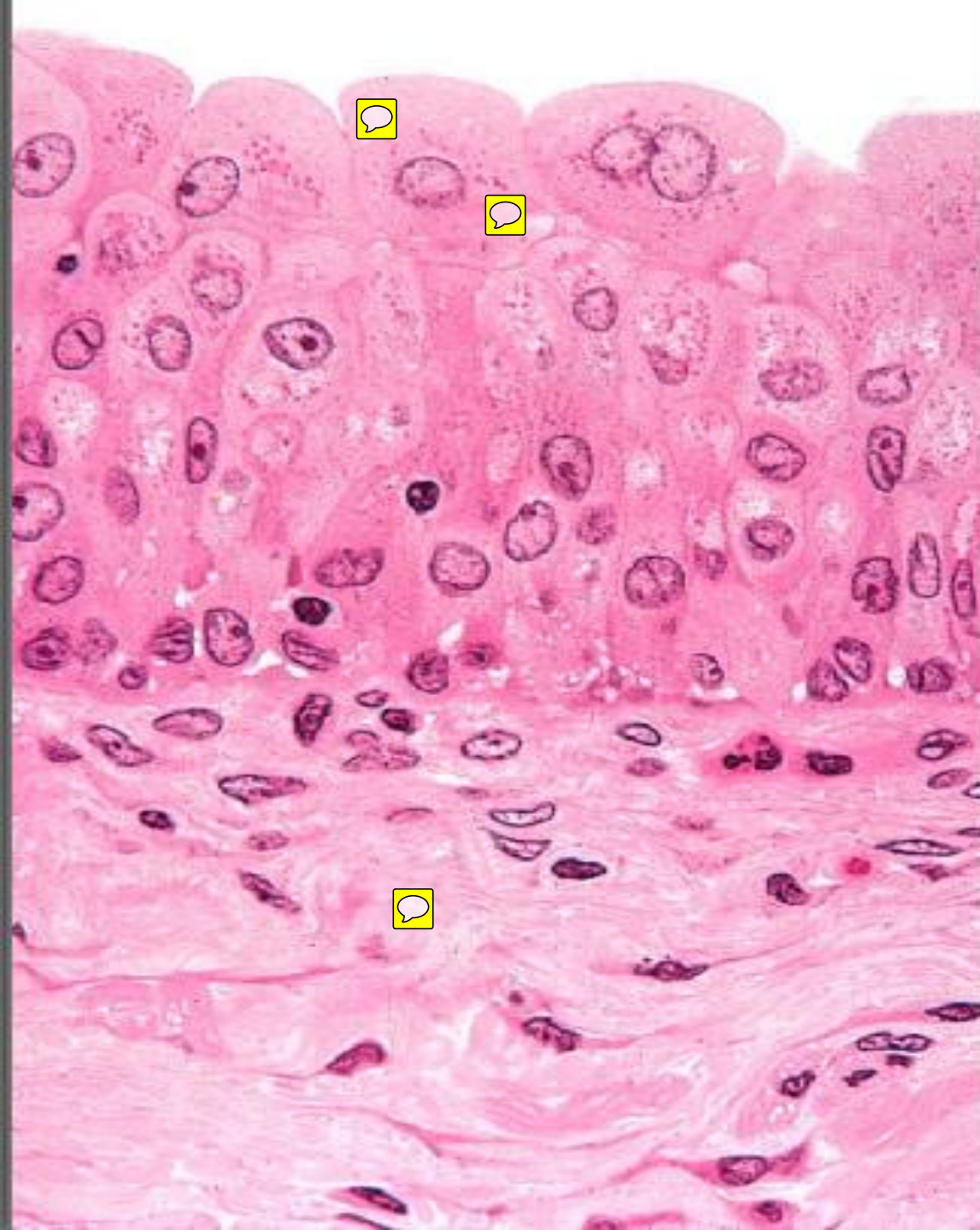






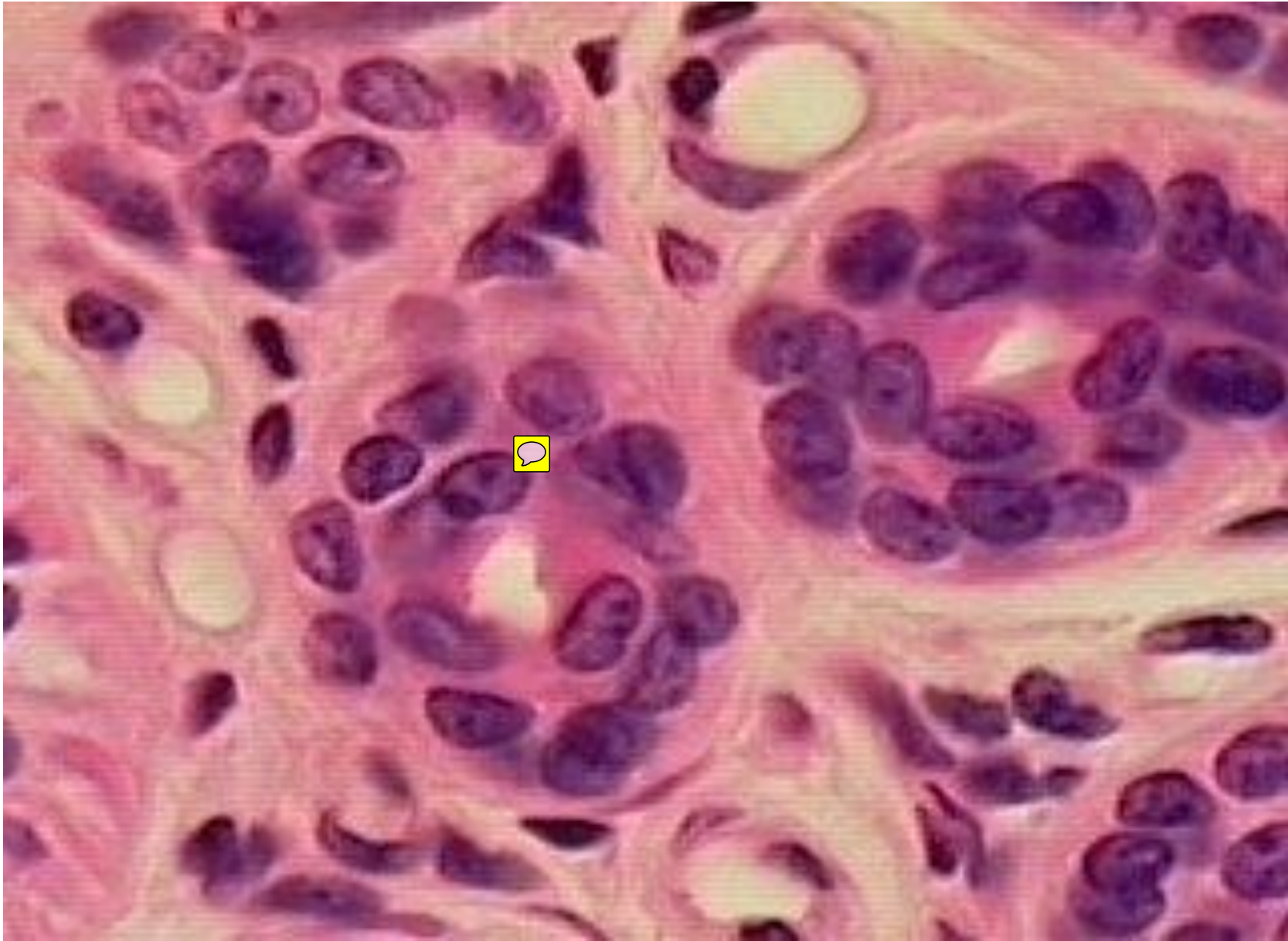

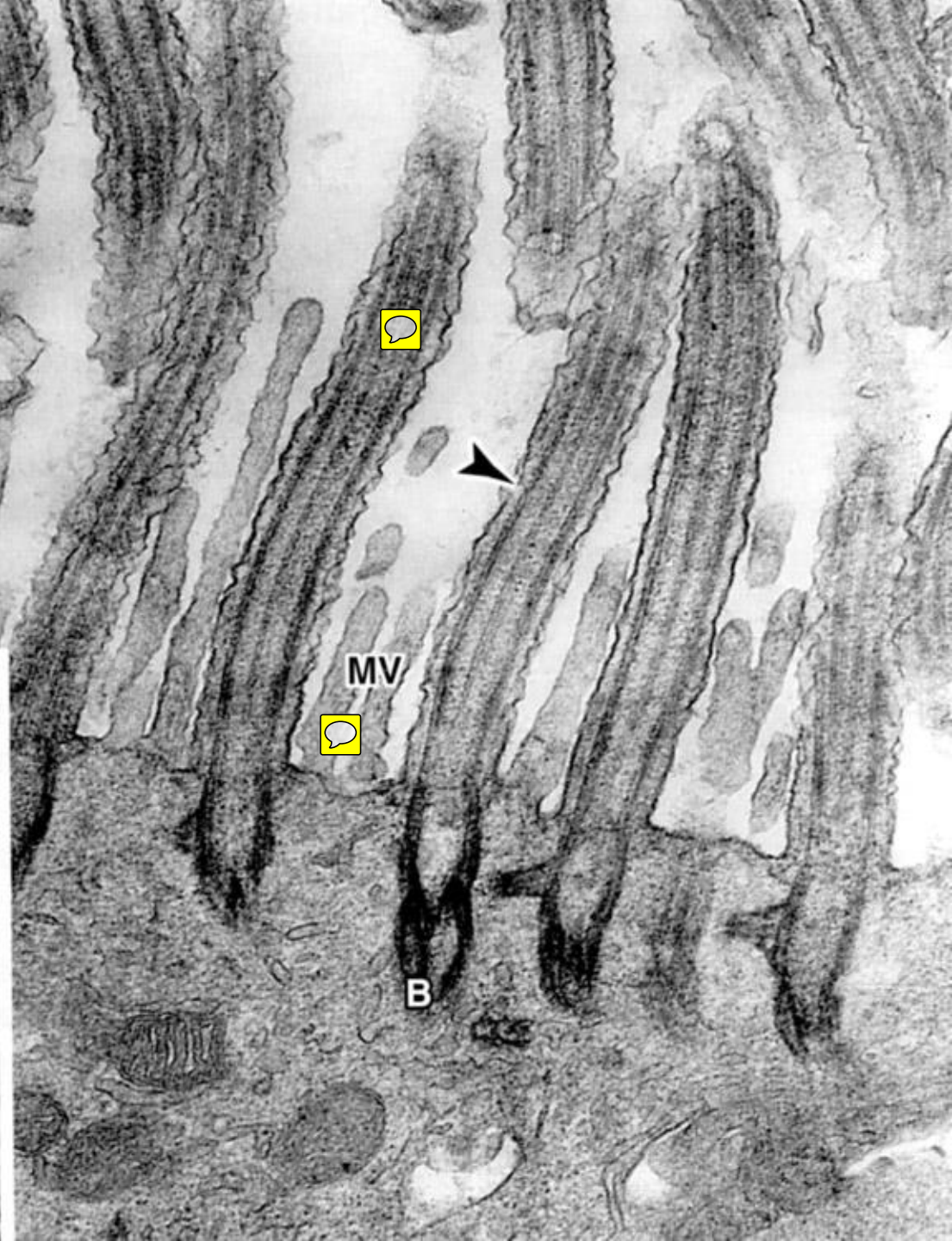
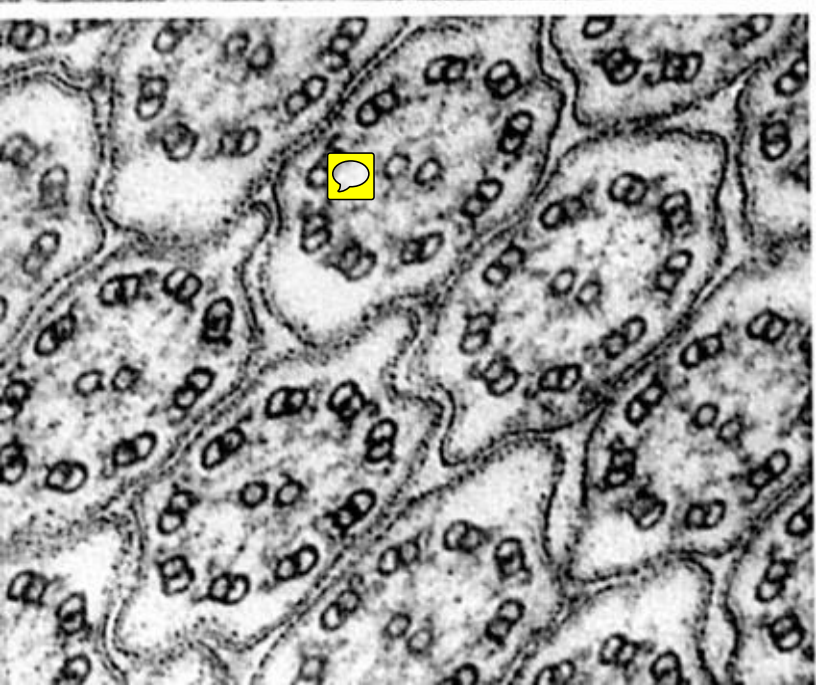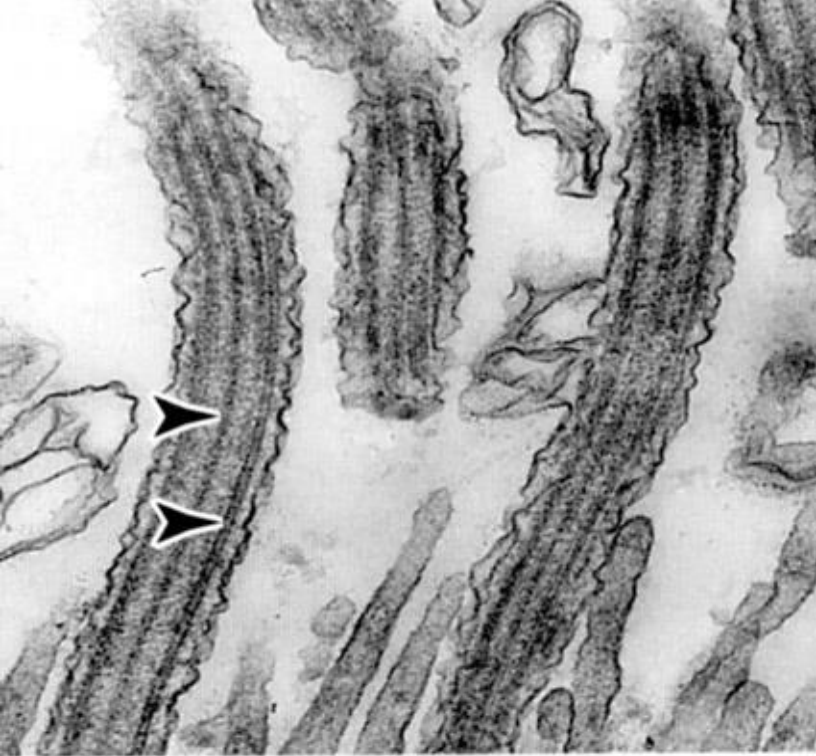




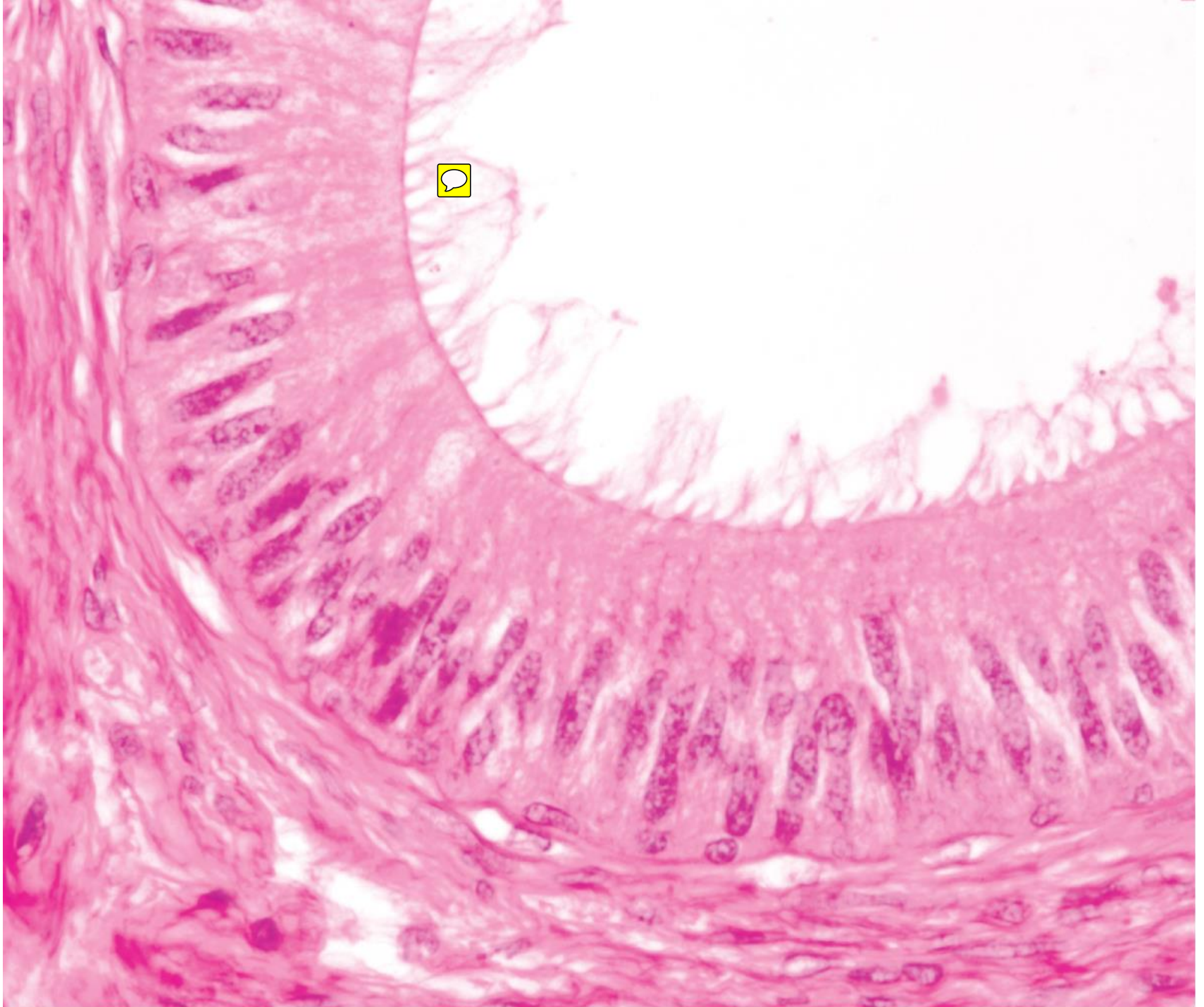












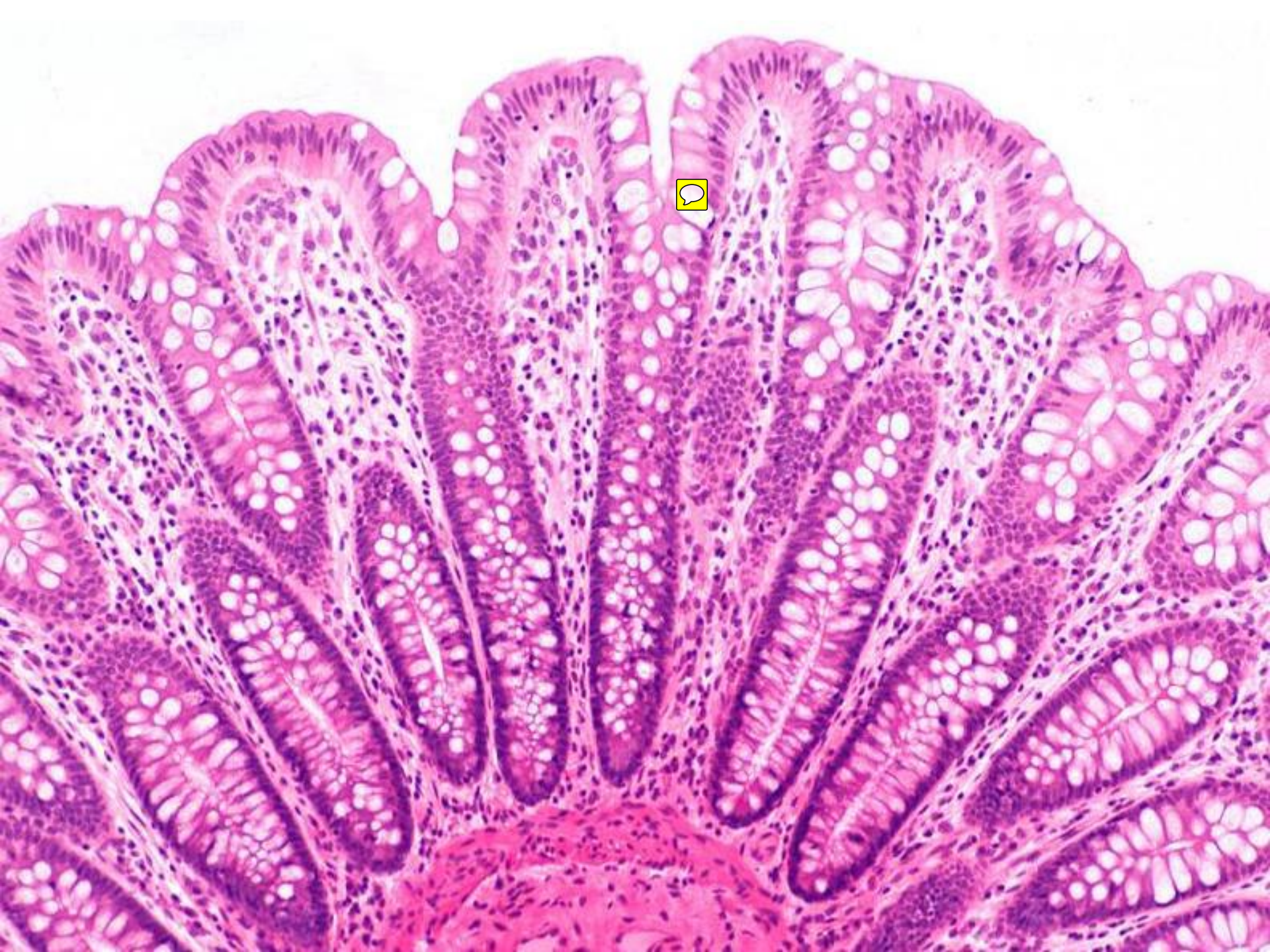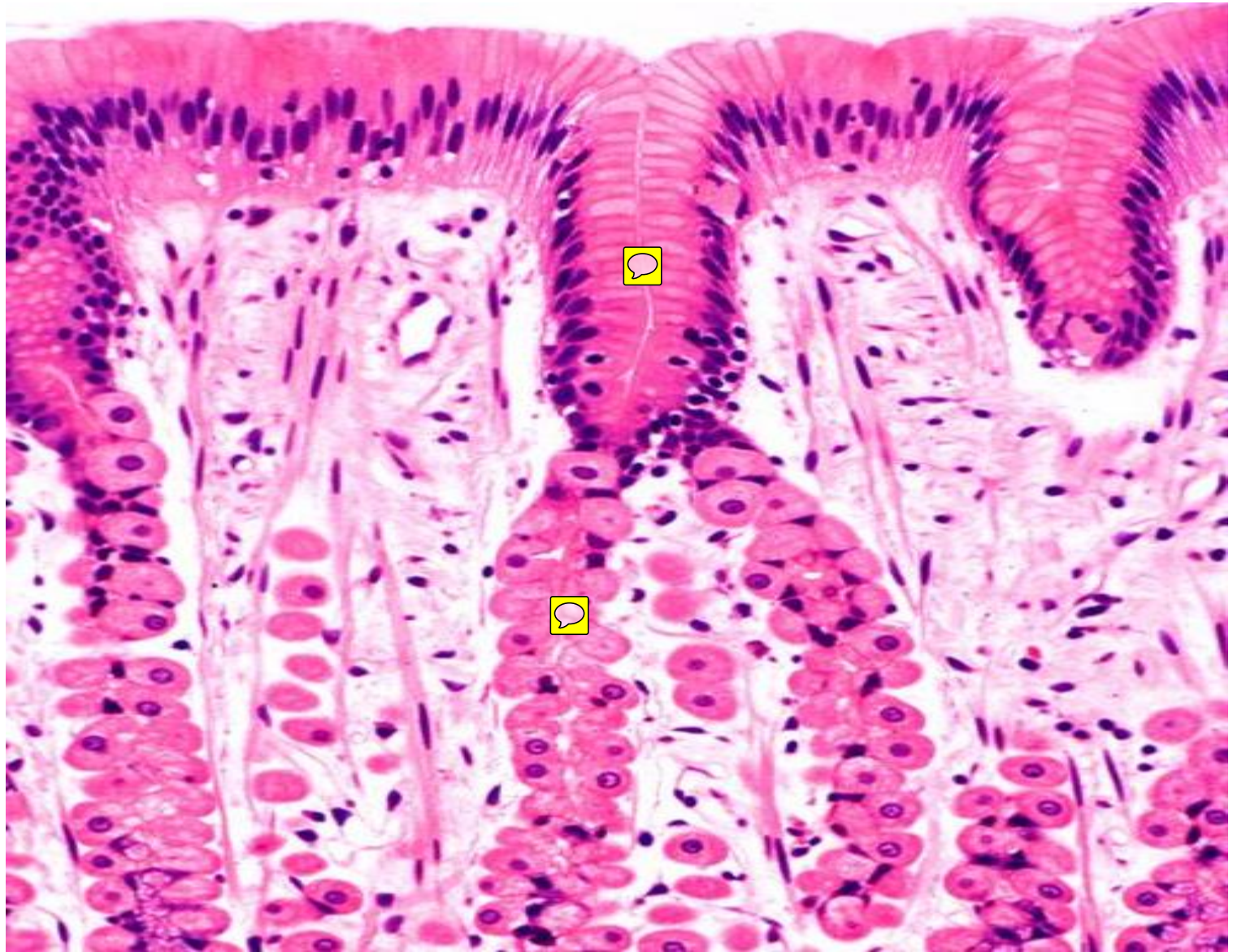


# Glands

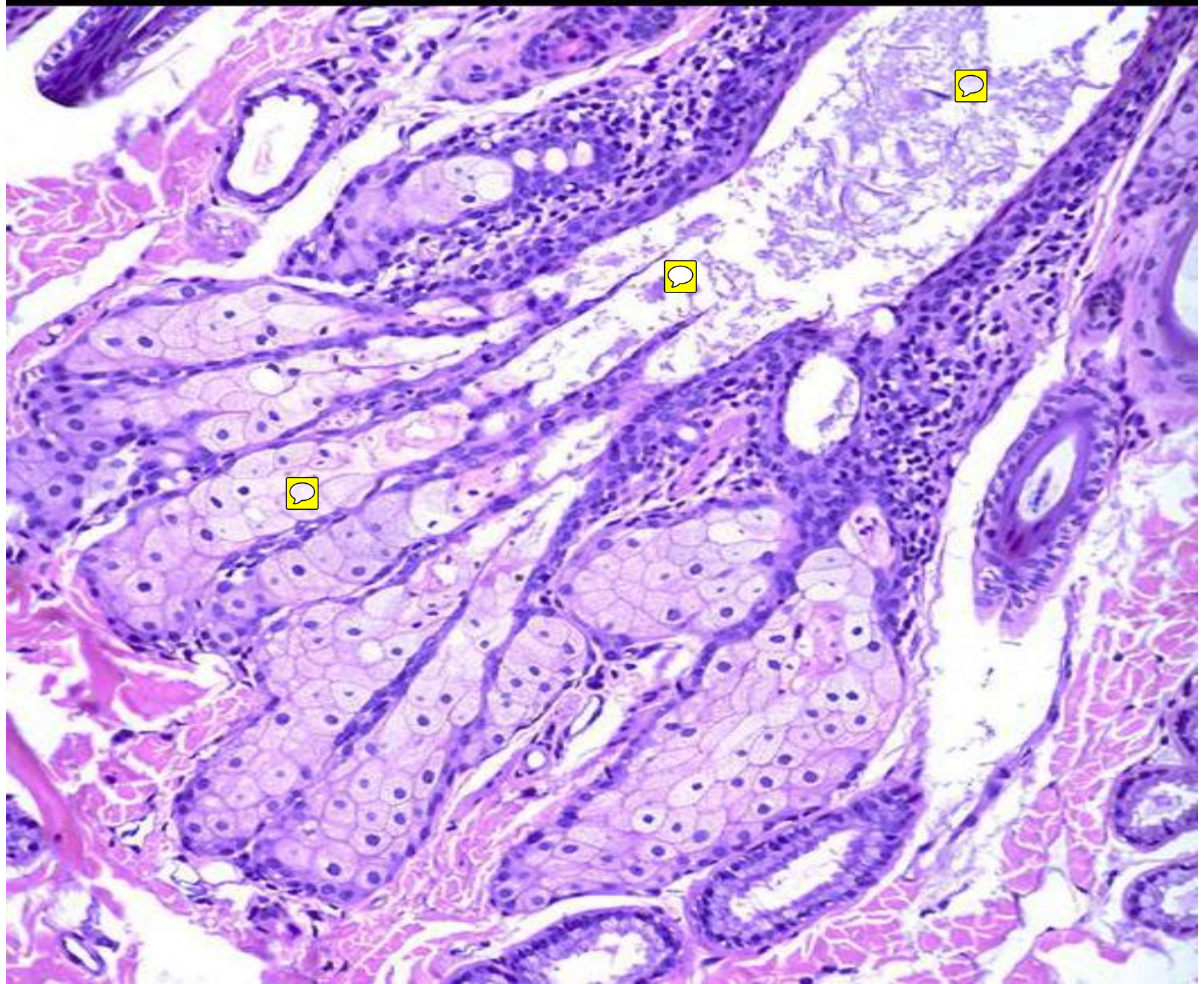




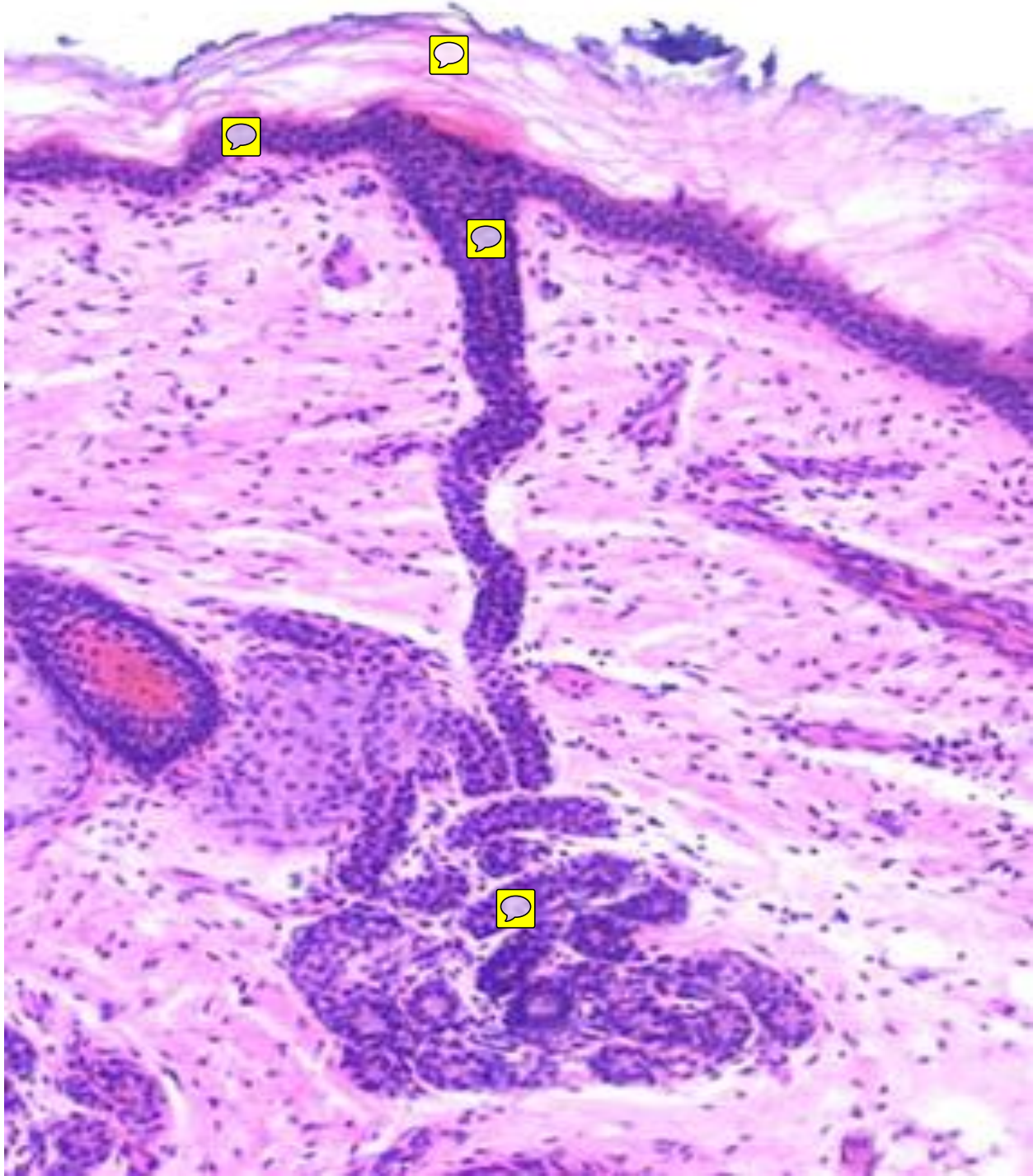




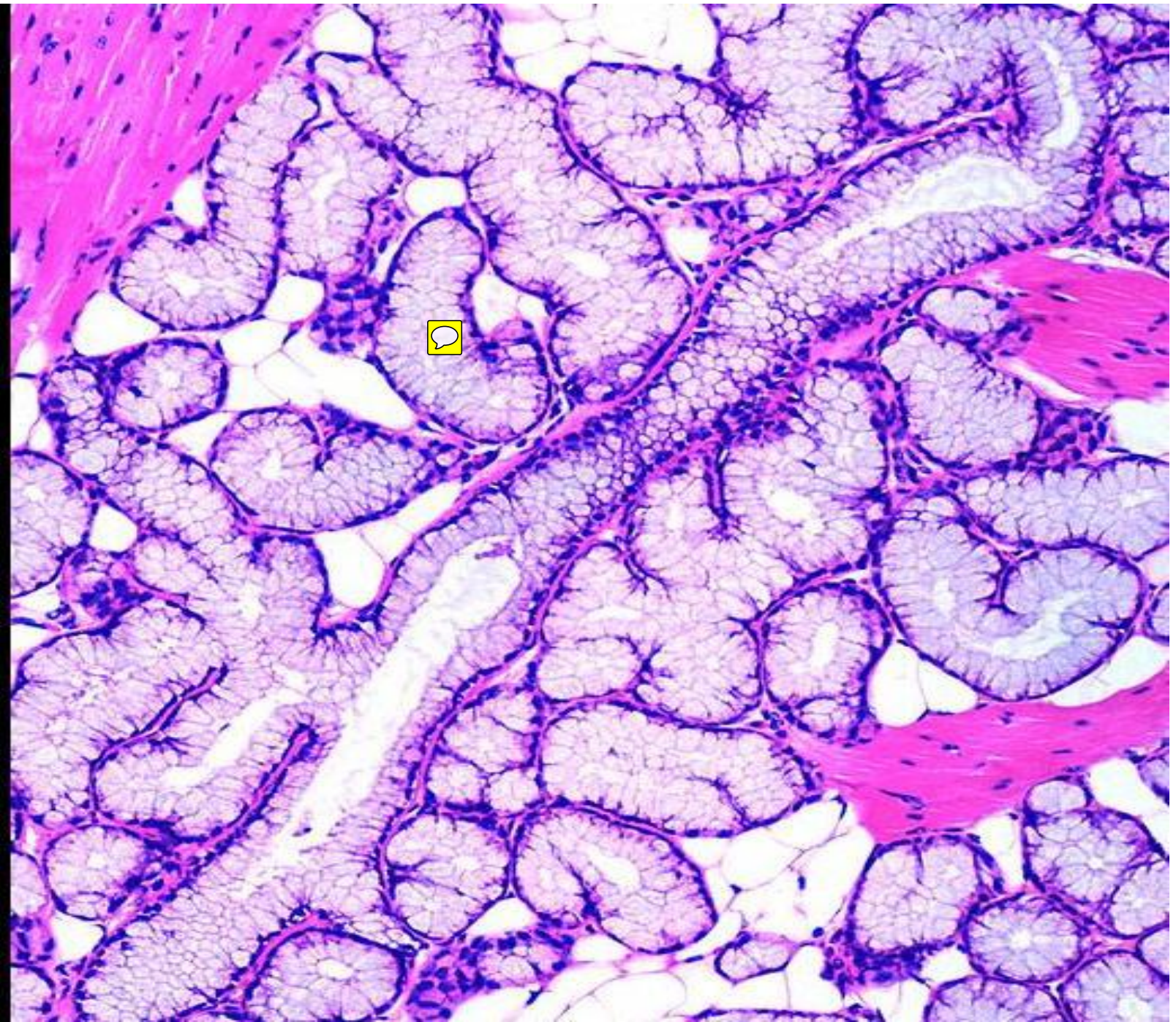




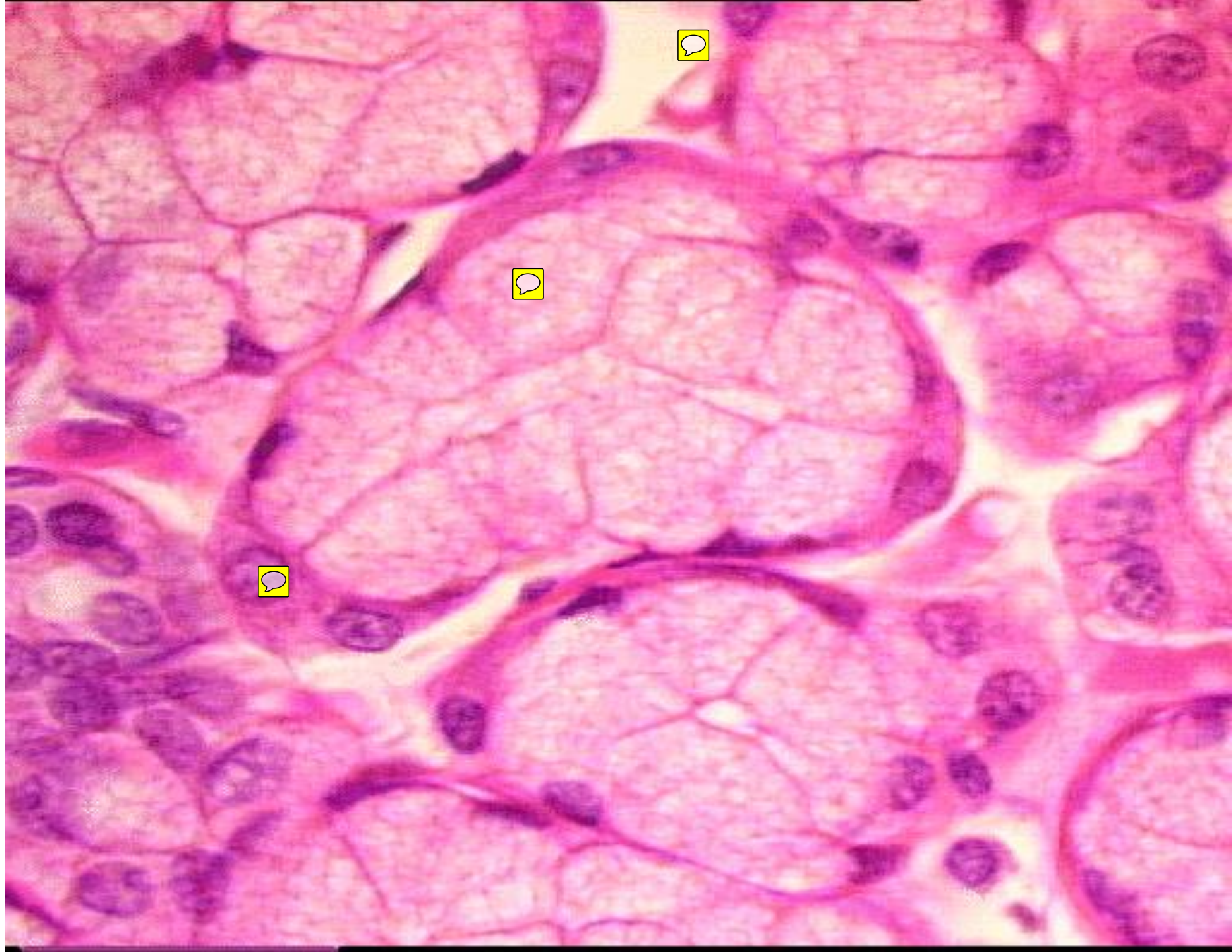




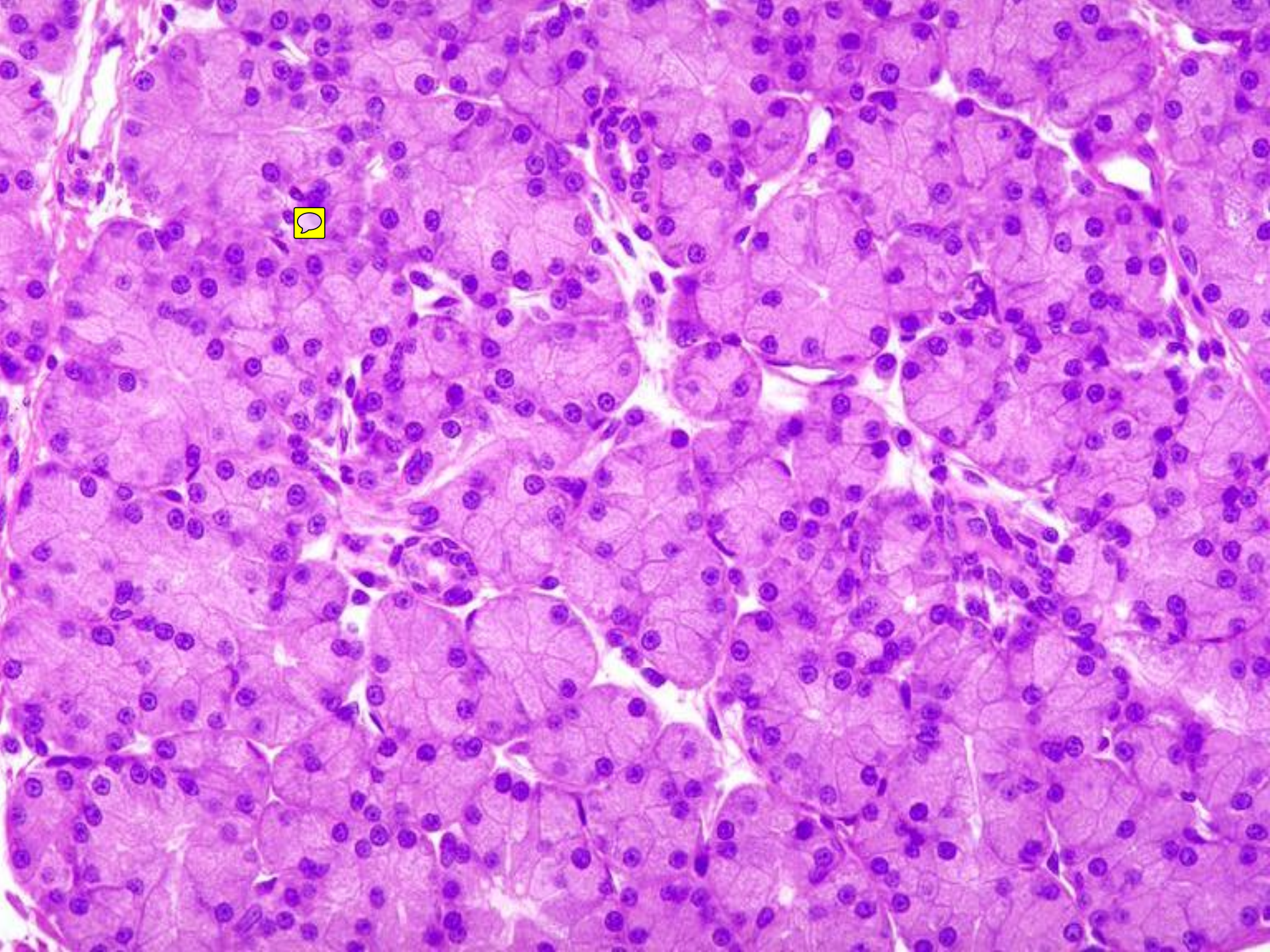




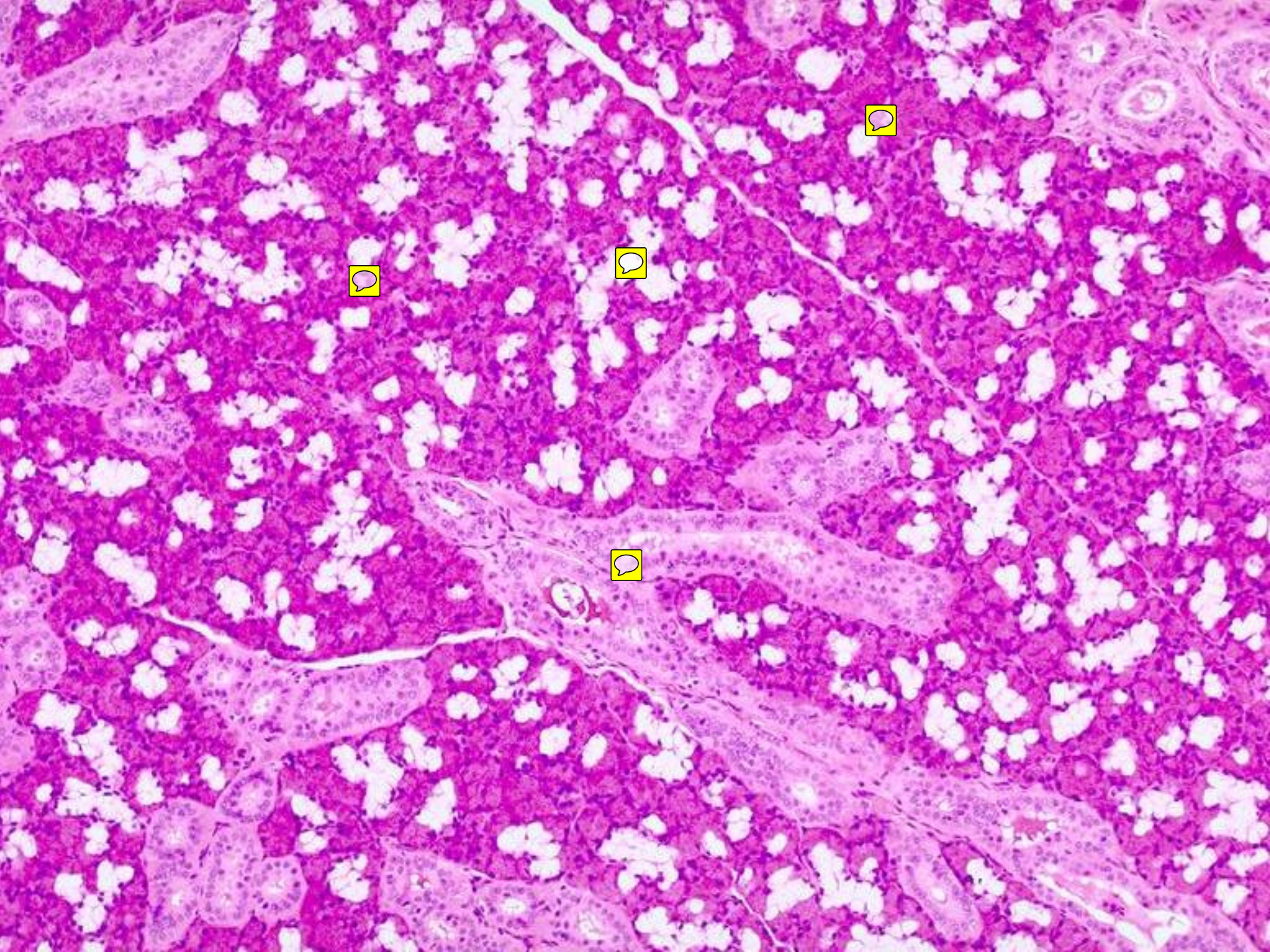




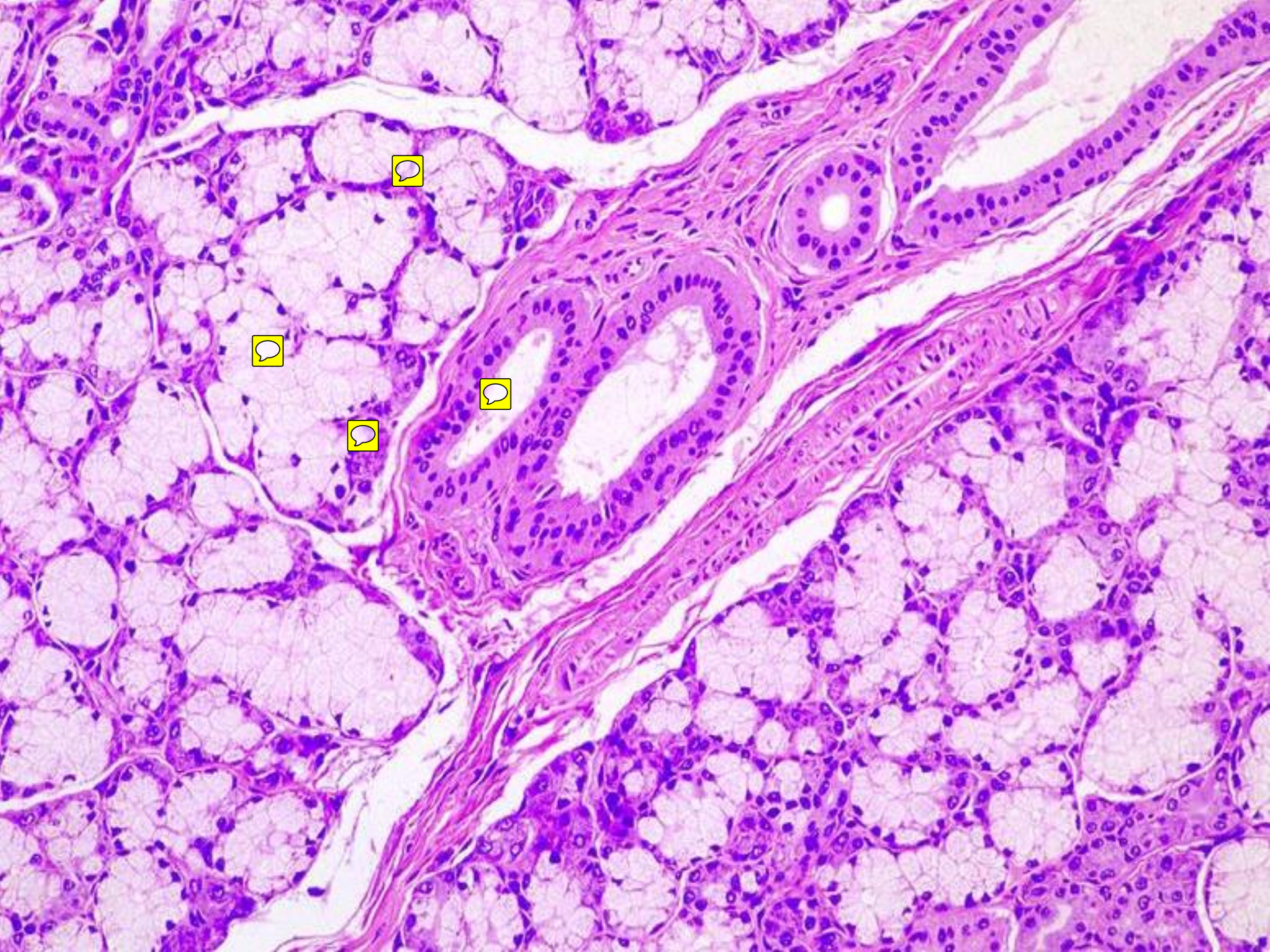




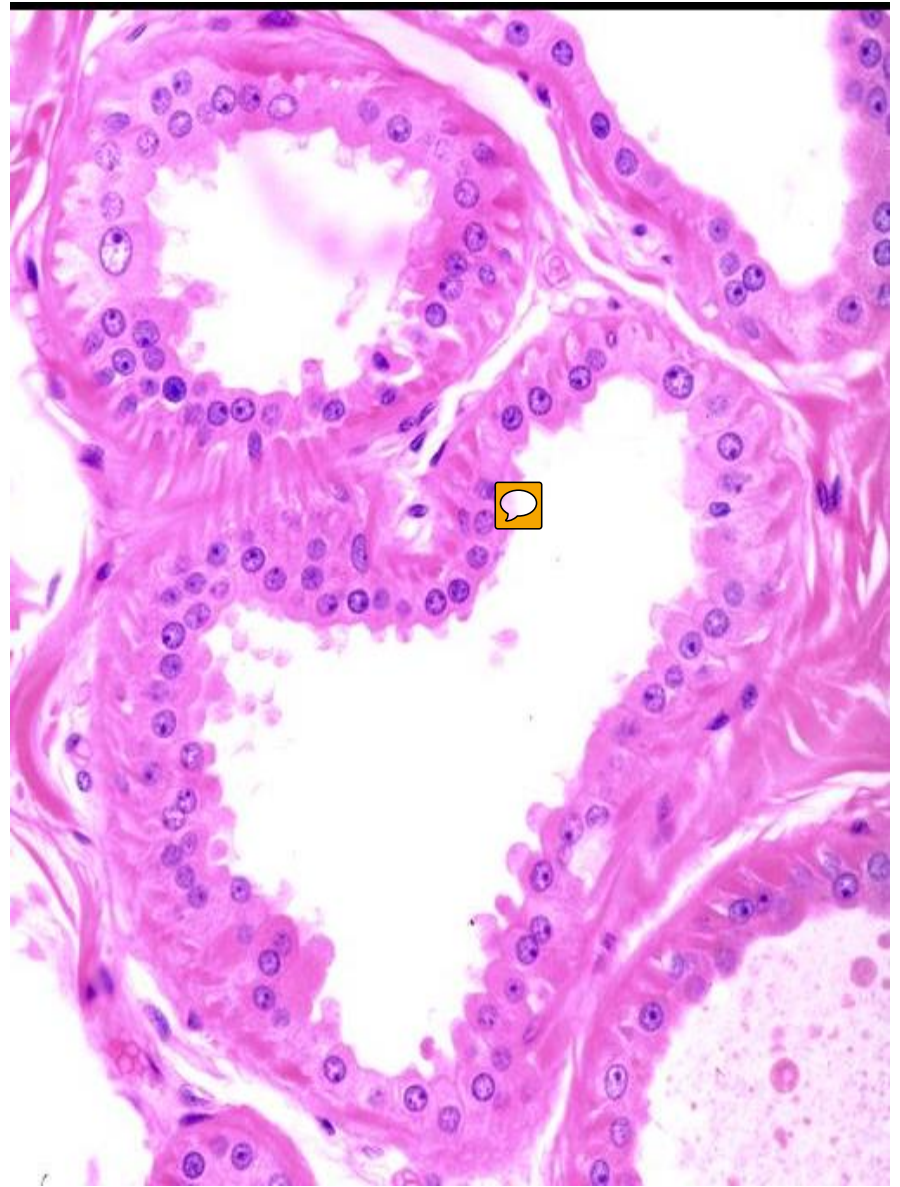
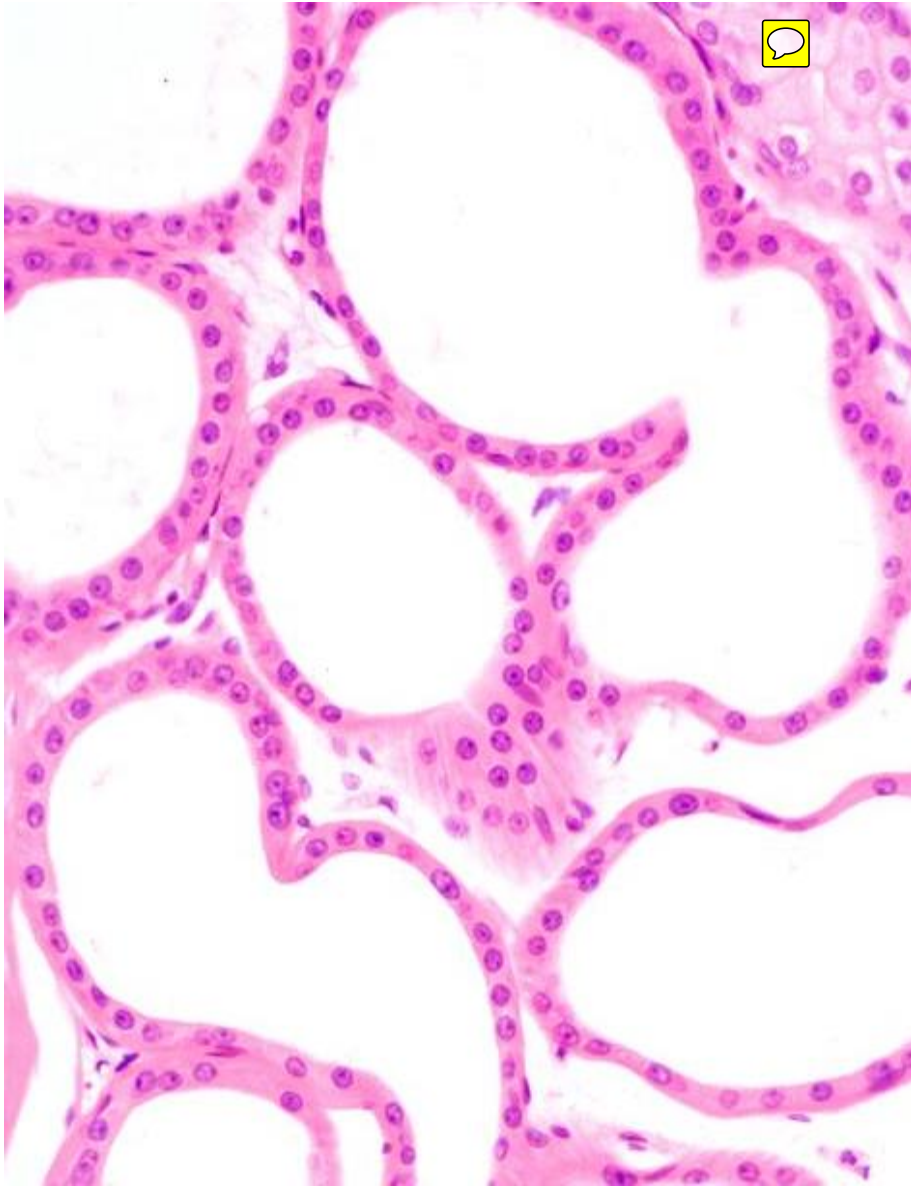






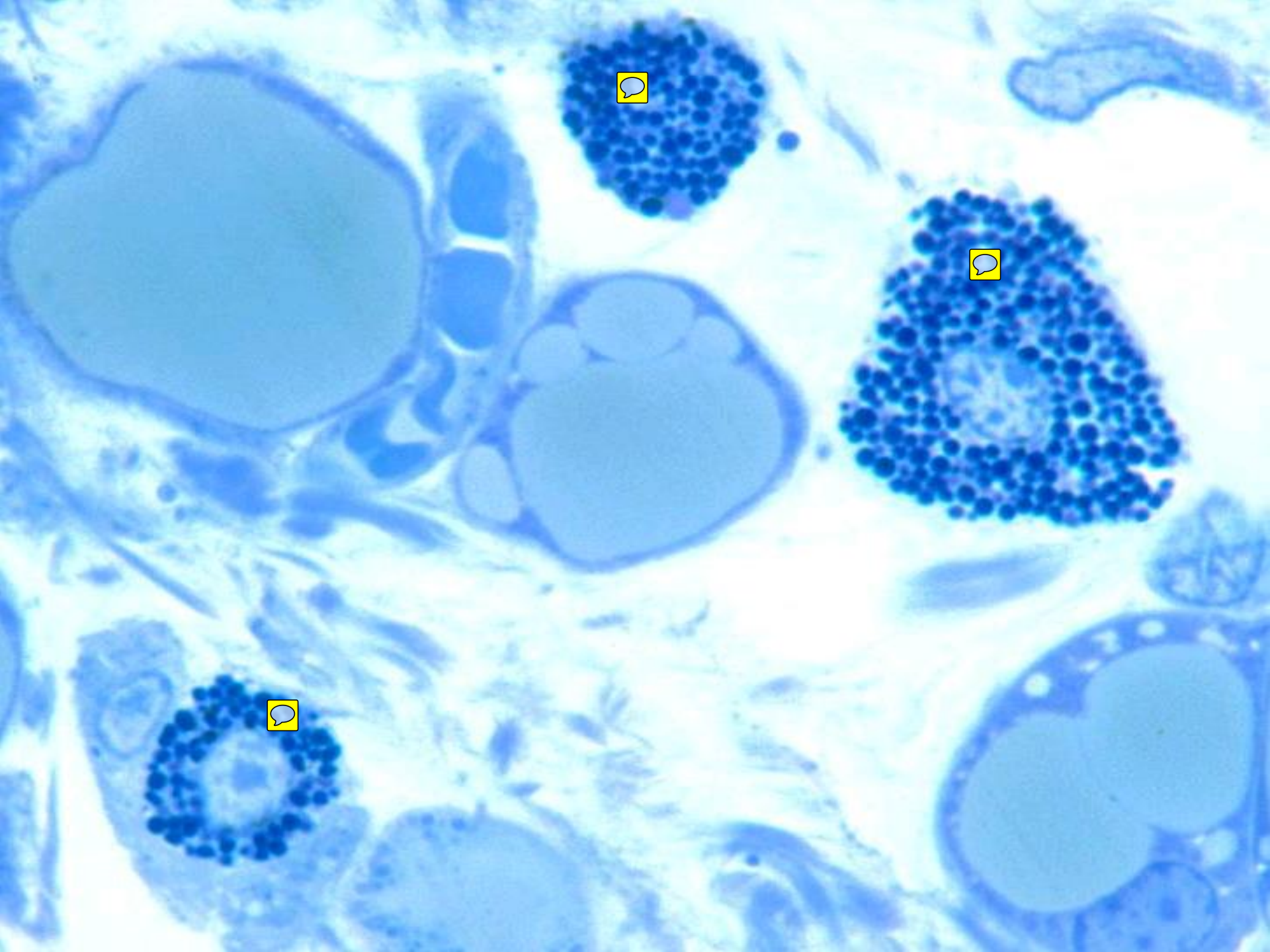




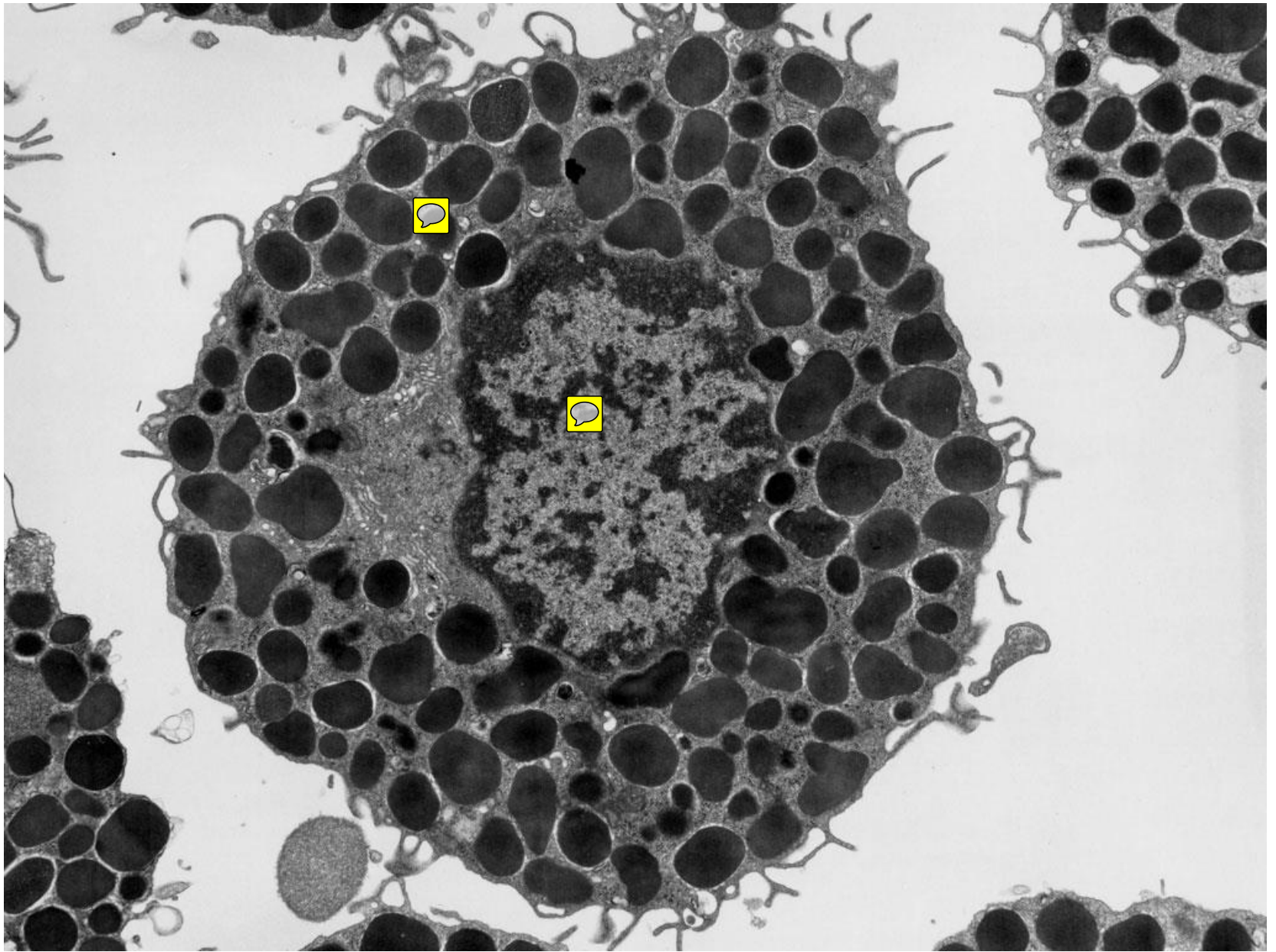




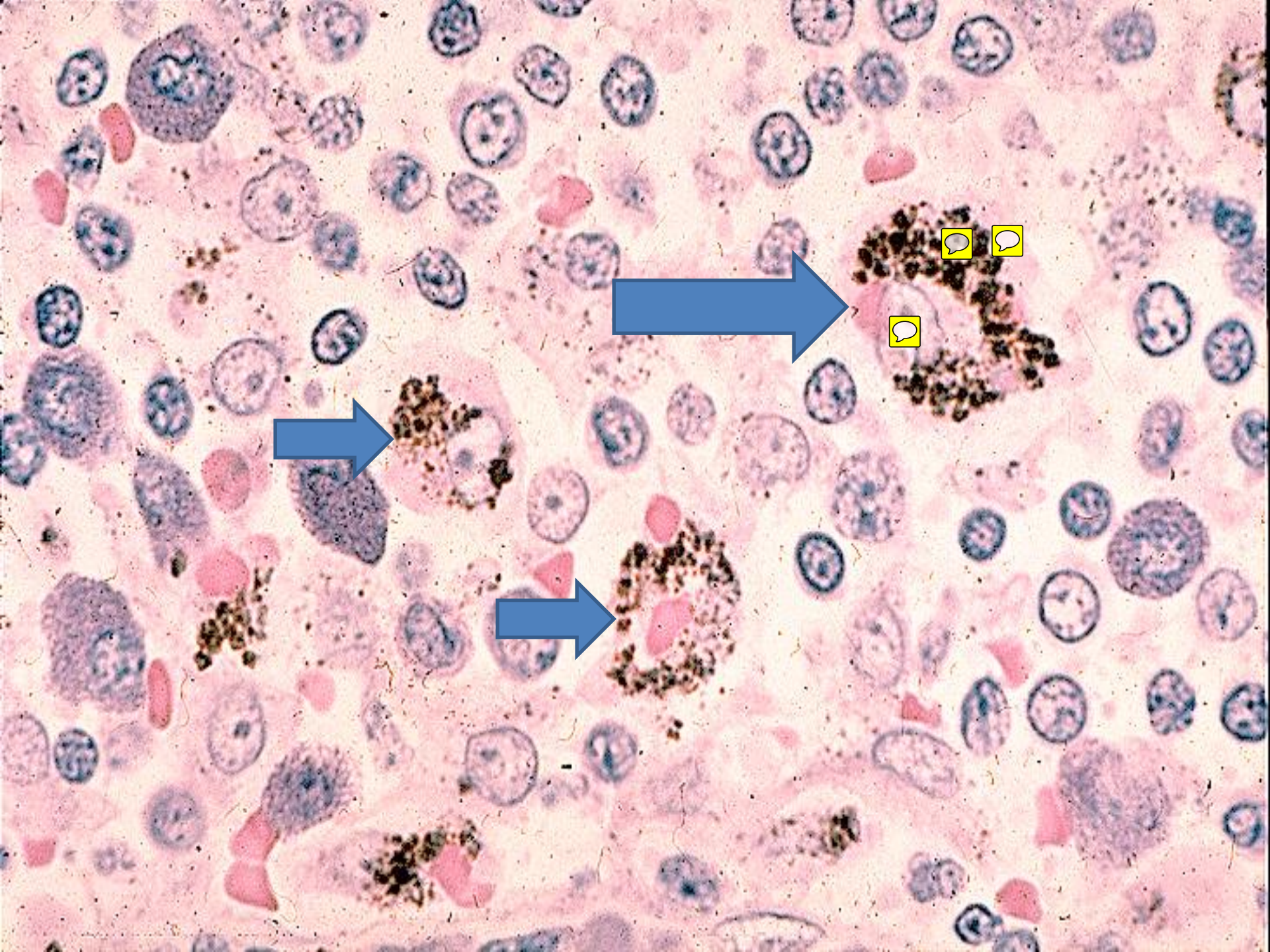
# Connective tissue



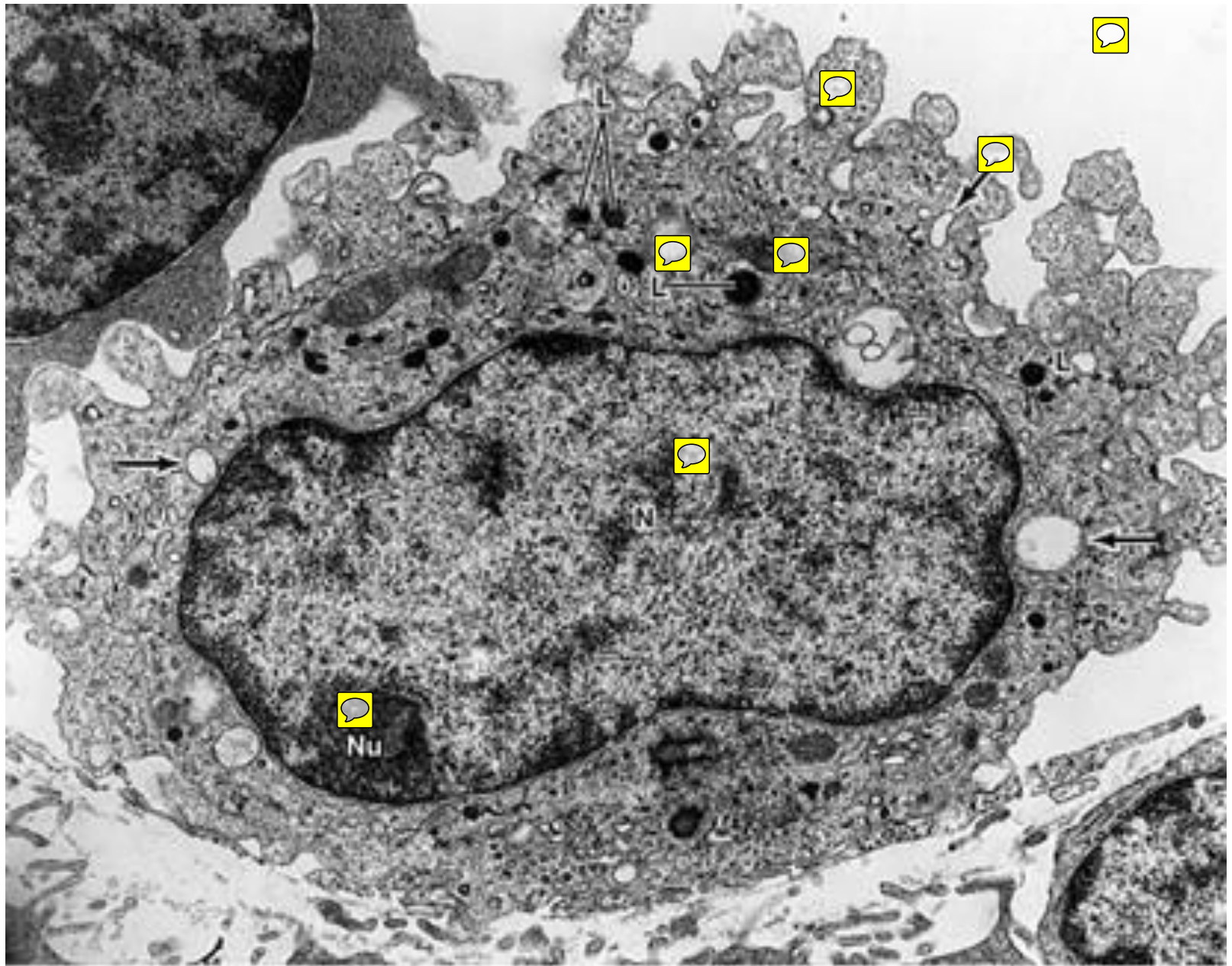




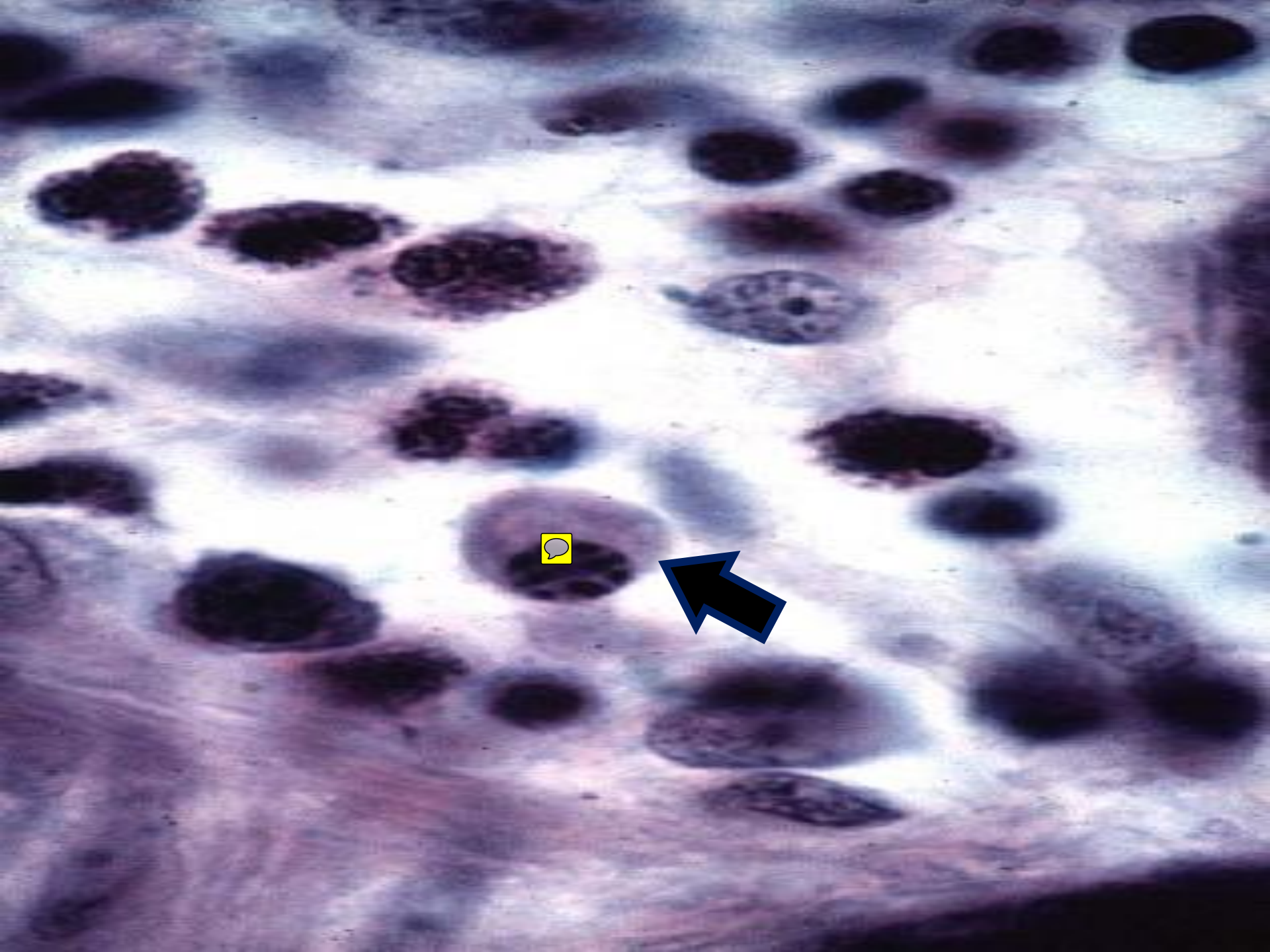




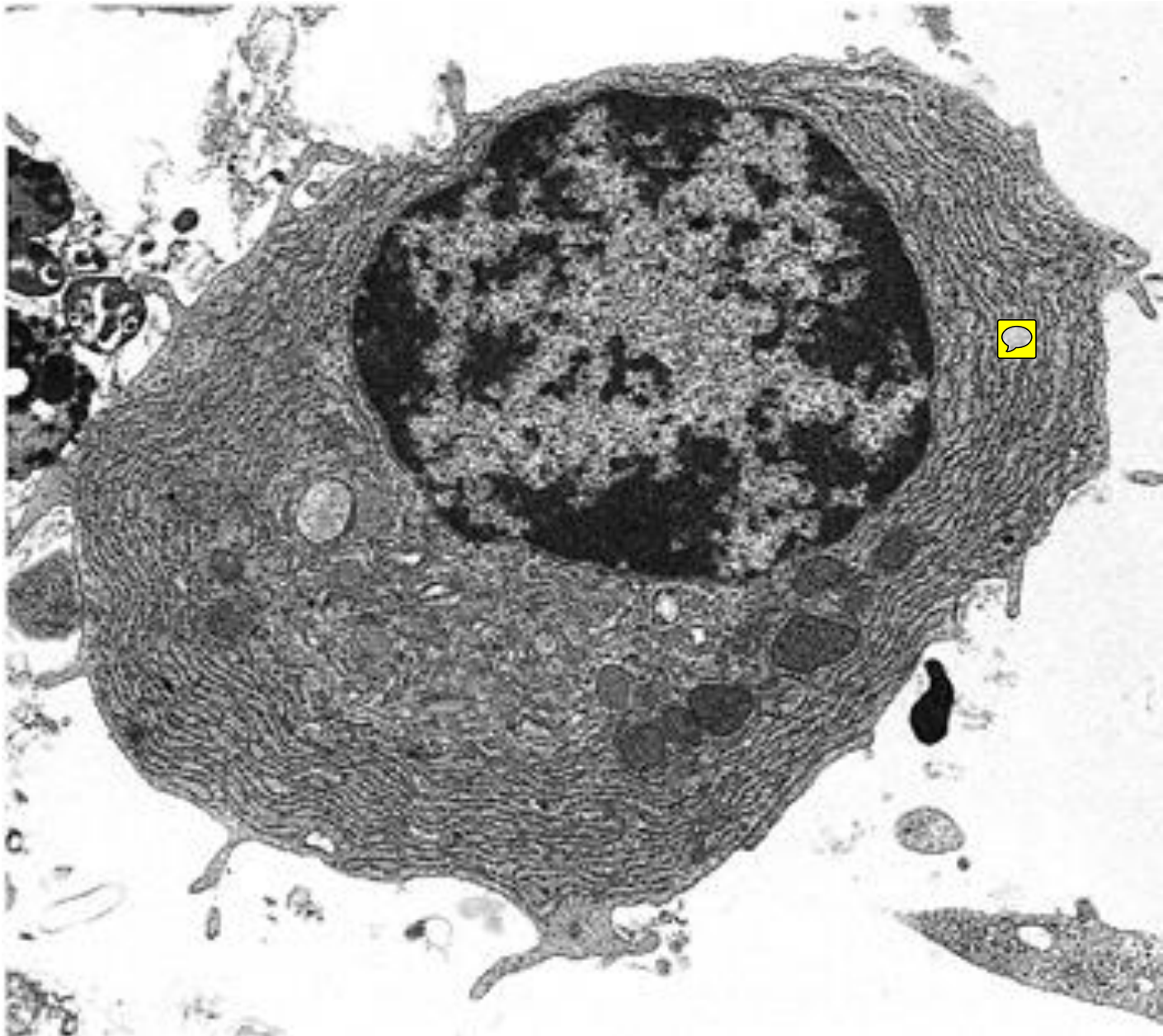




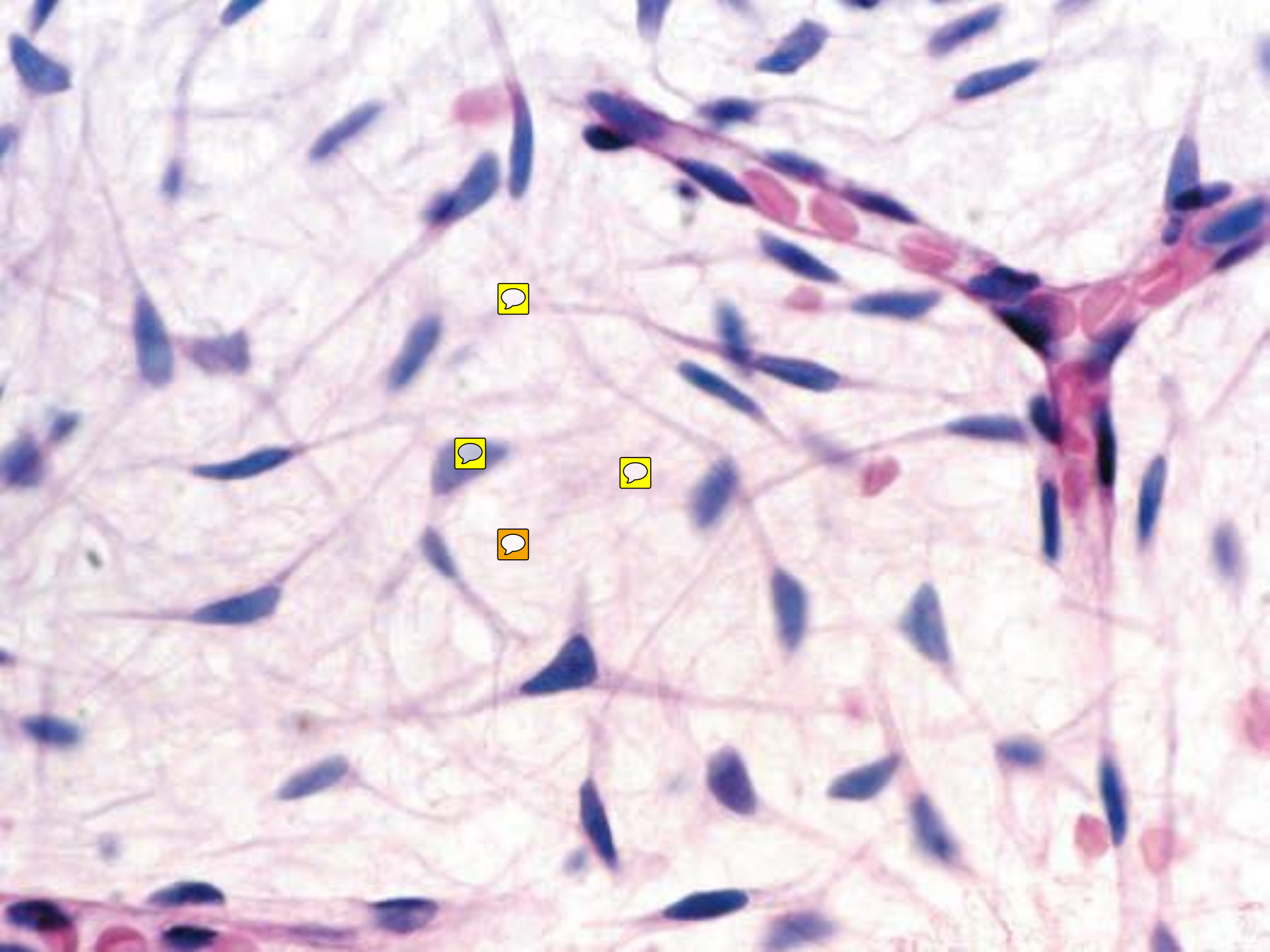




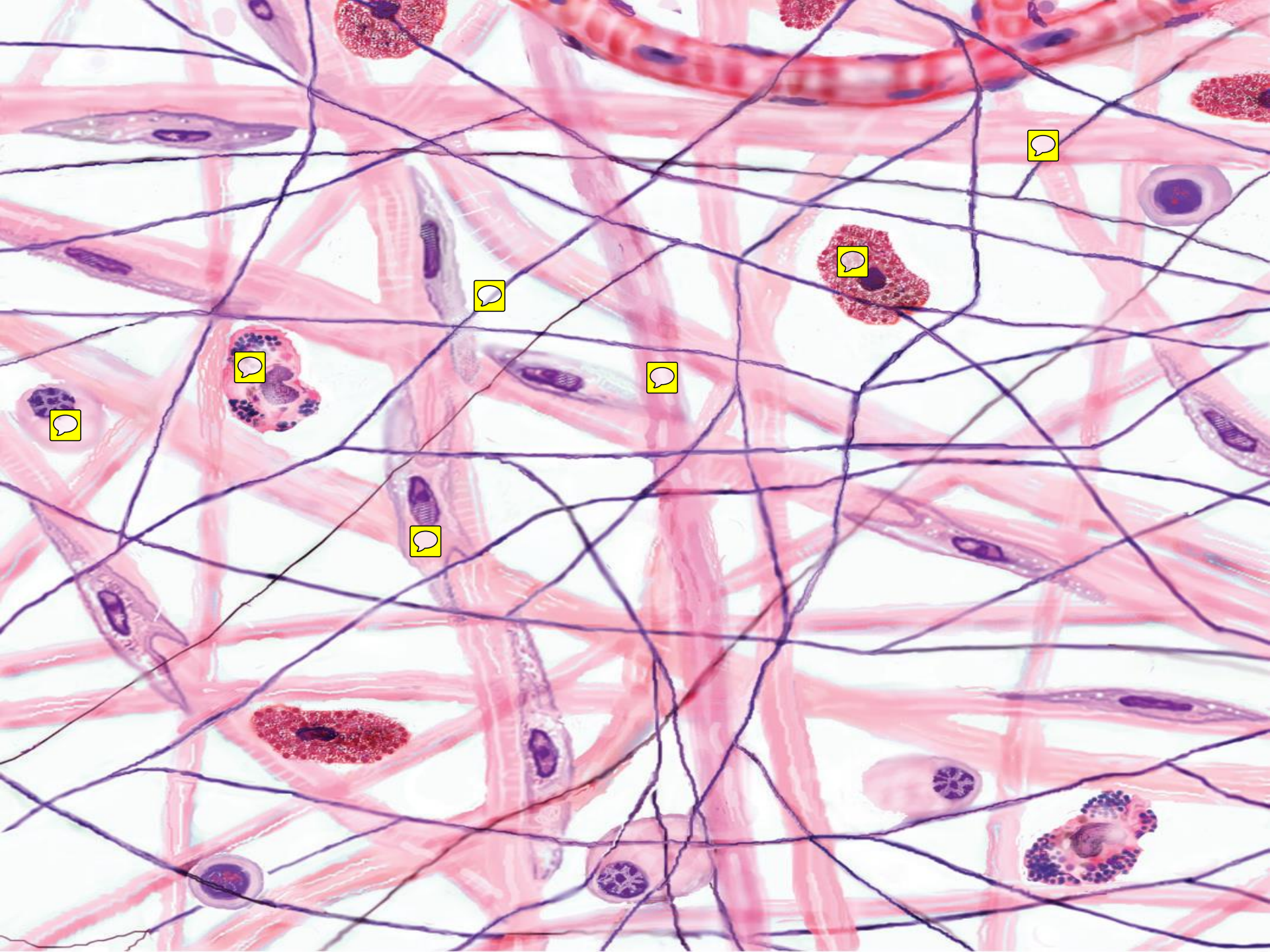




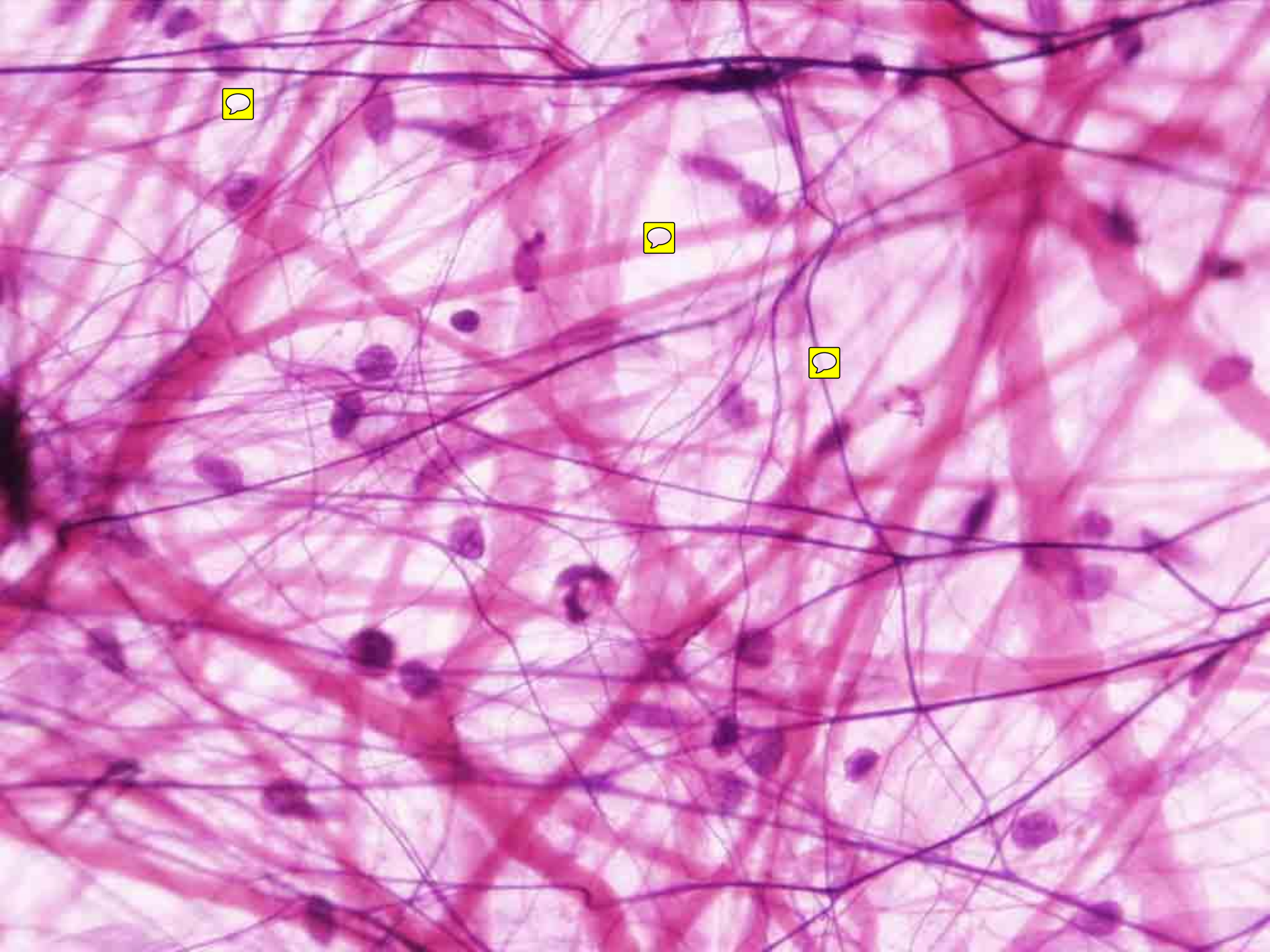




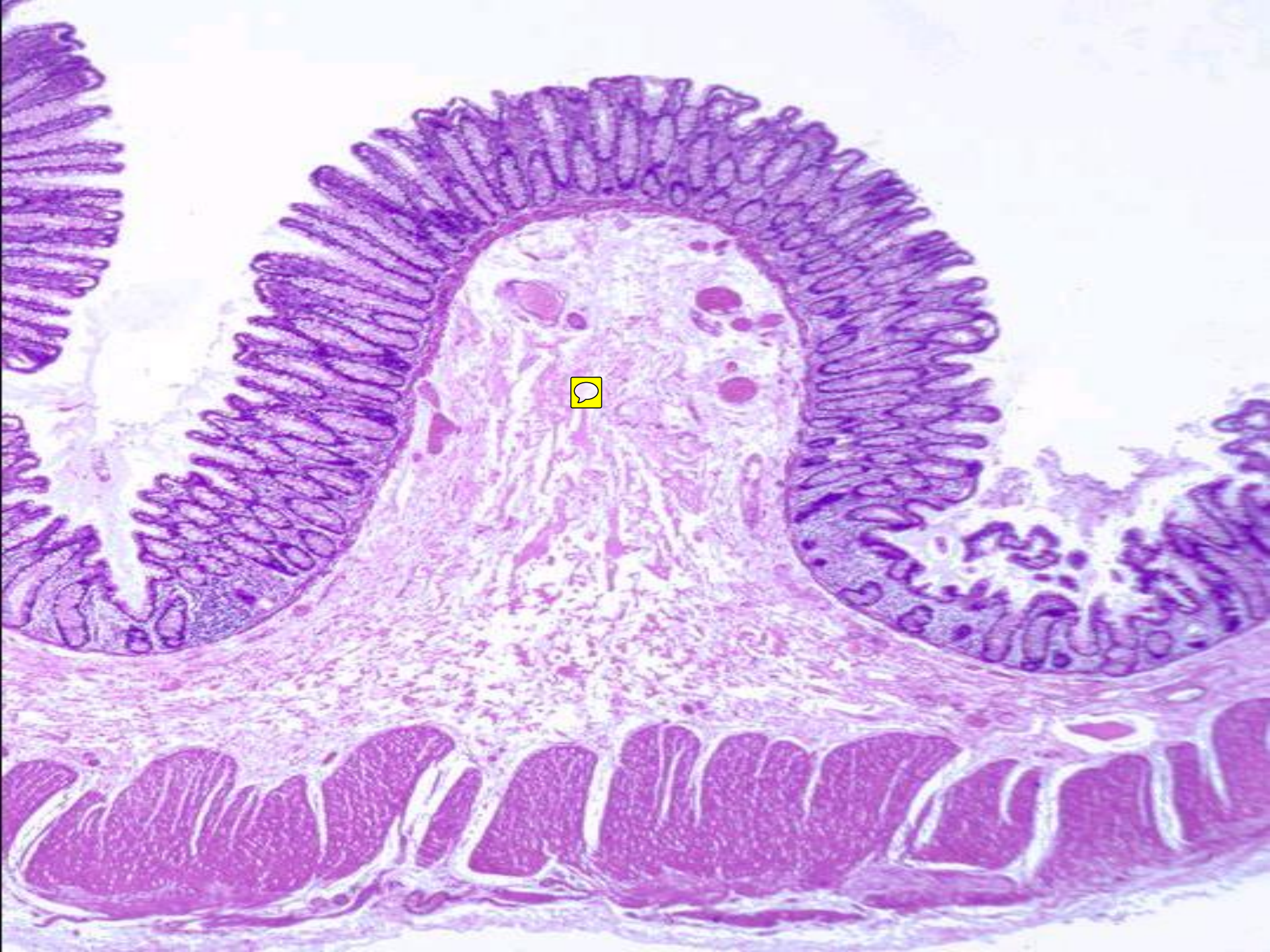








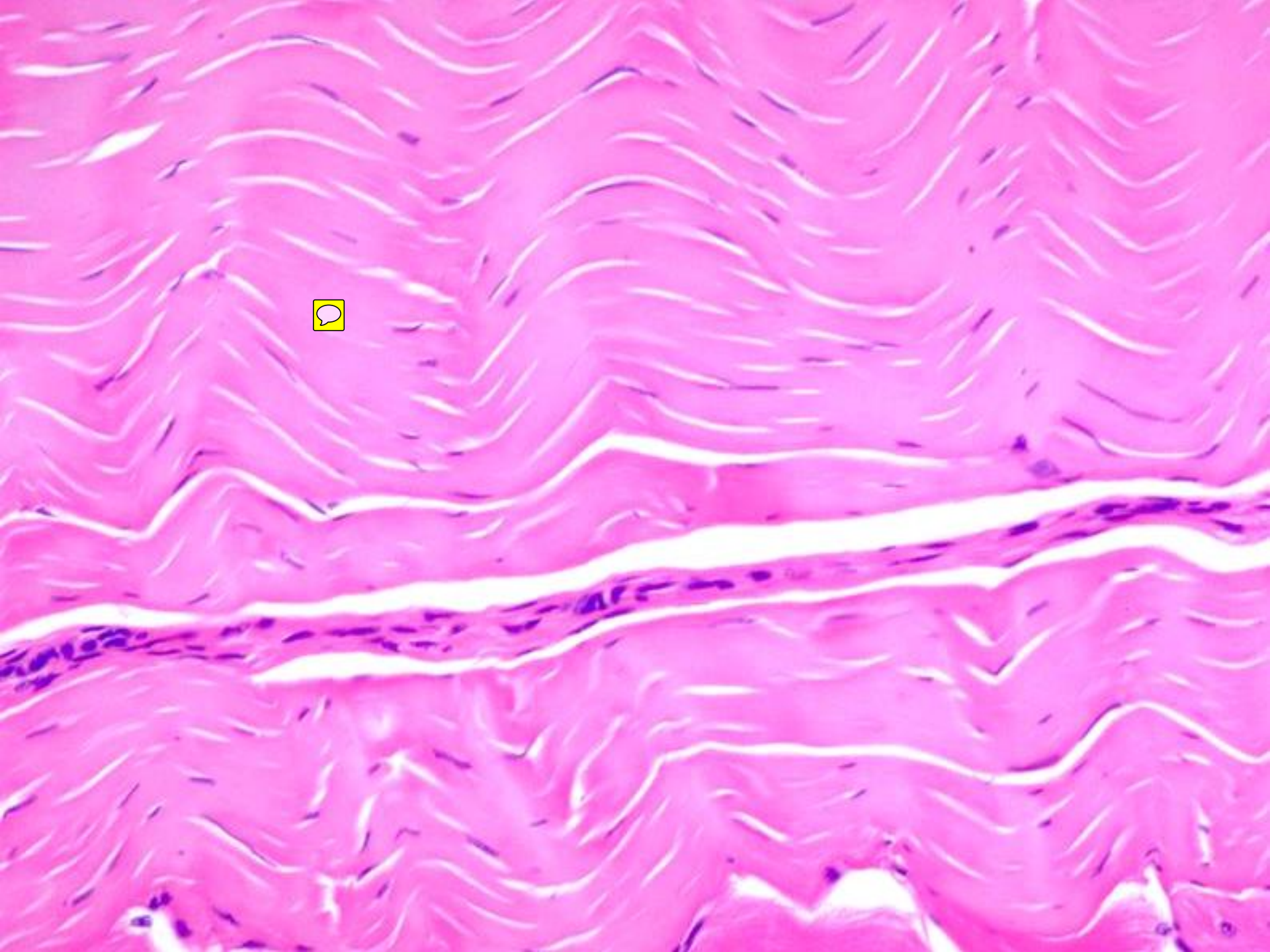




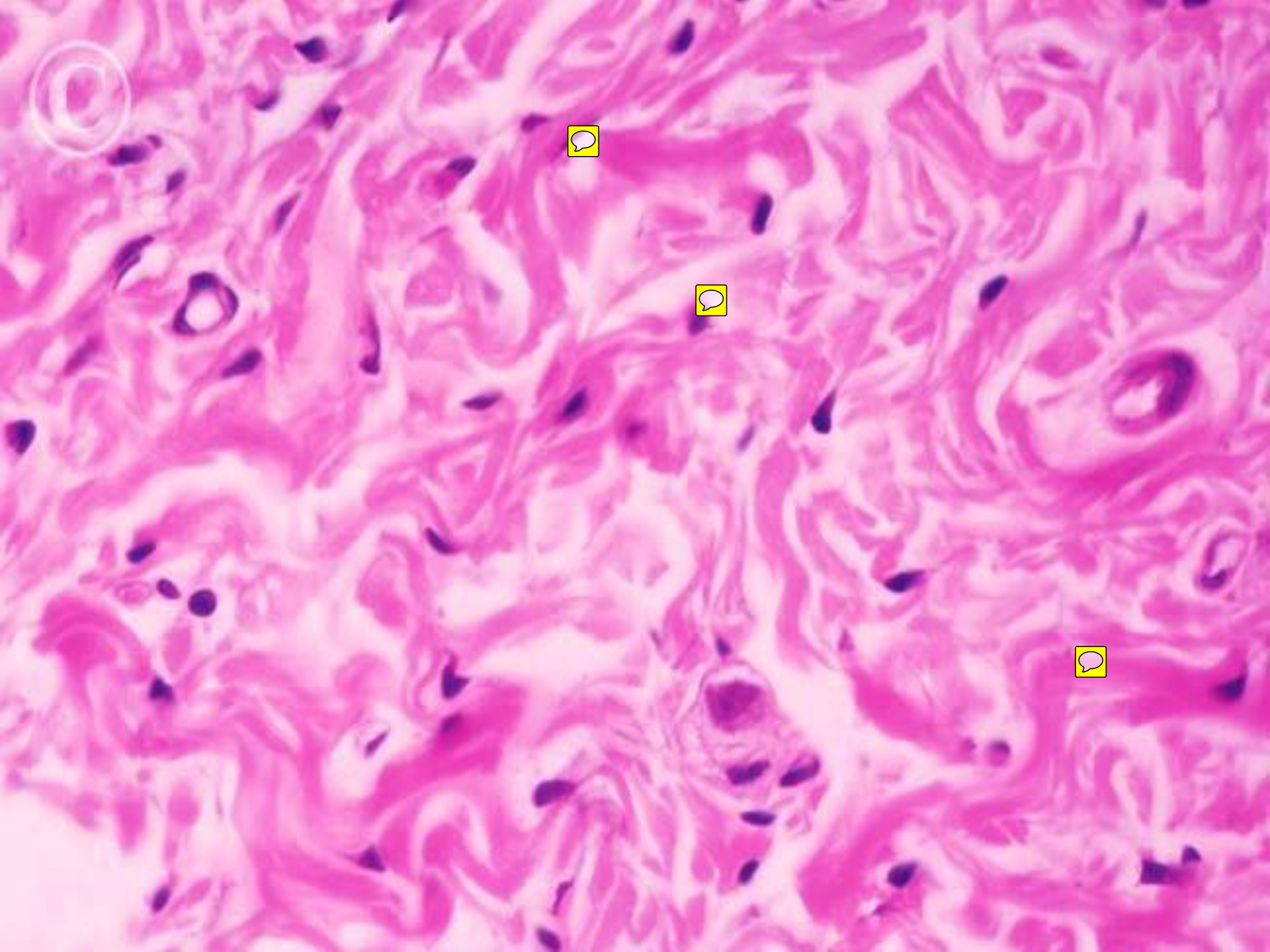




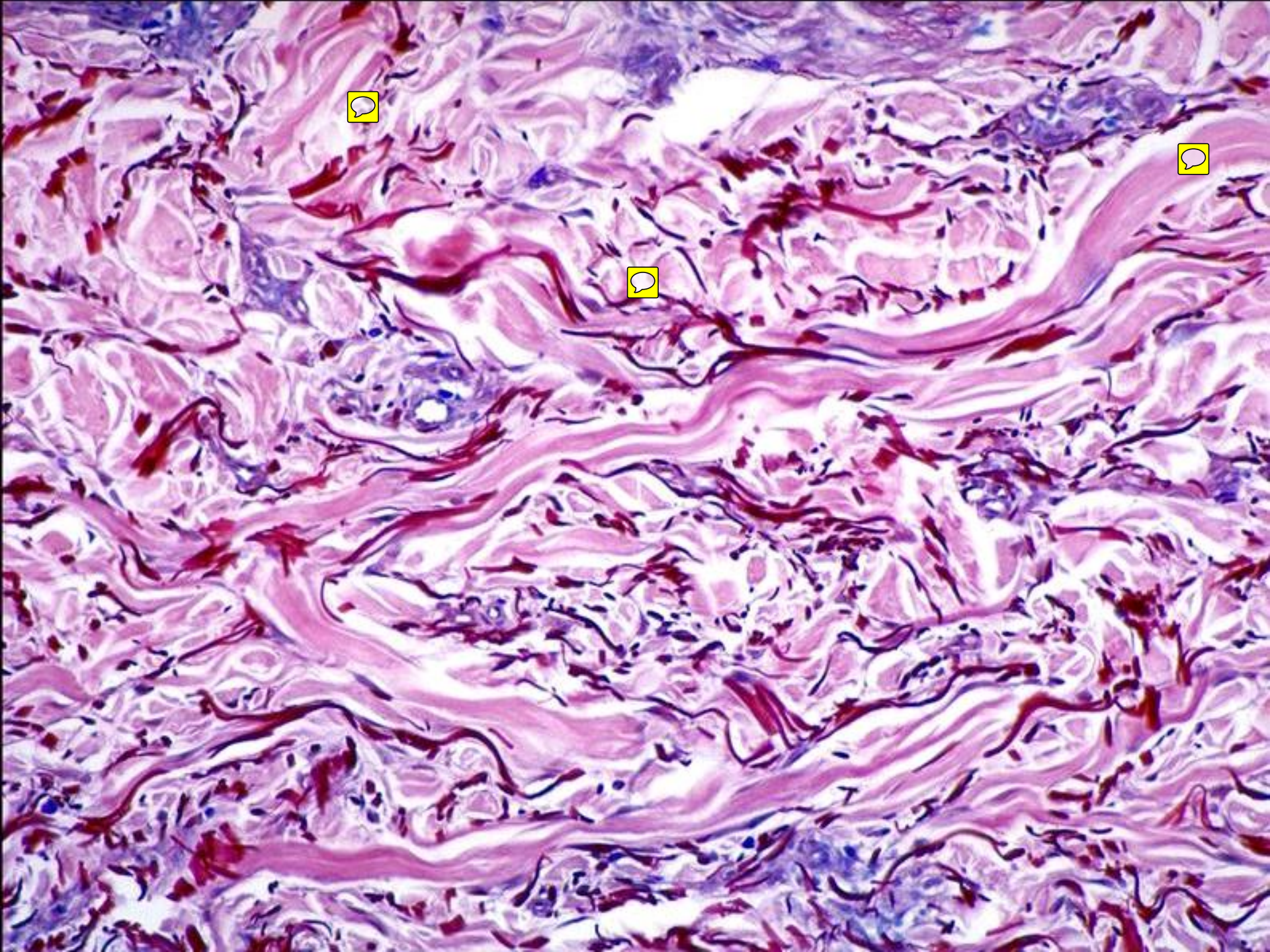




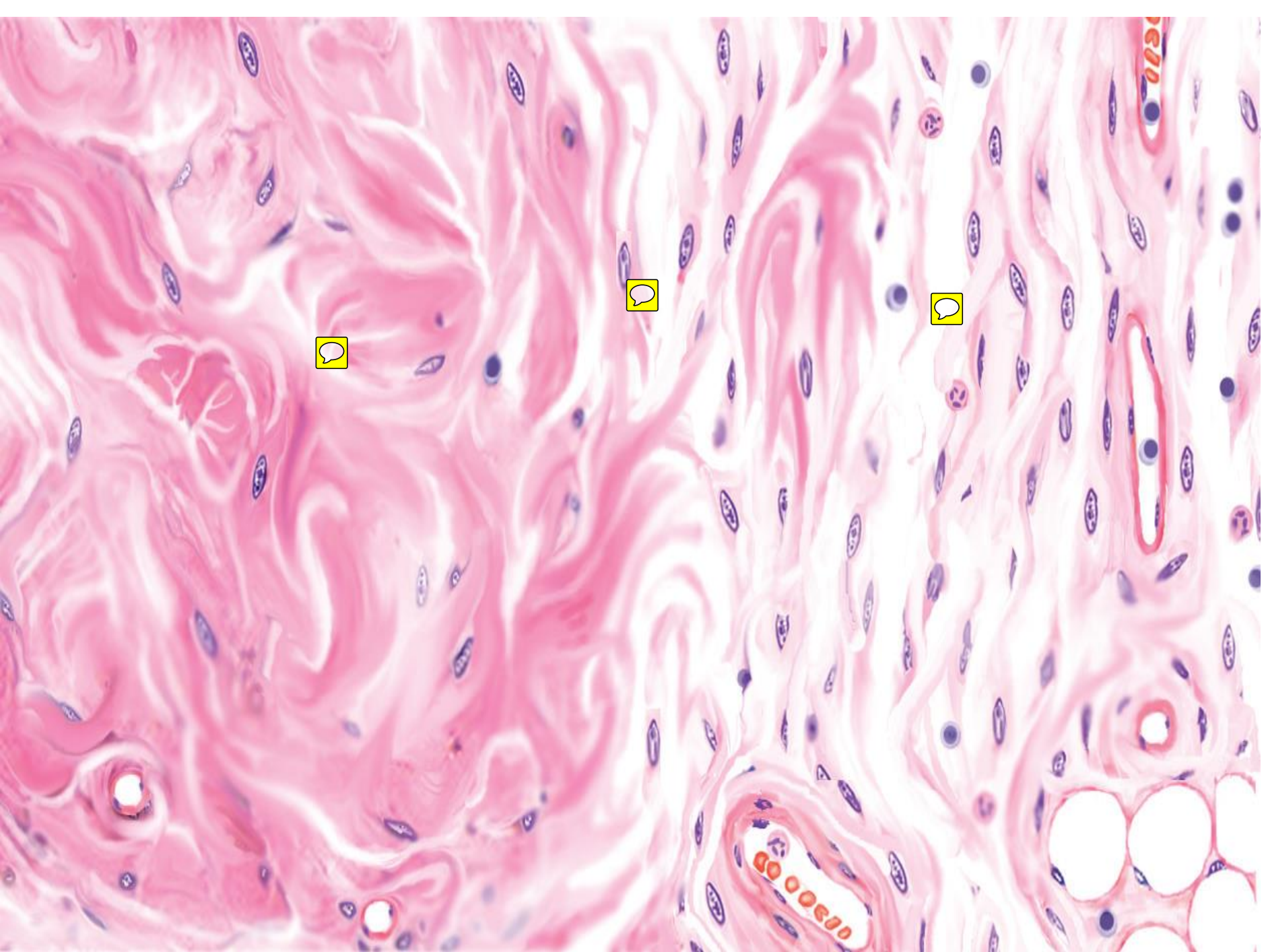
















A



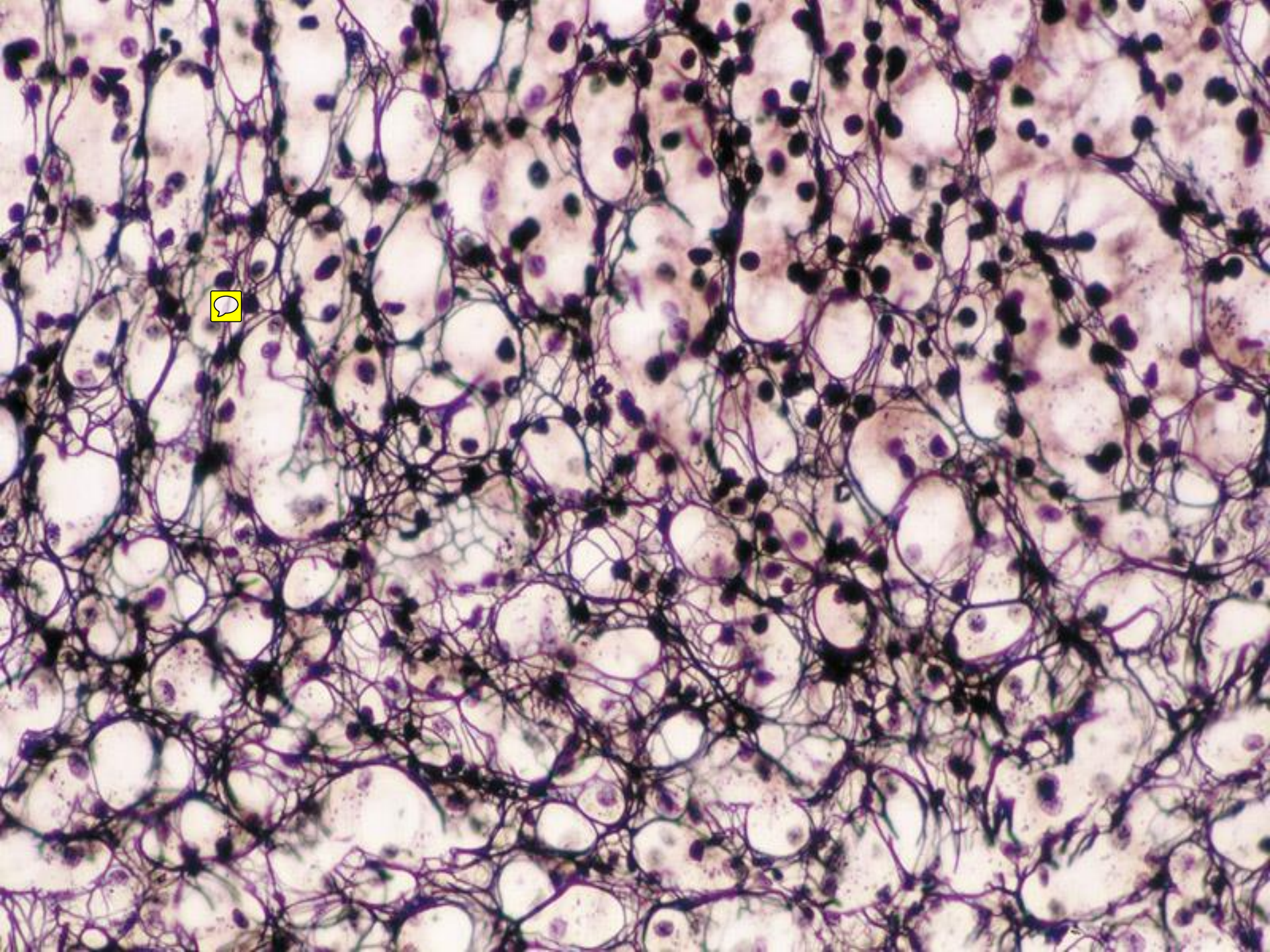
C



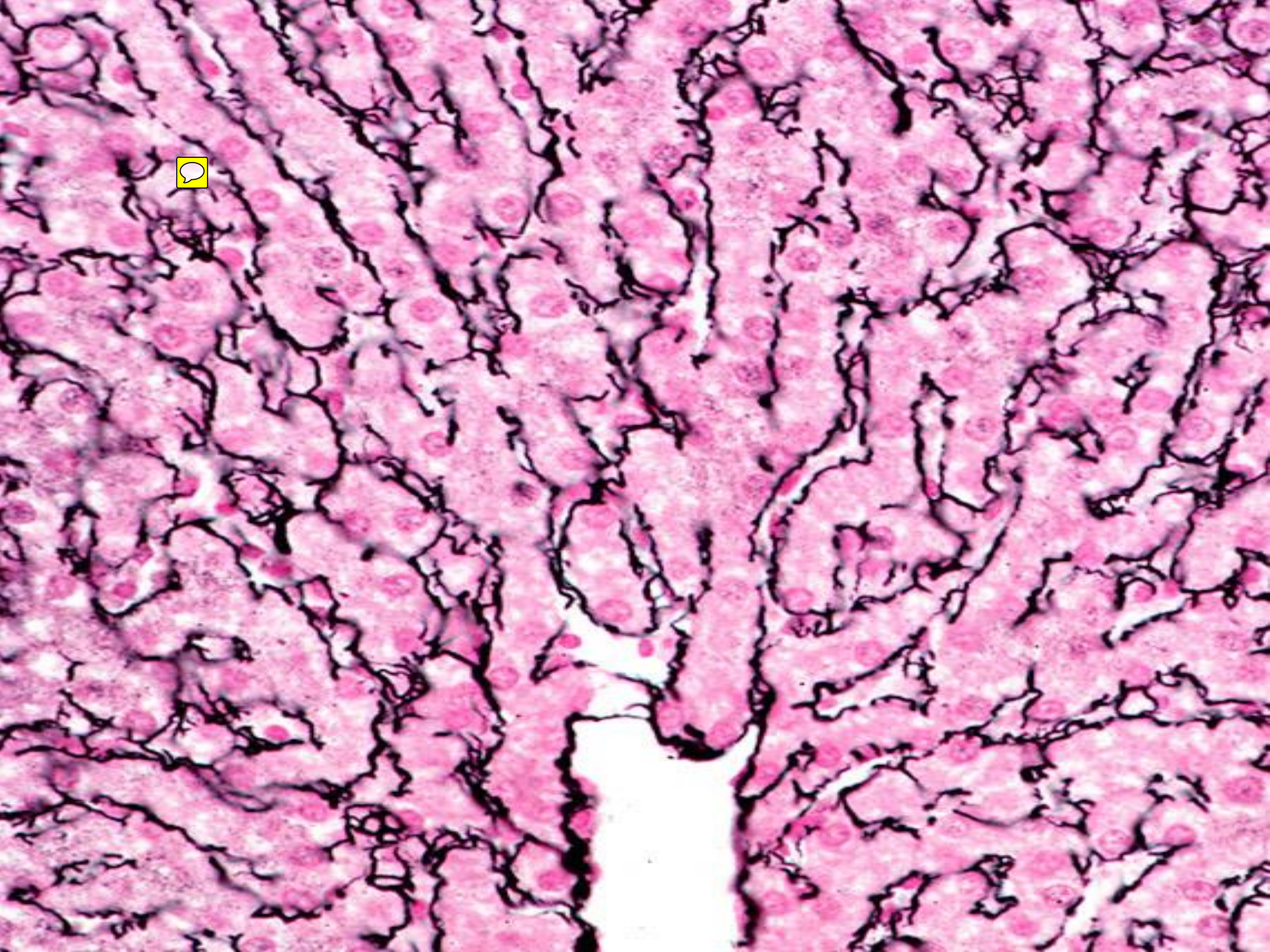
B



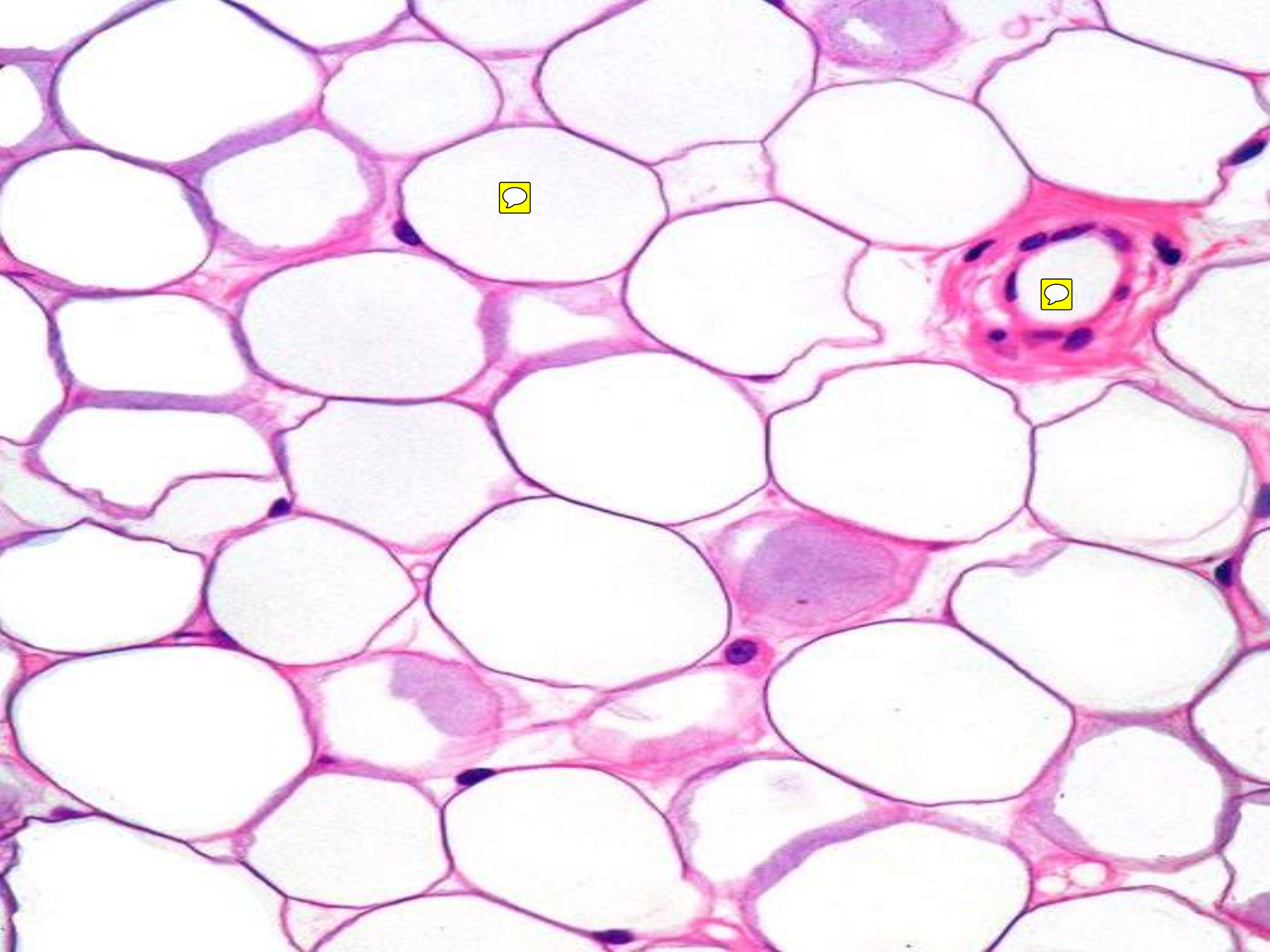




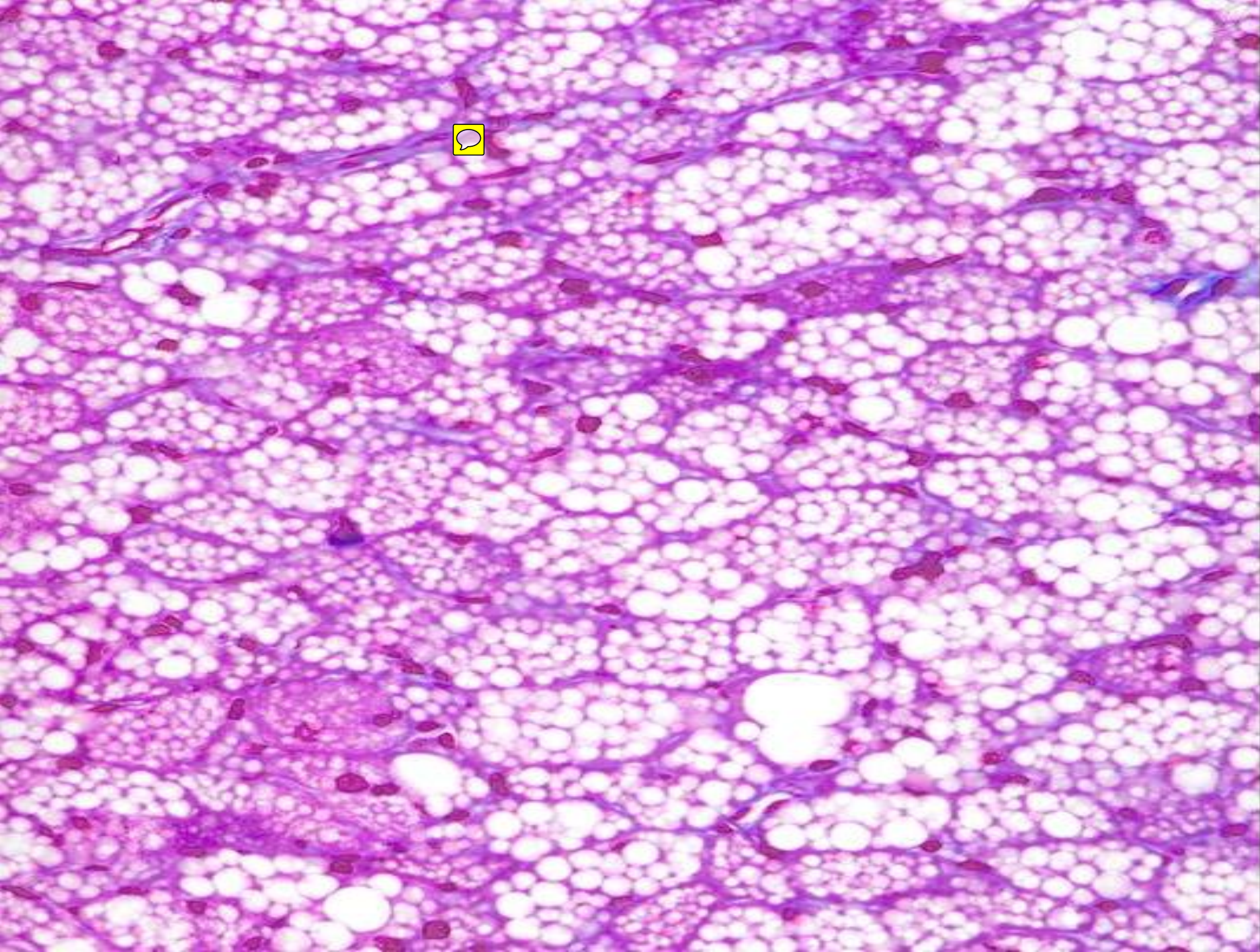








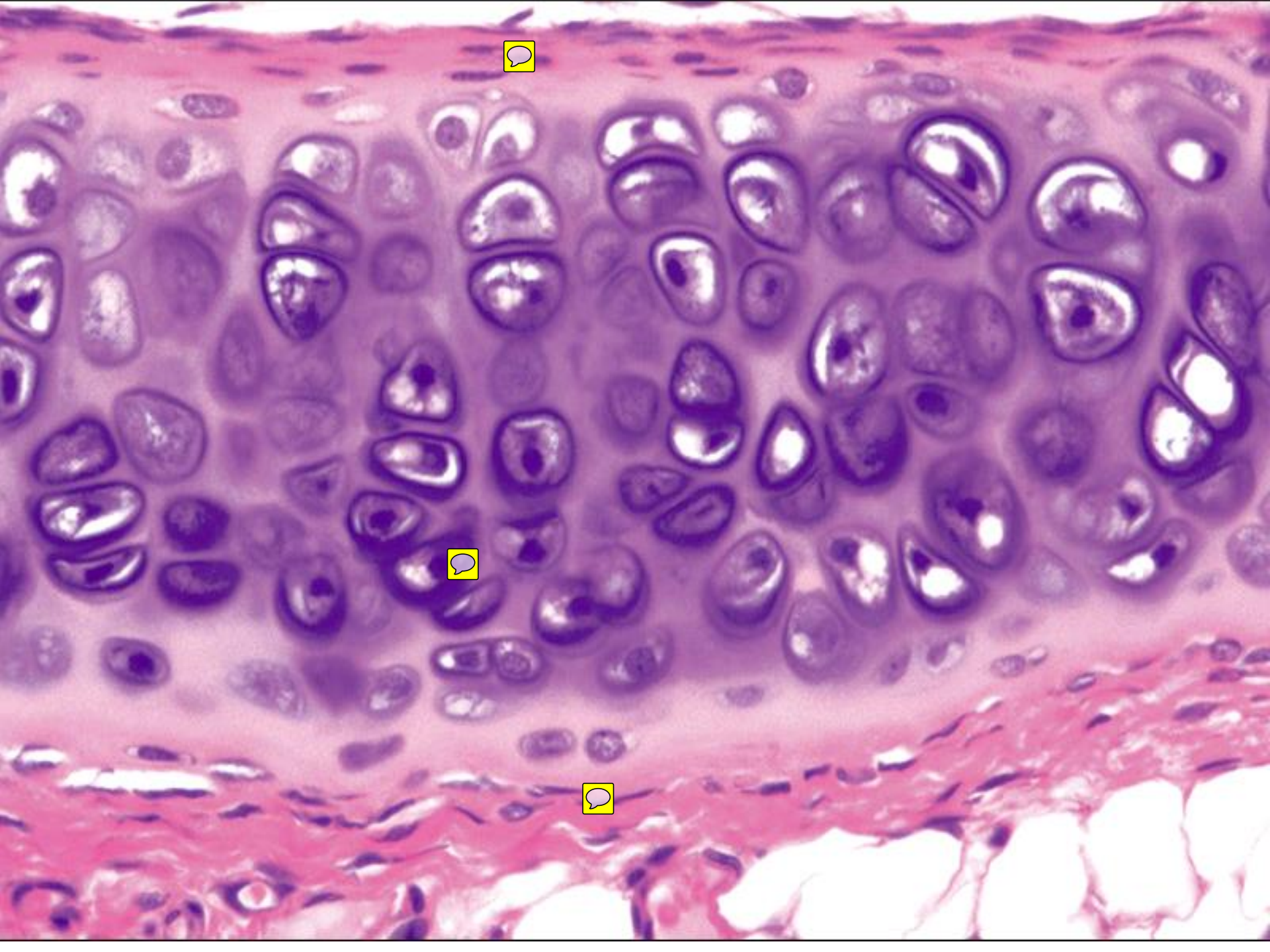




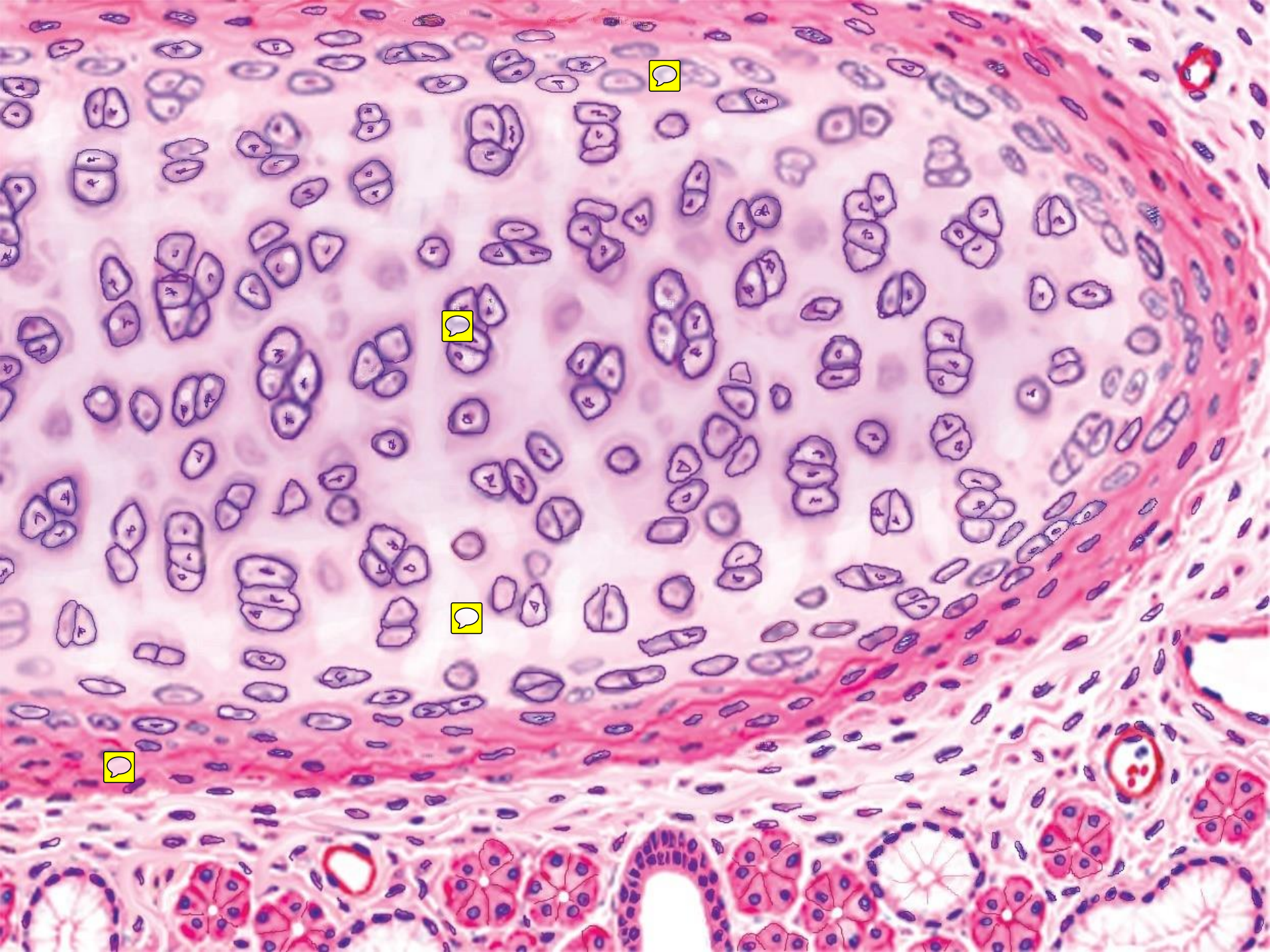


Cartilage





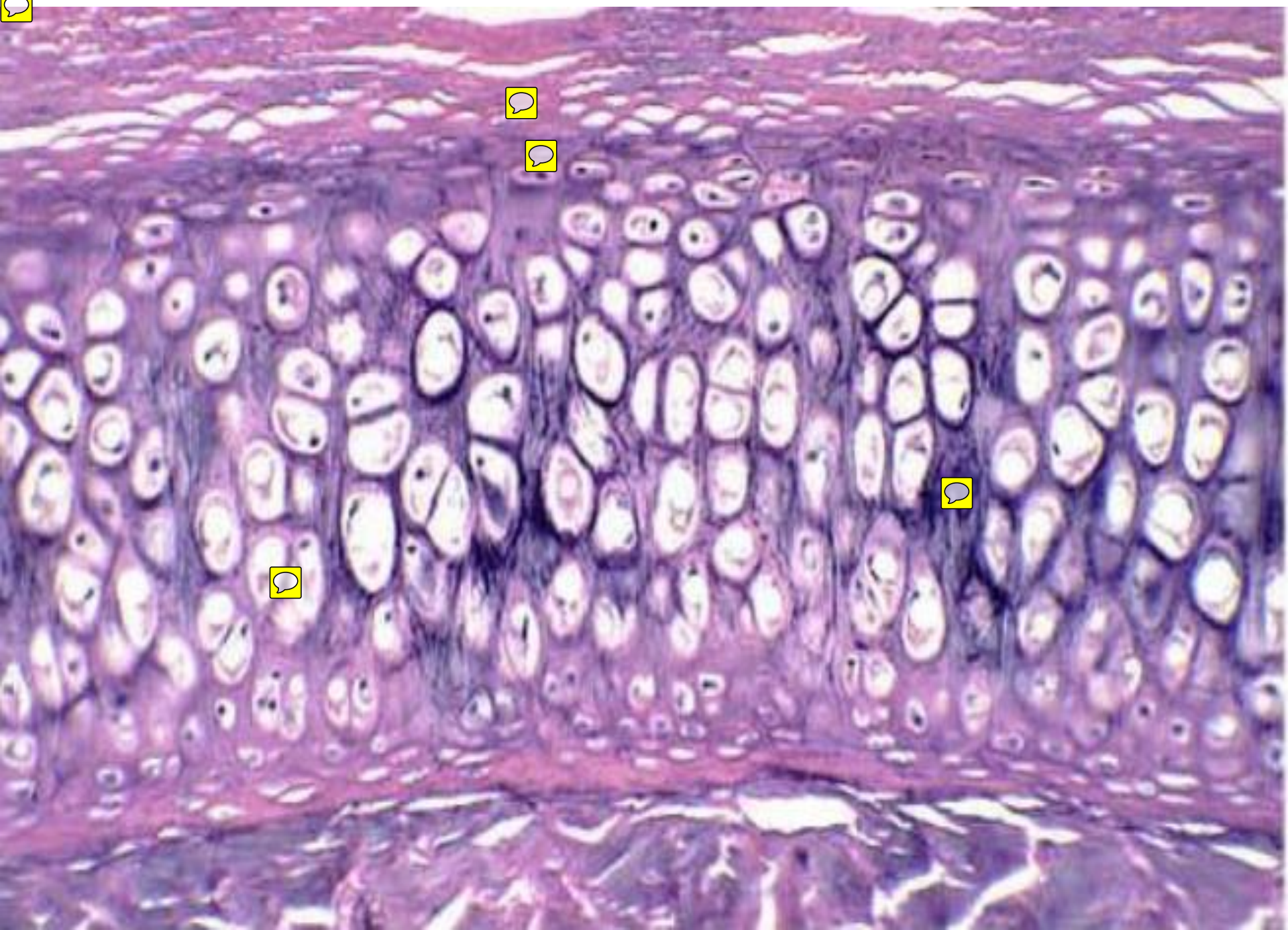




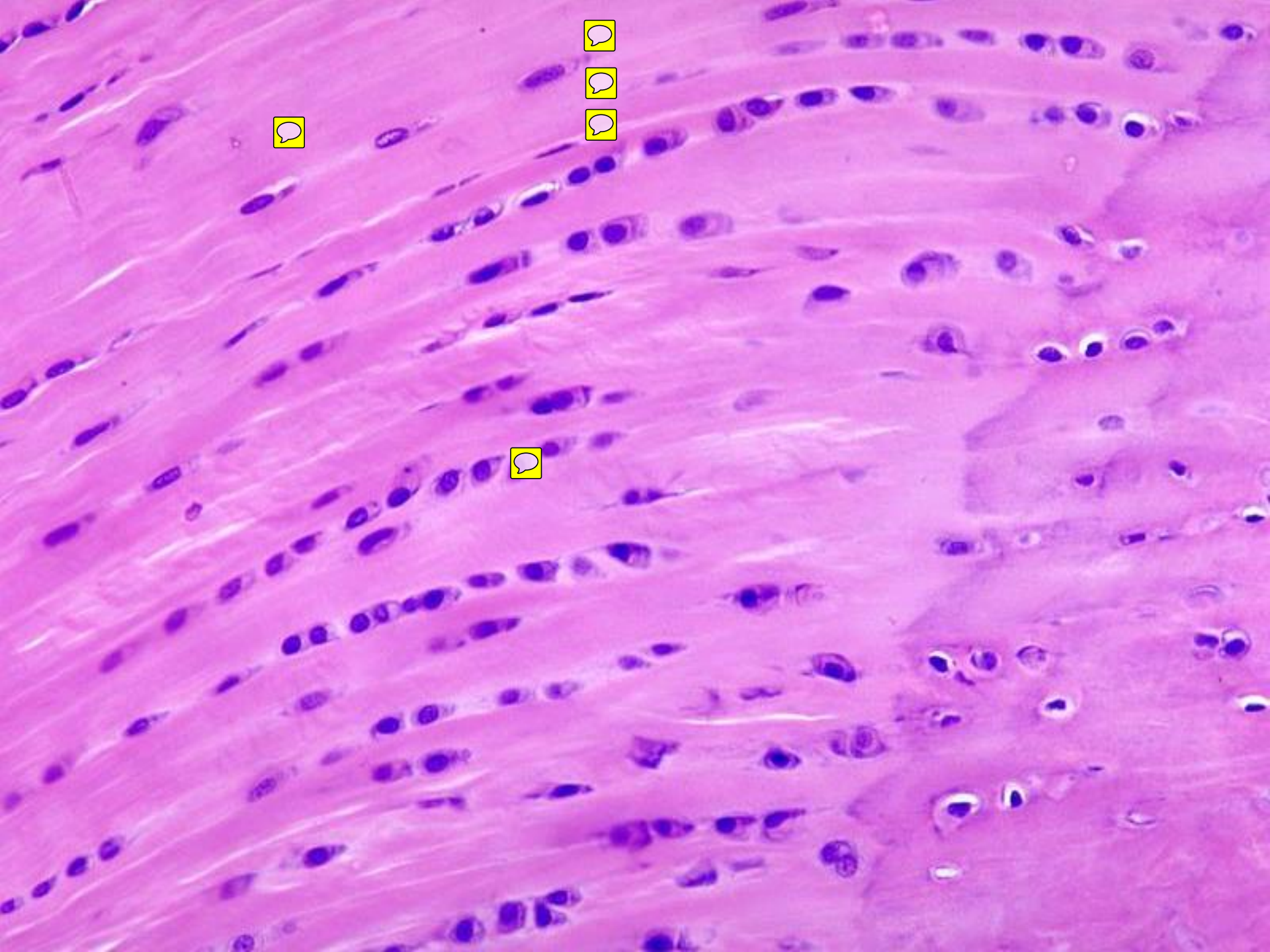




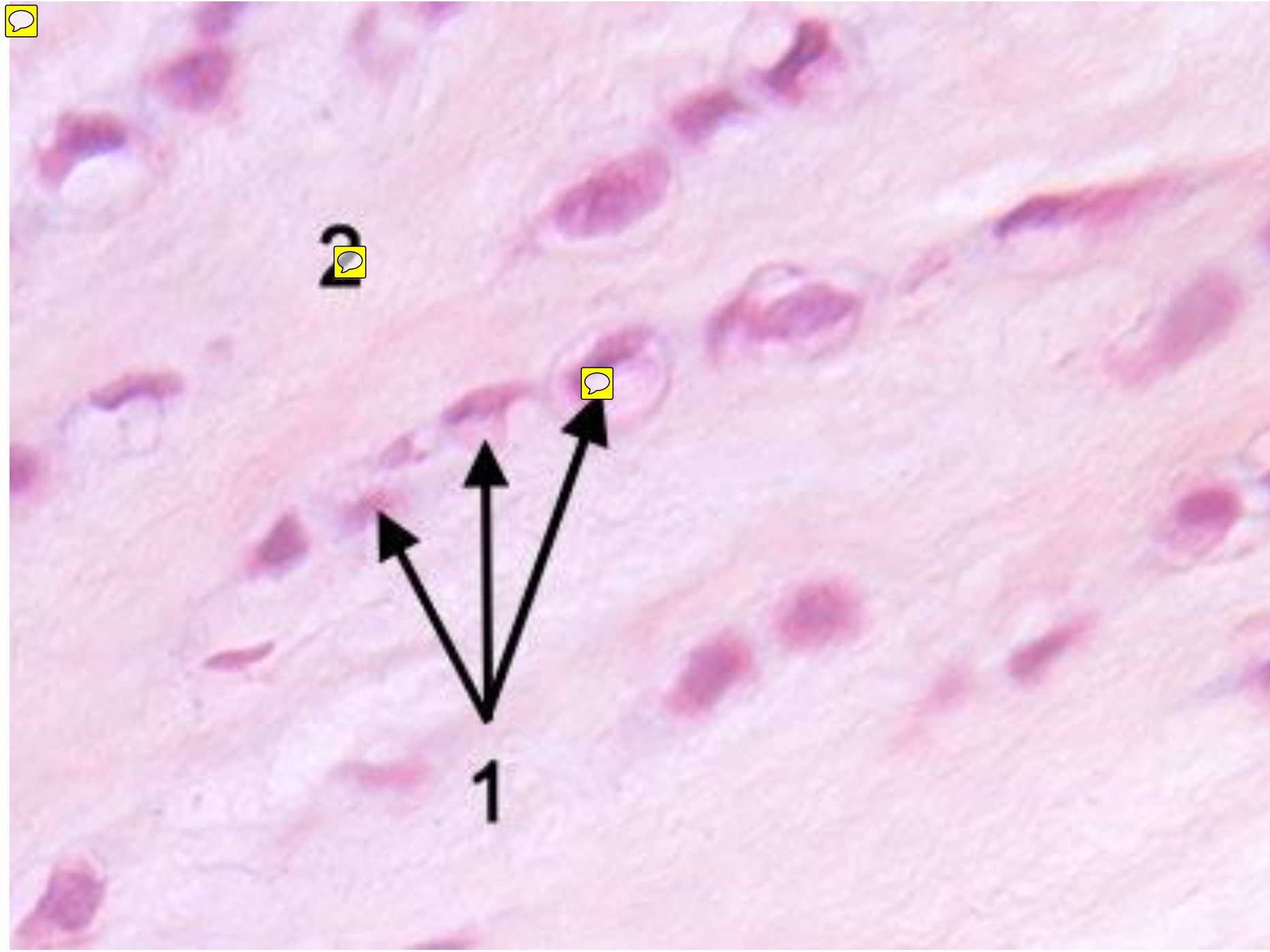












2

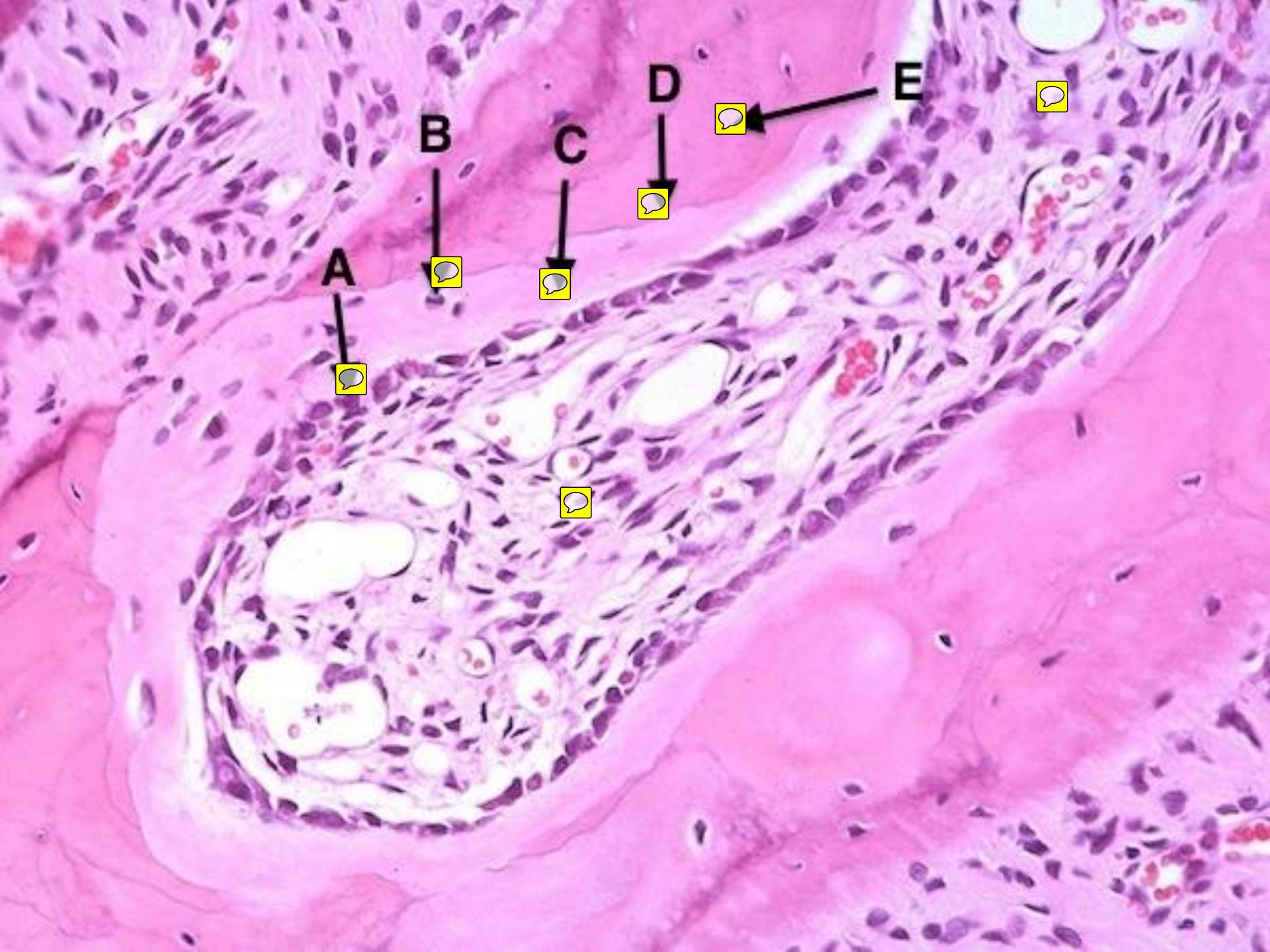


1

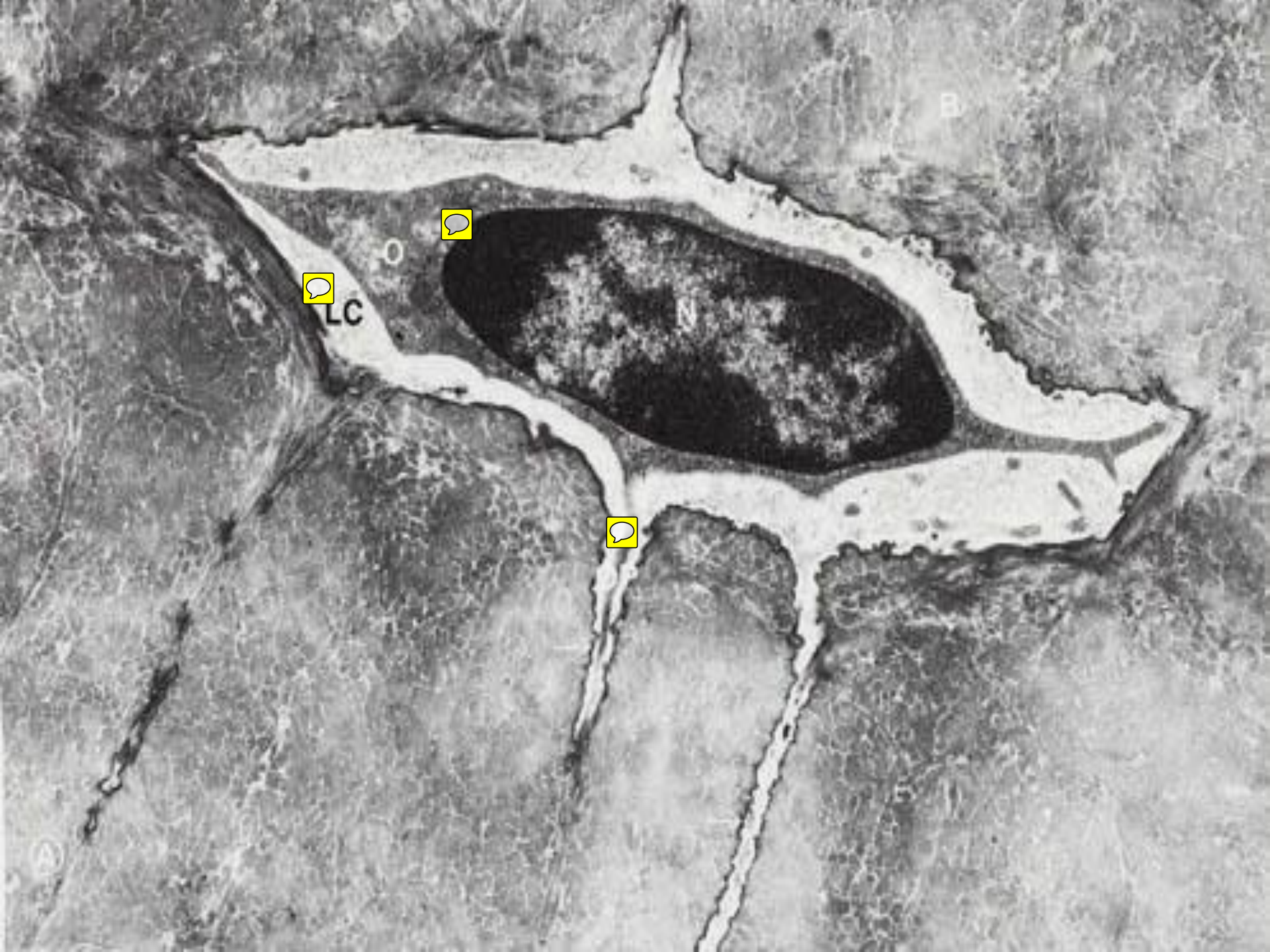


Bone

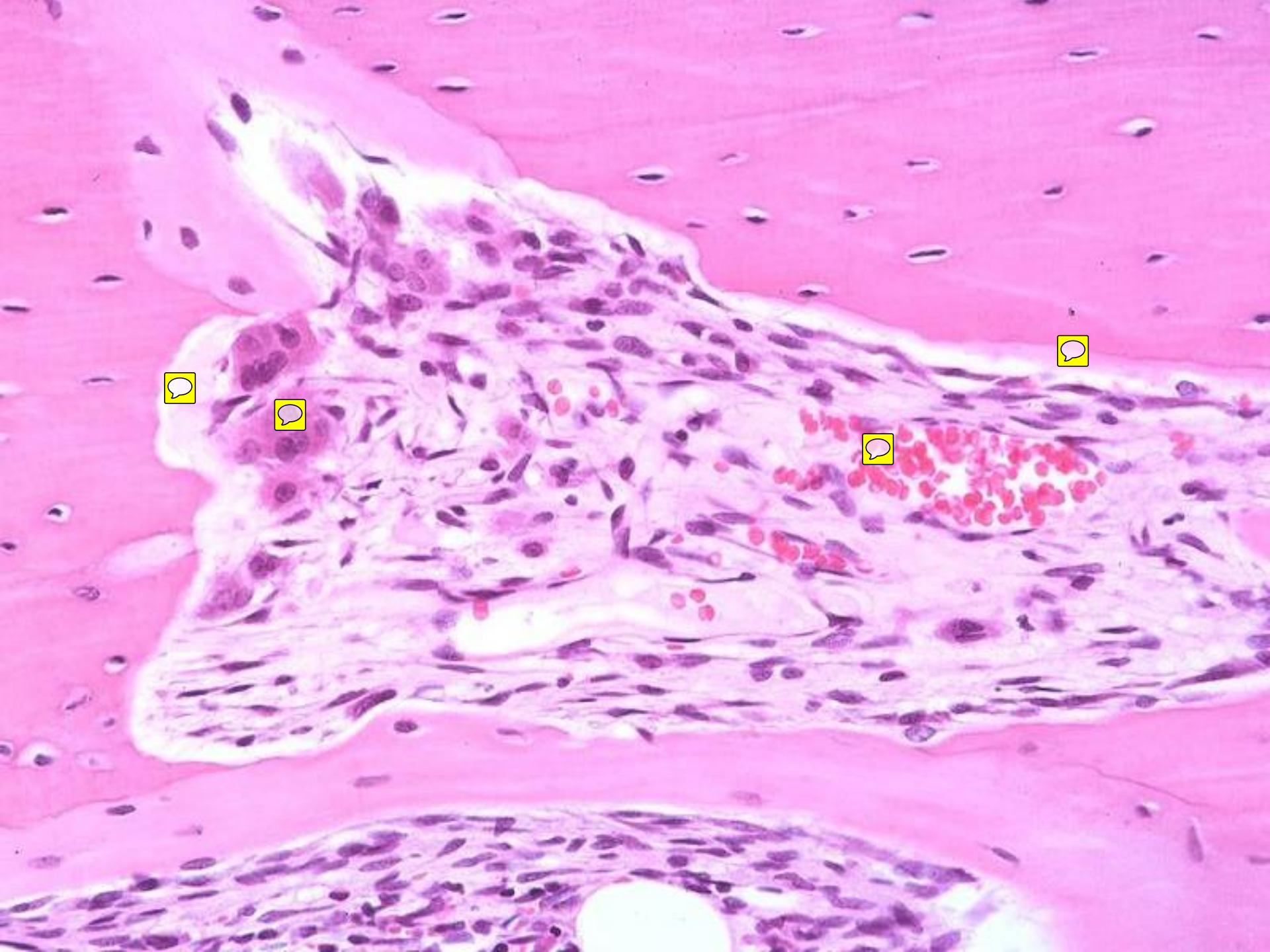




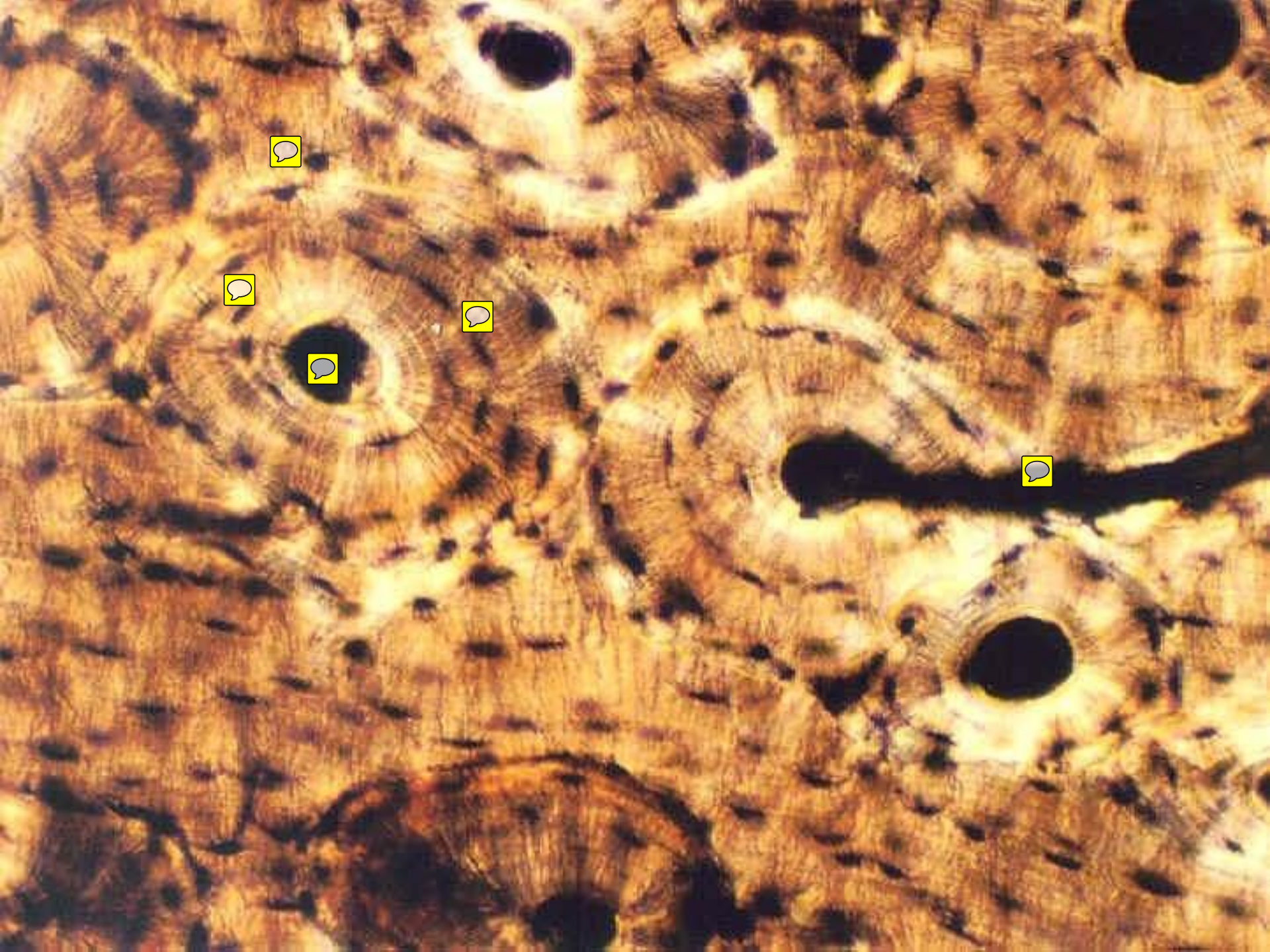




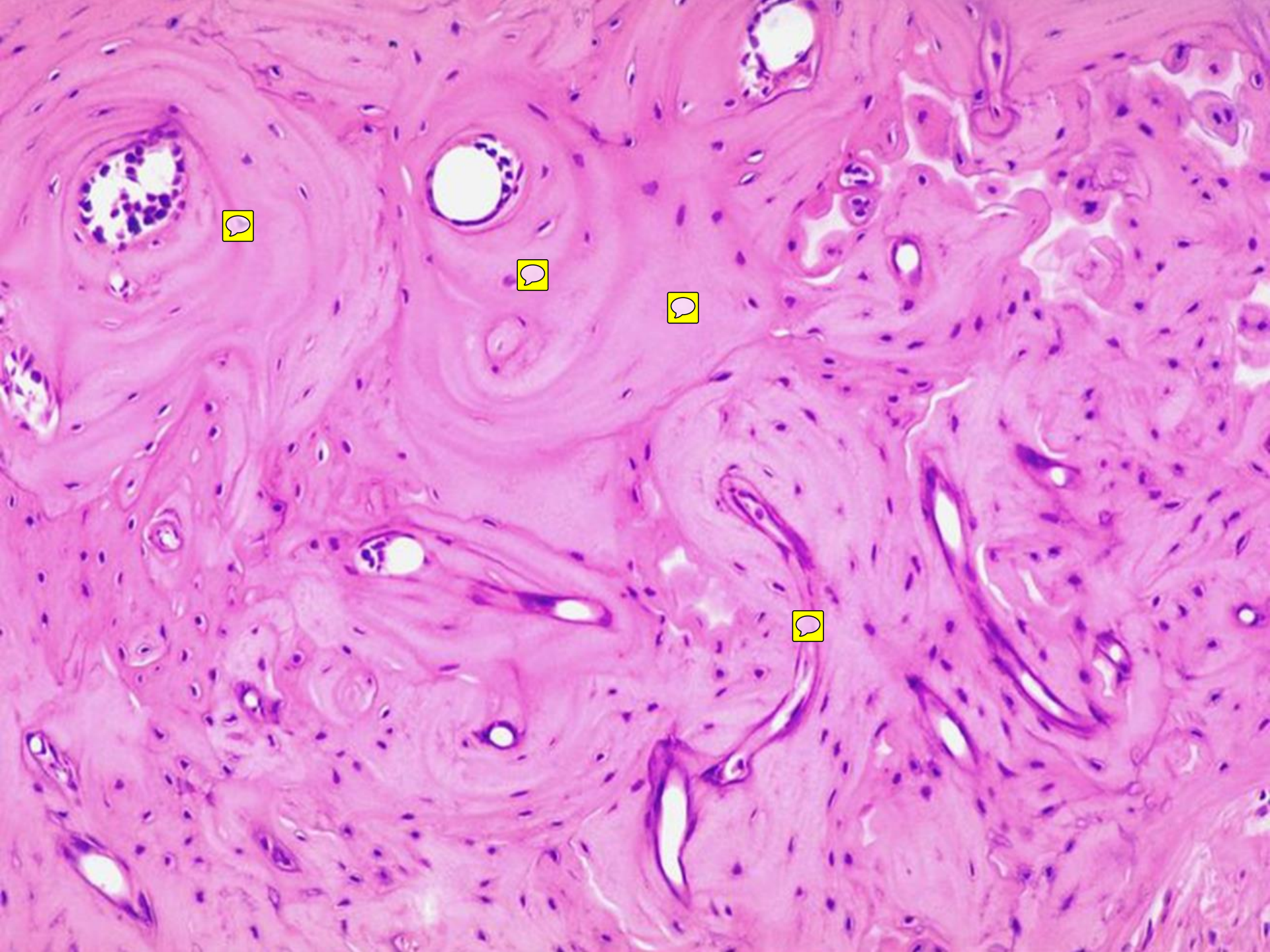




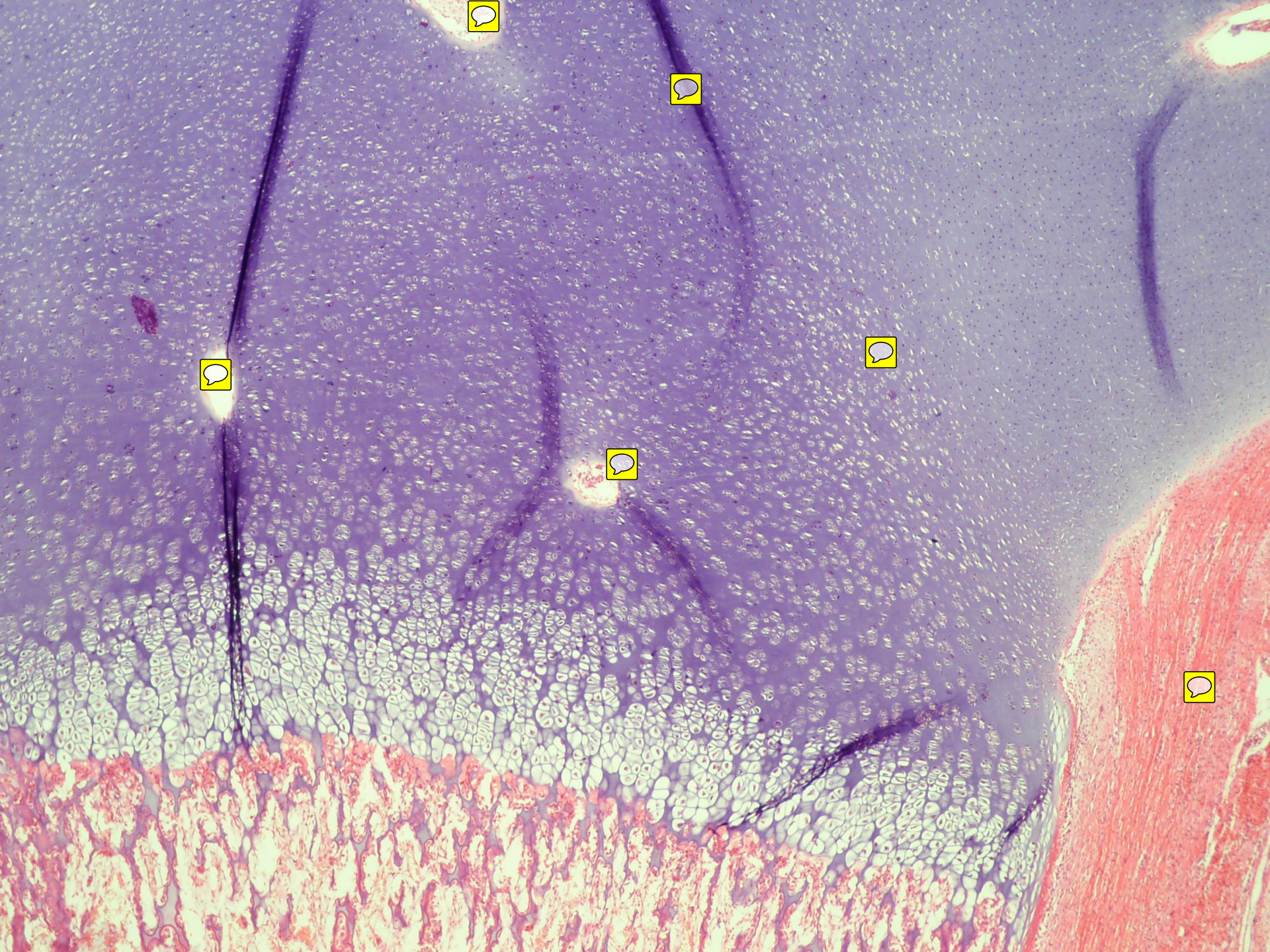




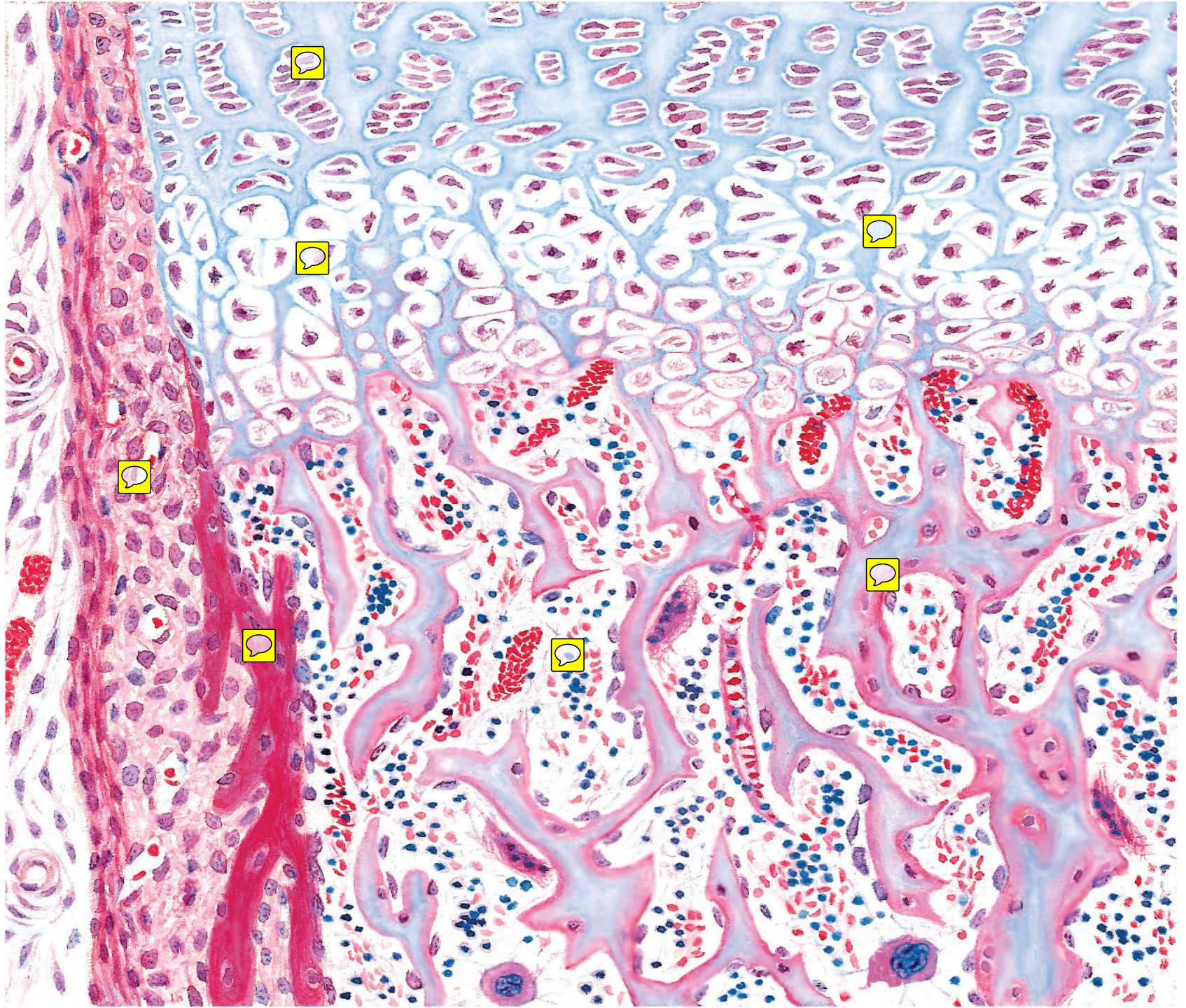




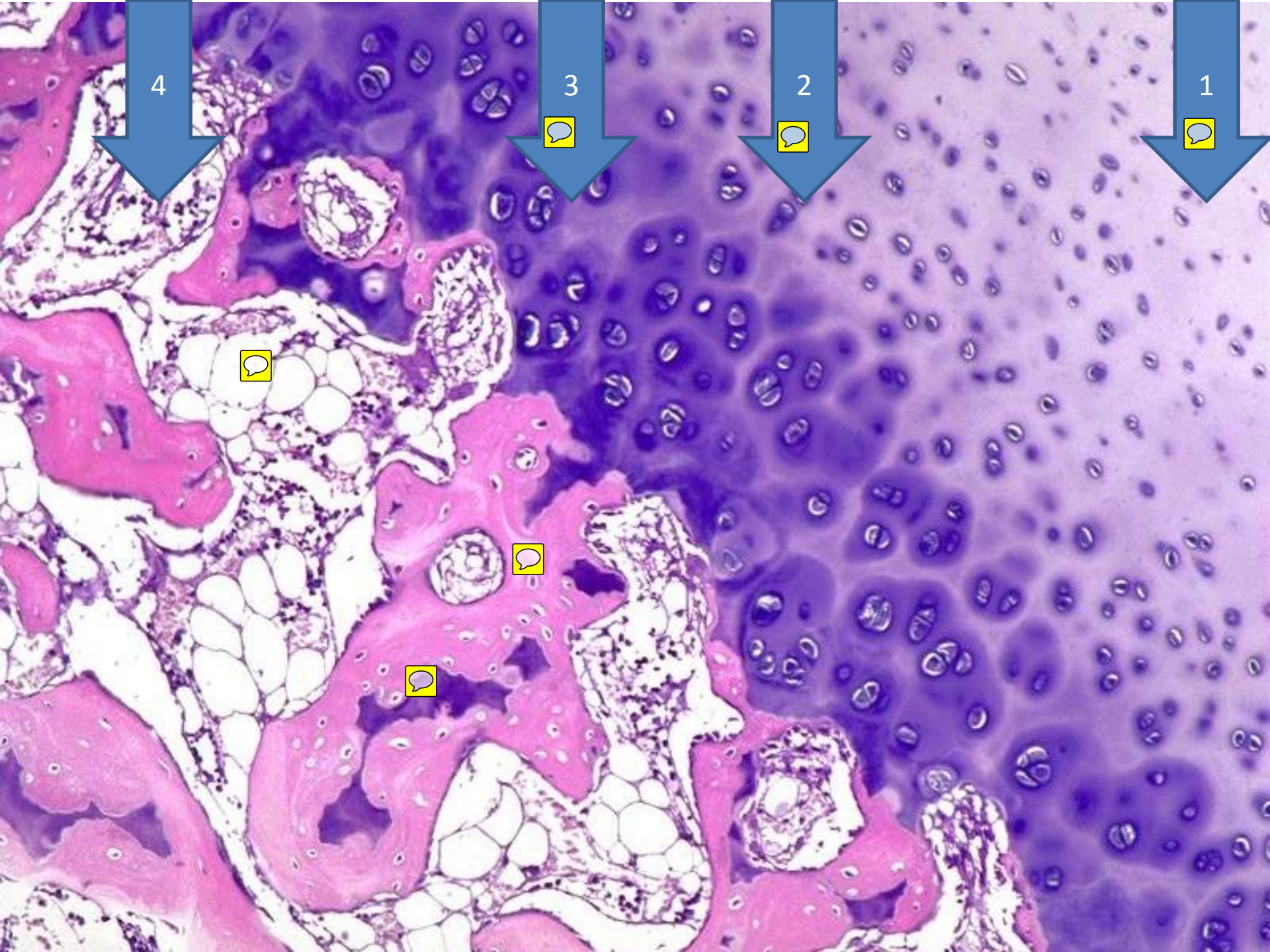




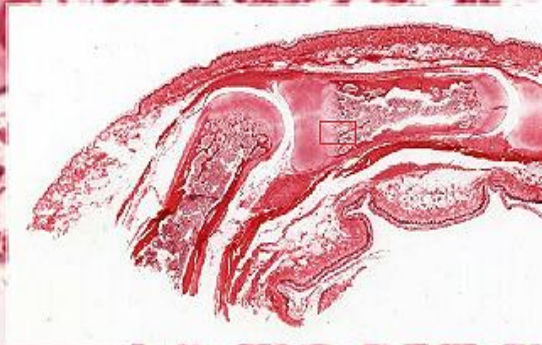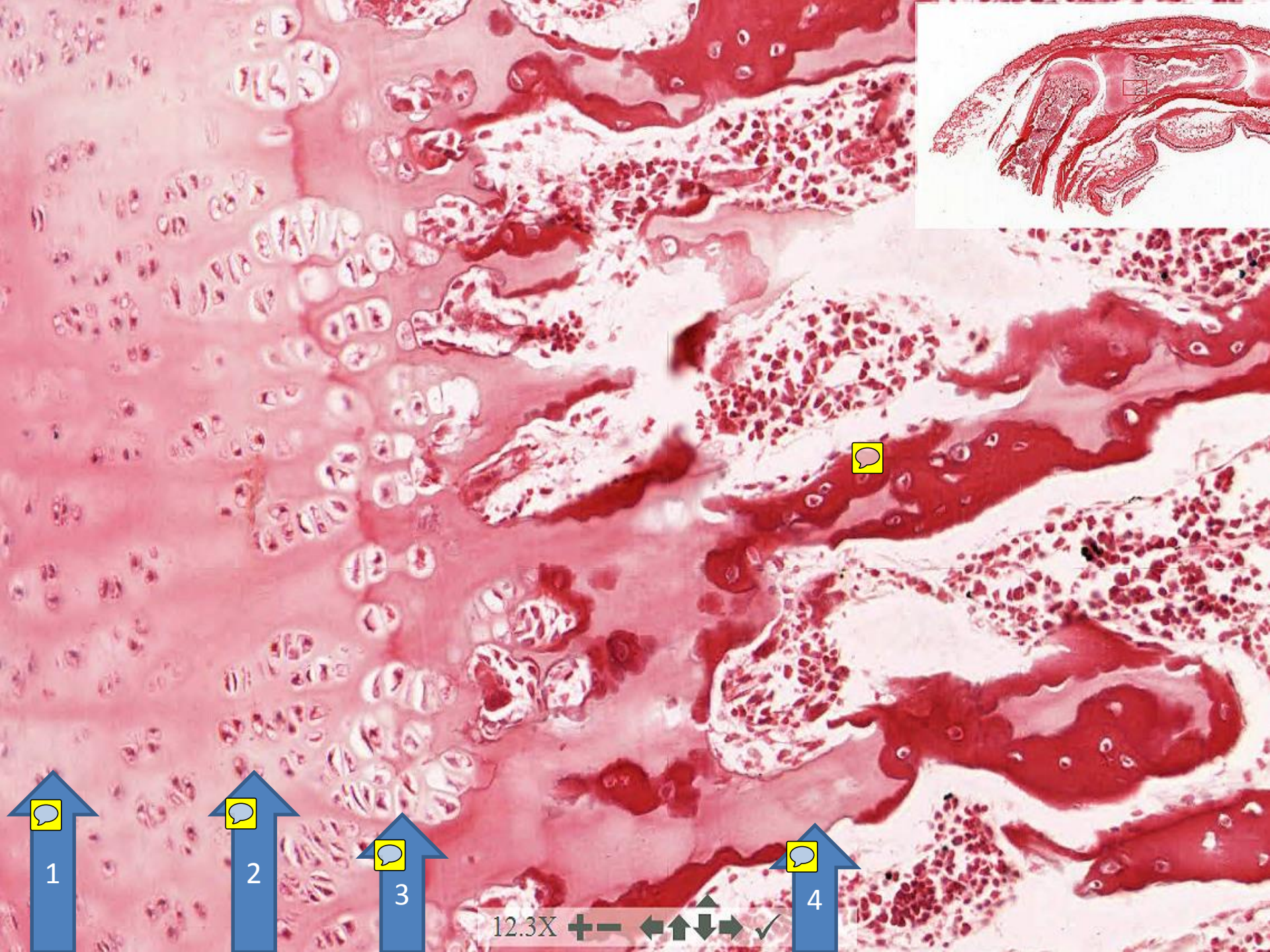












1



2



3

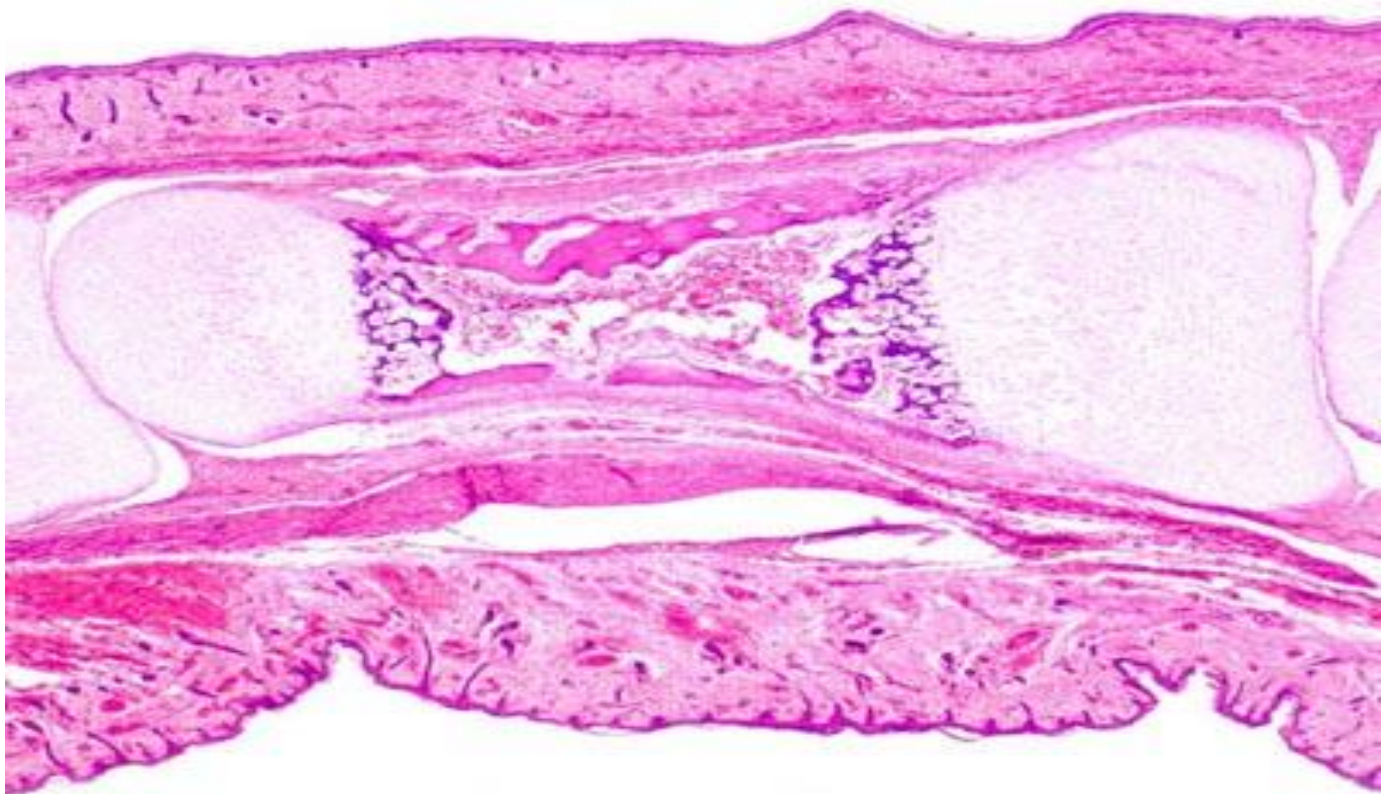


4

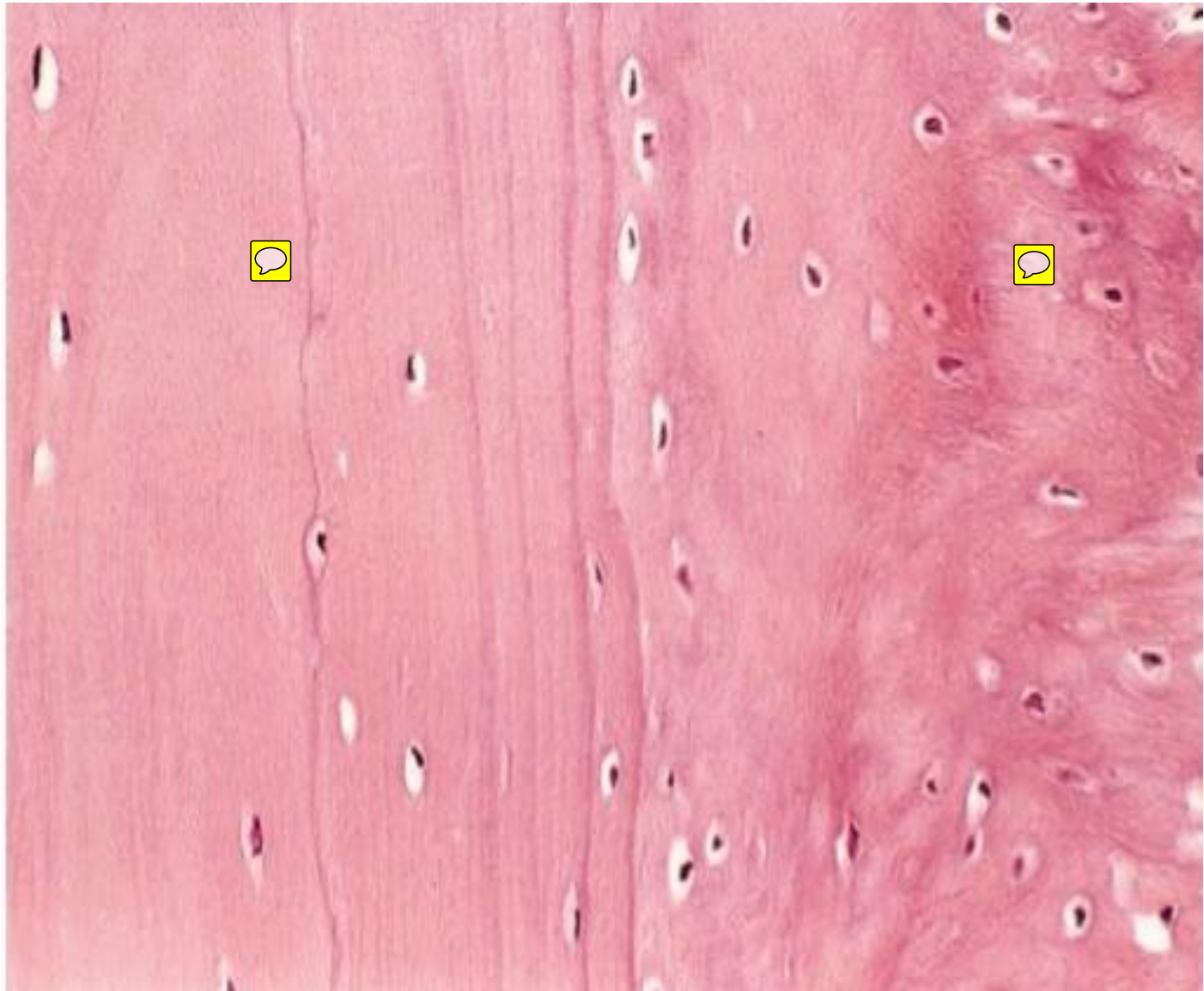
12.3X



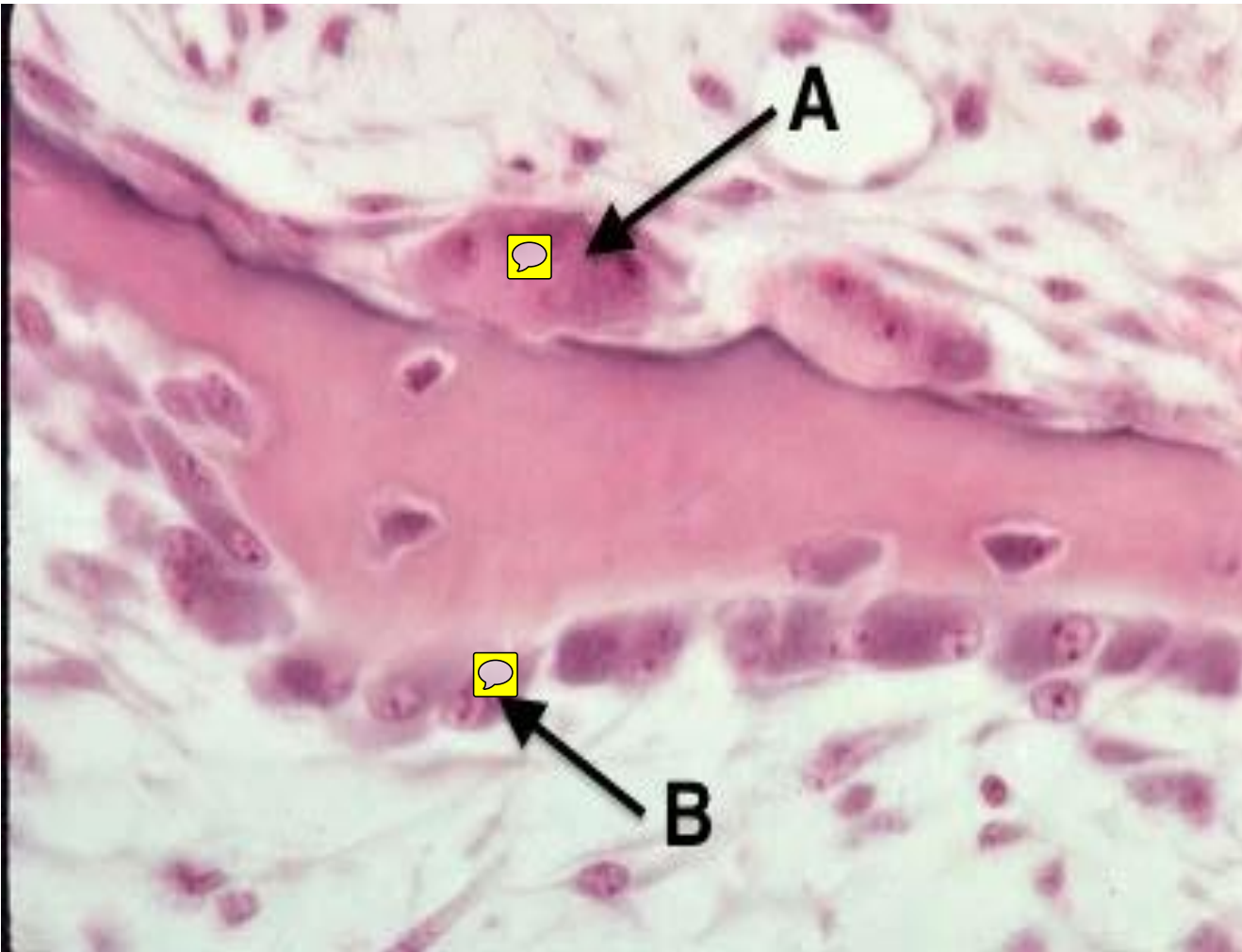








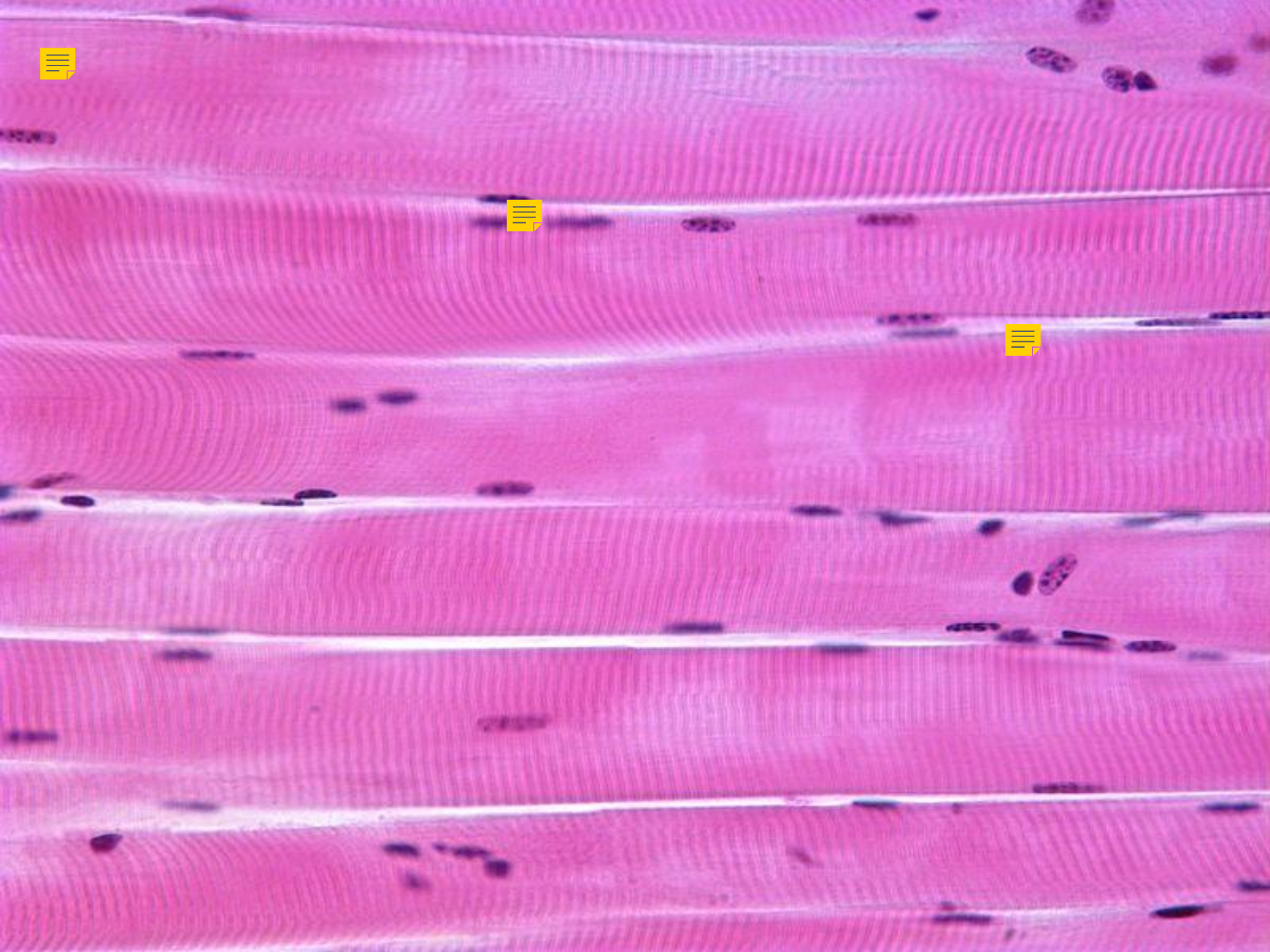




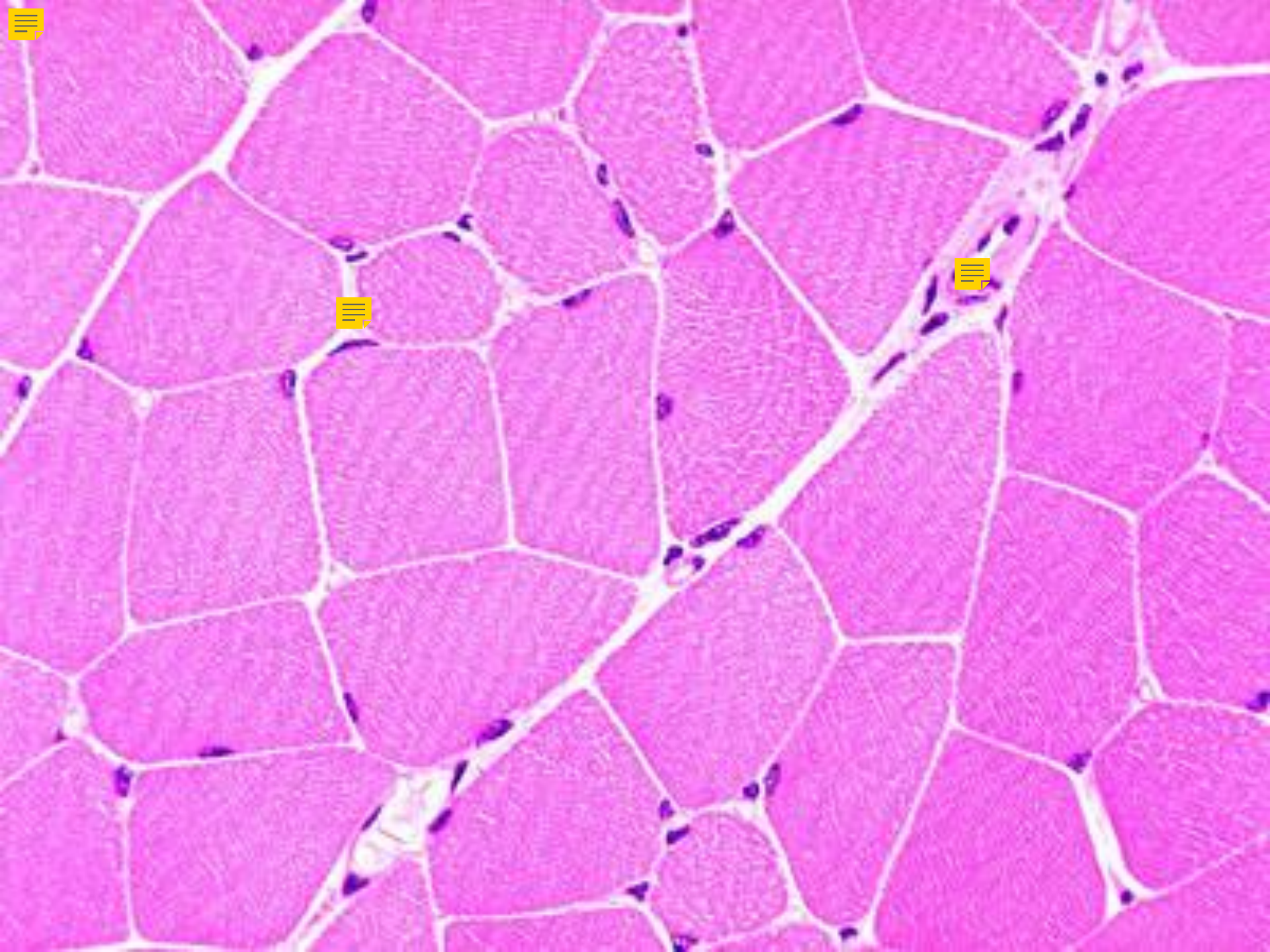


Muscle

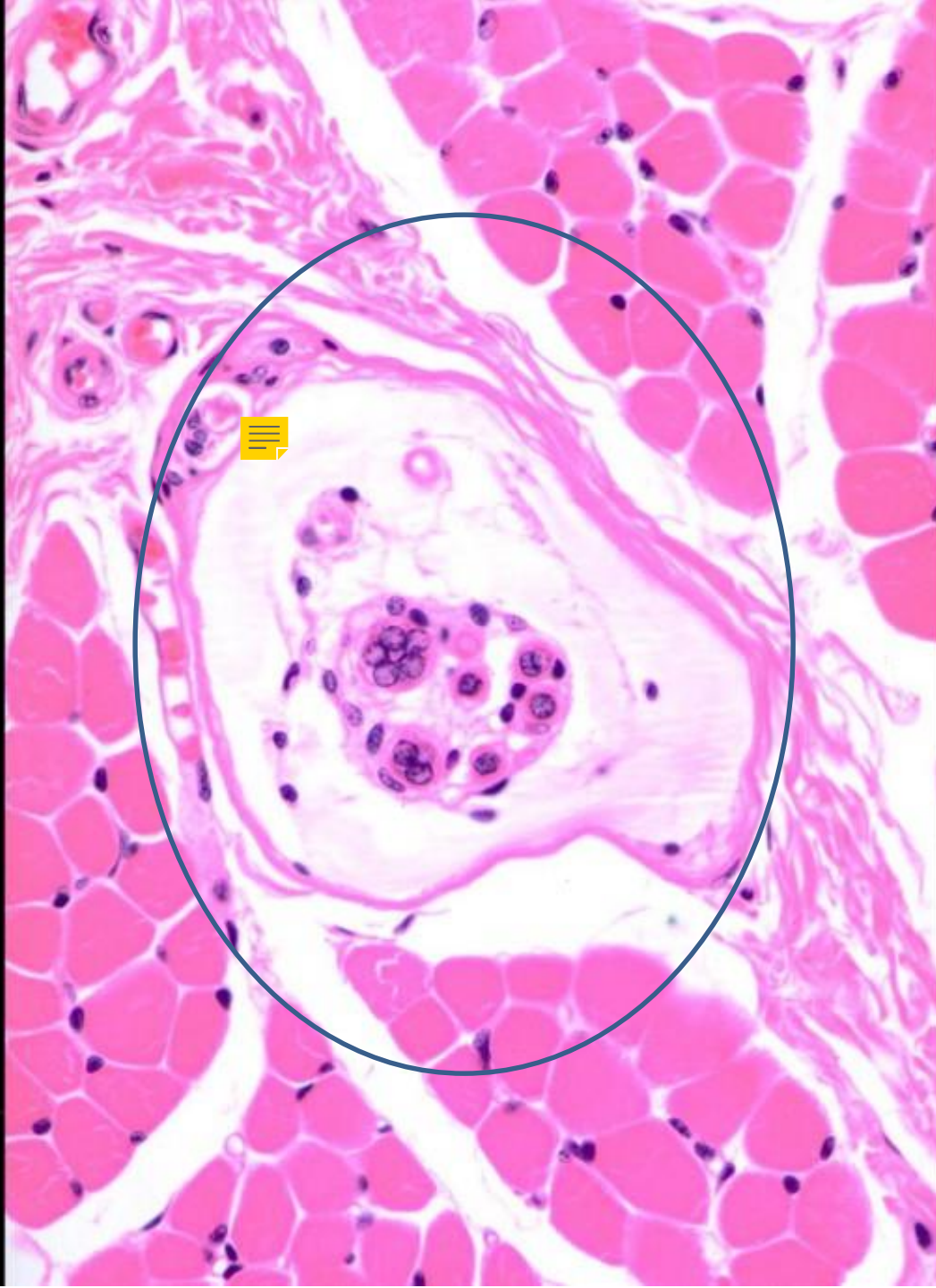









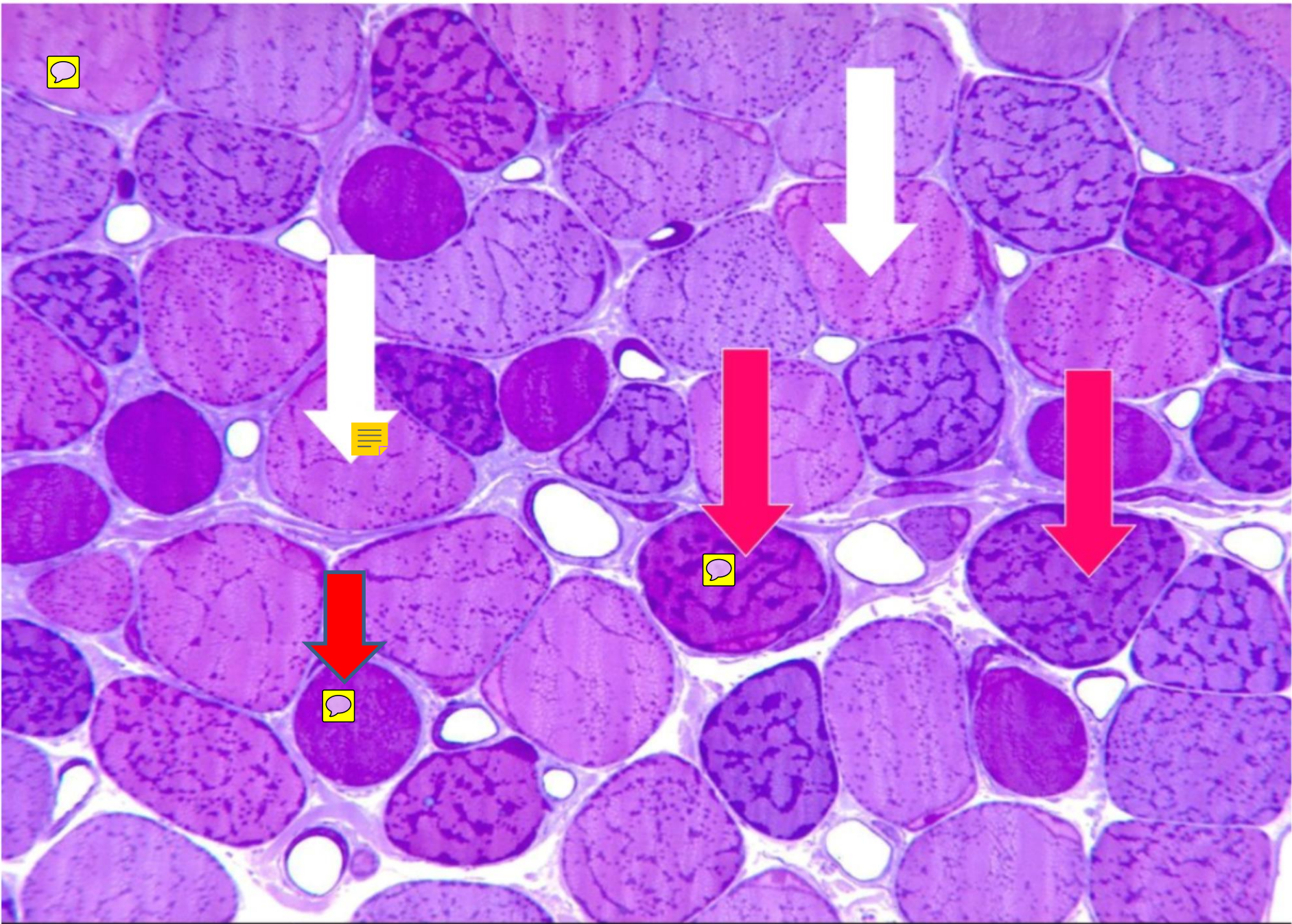




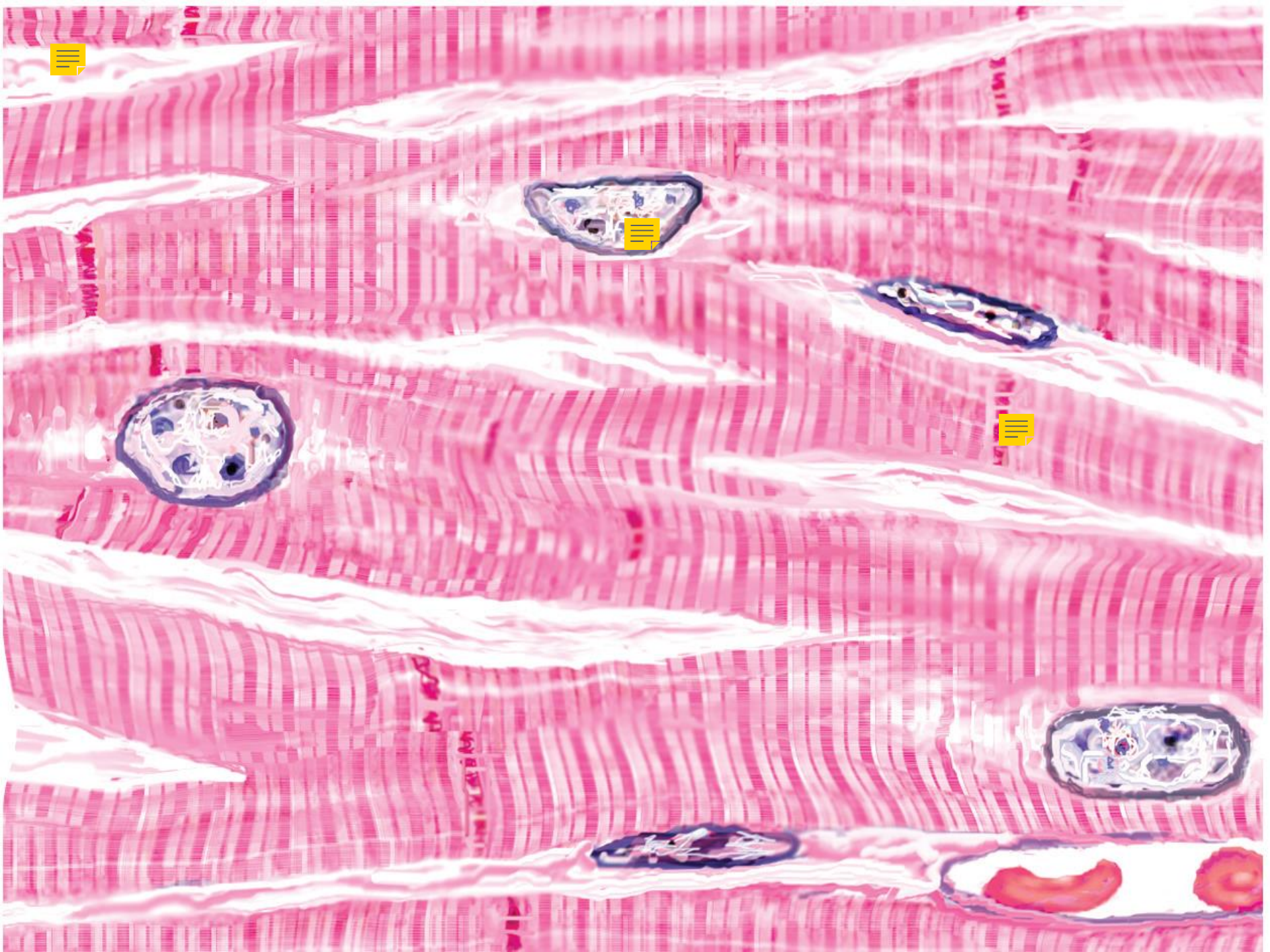




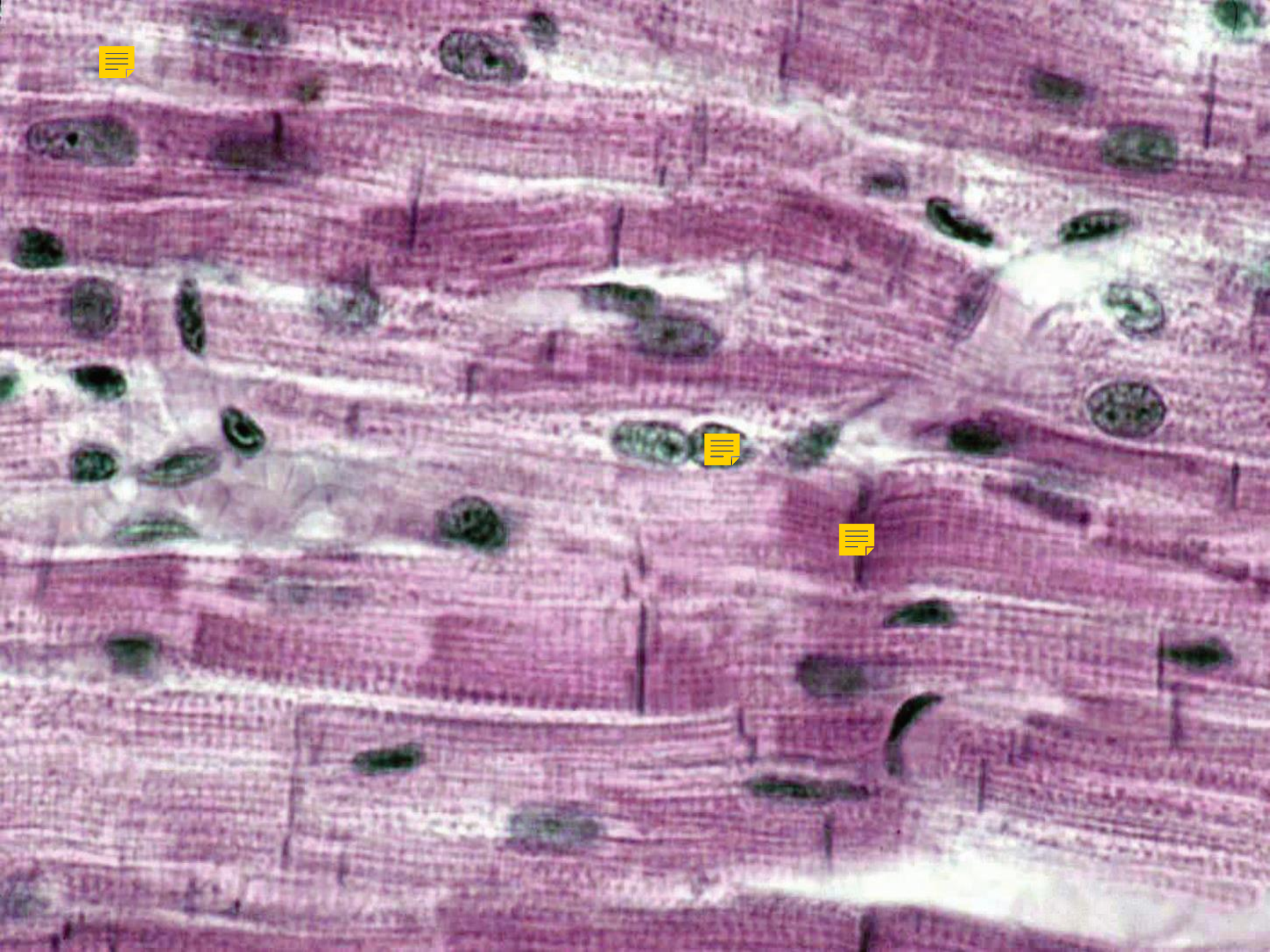




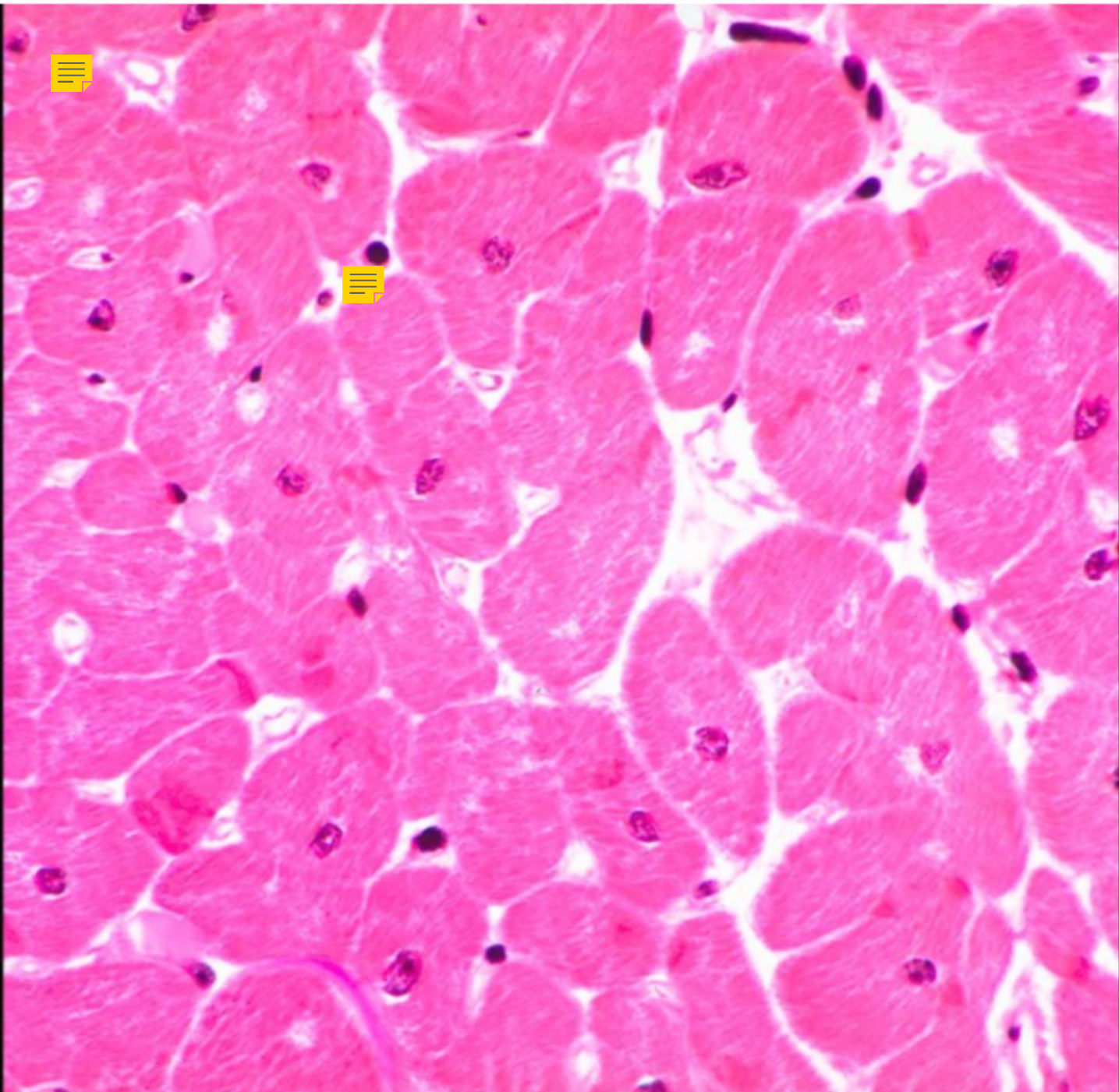




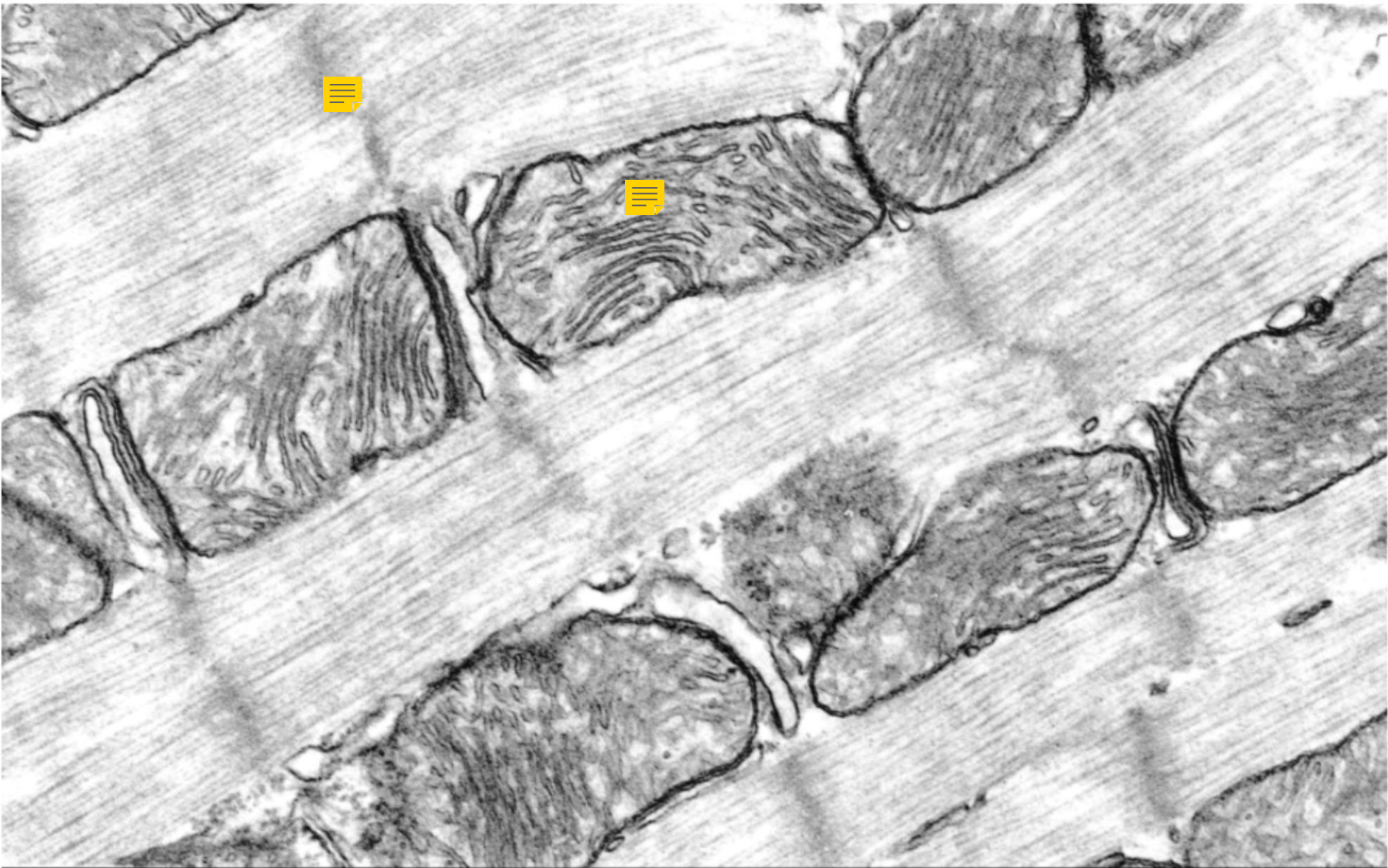




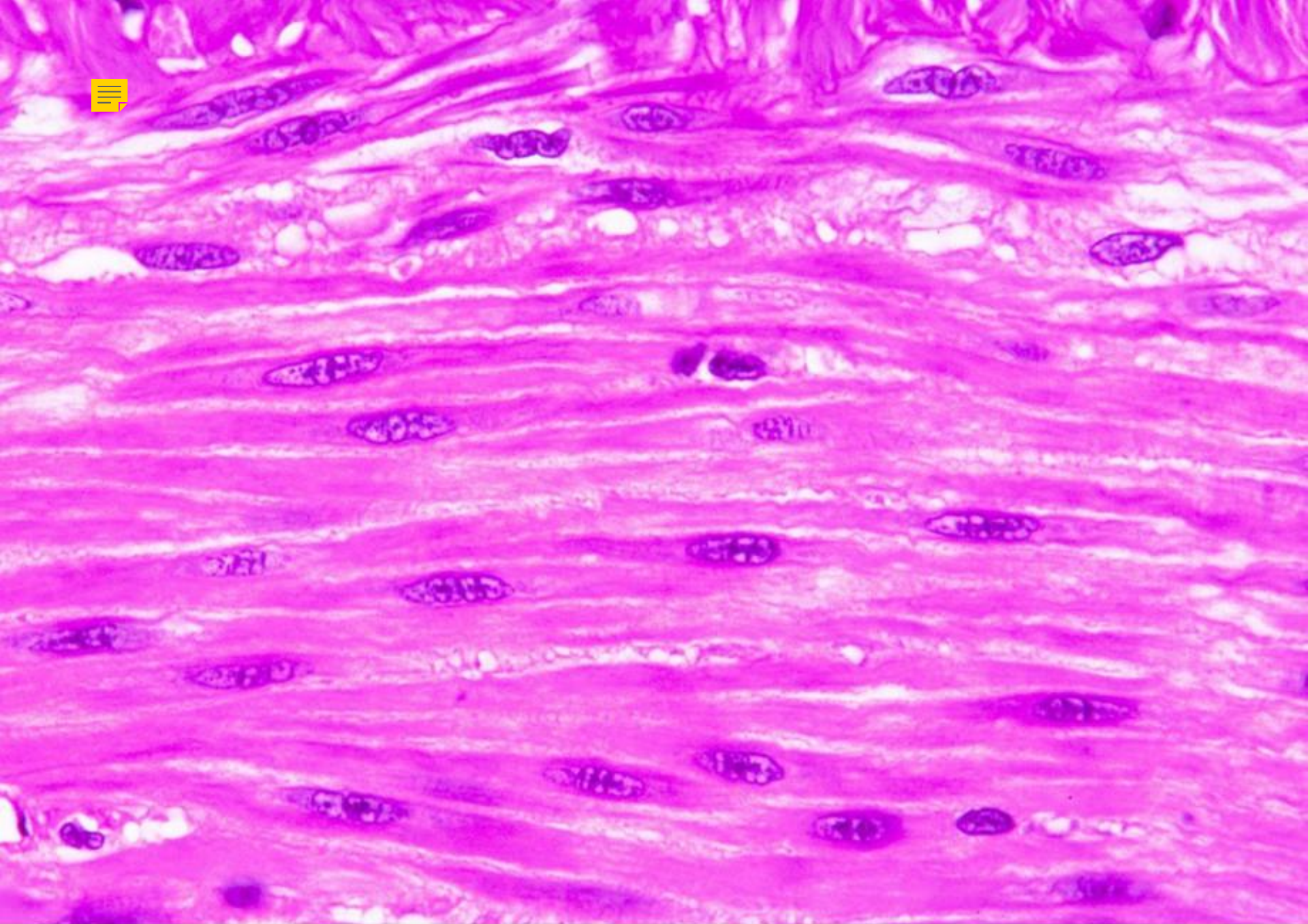




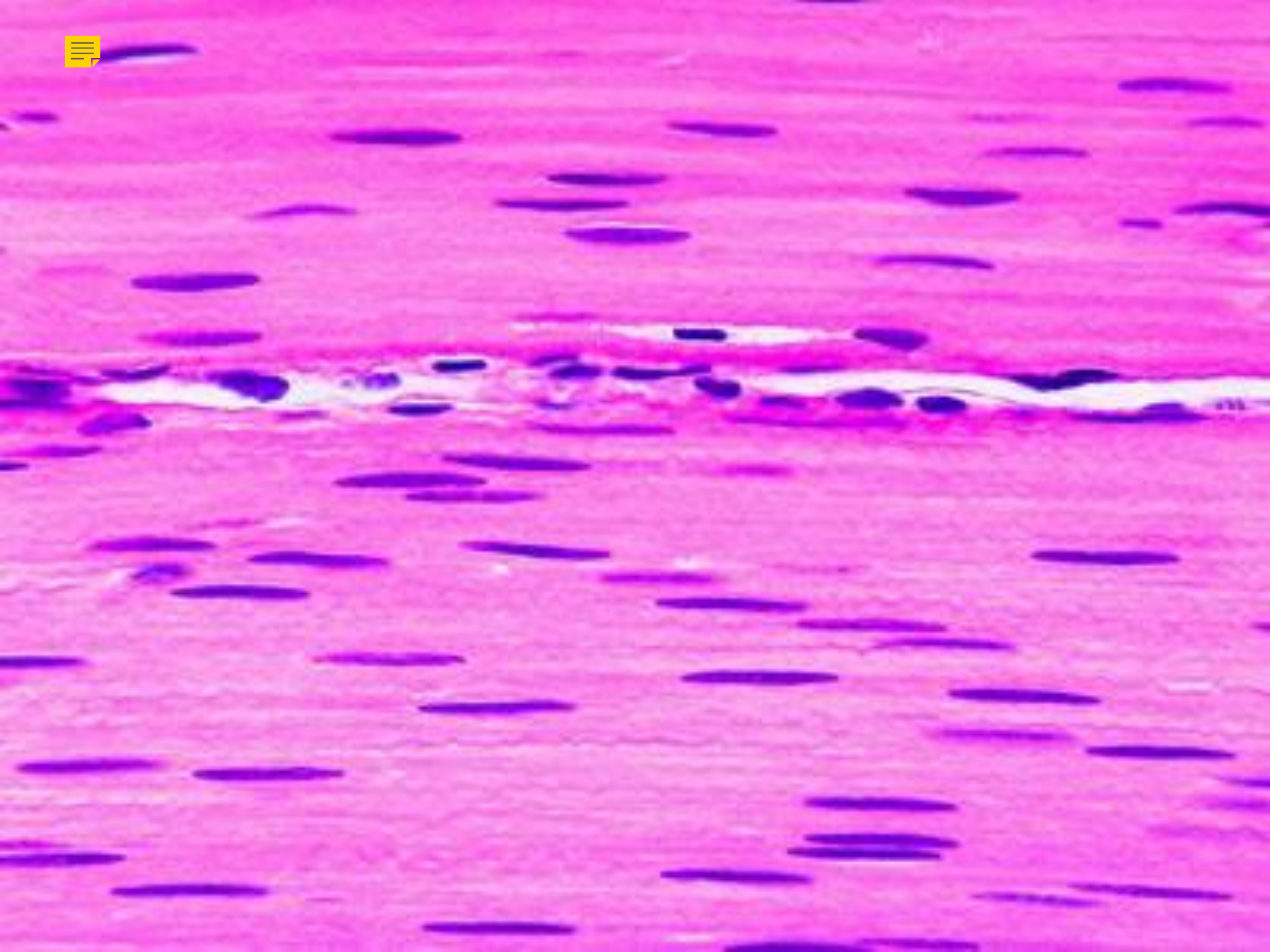




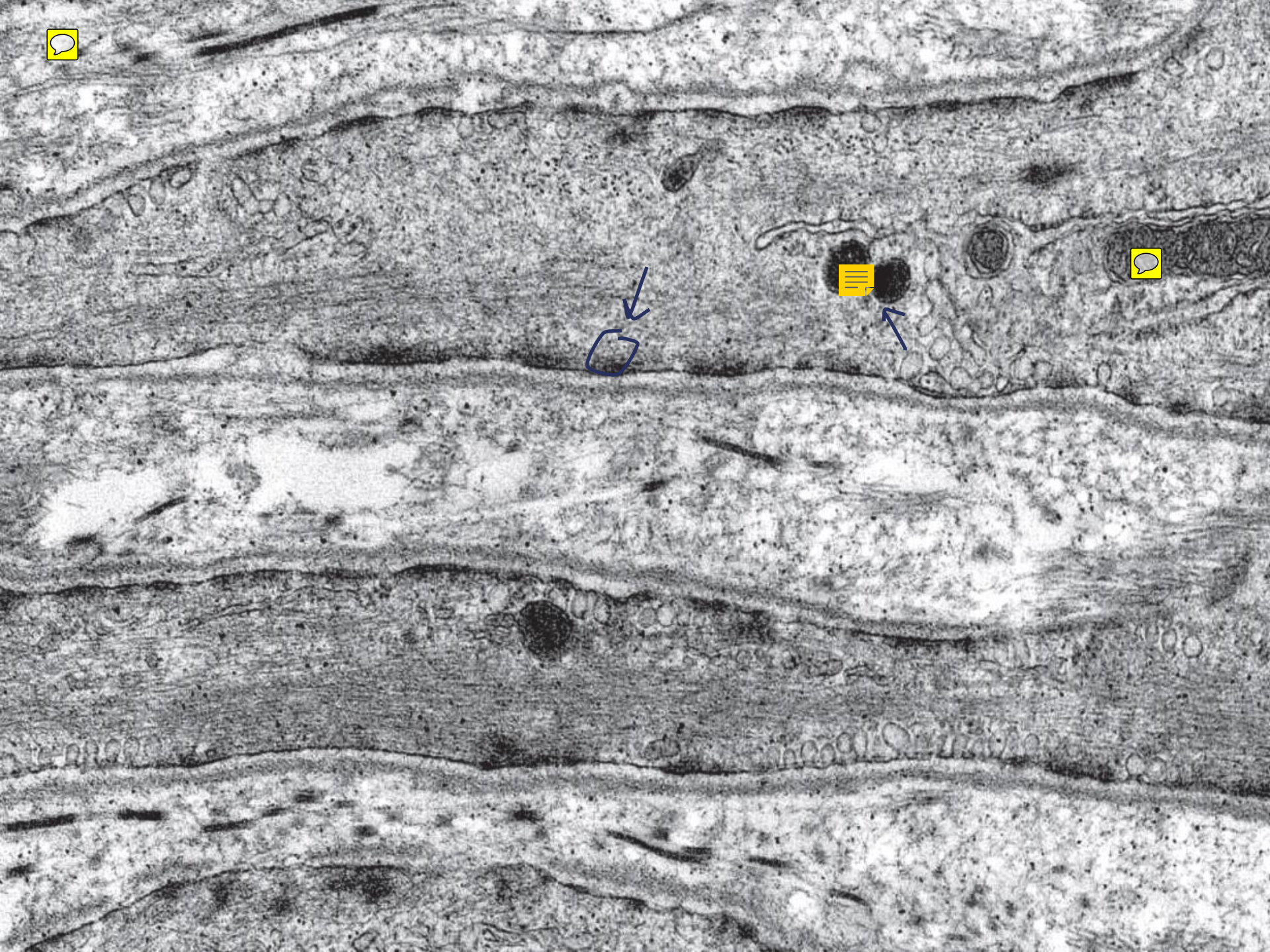








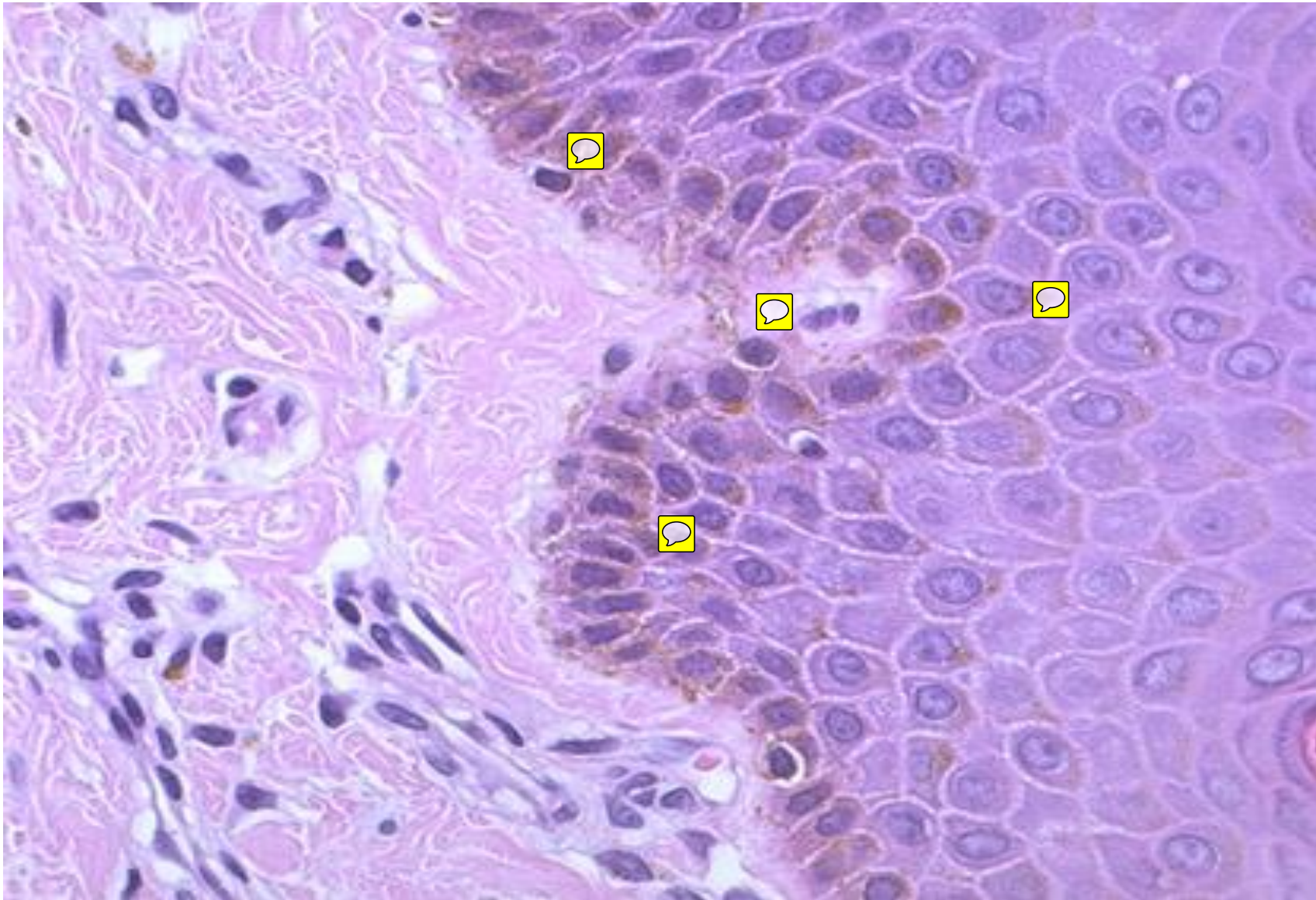






Skin









C

L



G

S

