

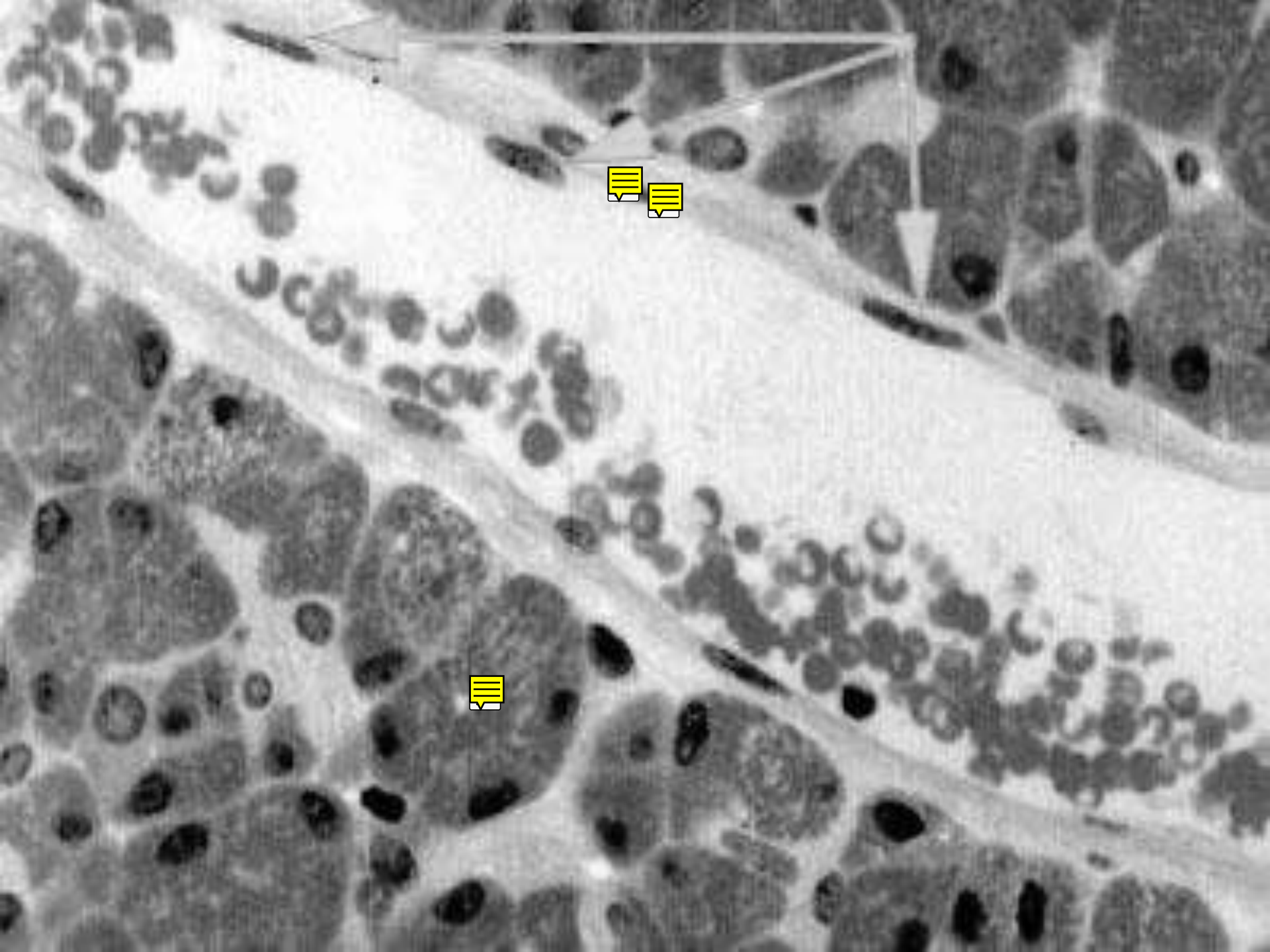
# Sections for practical exam


Introduction to Histology Course

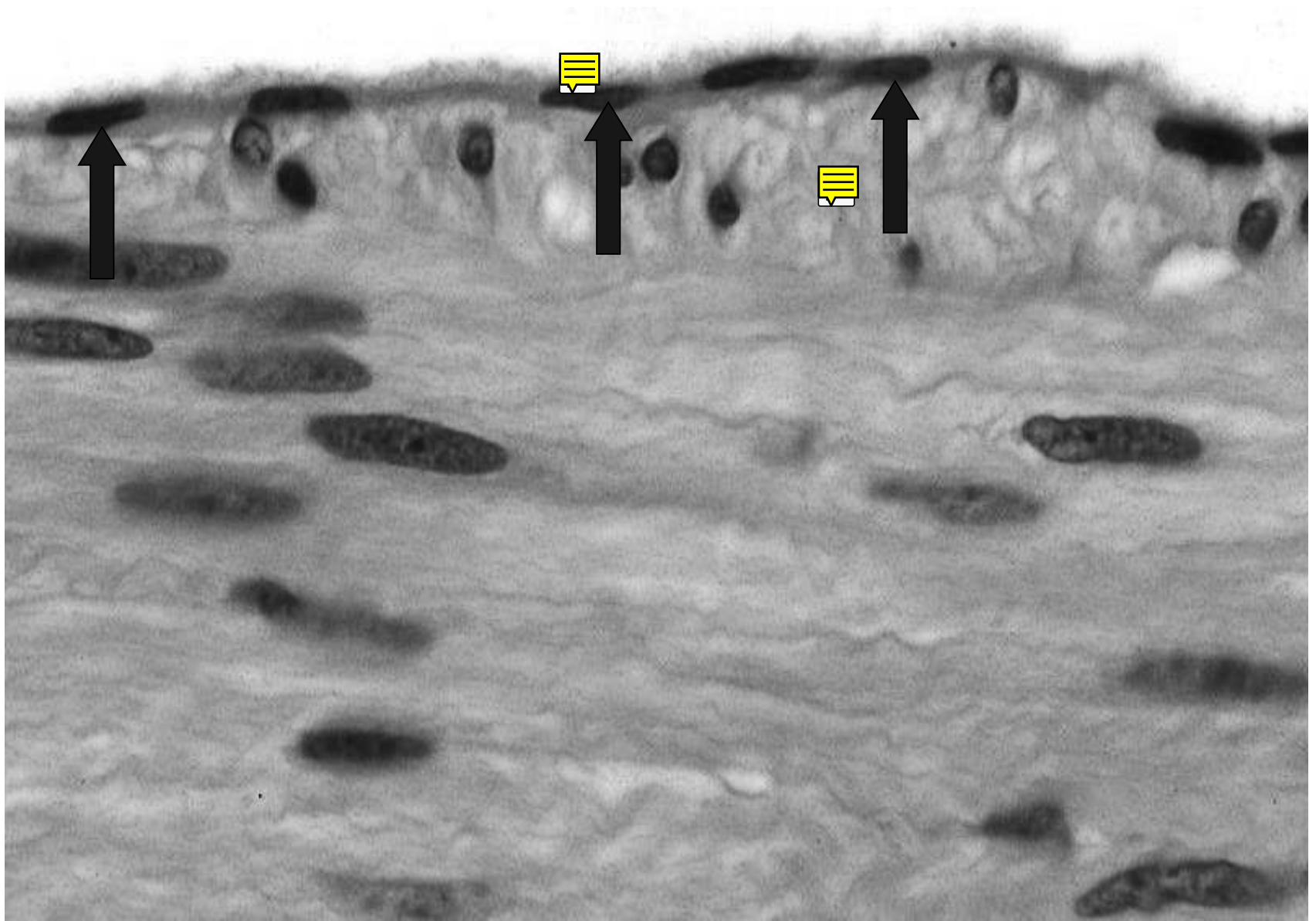
First year Medical Students

2015/2016

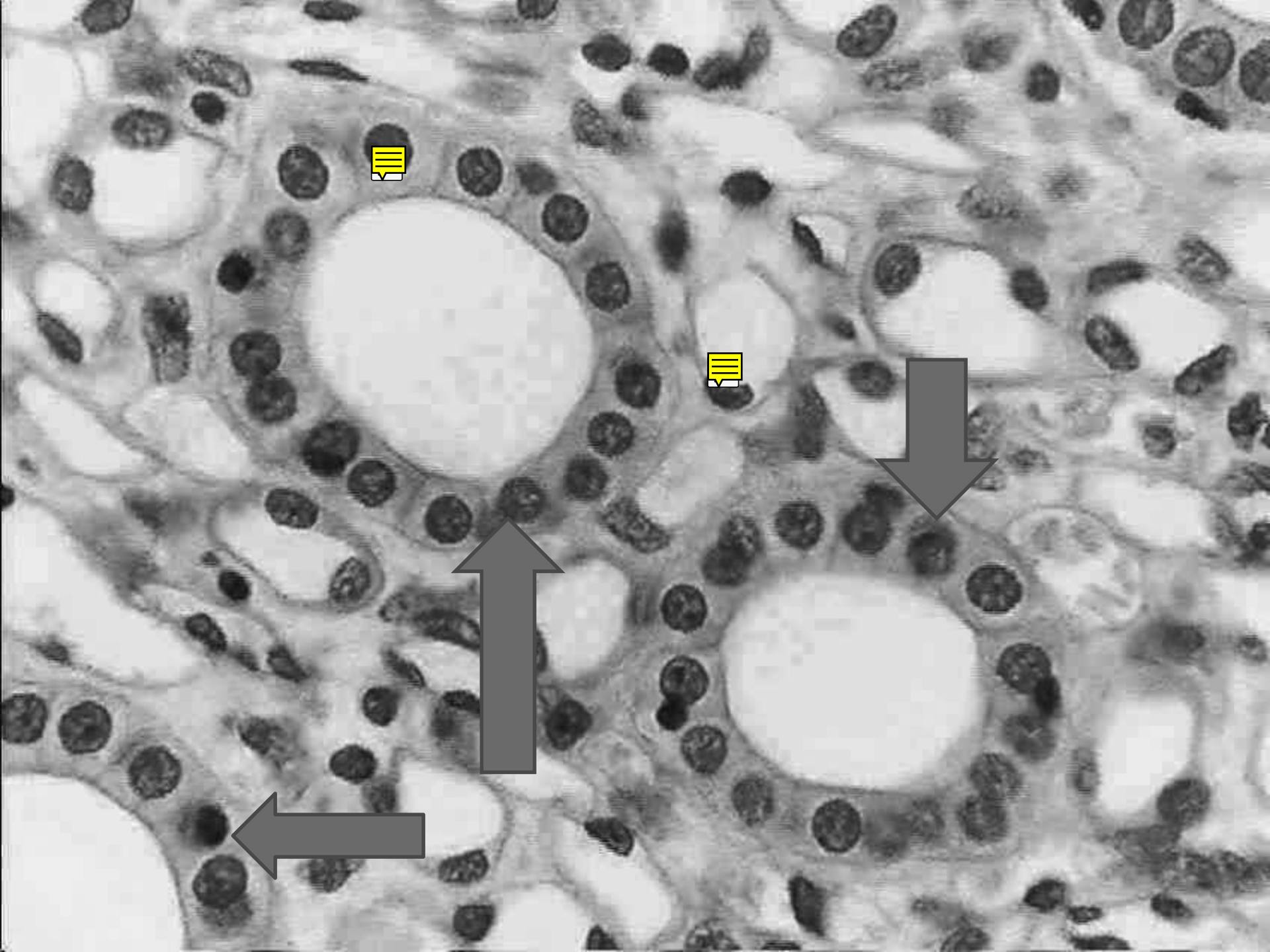
Epithelium

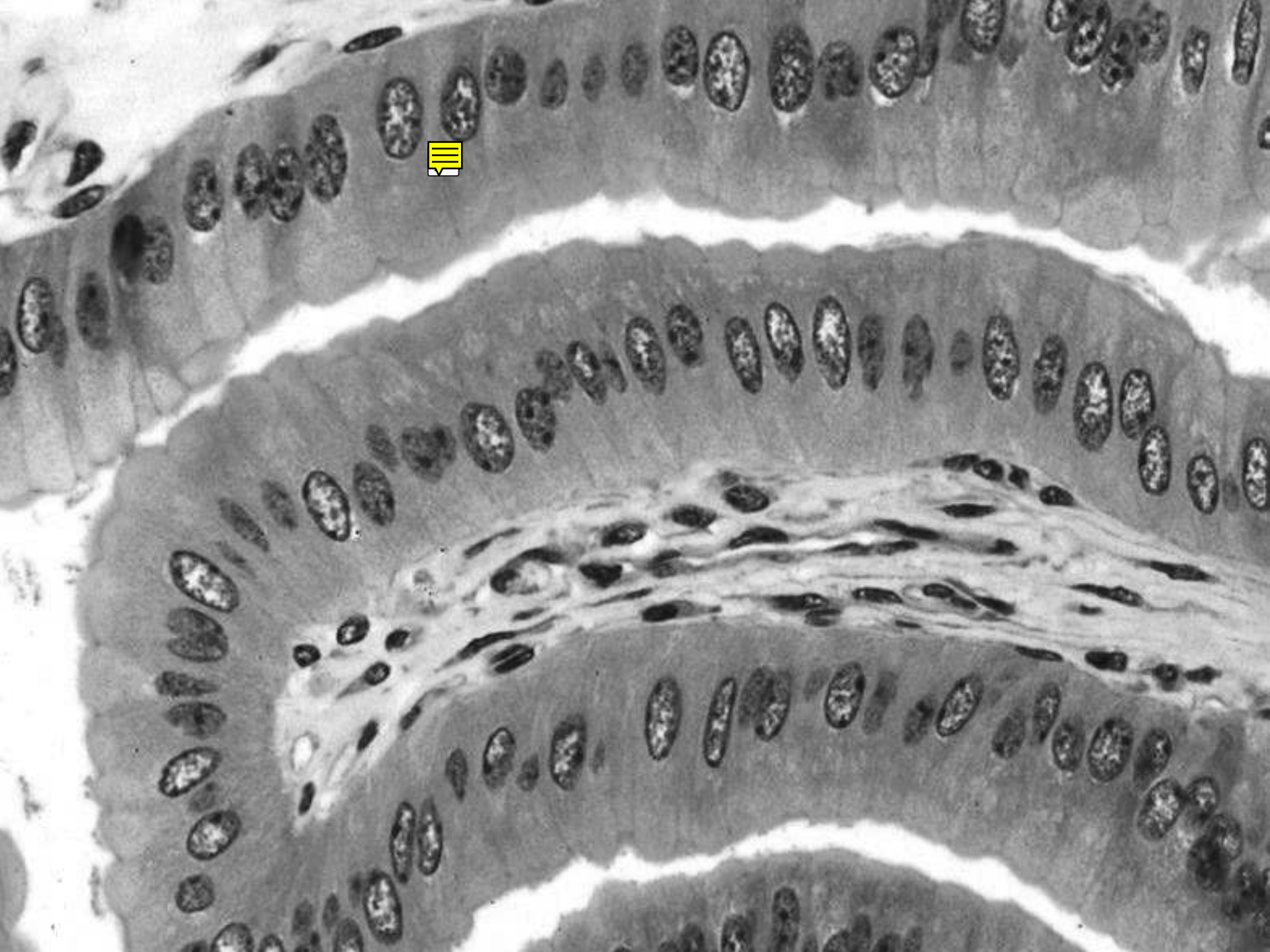




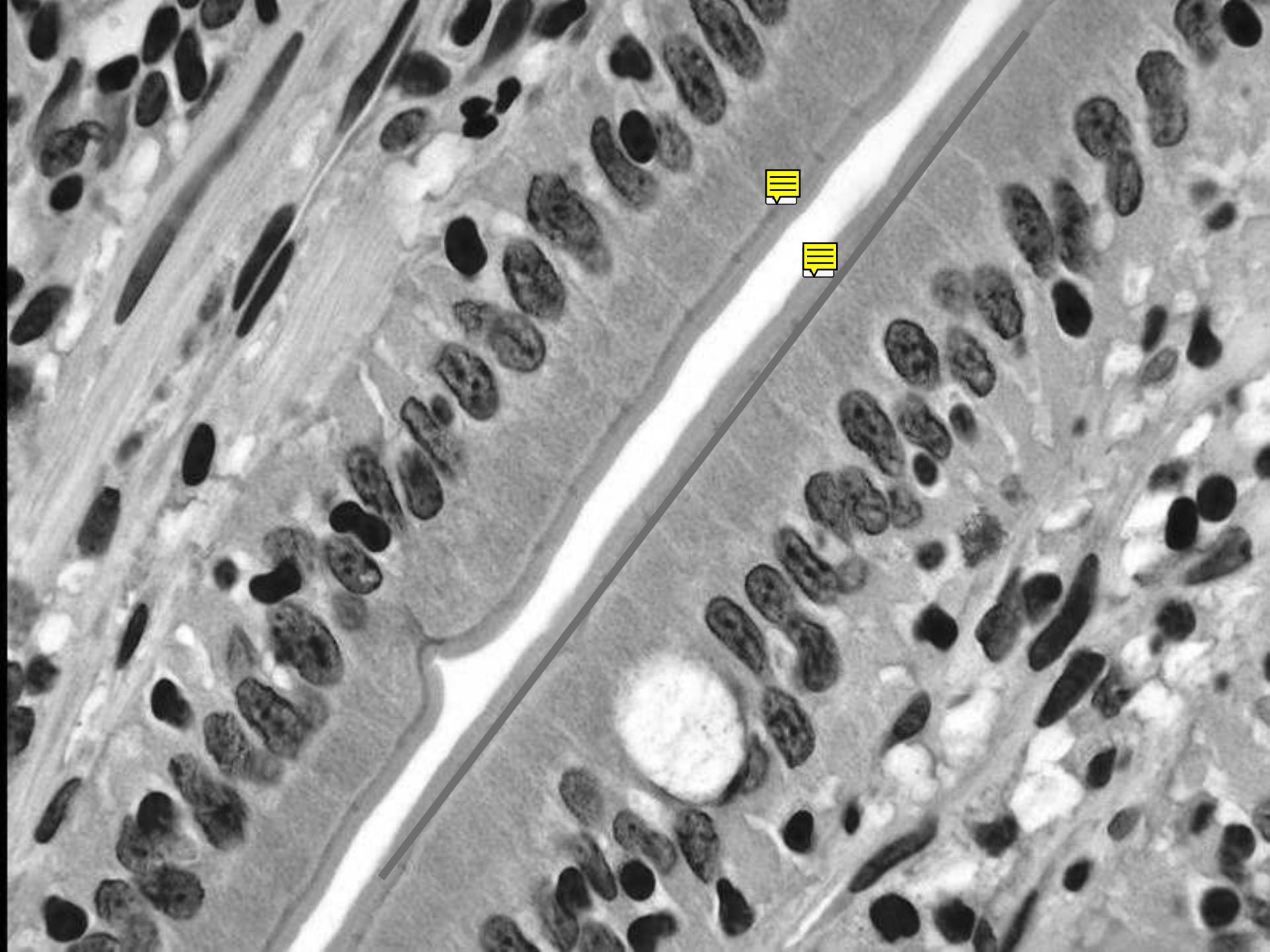




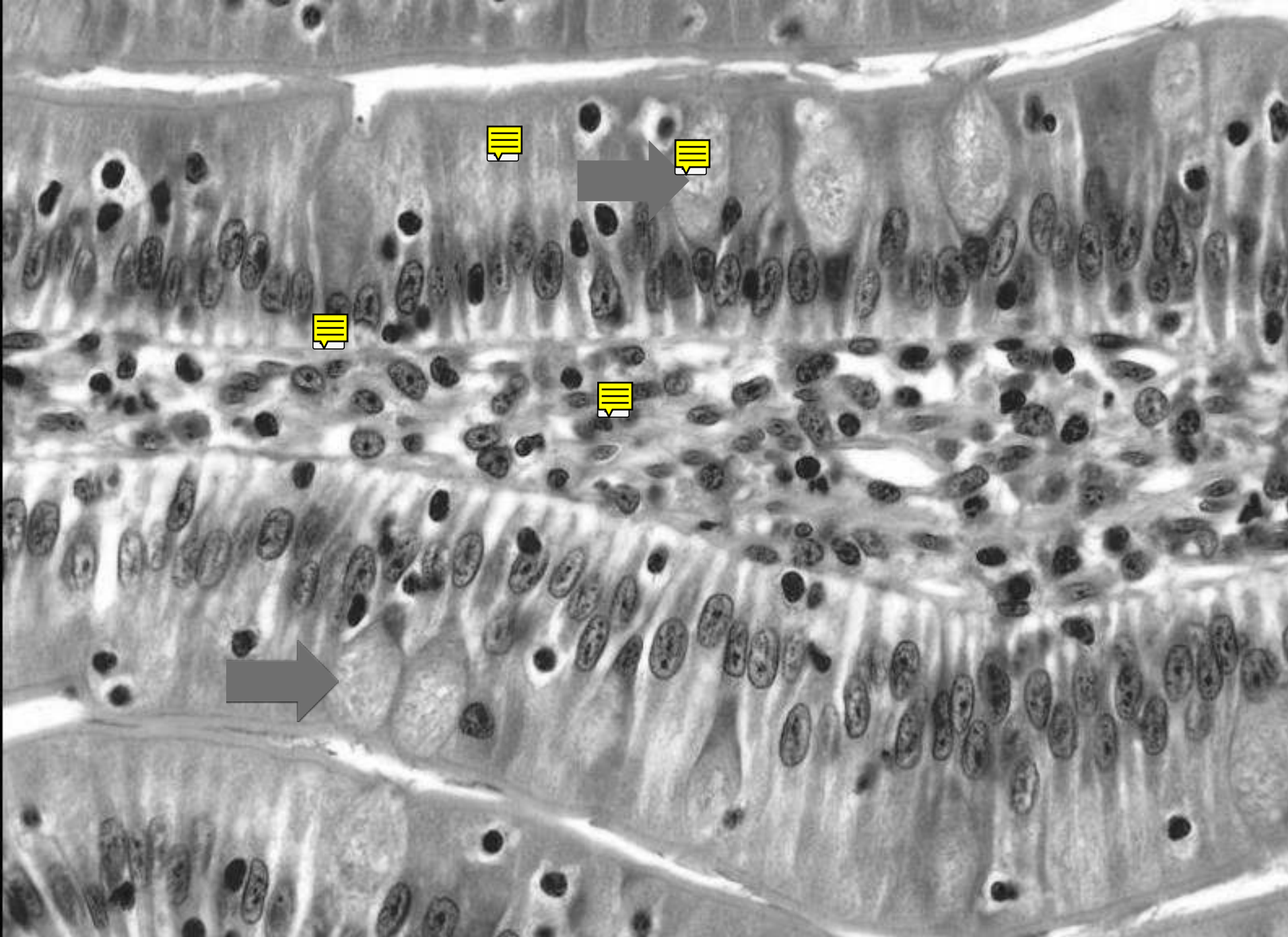


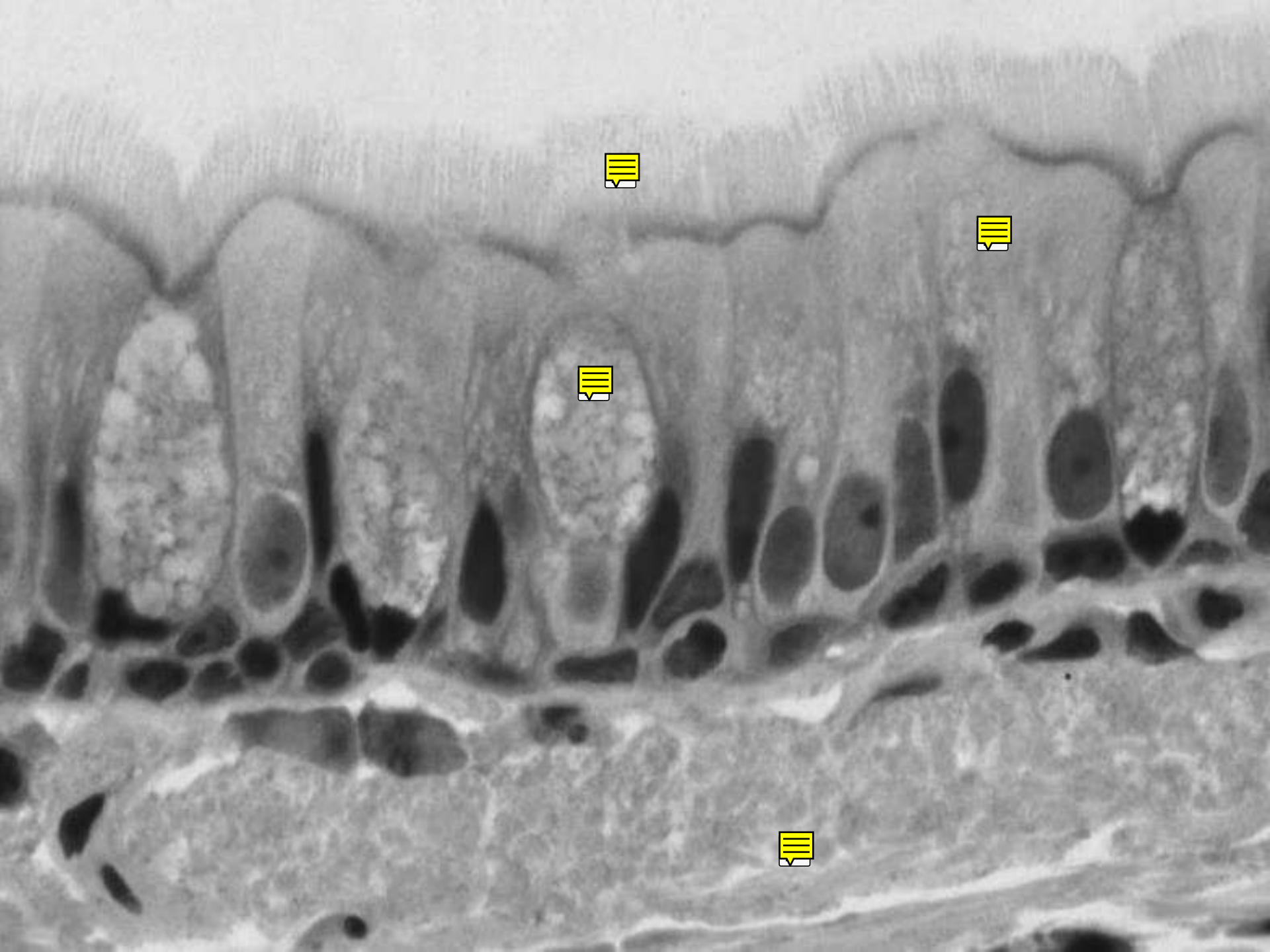




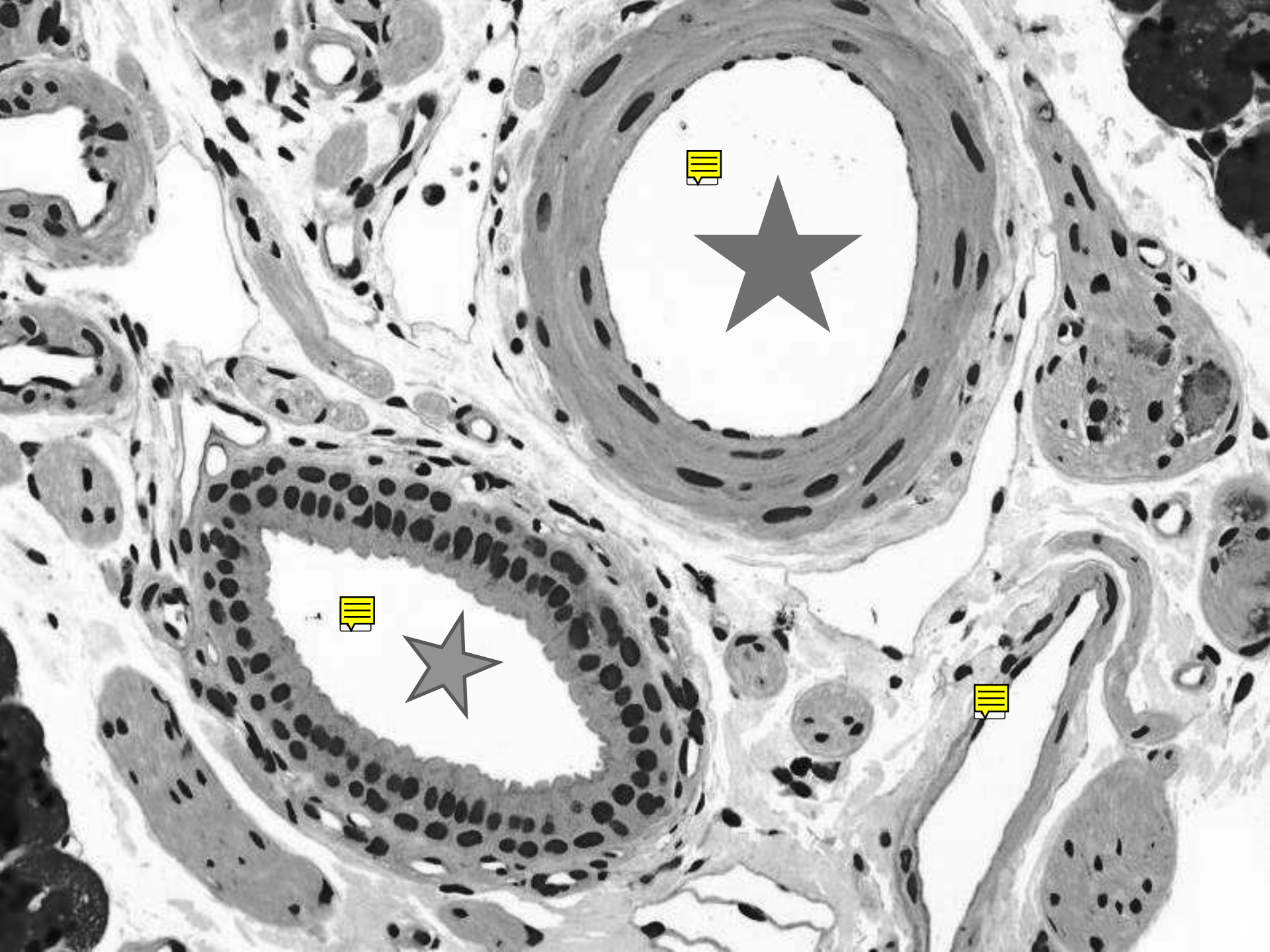


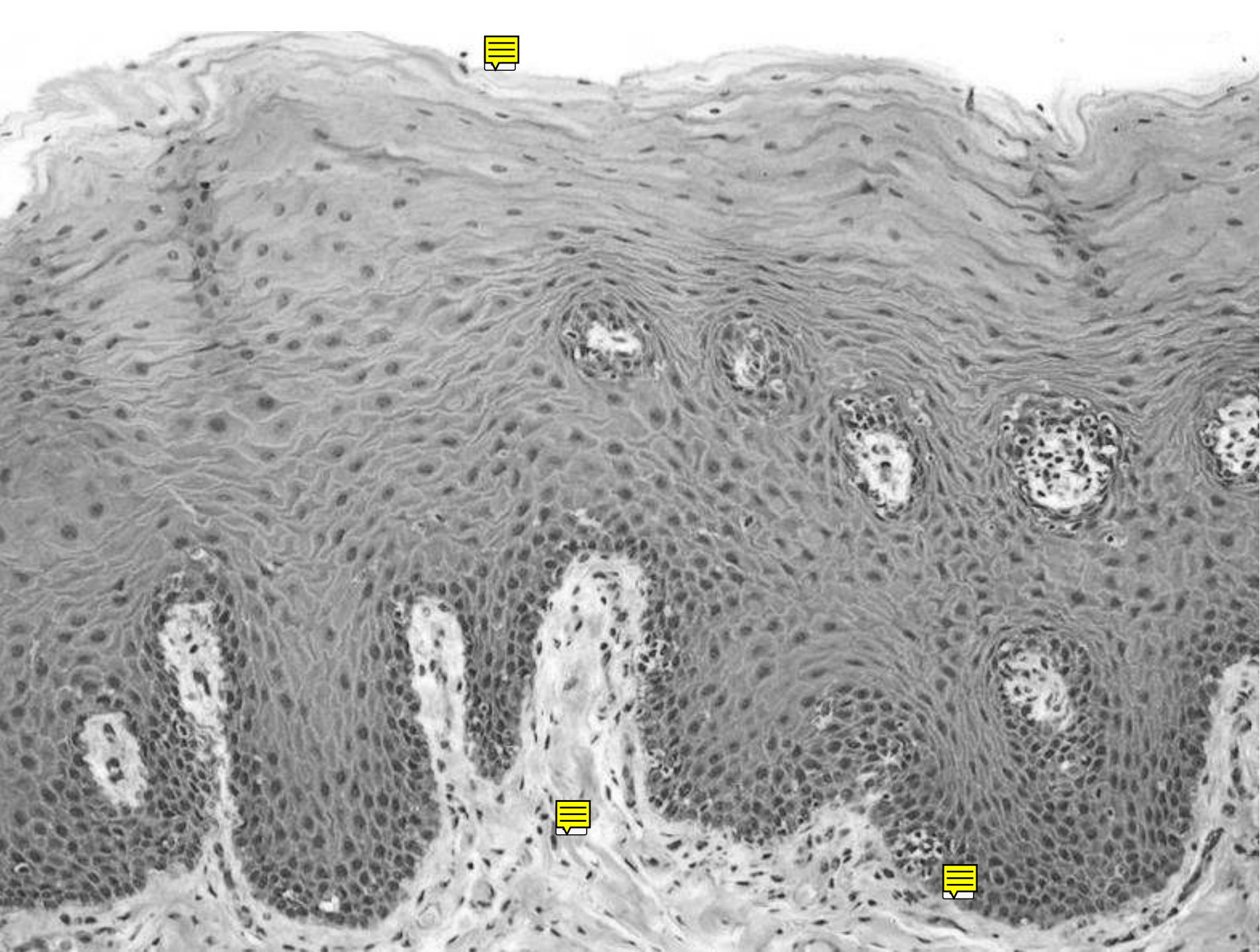




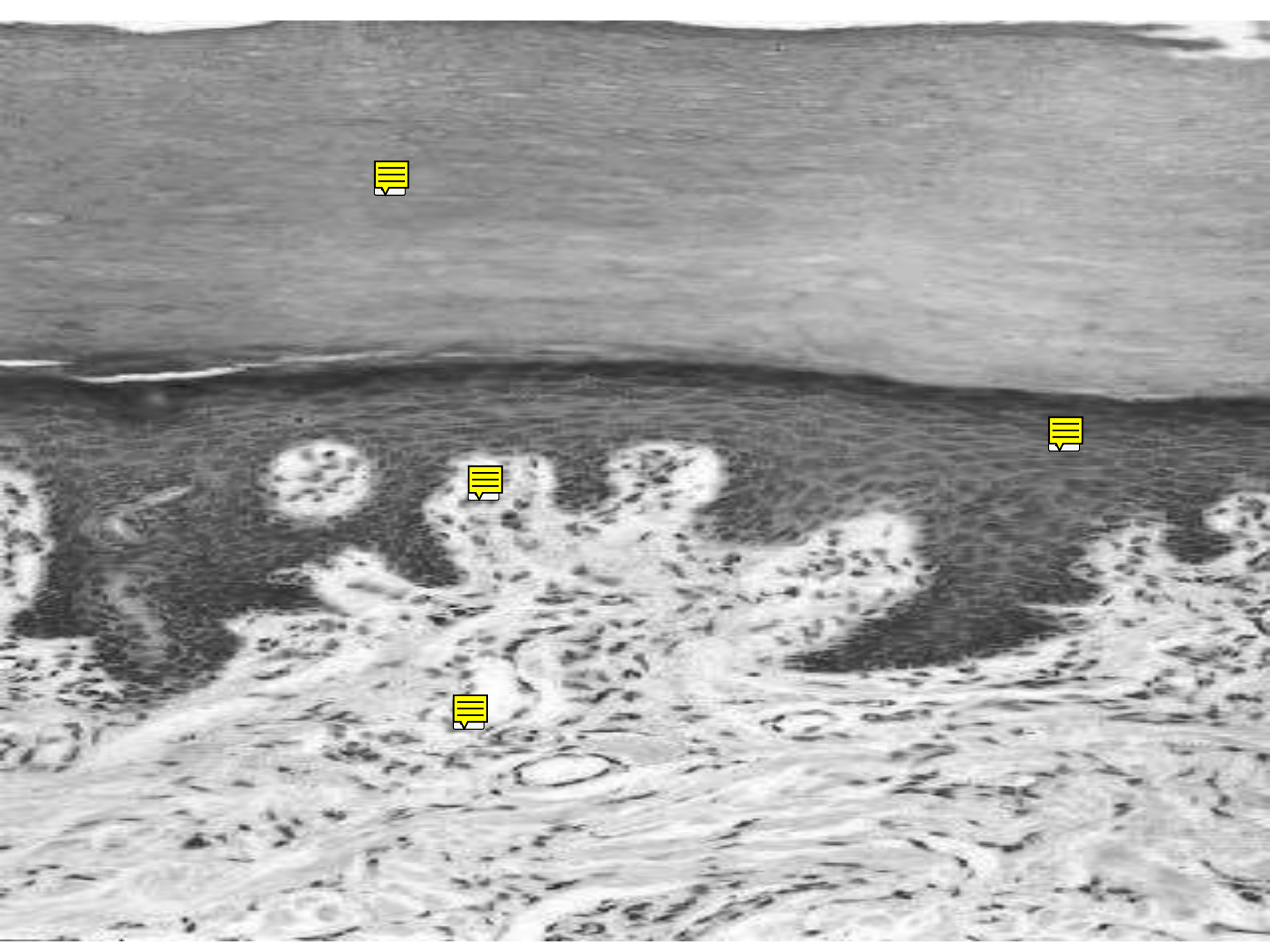


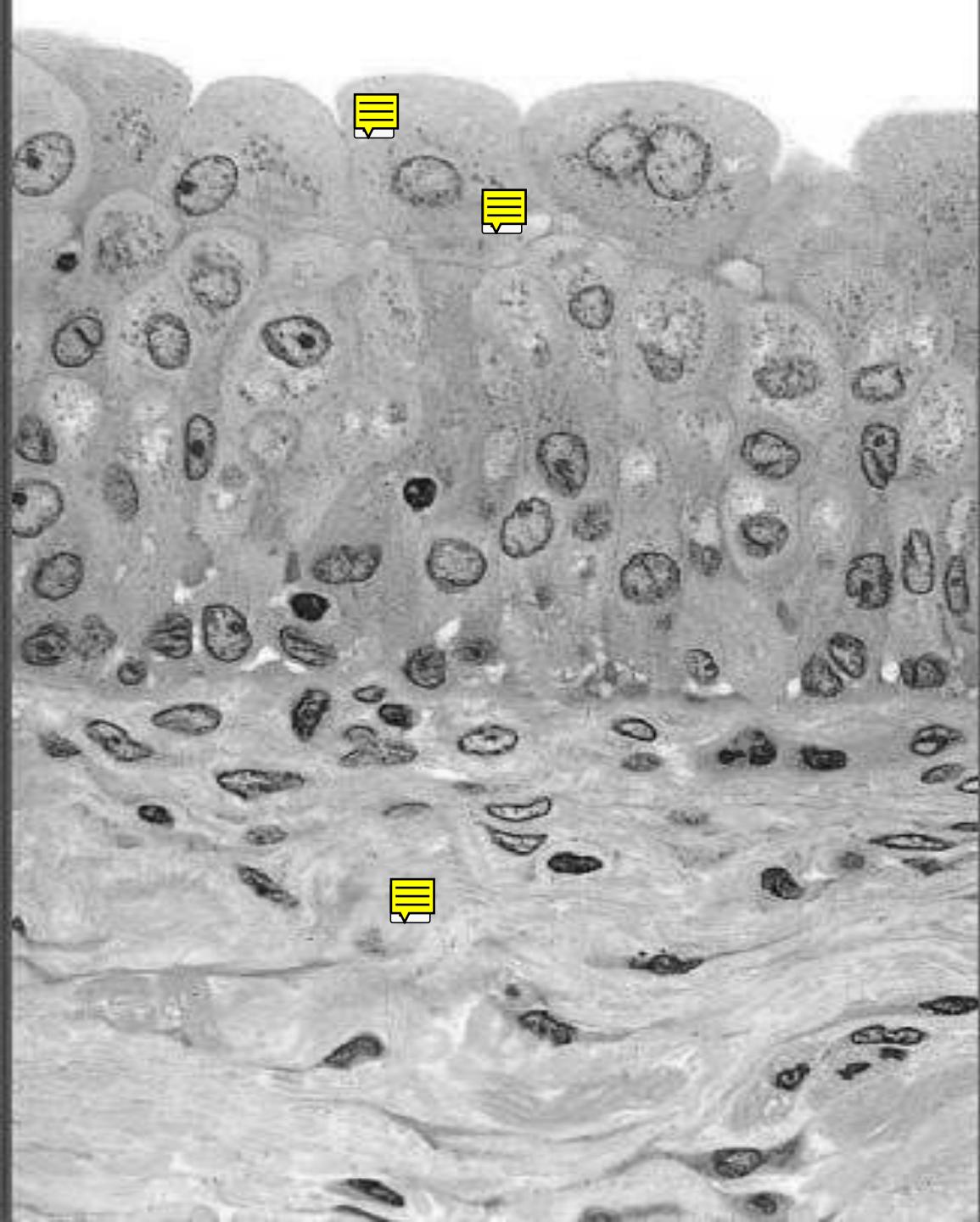


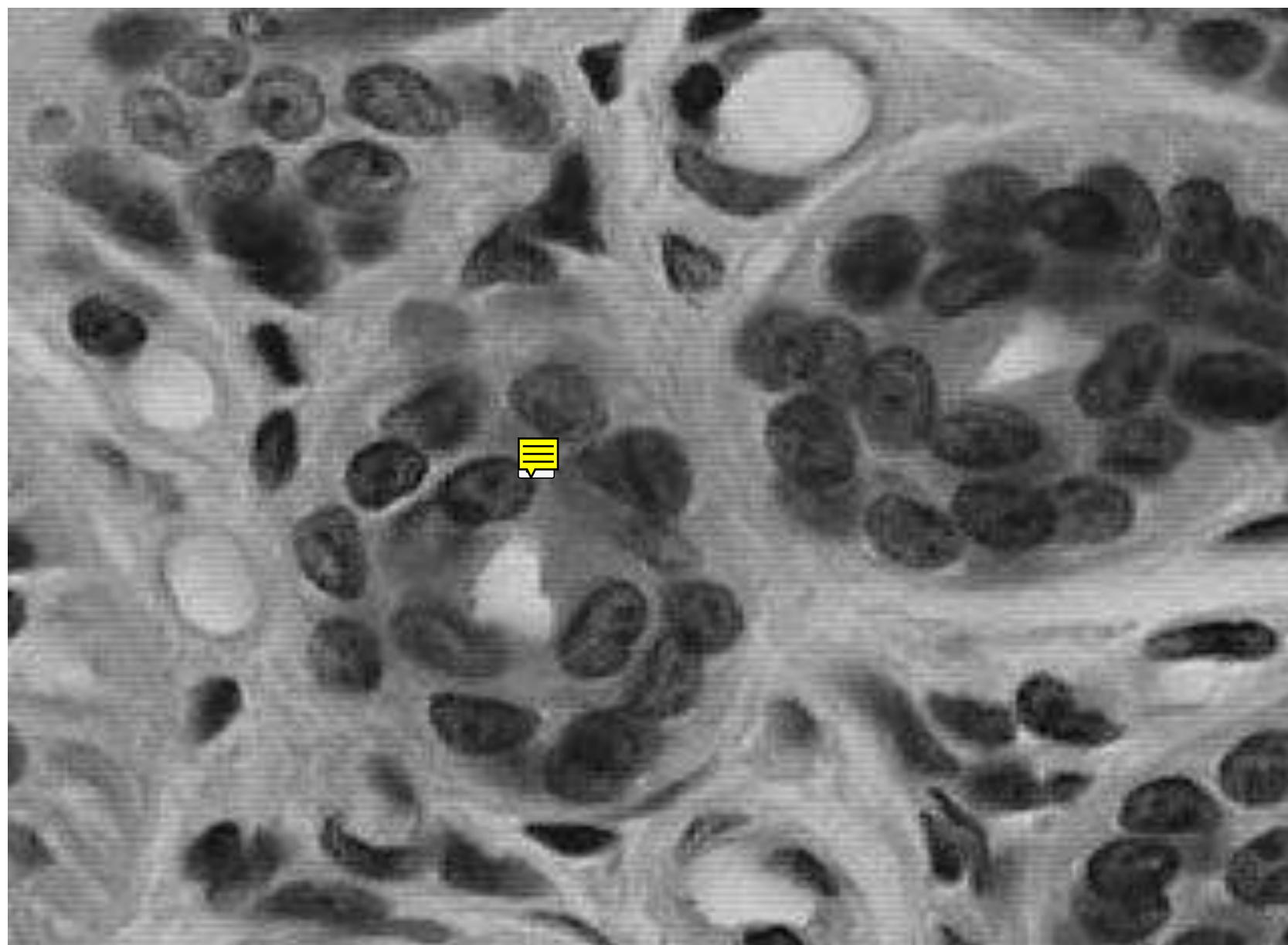




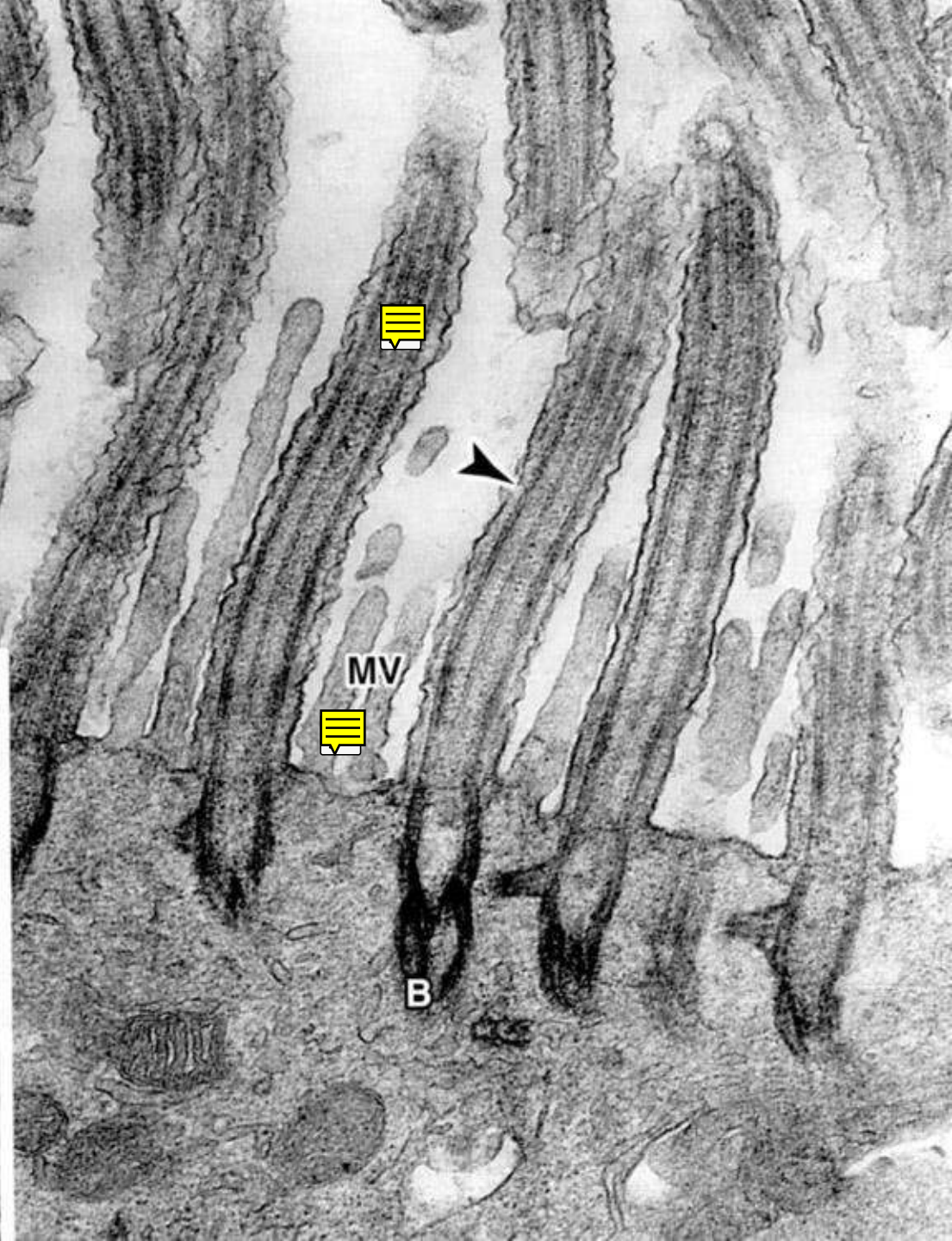
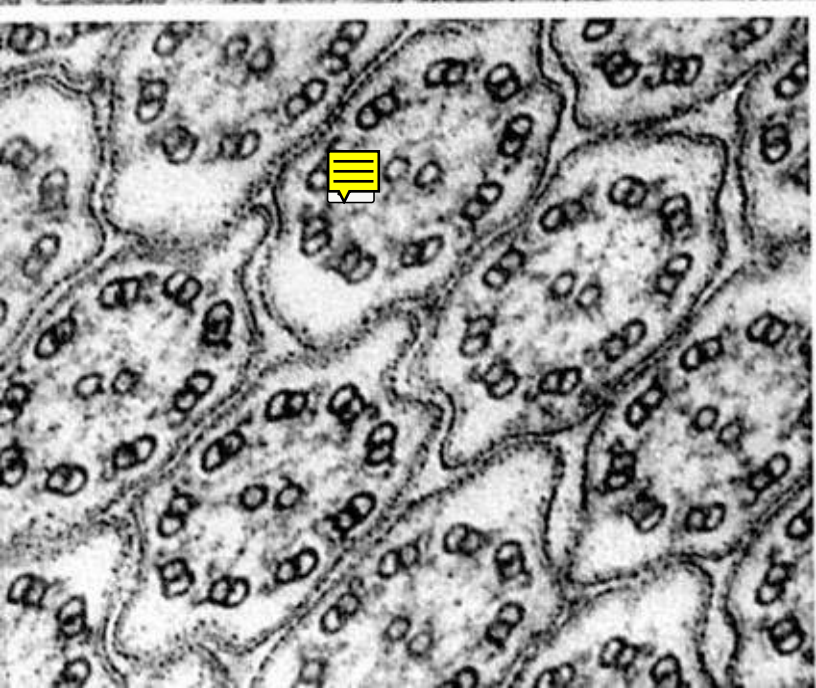
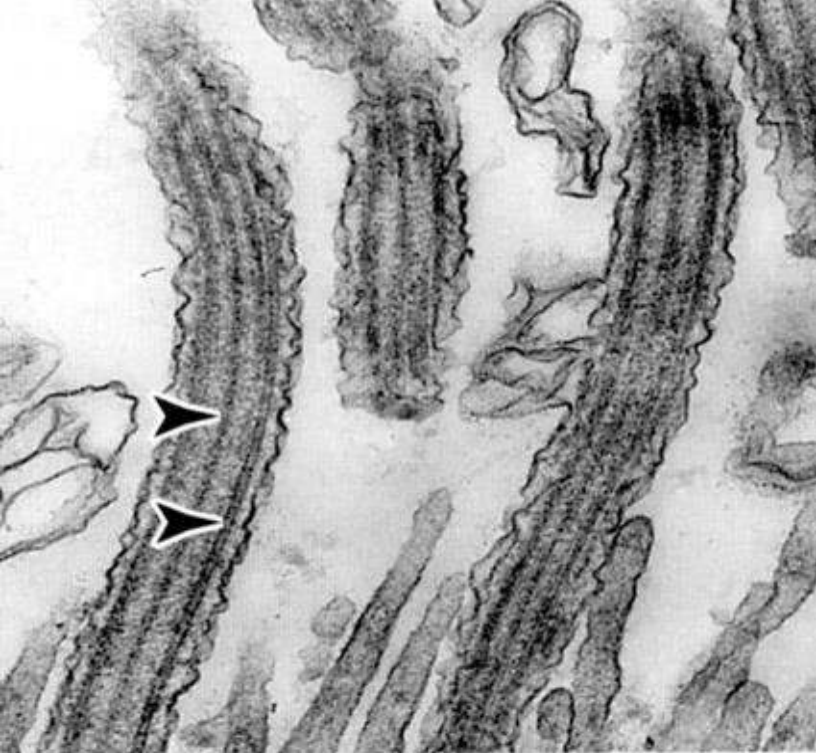




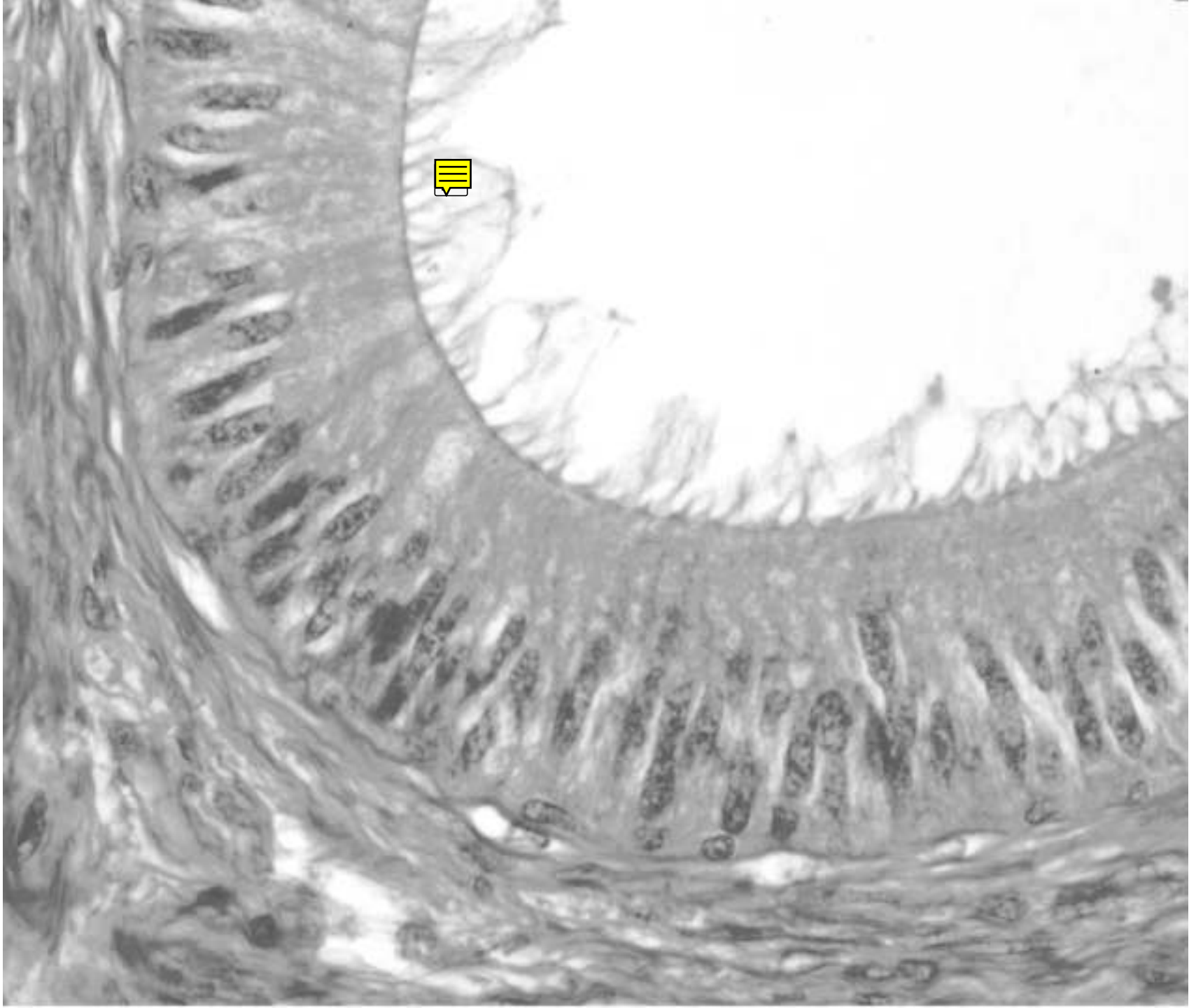






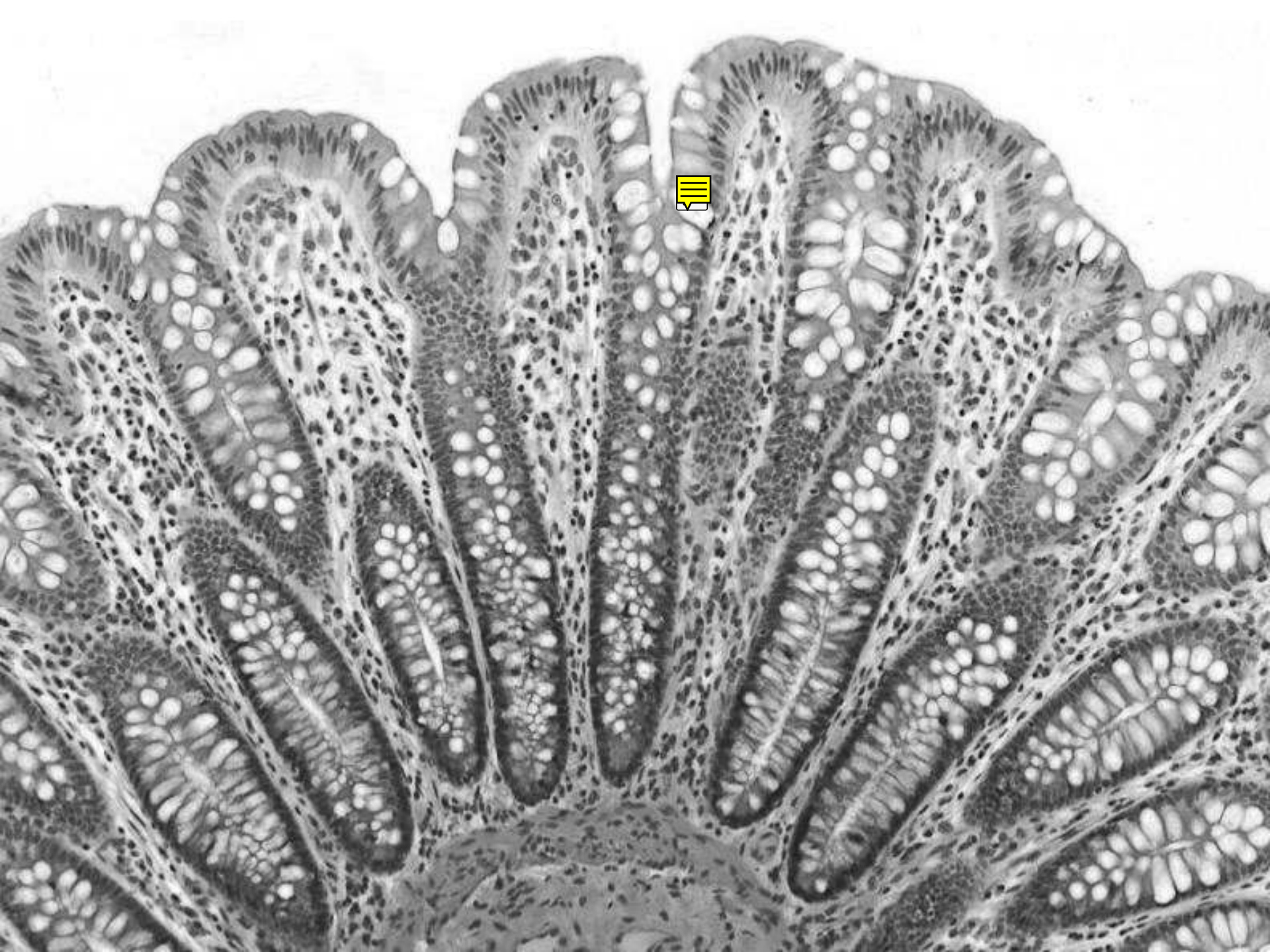




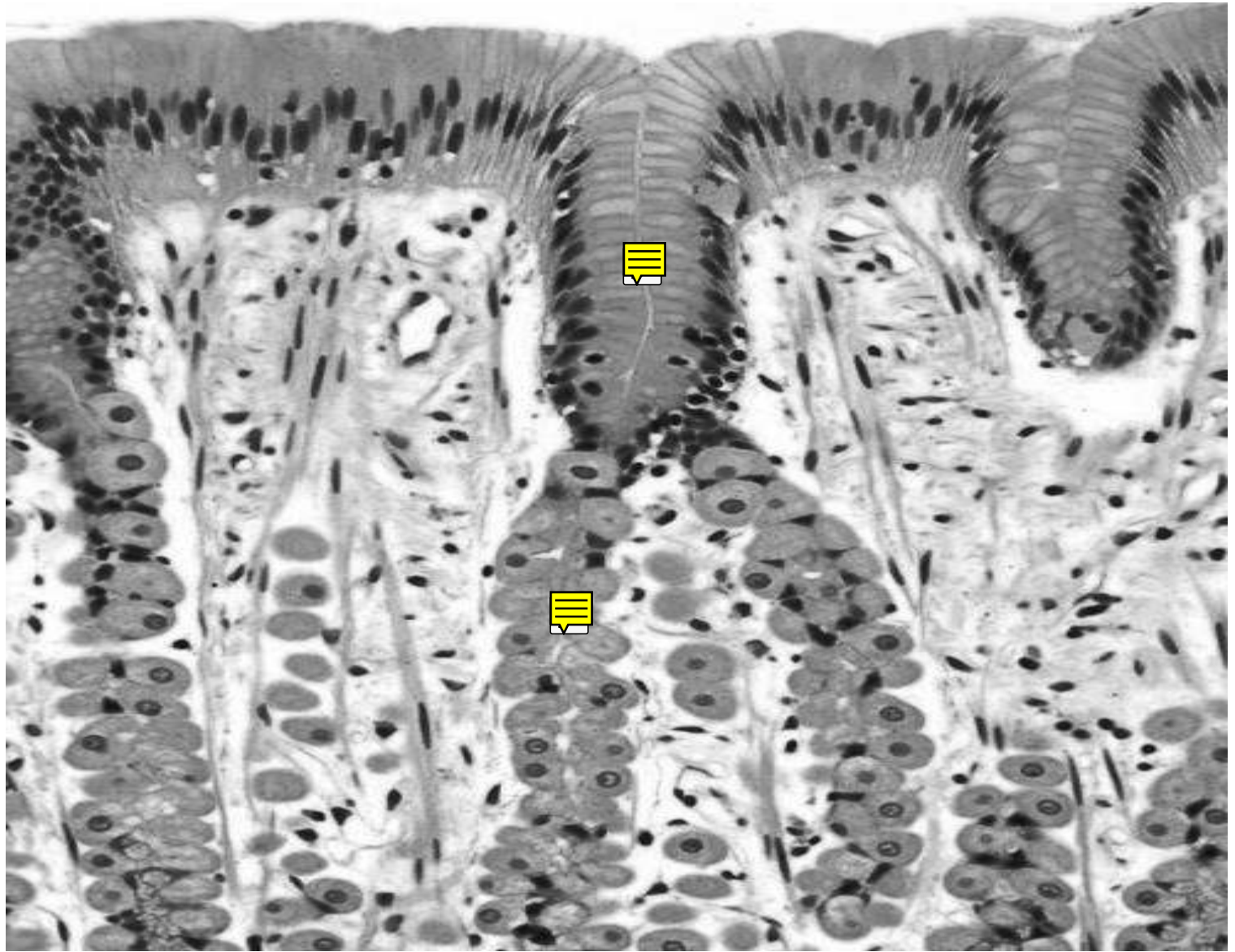




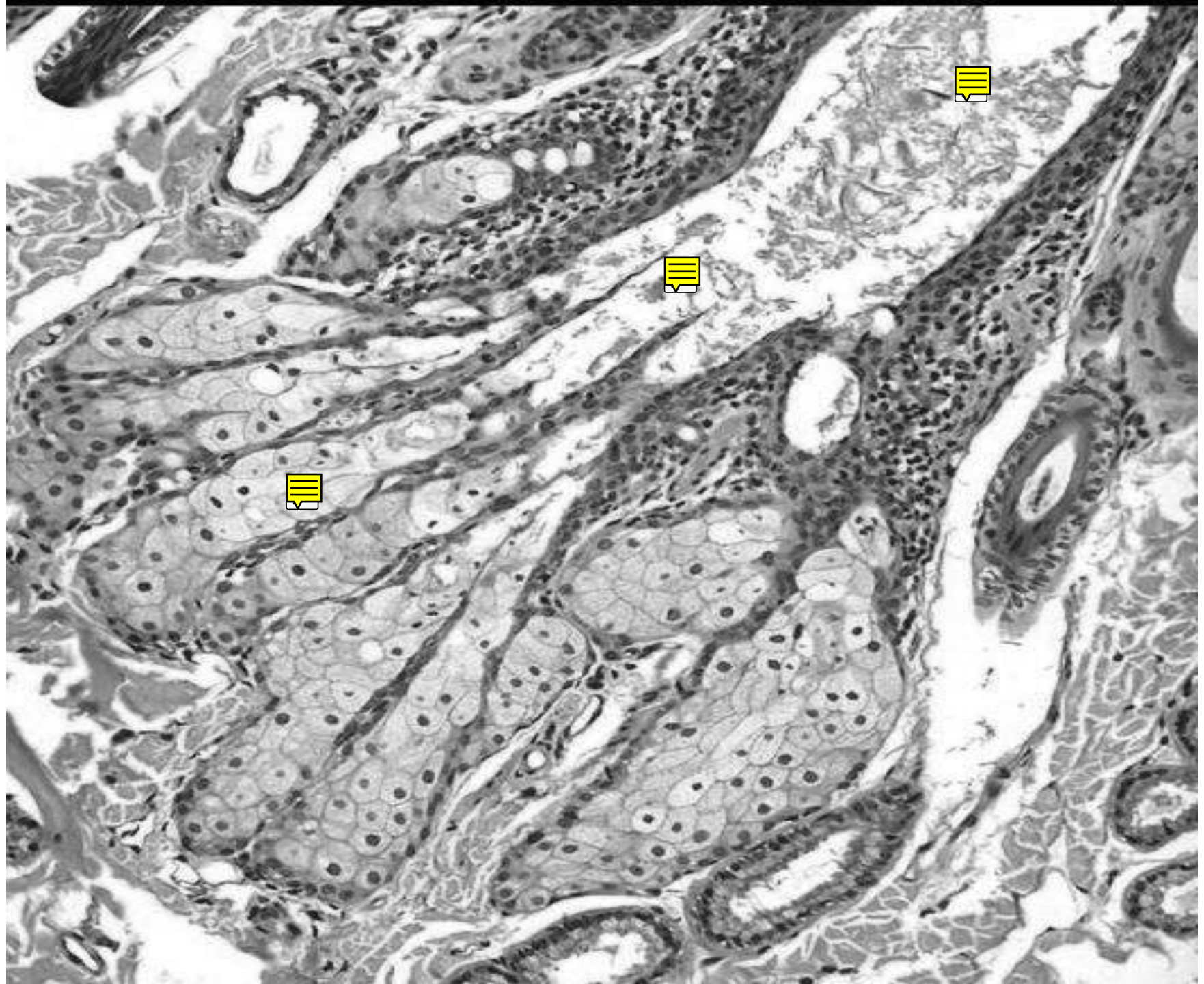
# Glands

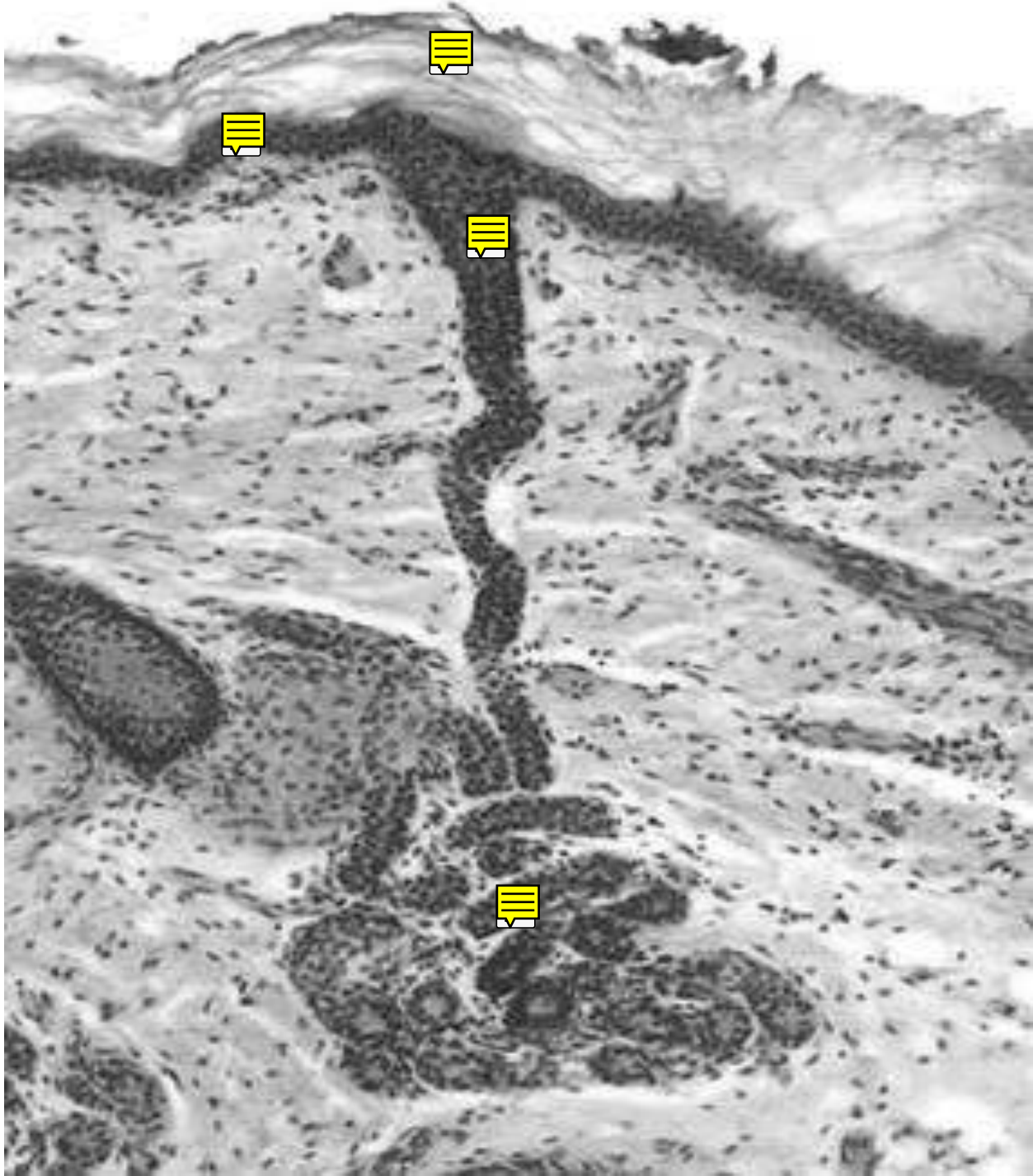




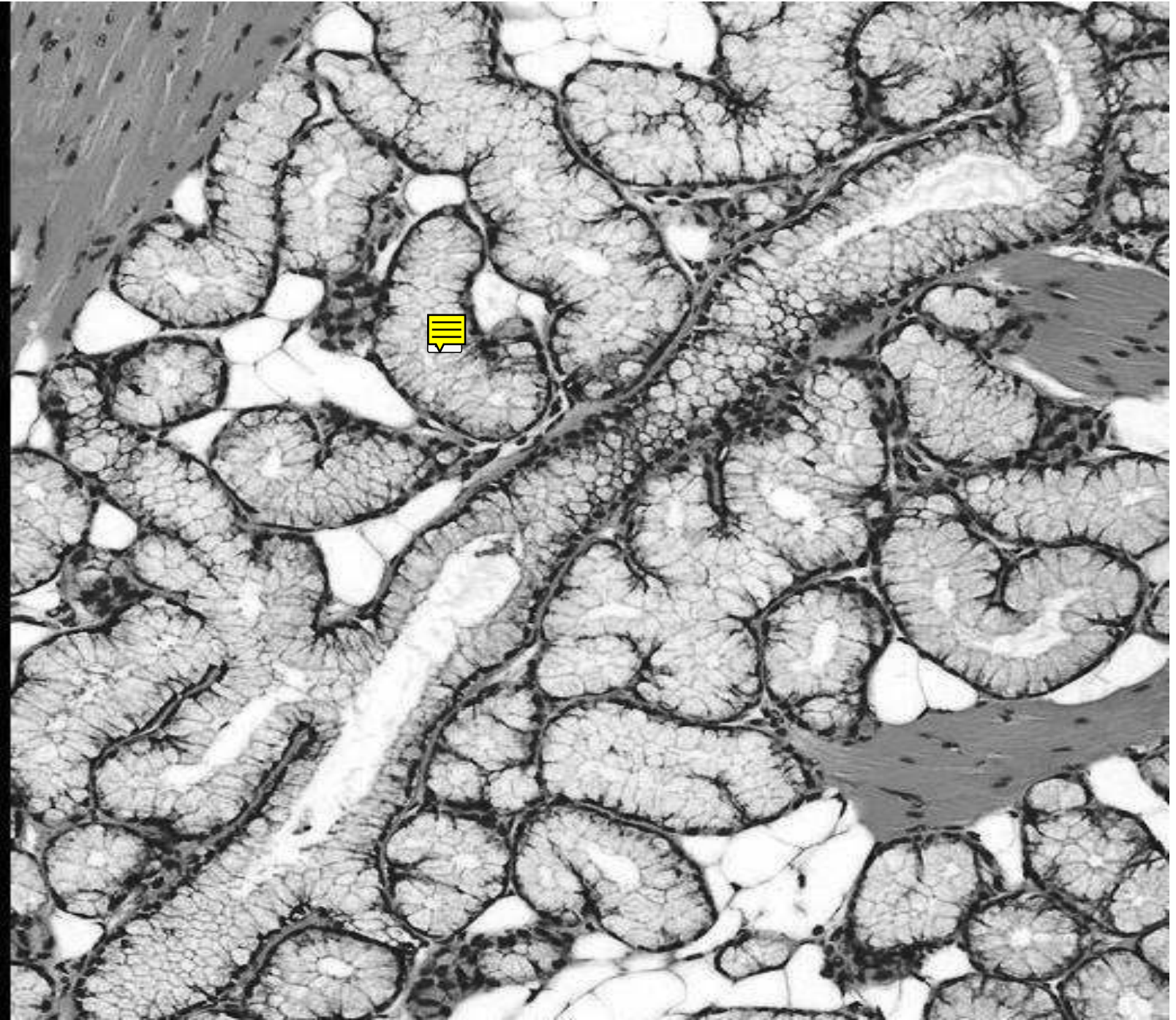


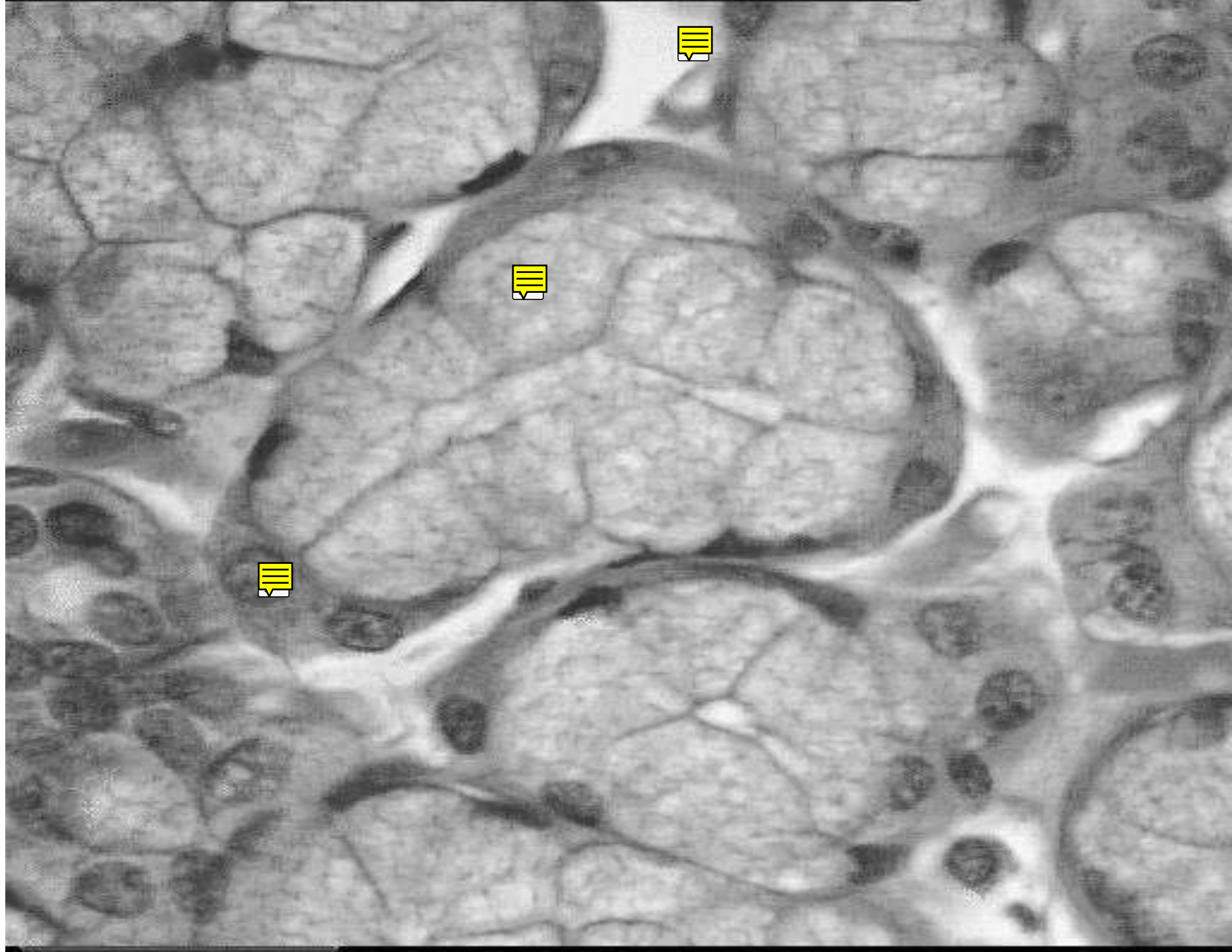




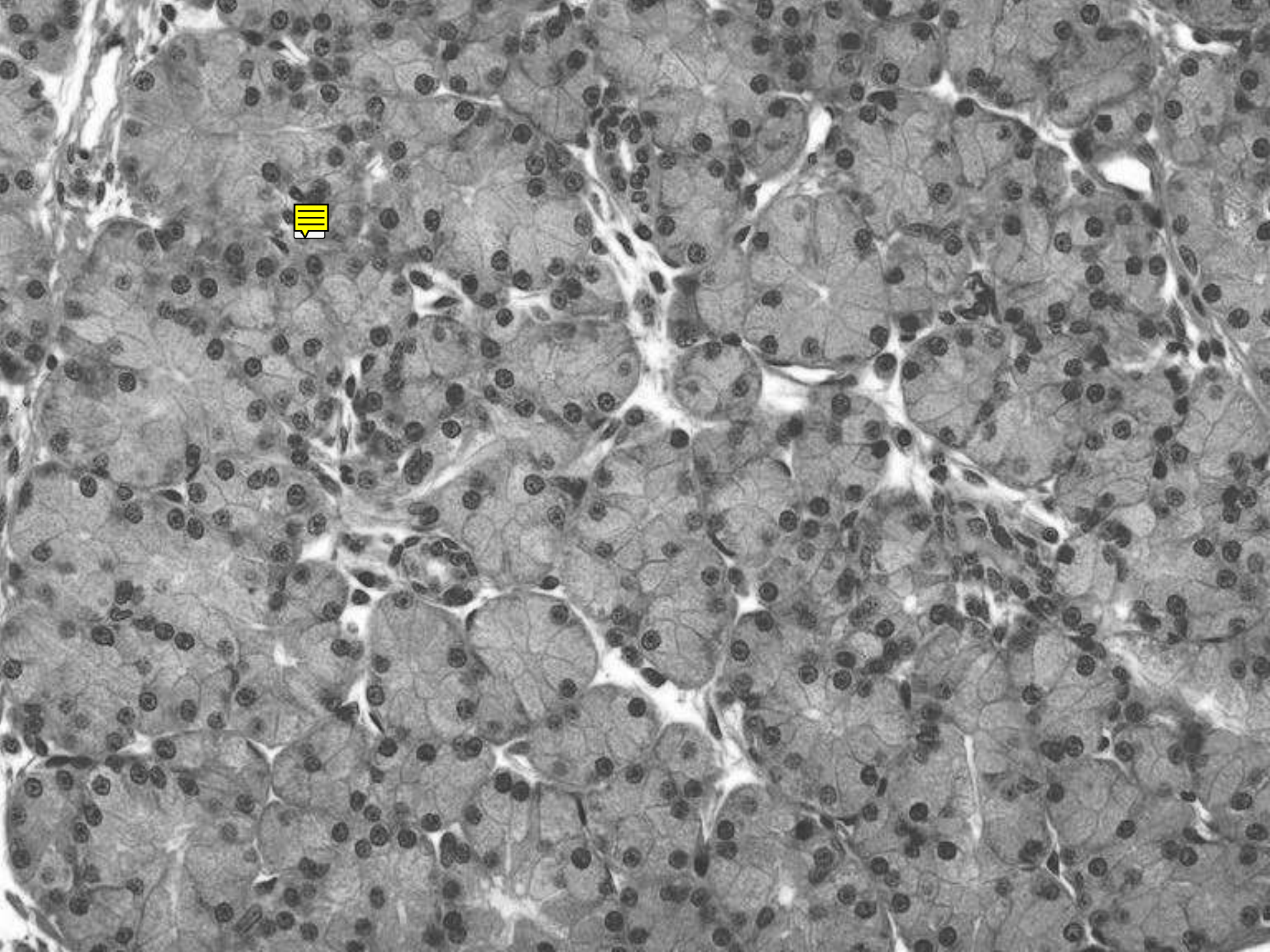




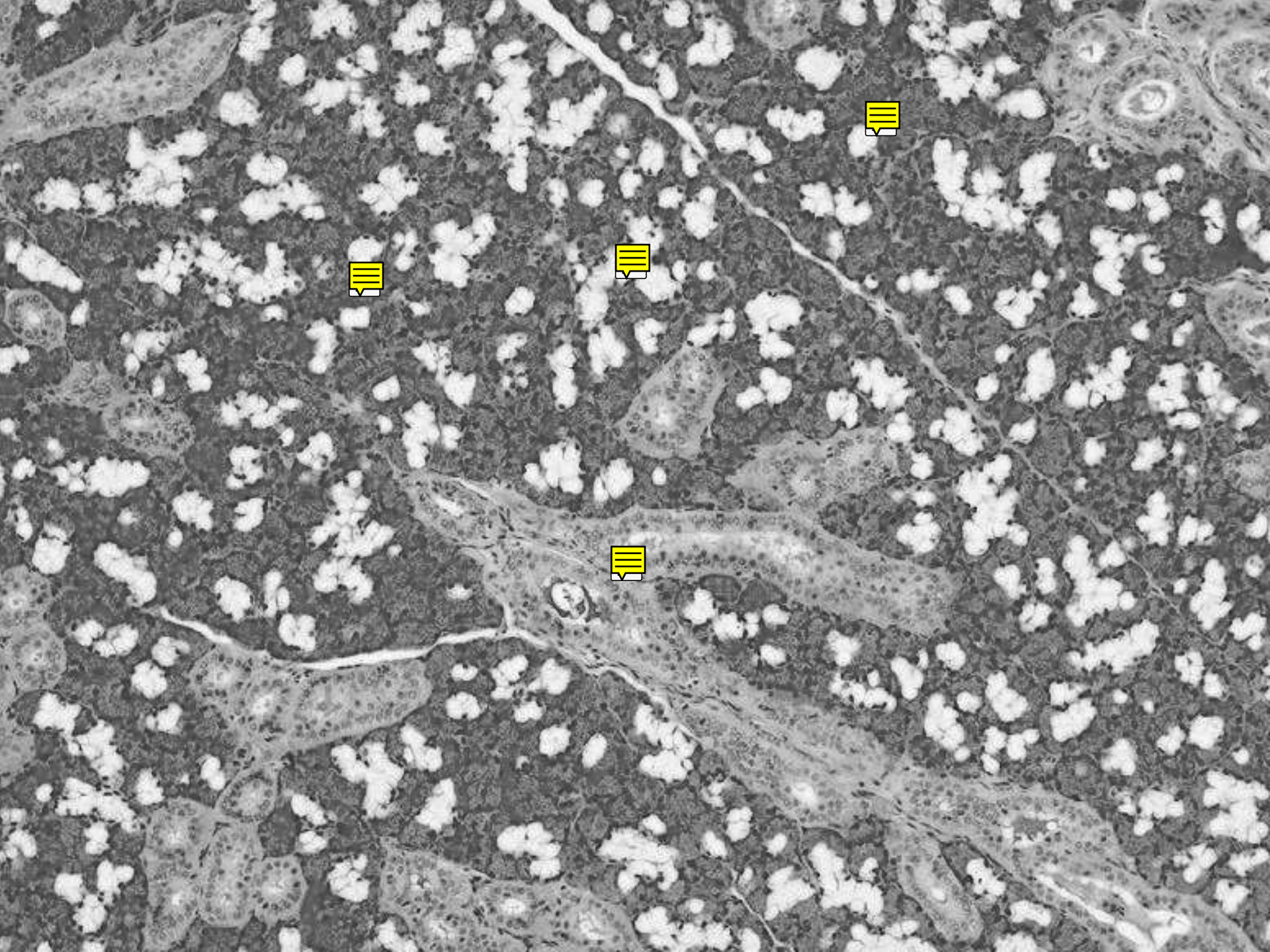




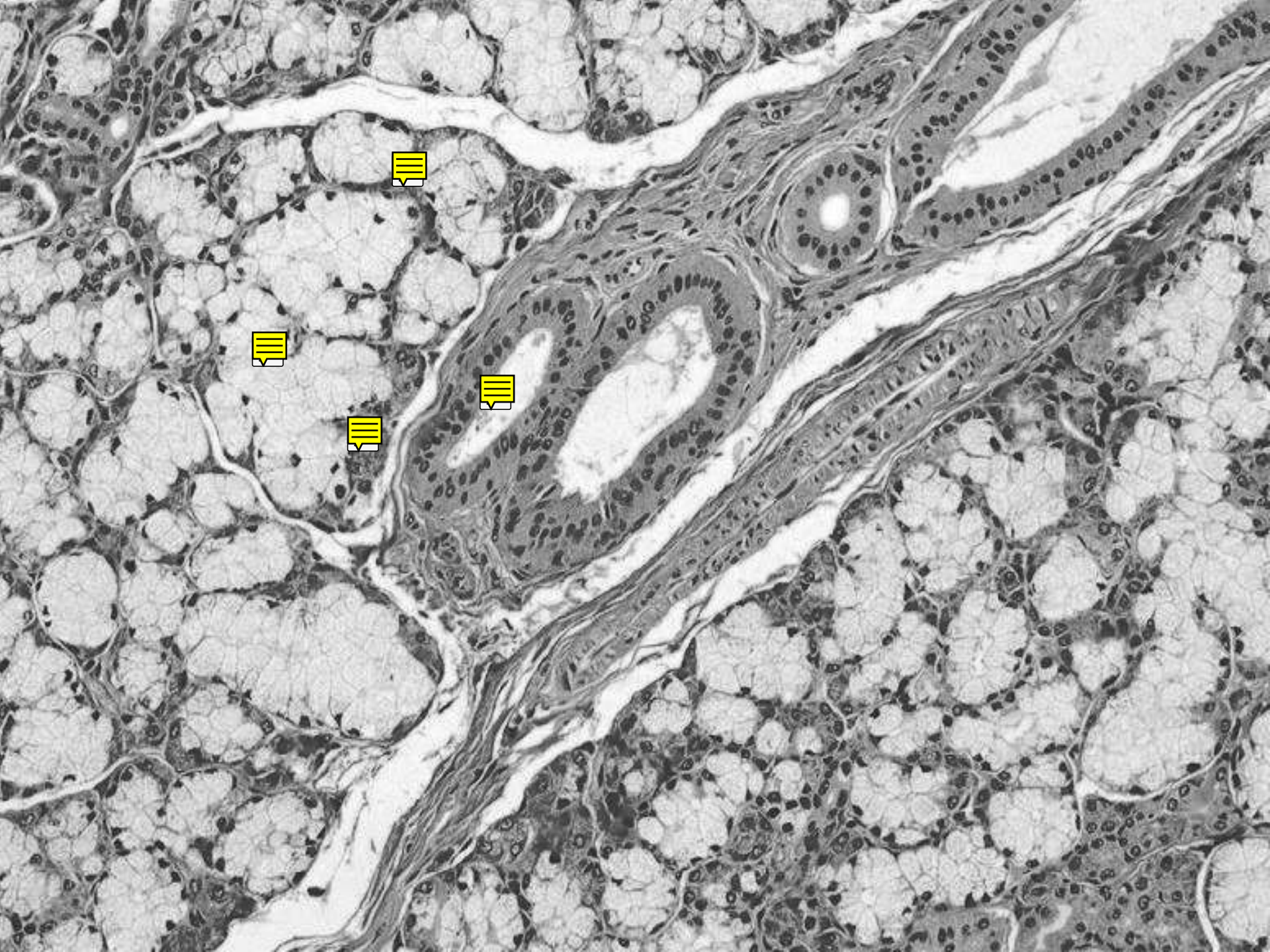




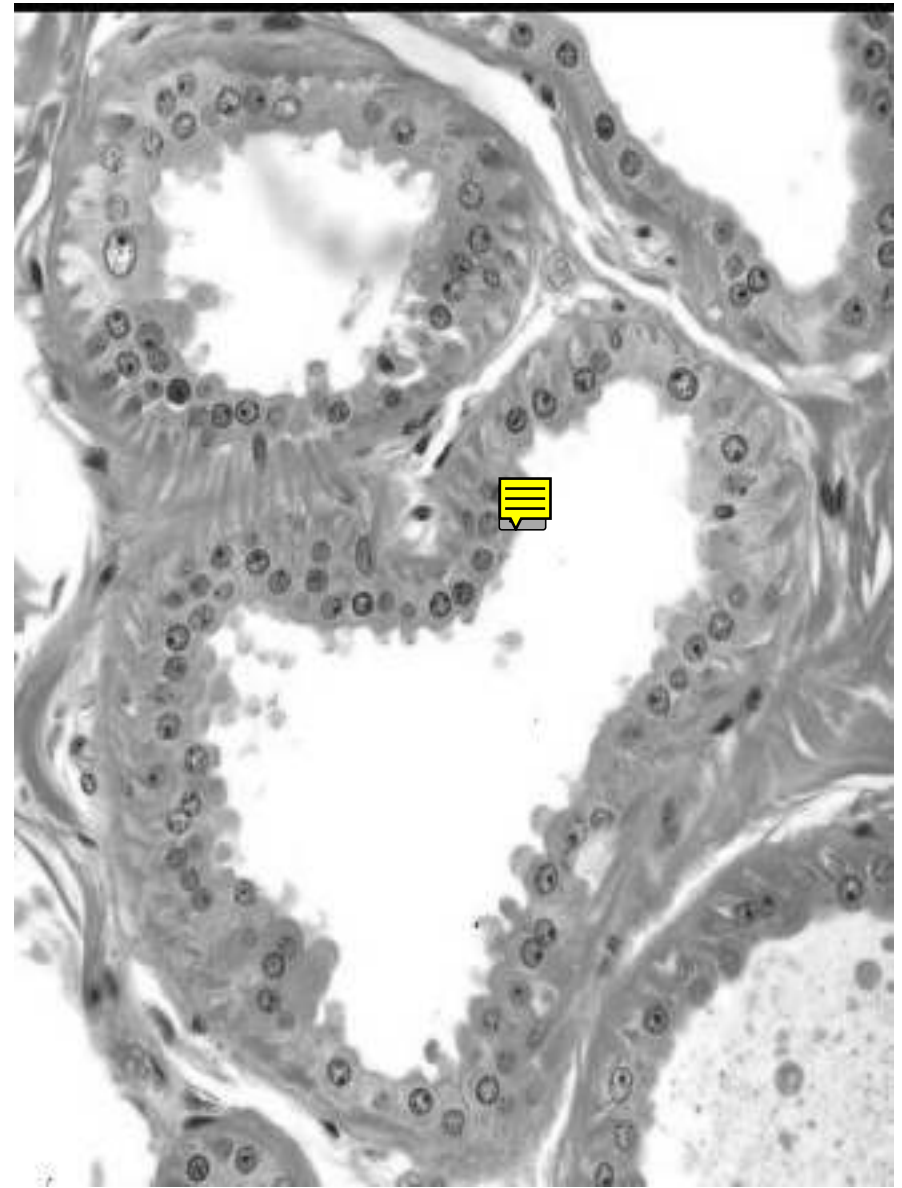
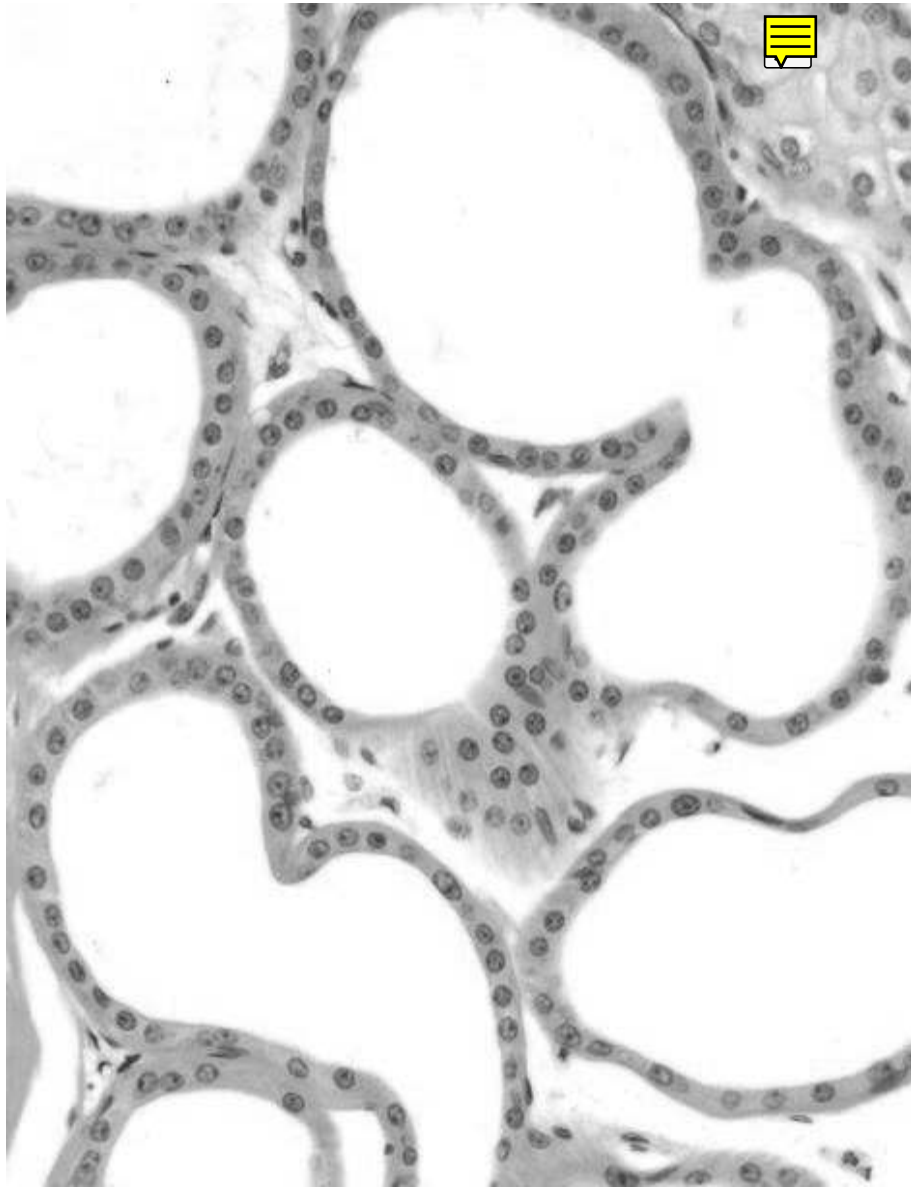




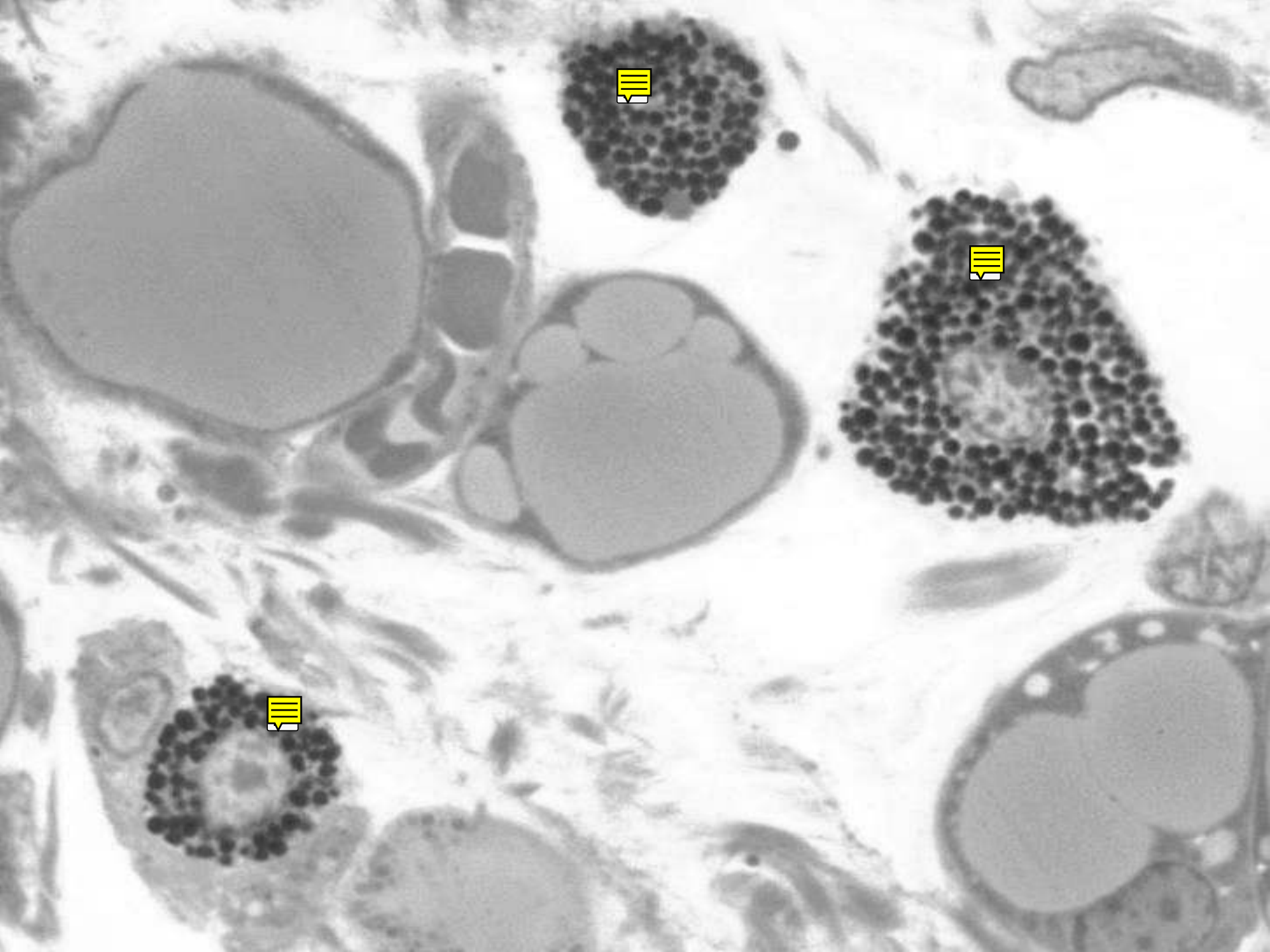




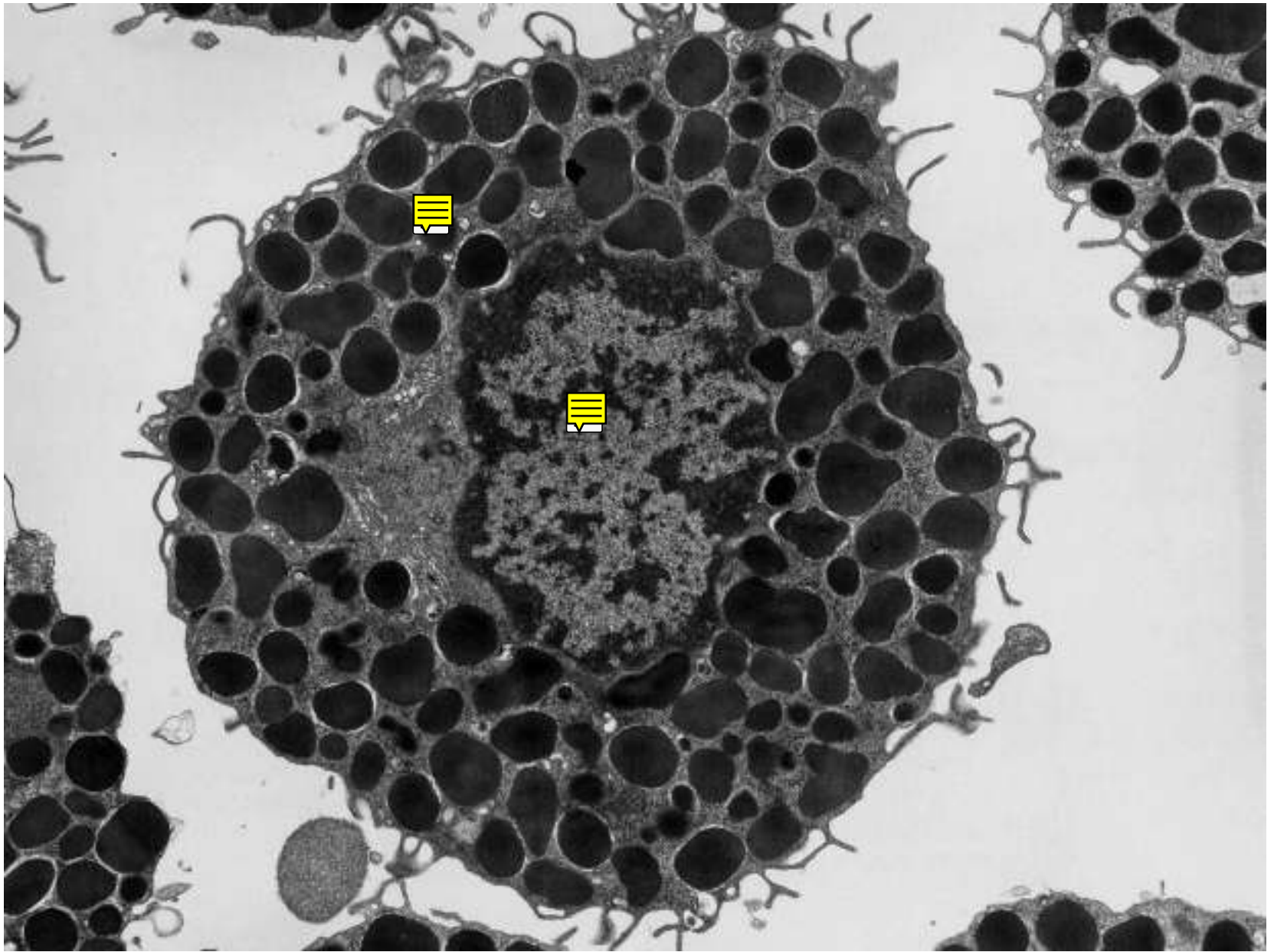


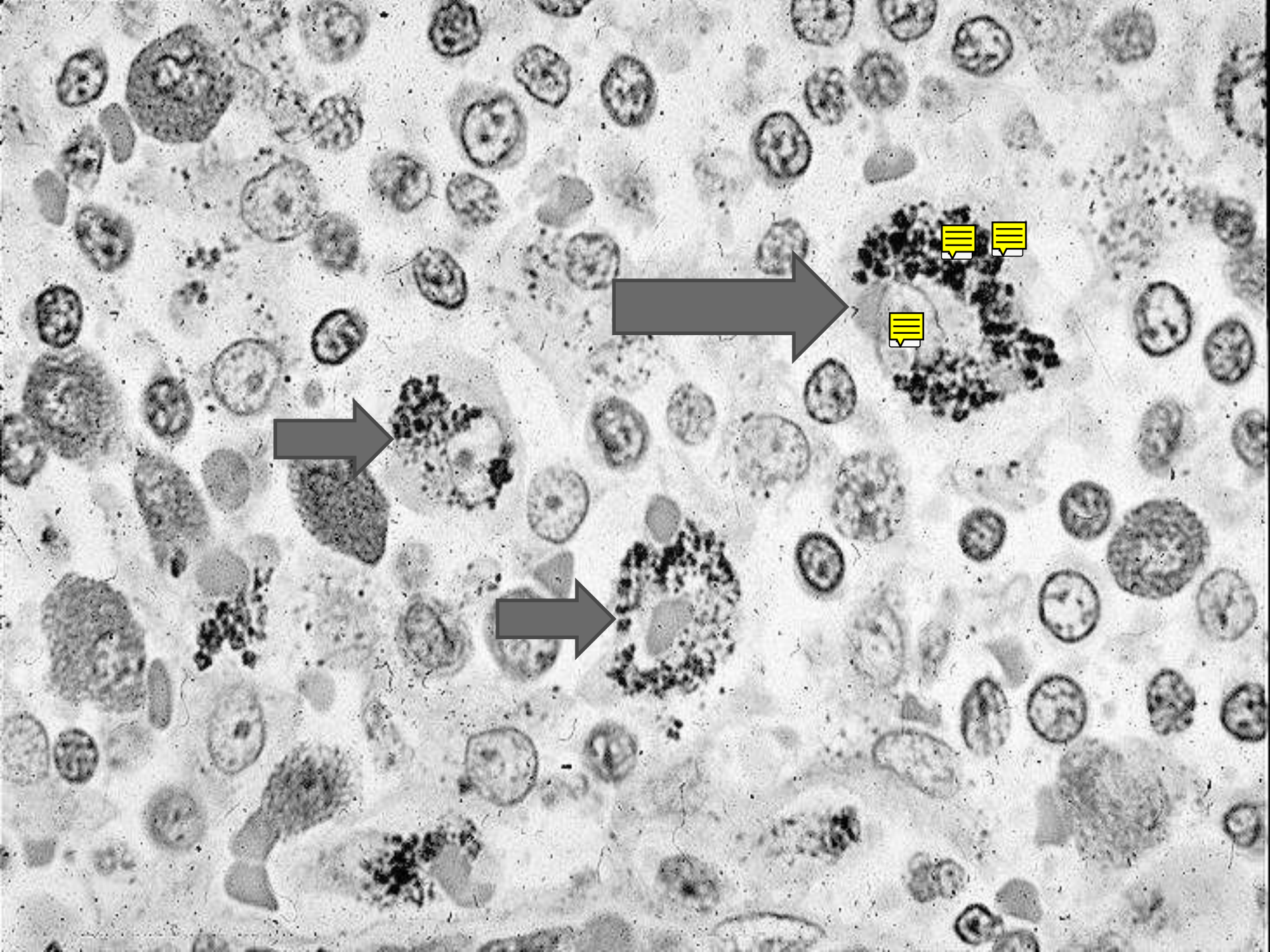


# Connective tissue

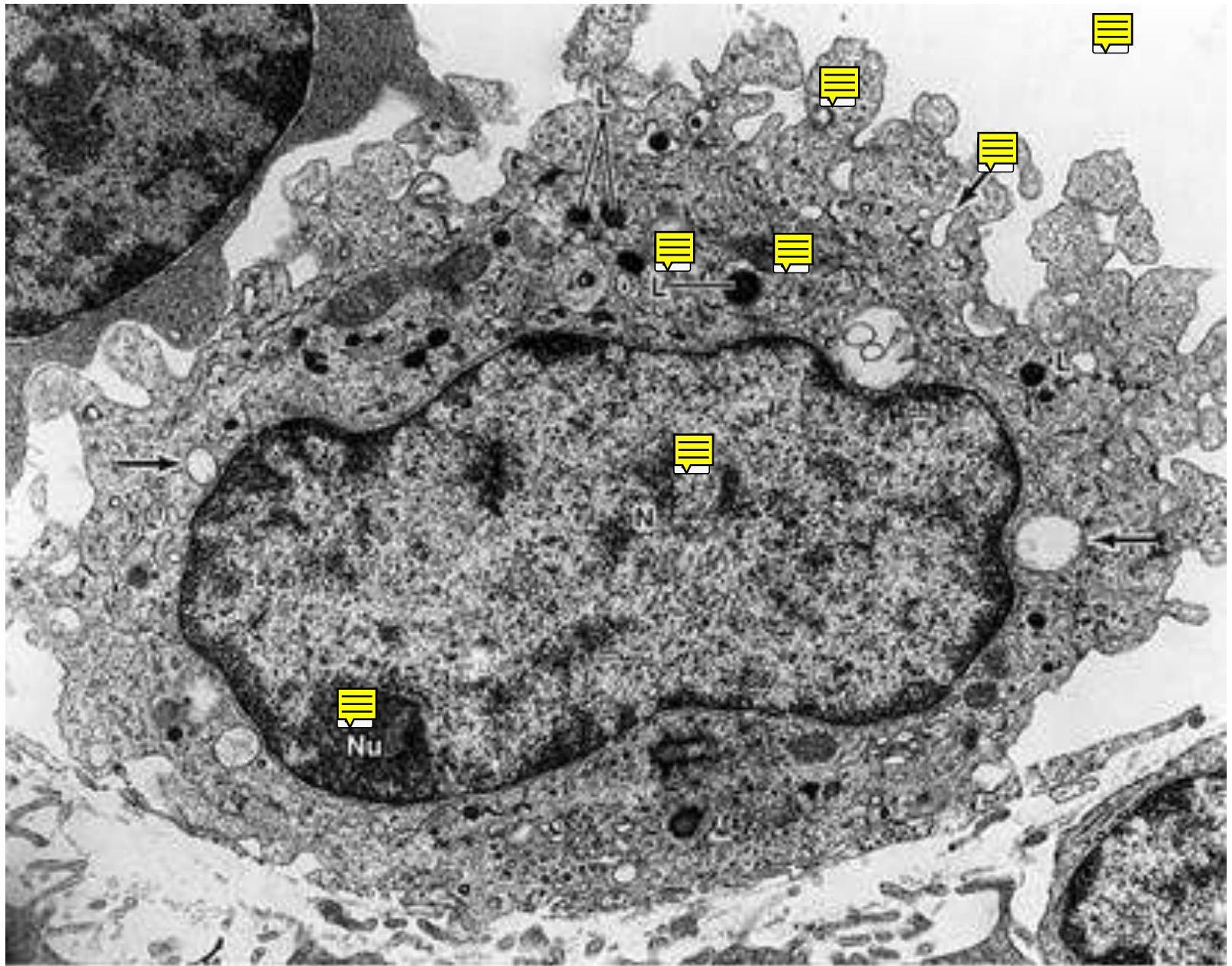




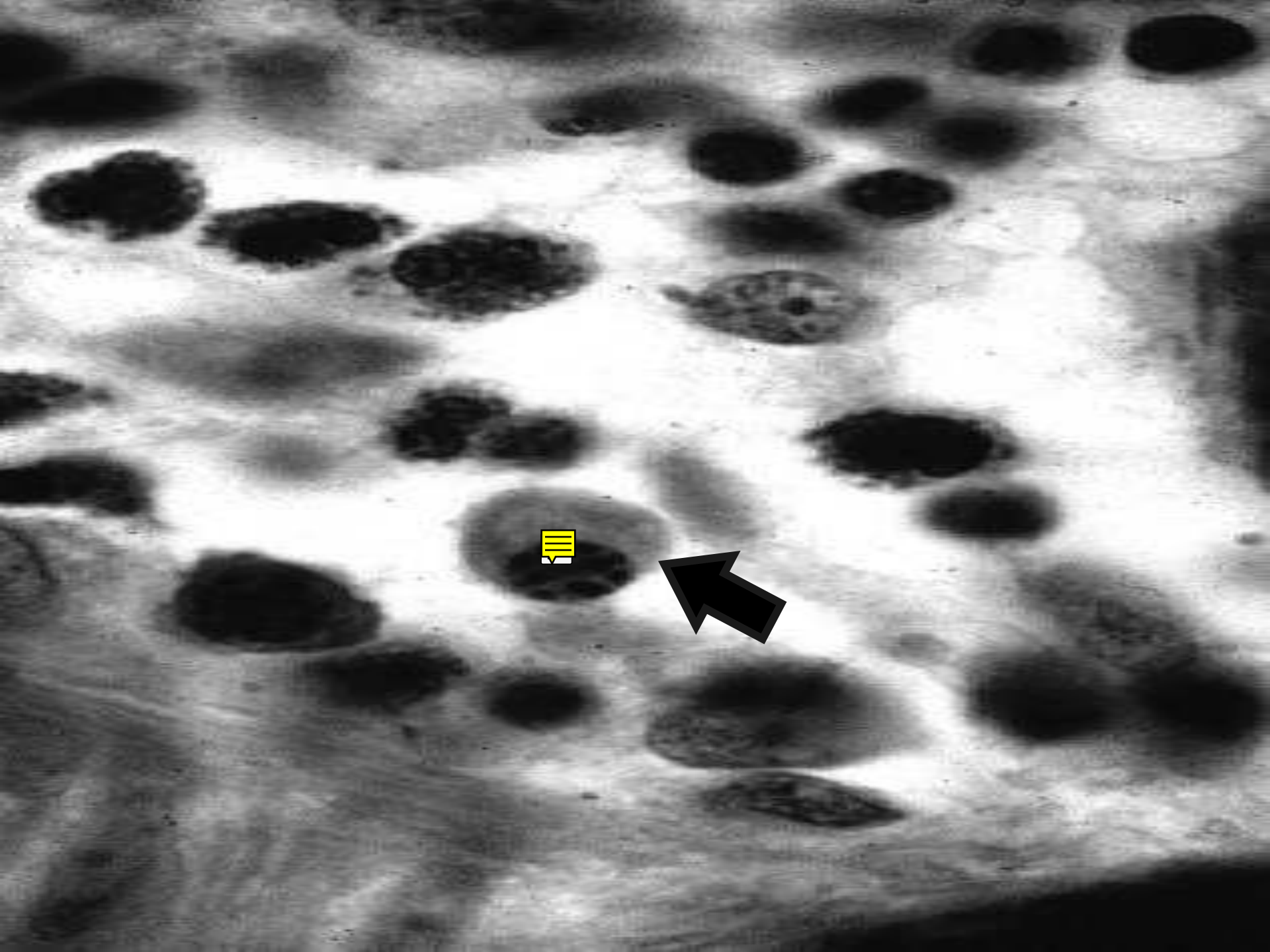


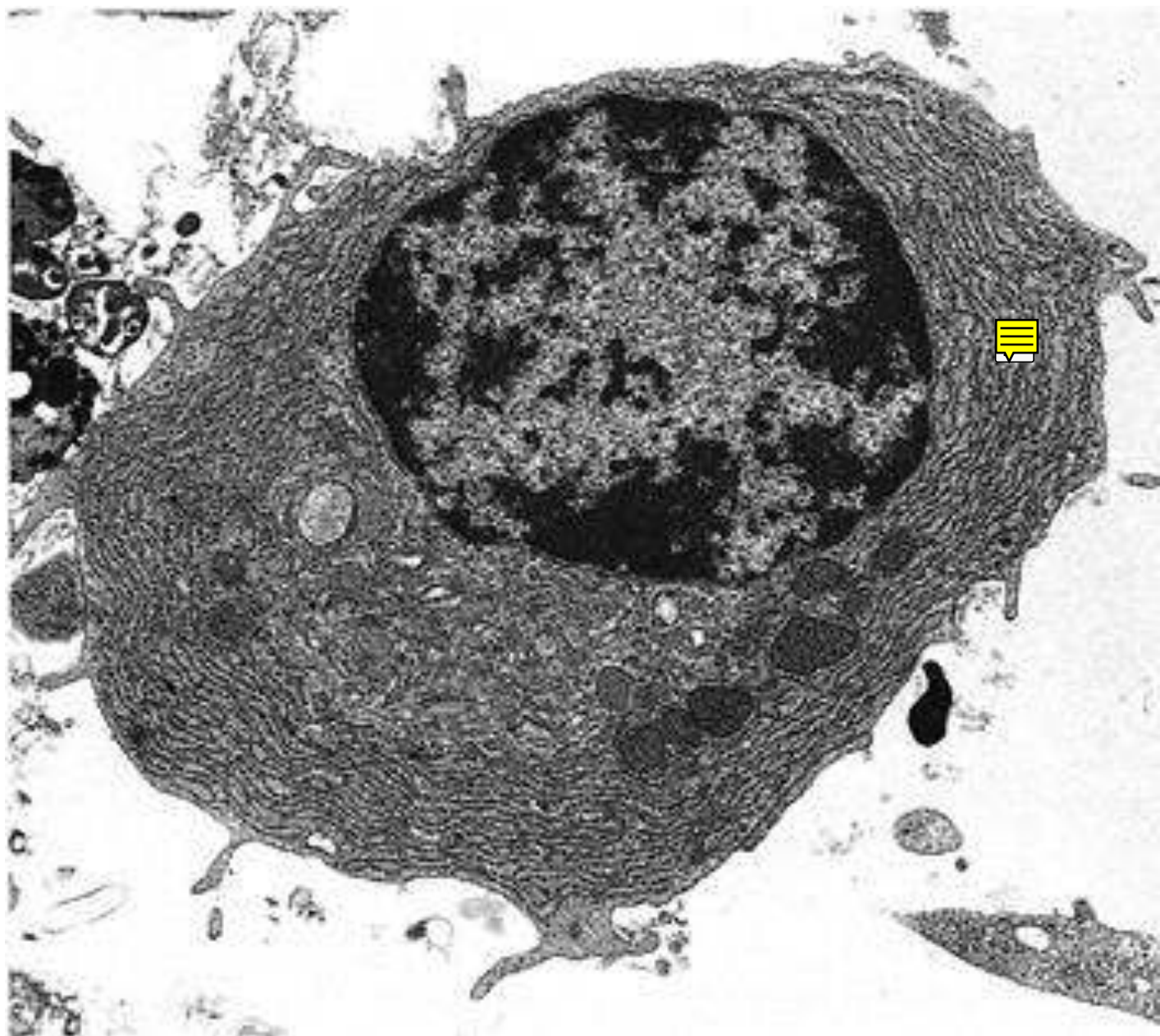


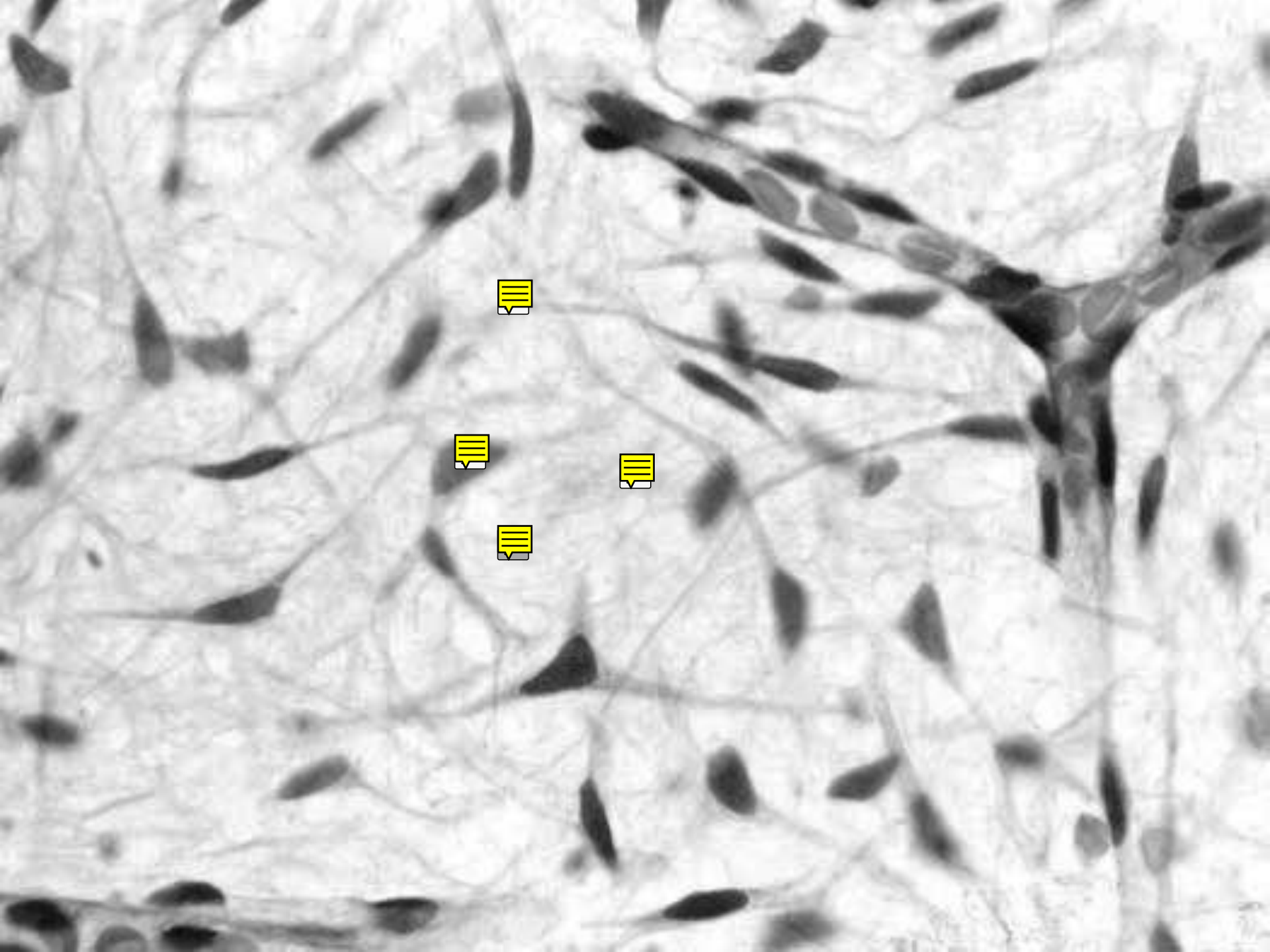




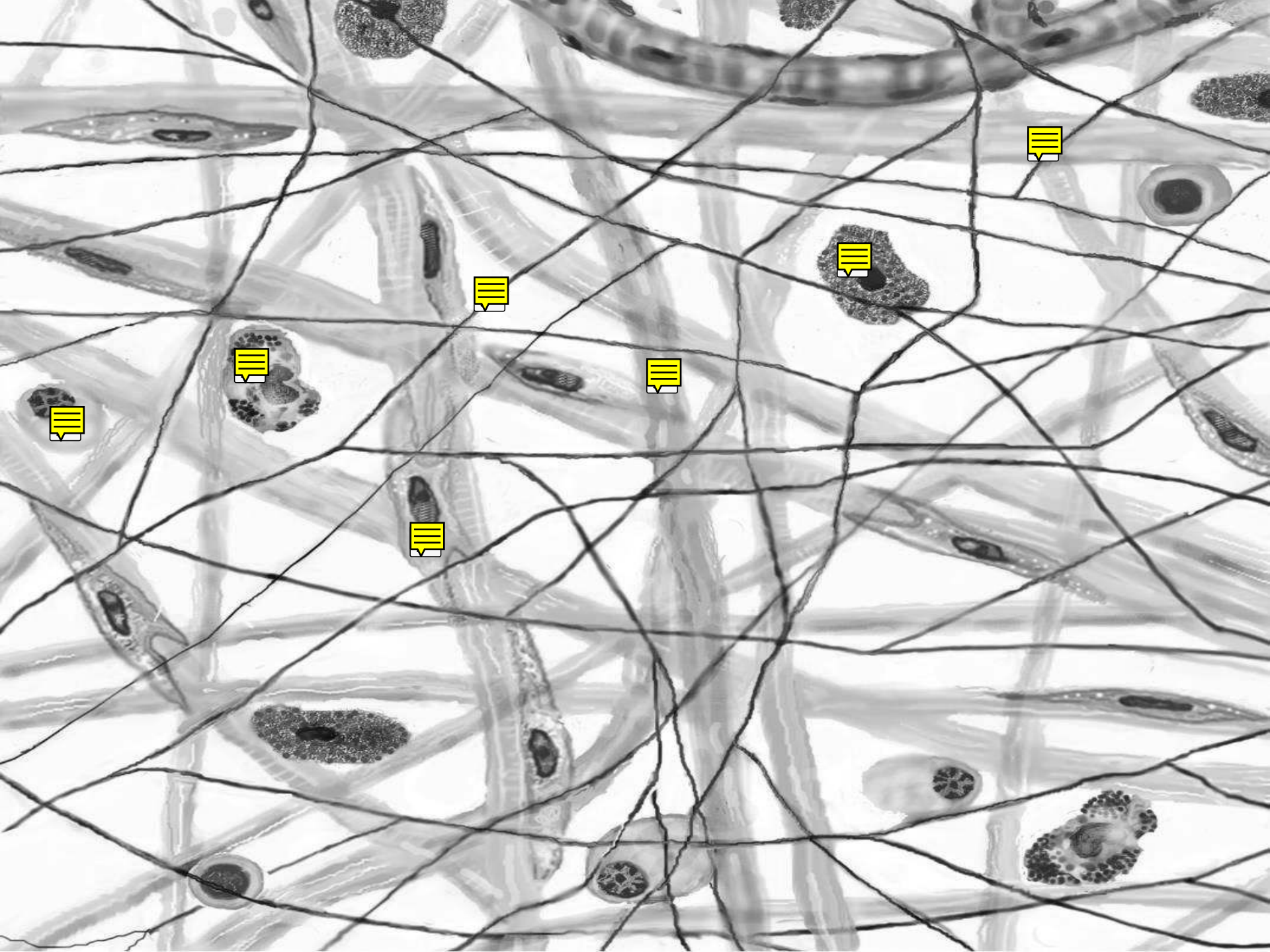


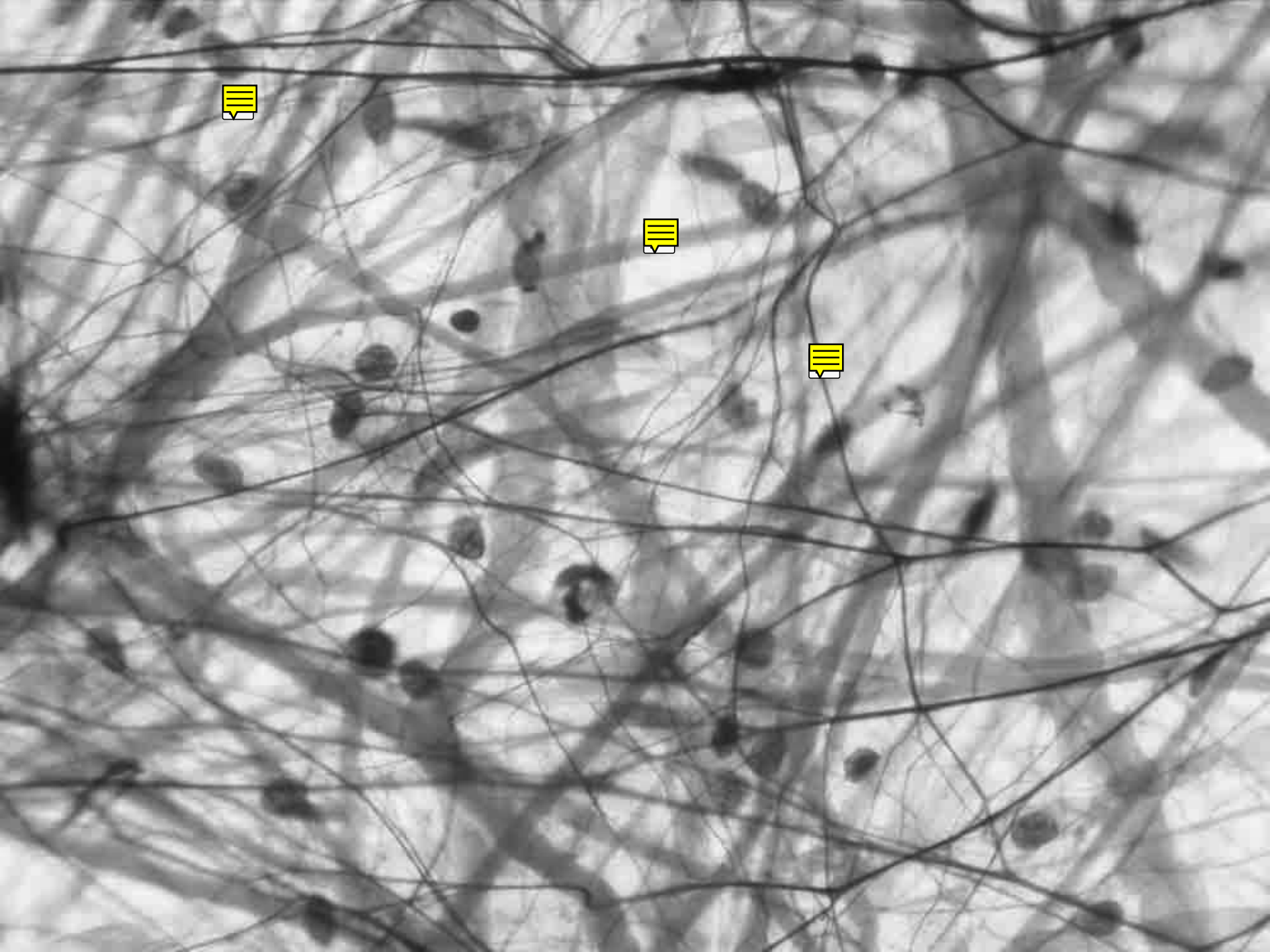




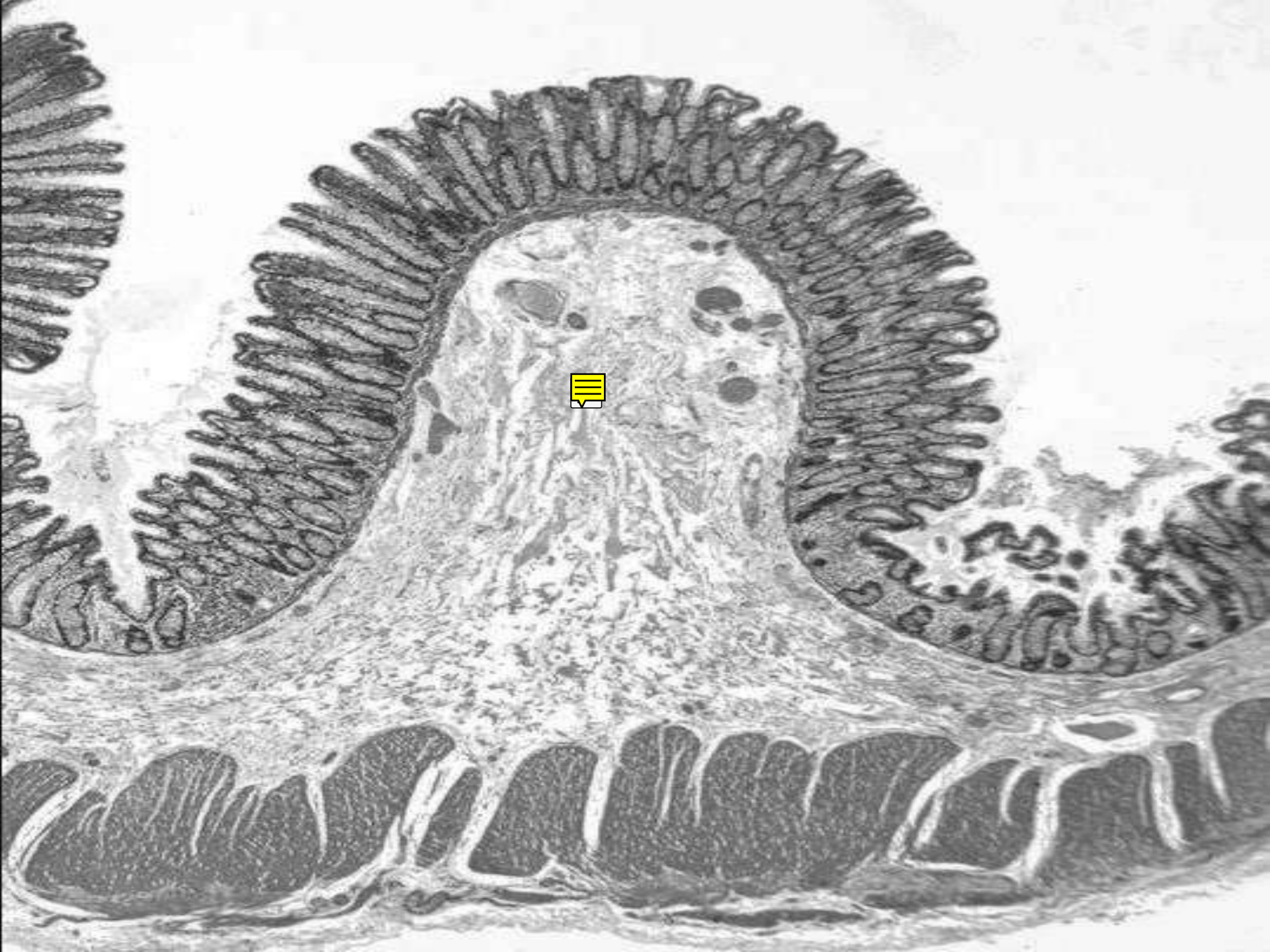







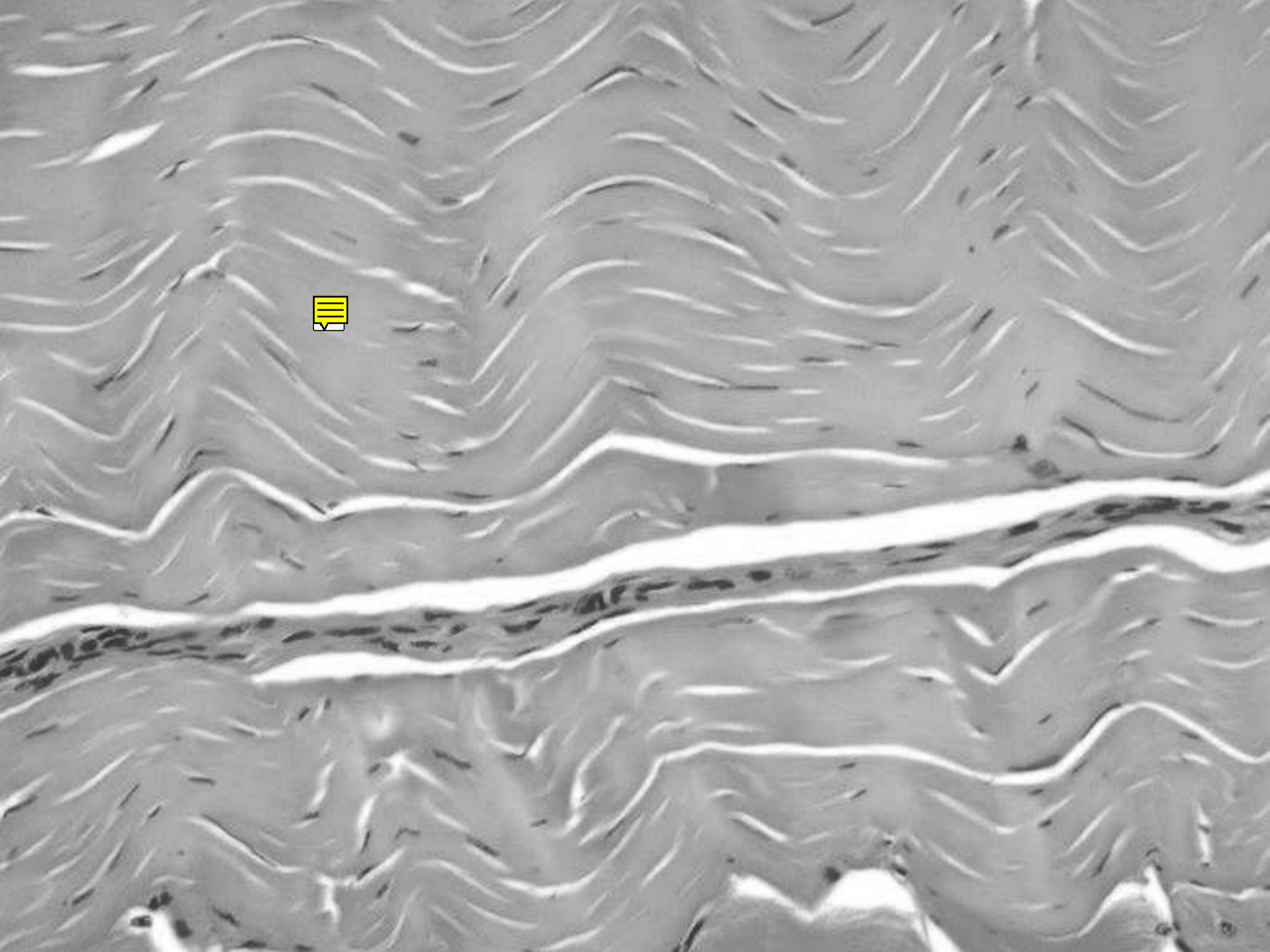






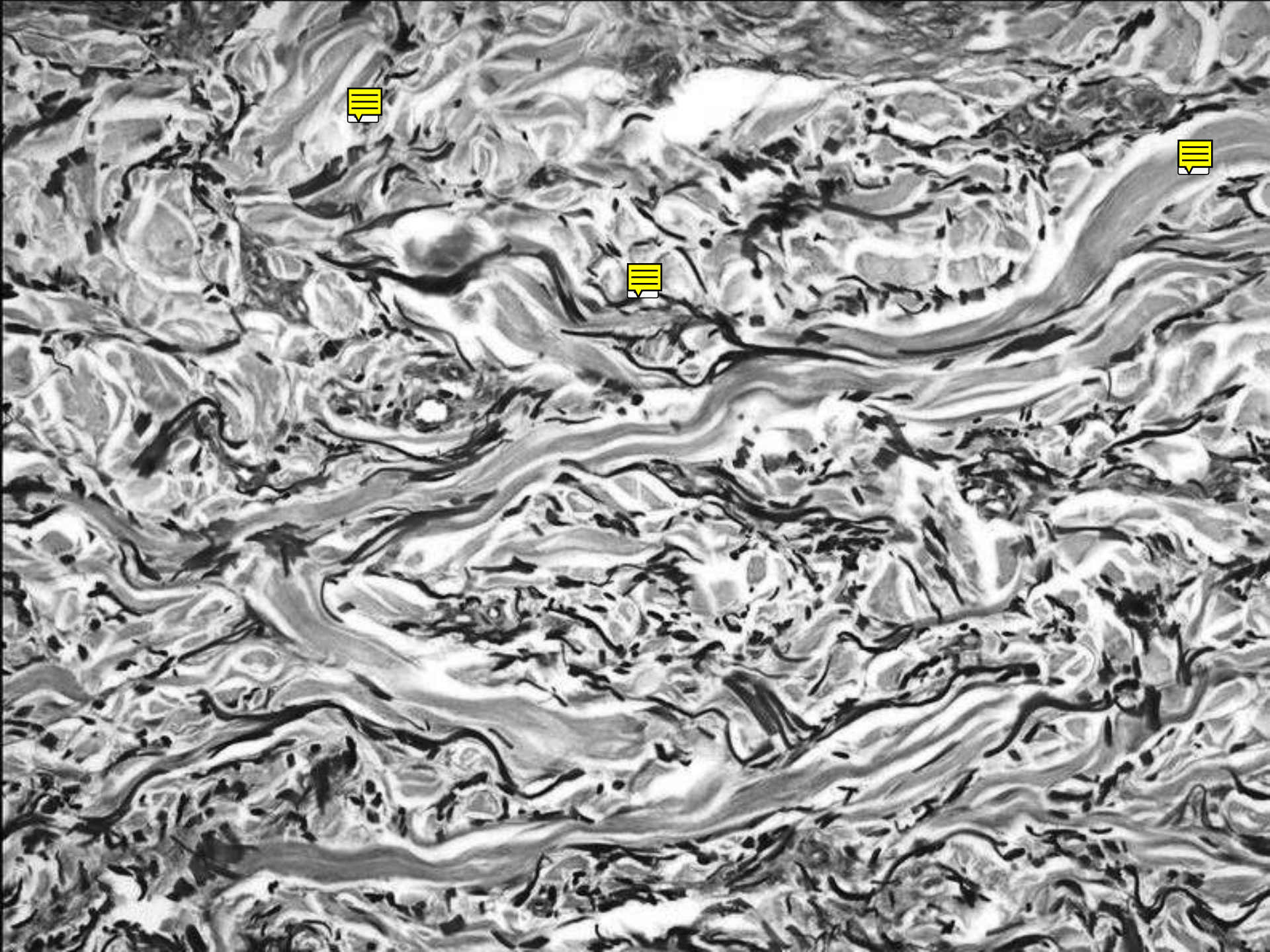




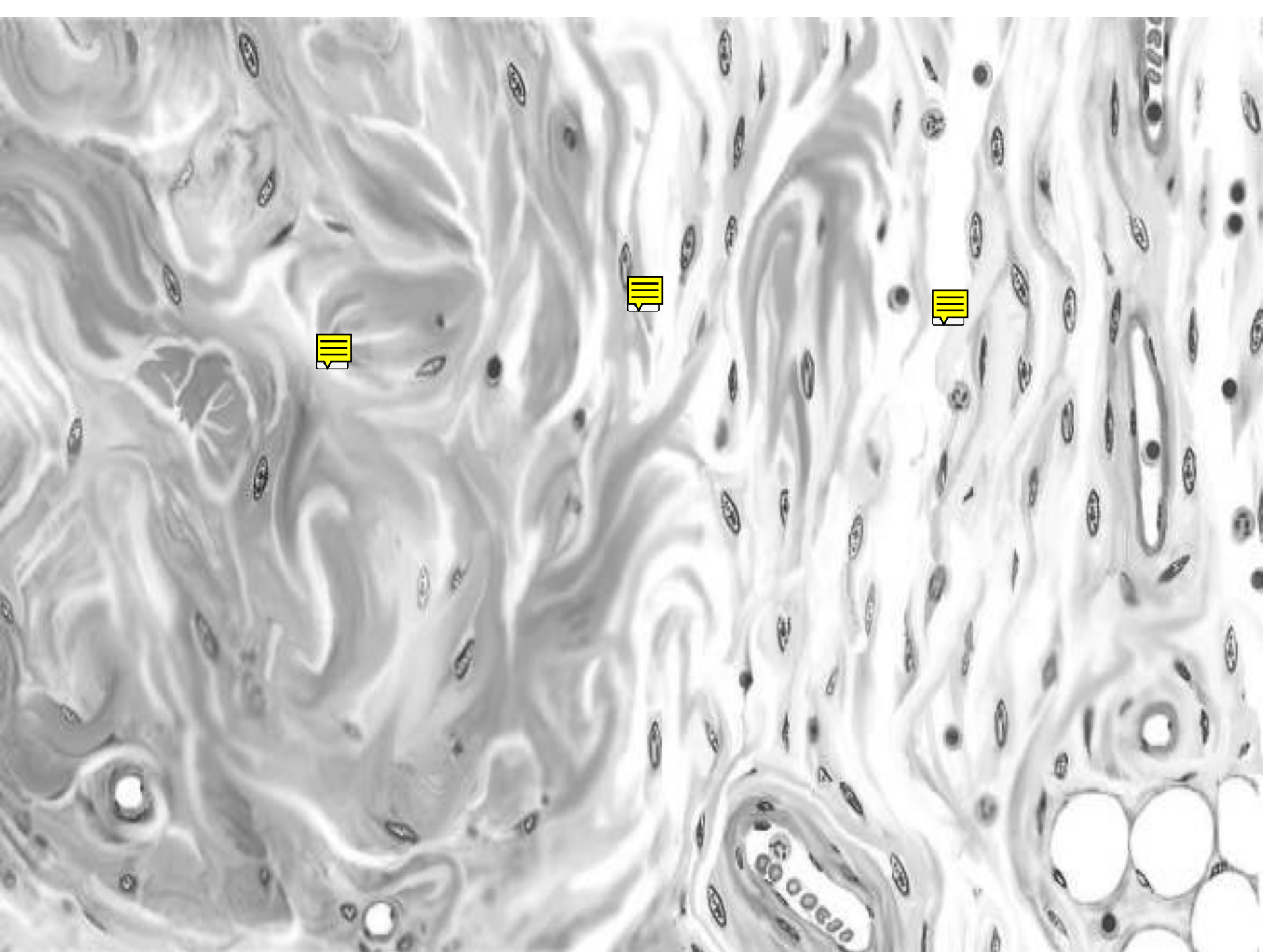














A



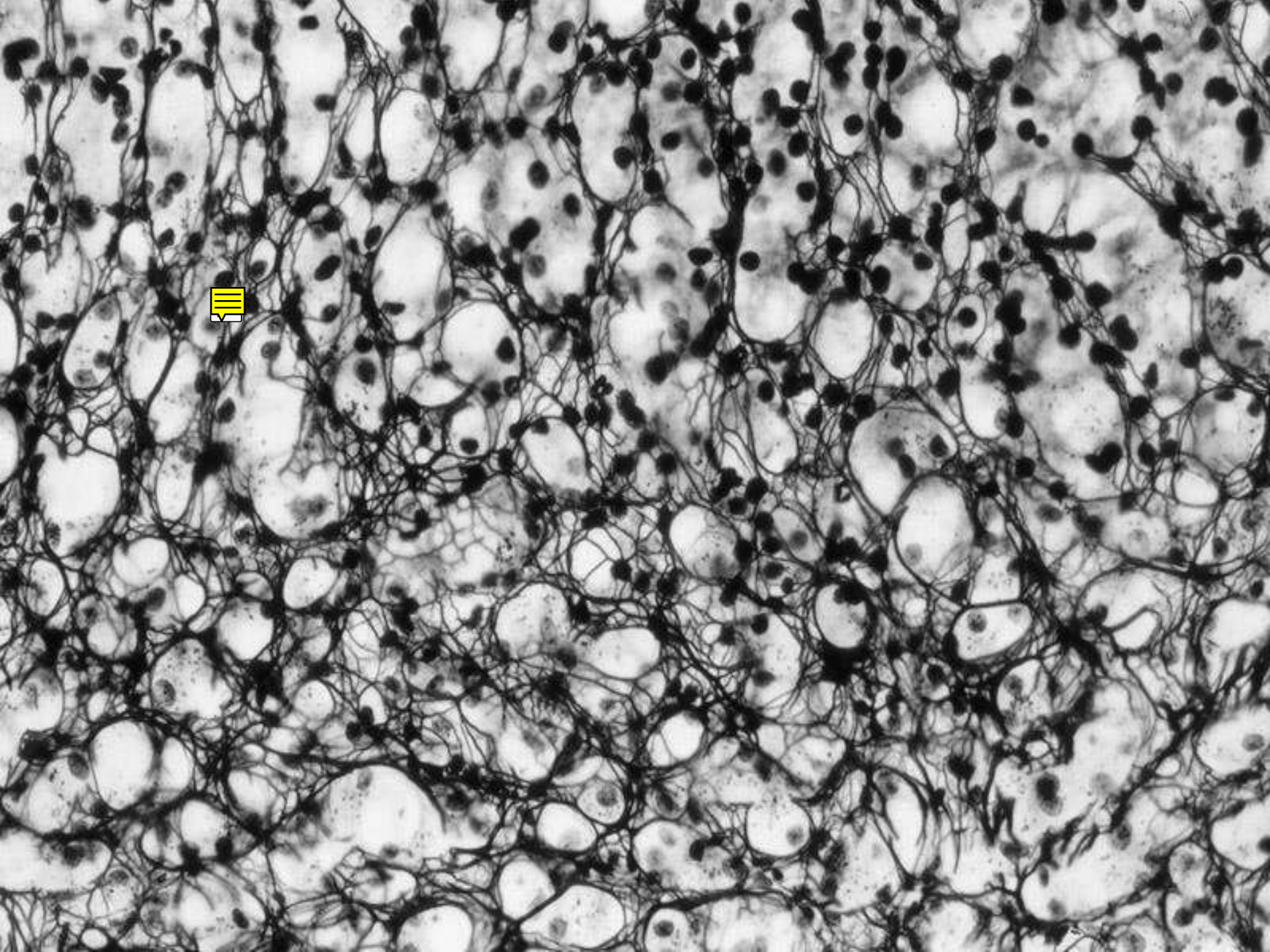
C



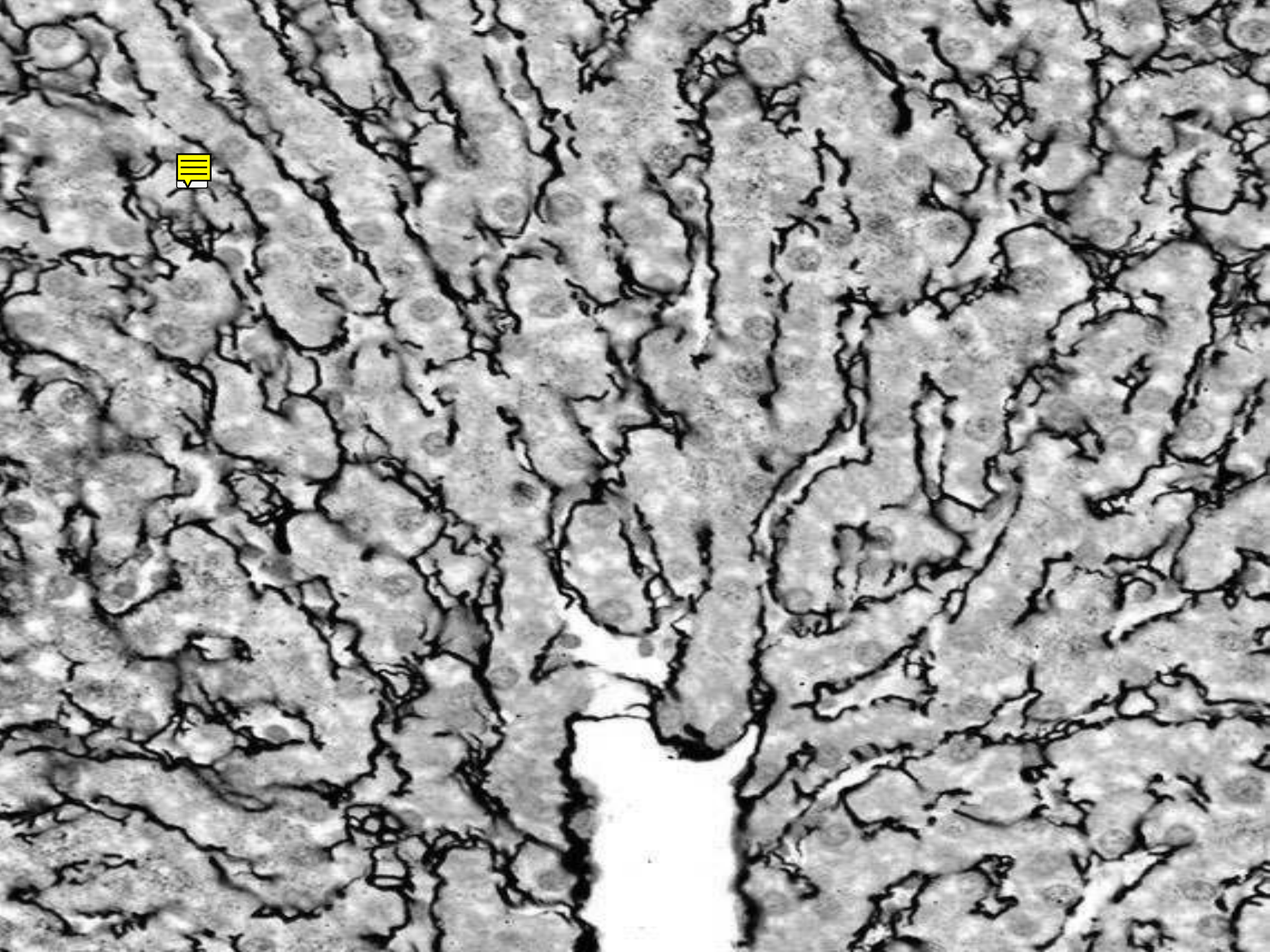
B



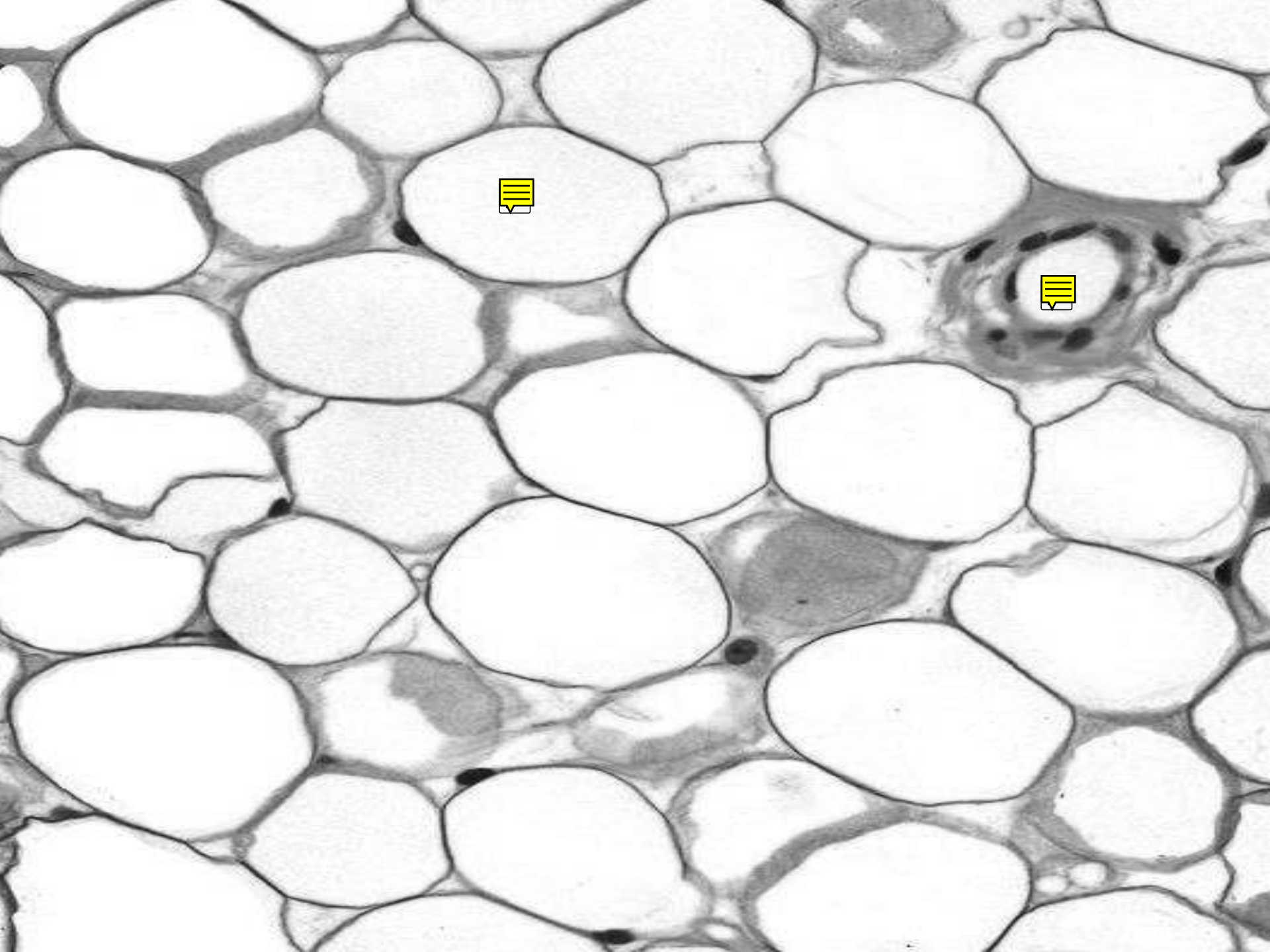


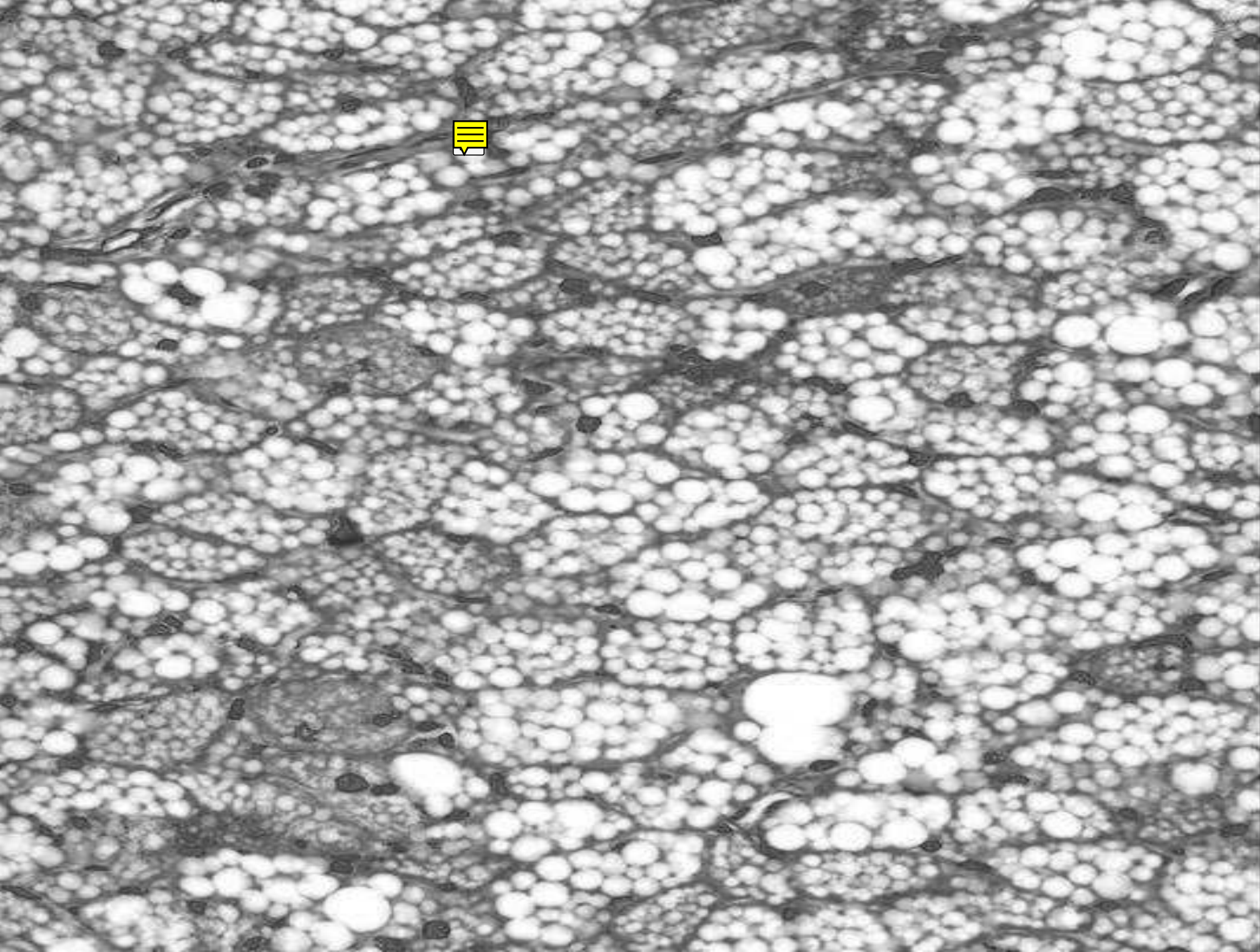






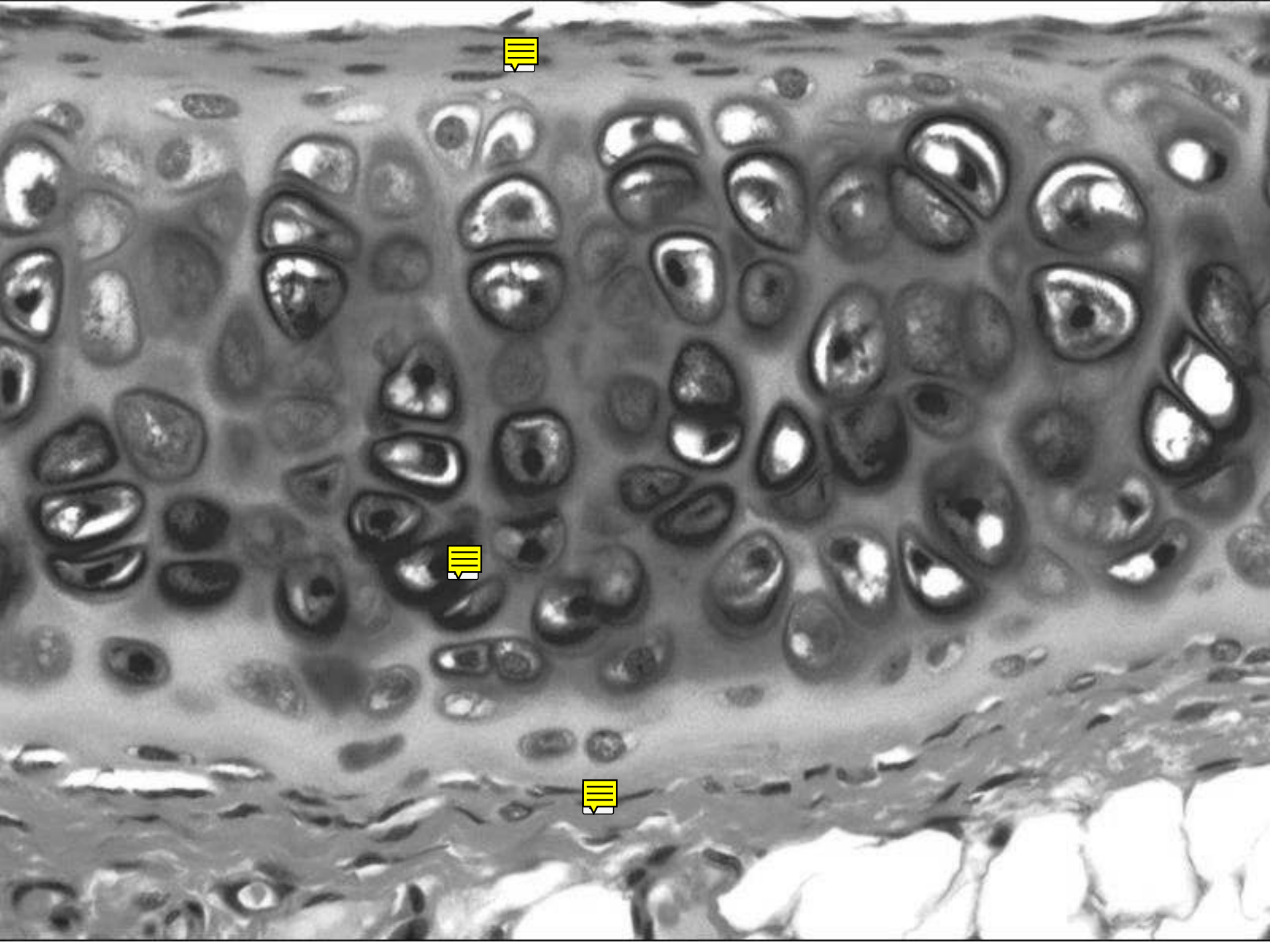




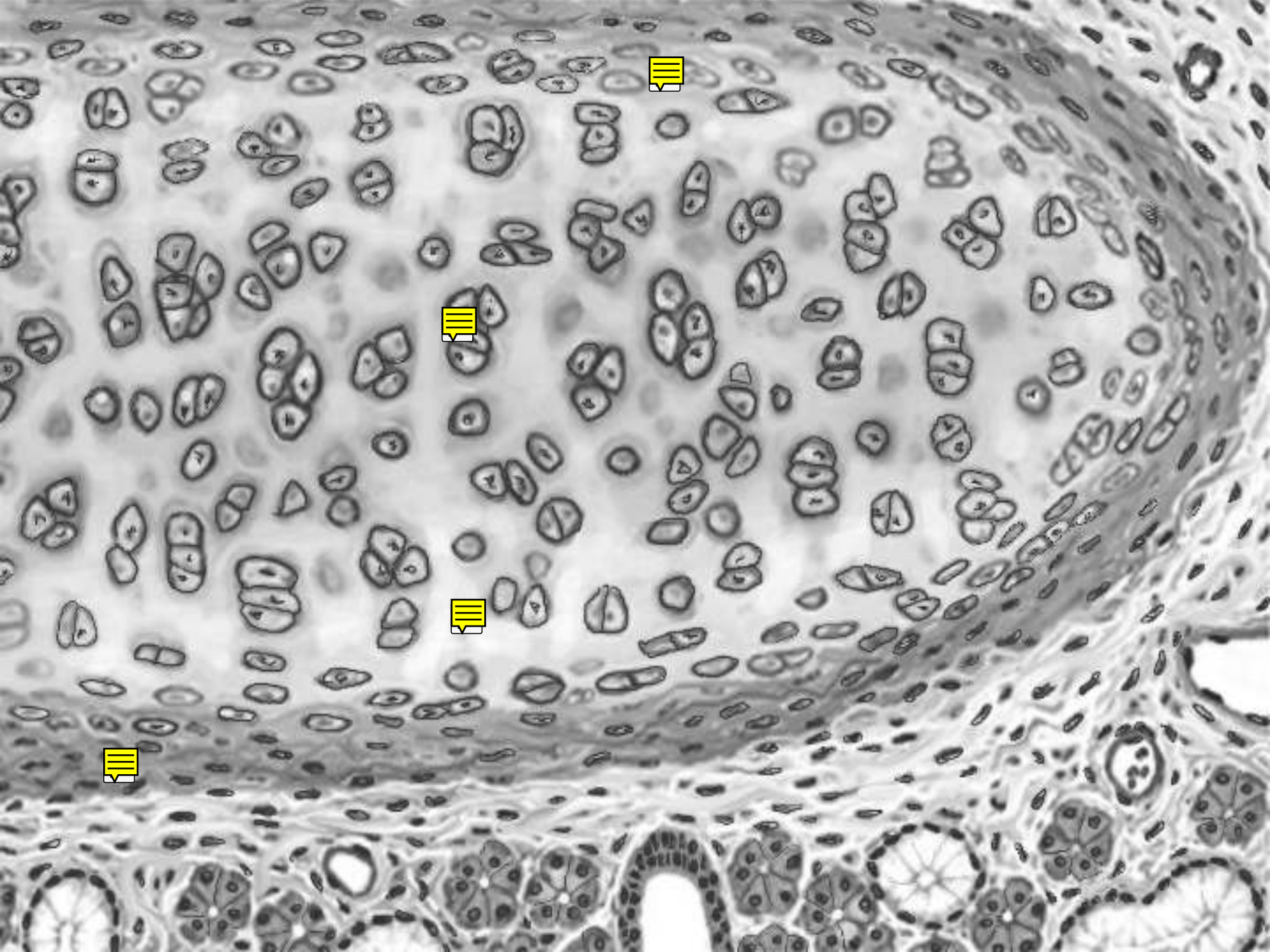


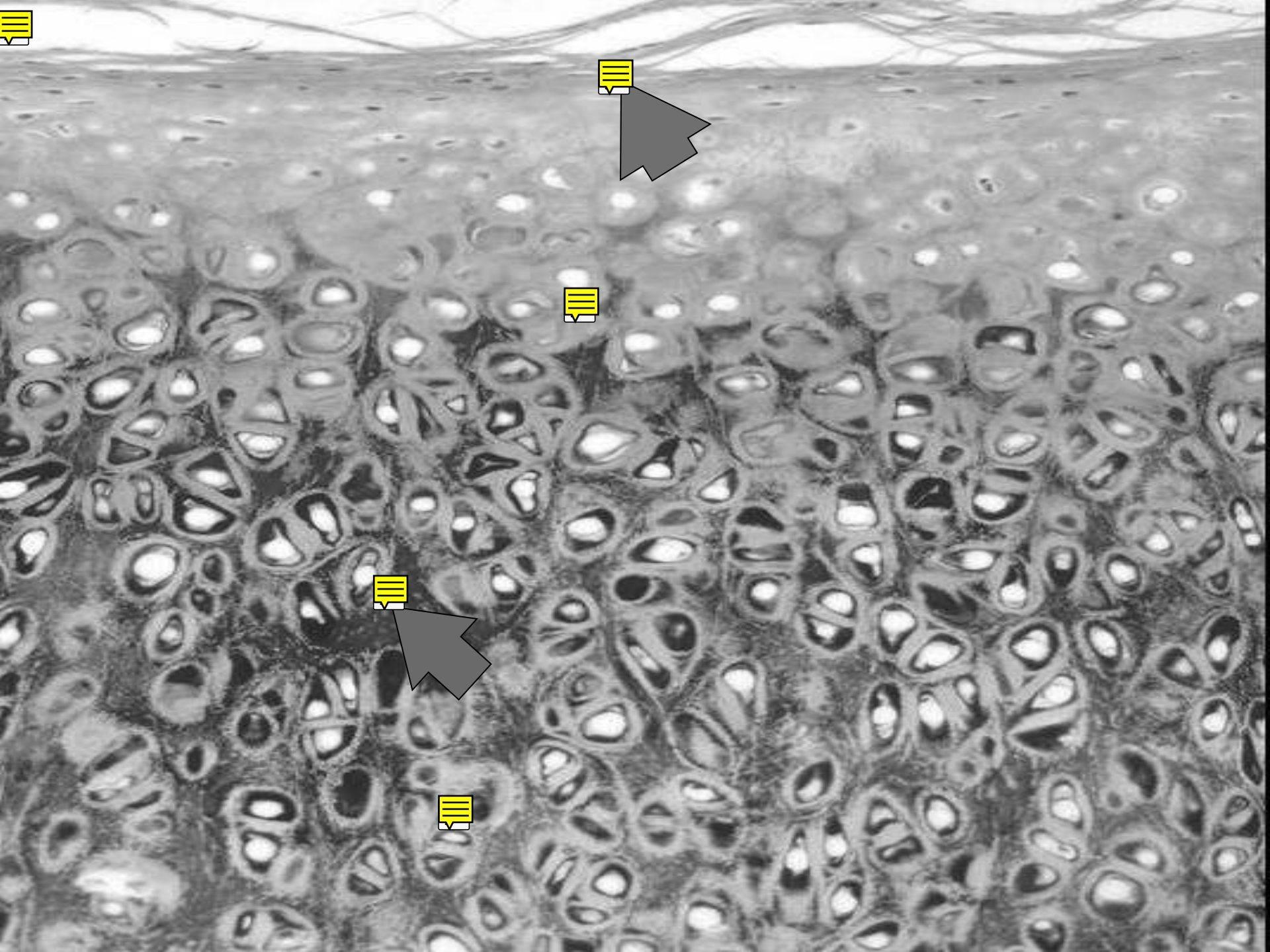


# Cartilage

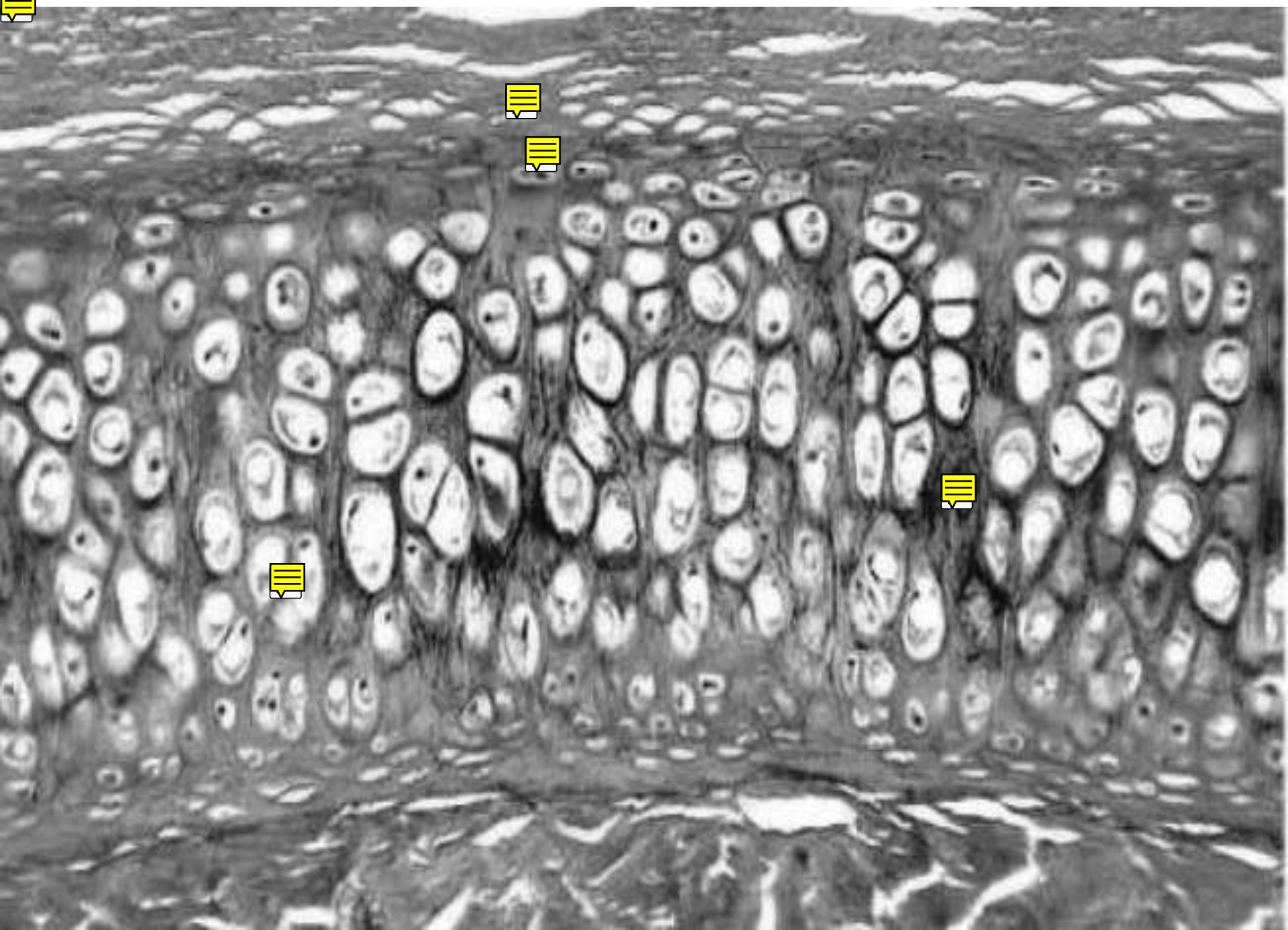


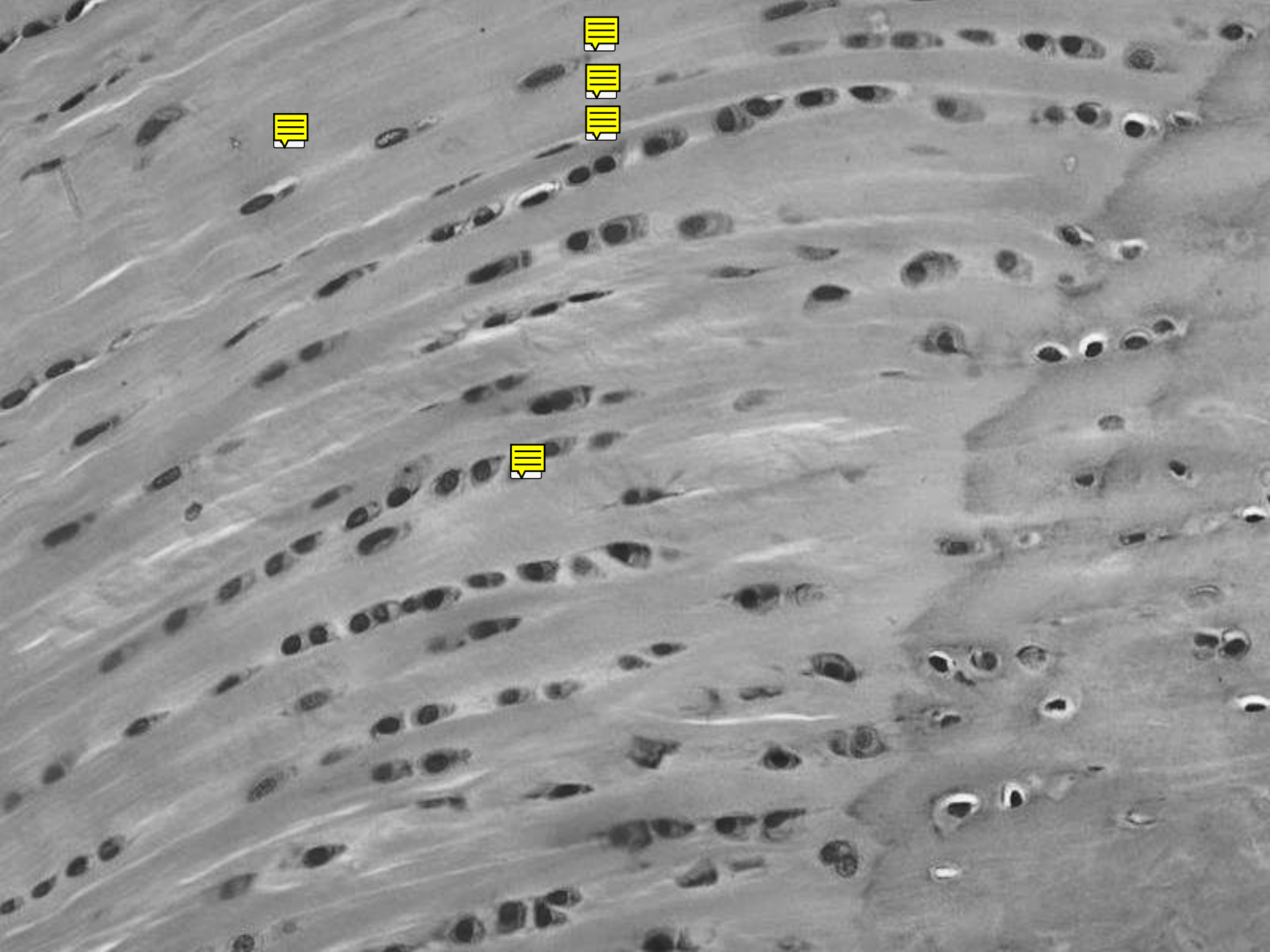




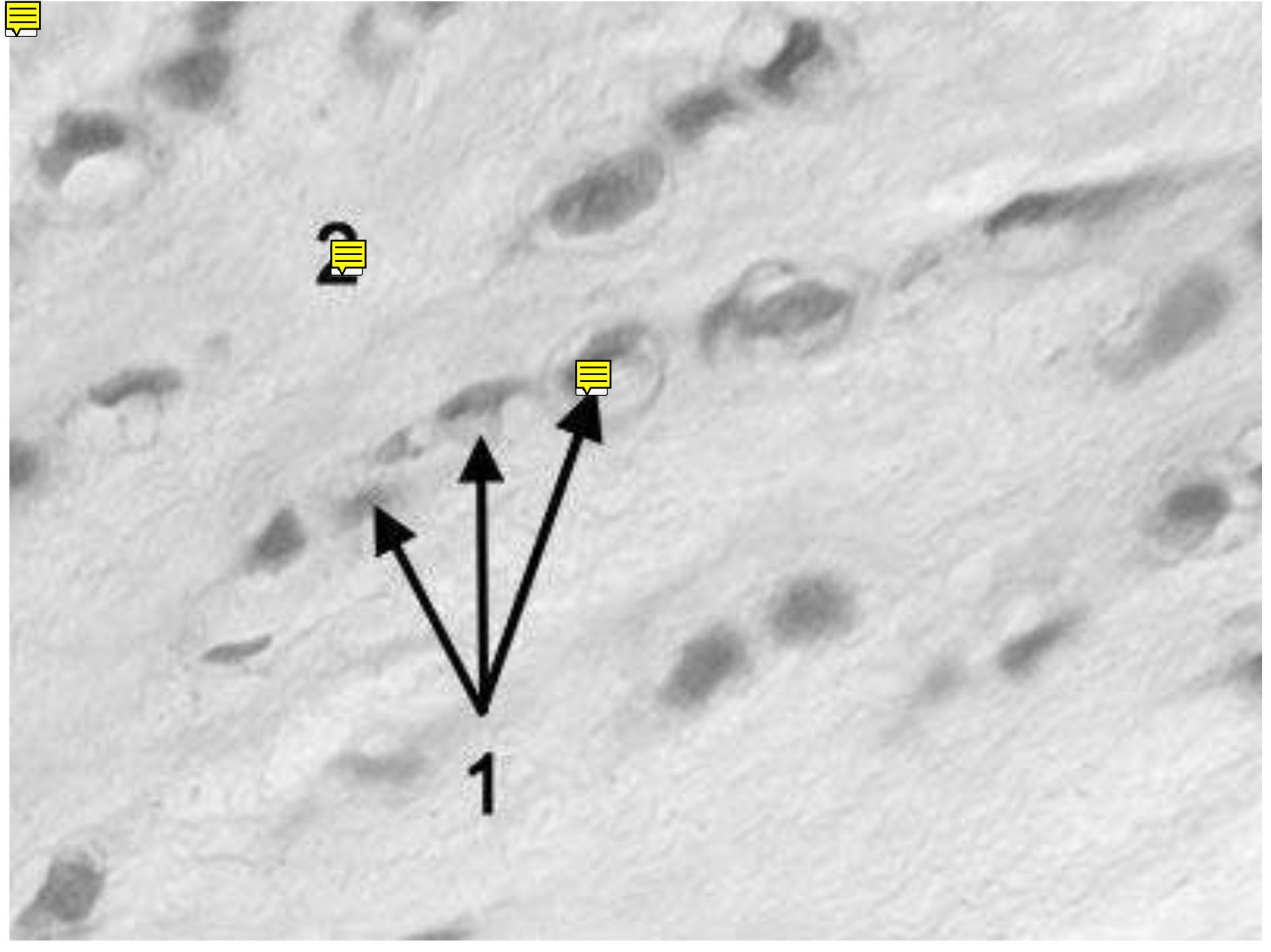








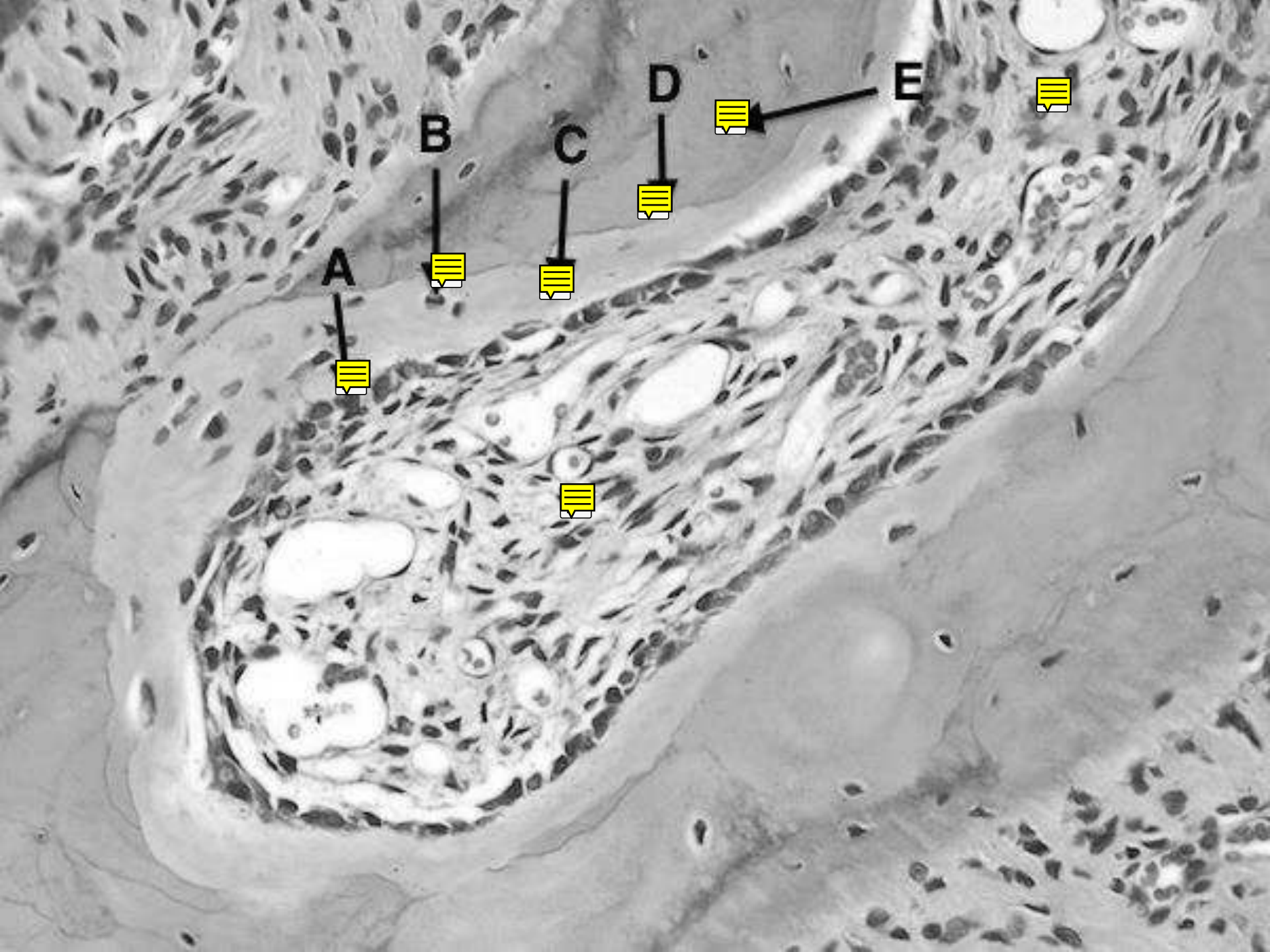


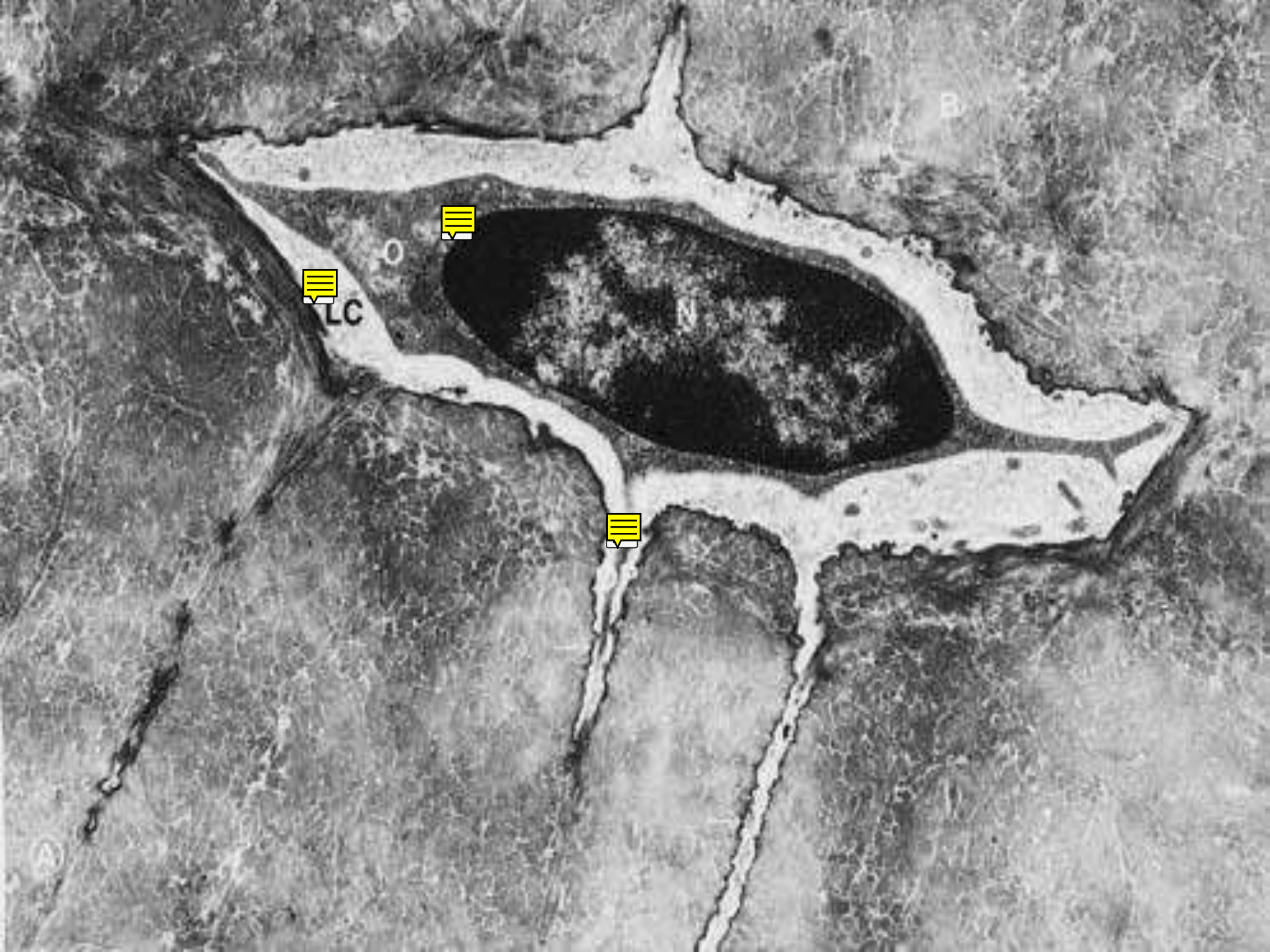


1

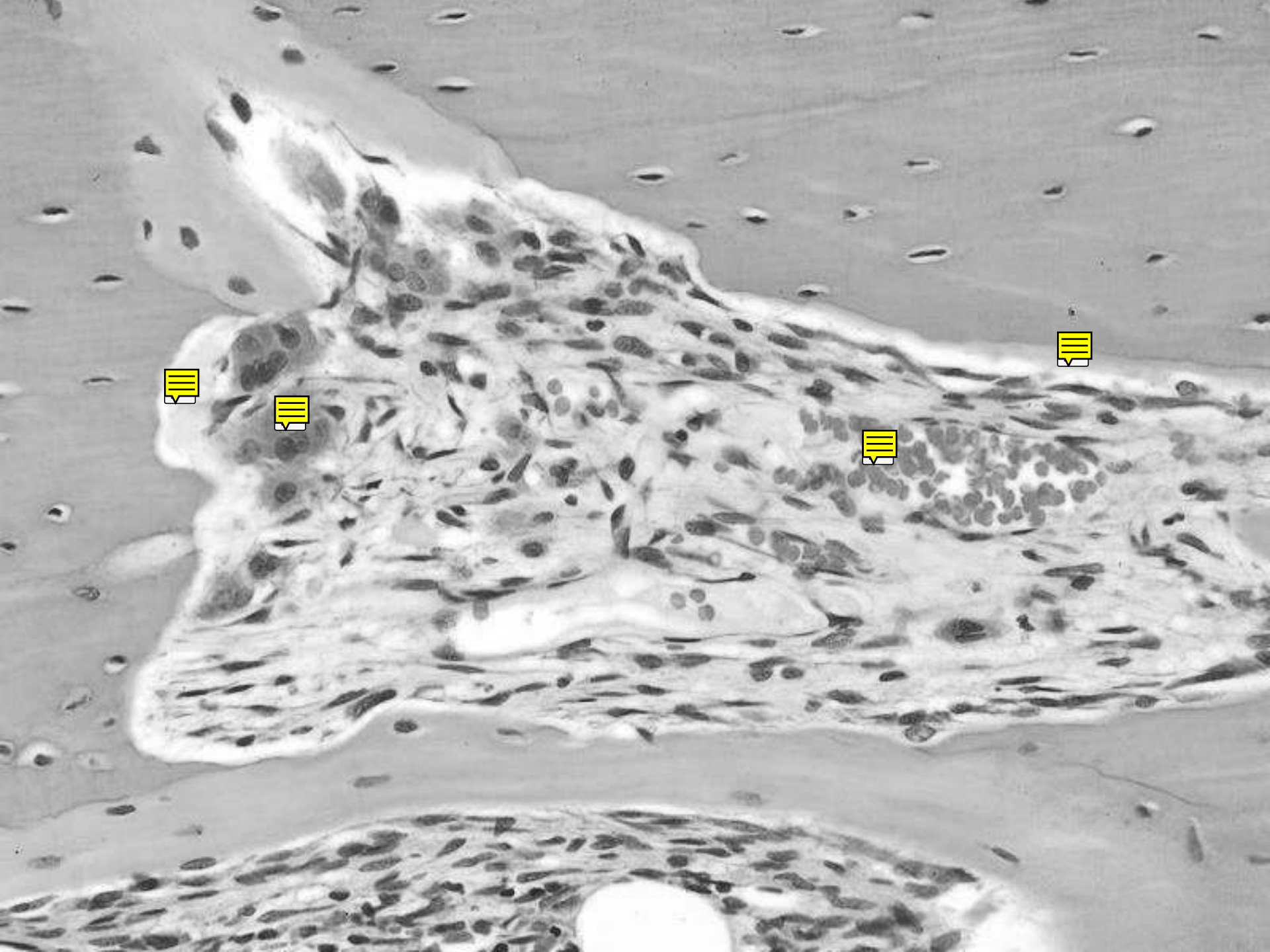
Bone

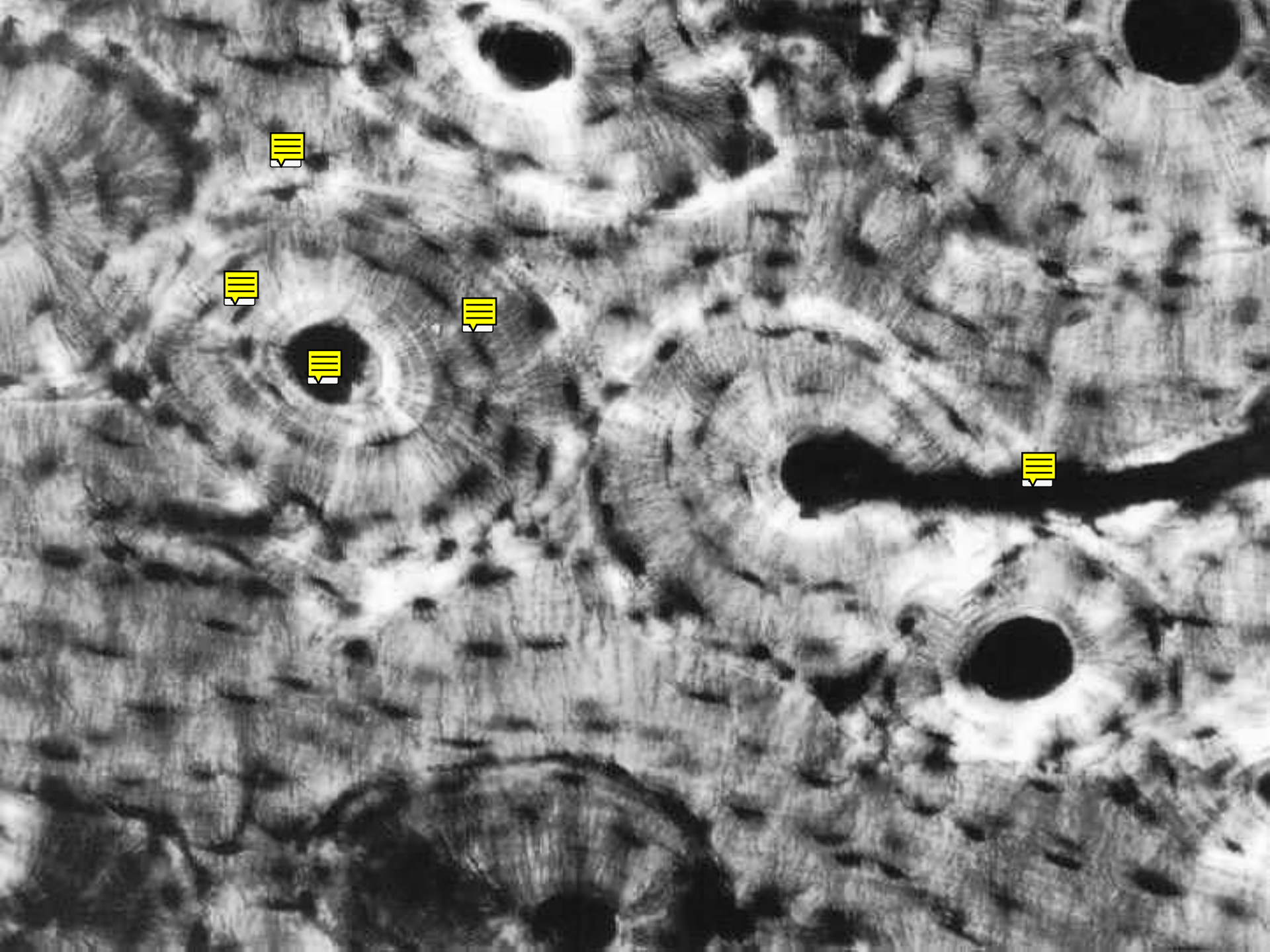




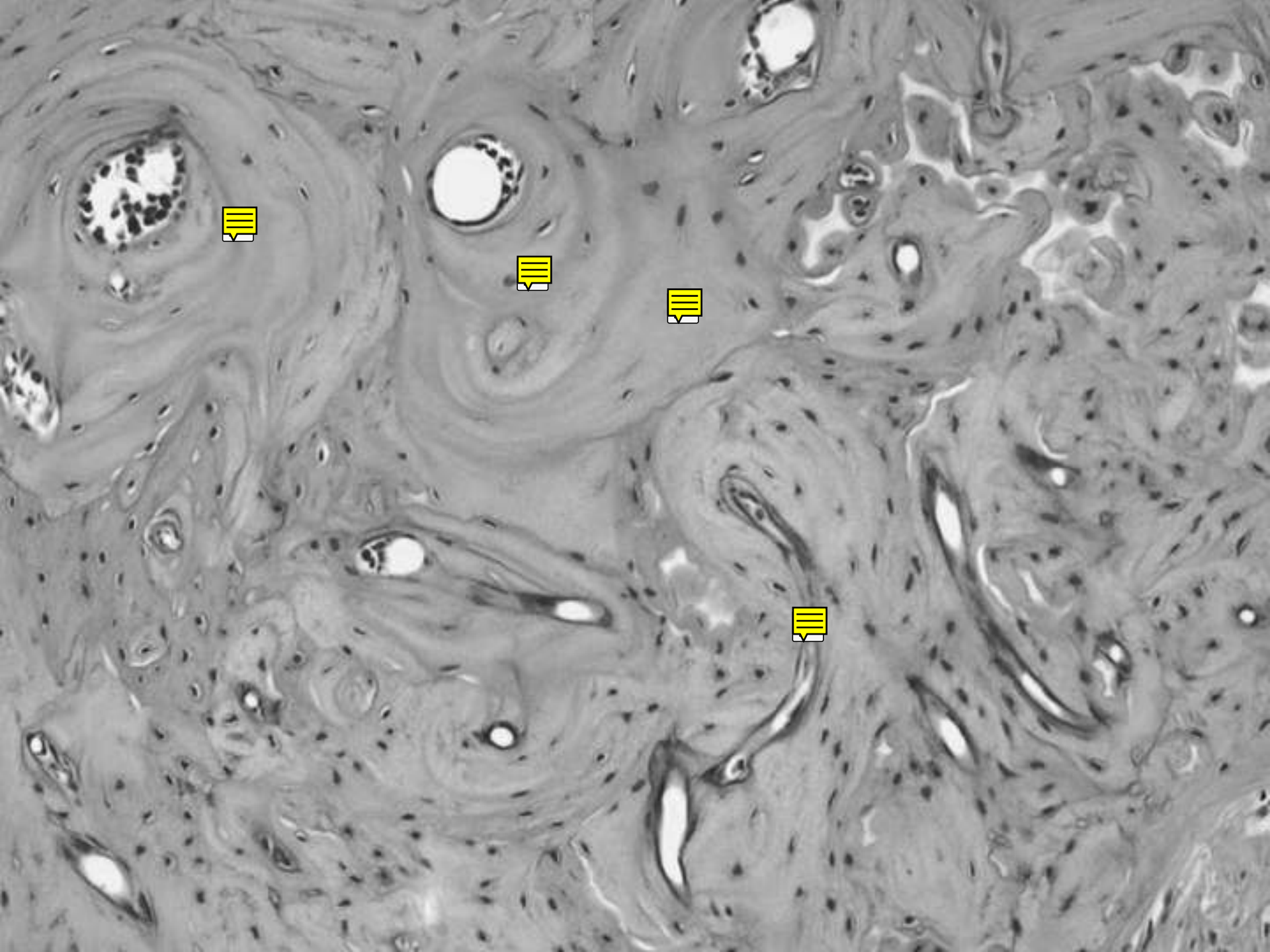


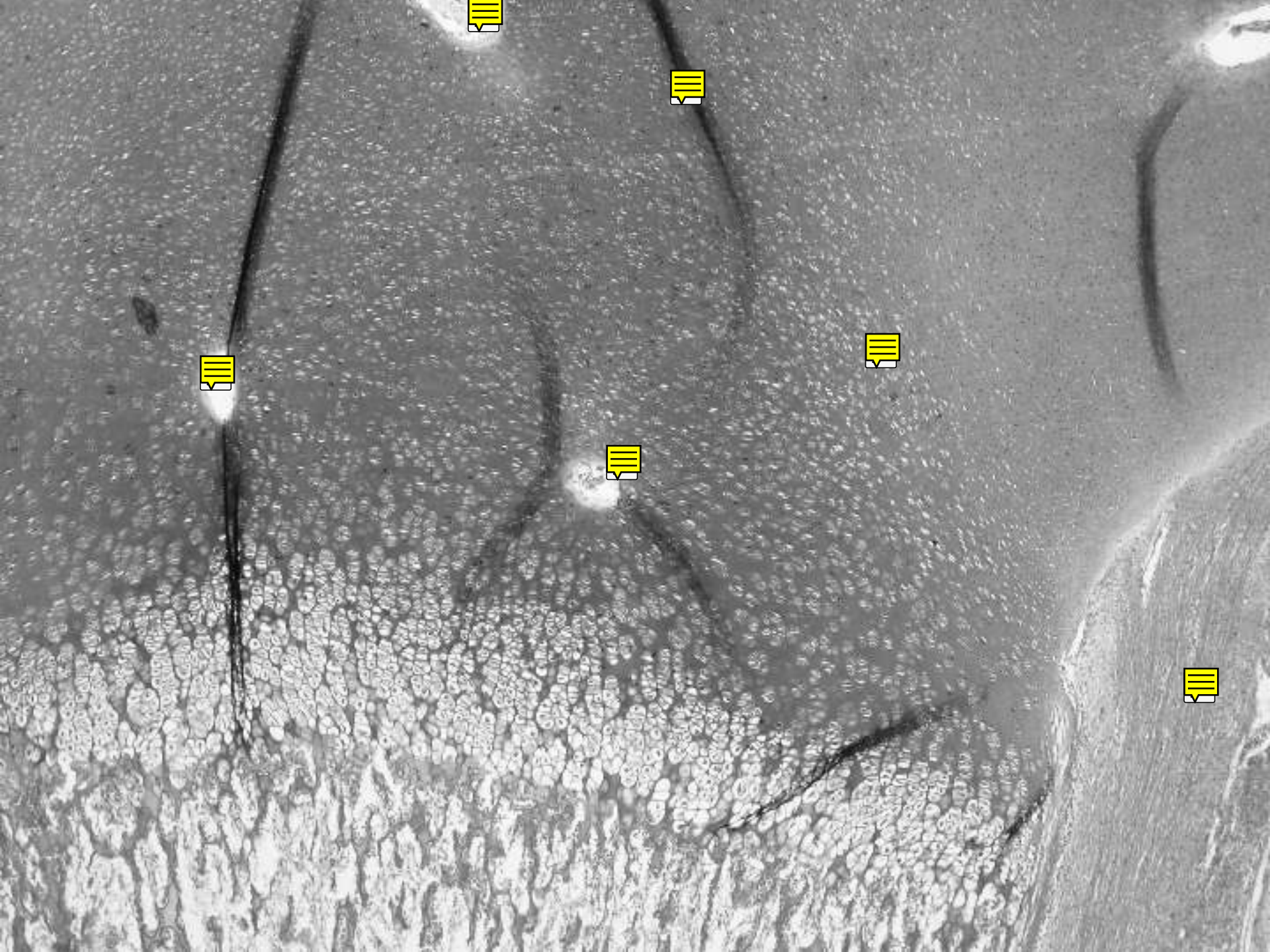




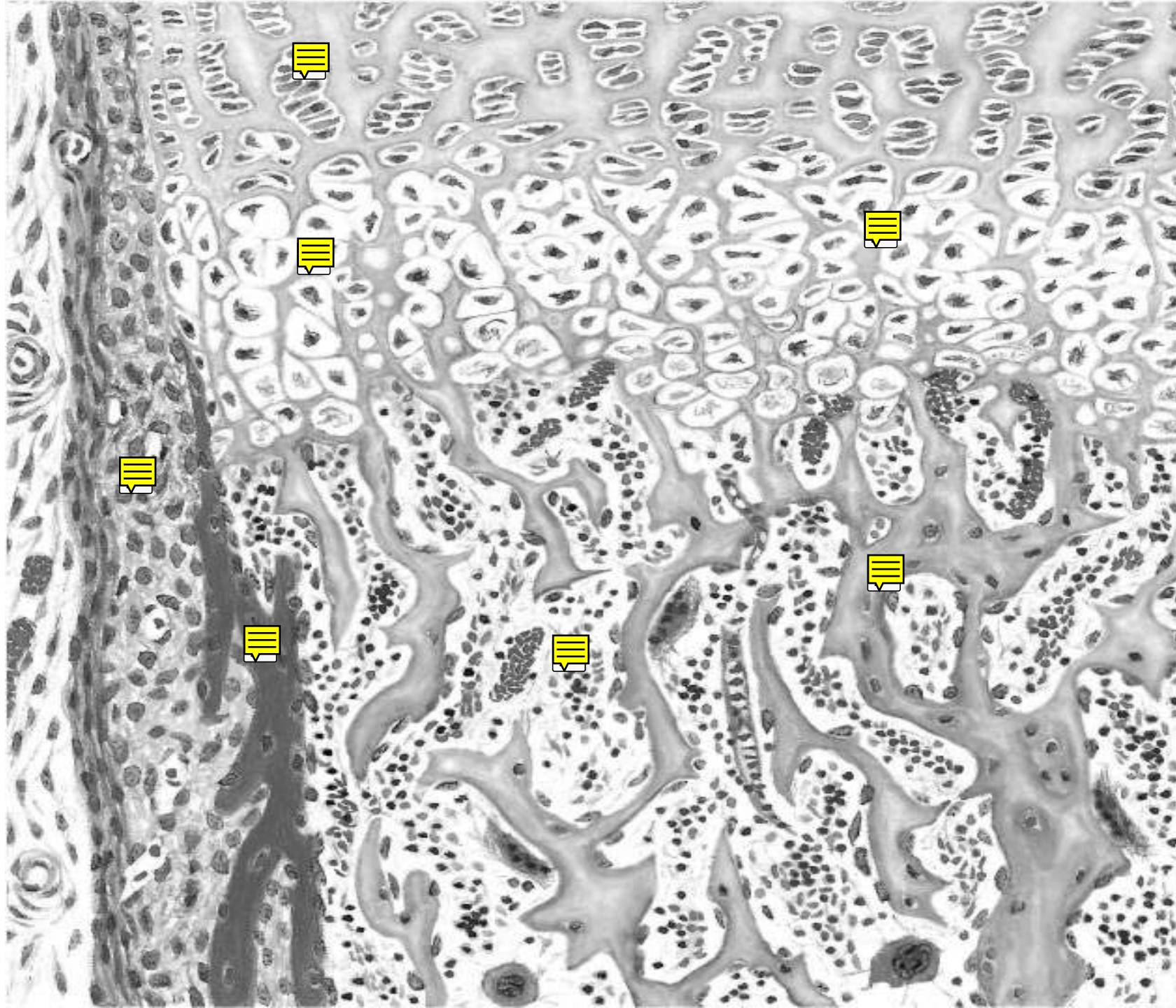




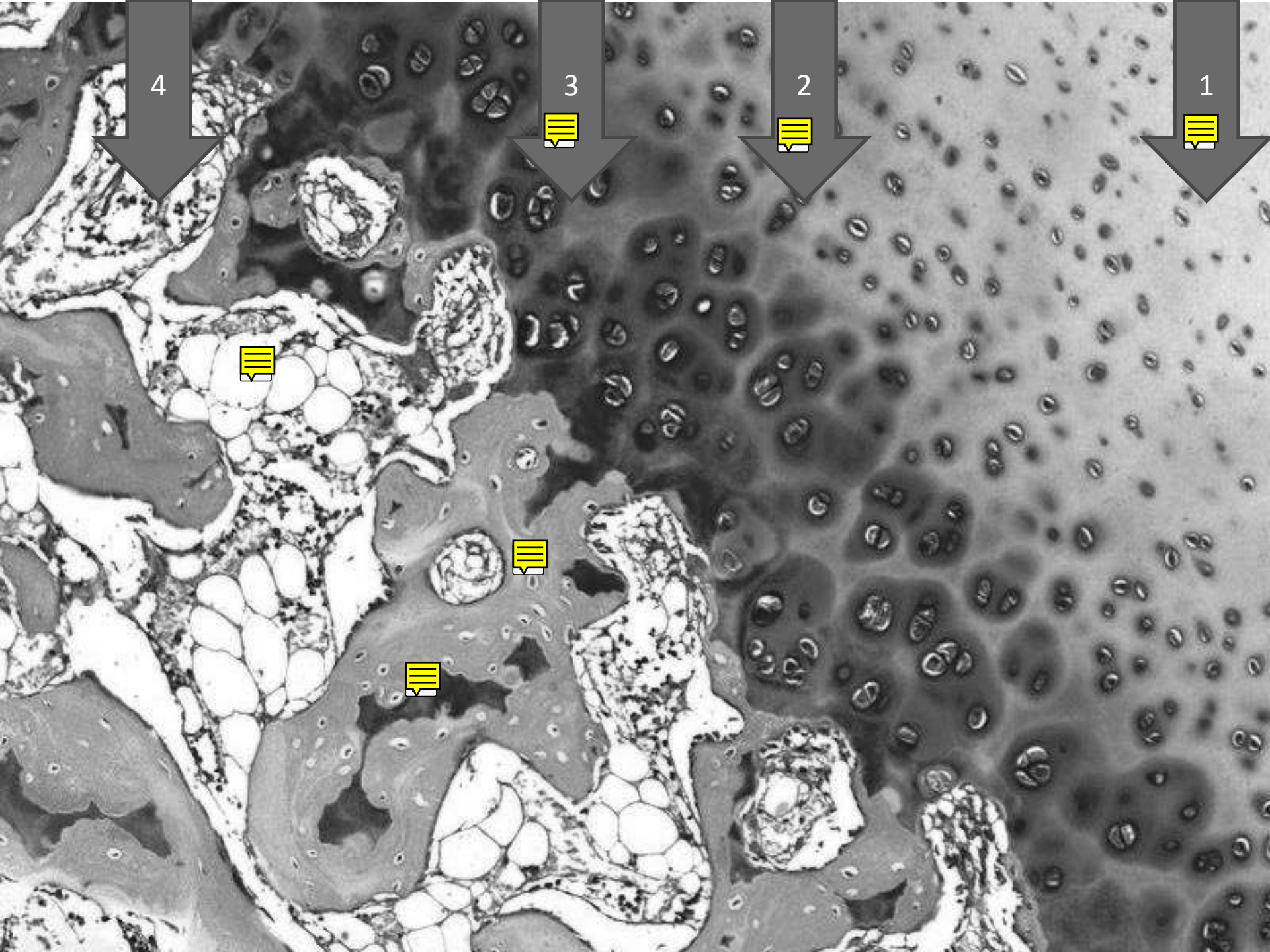




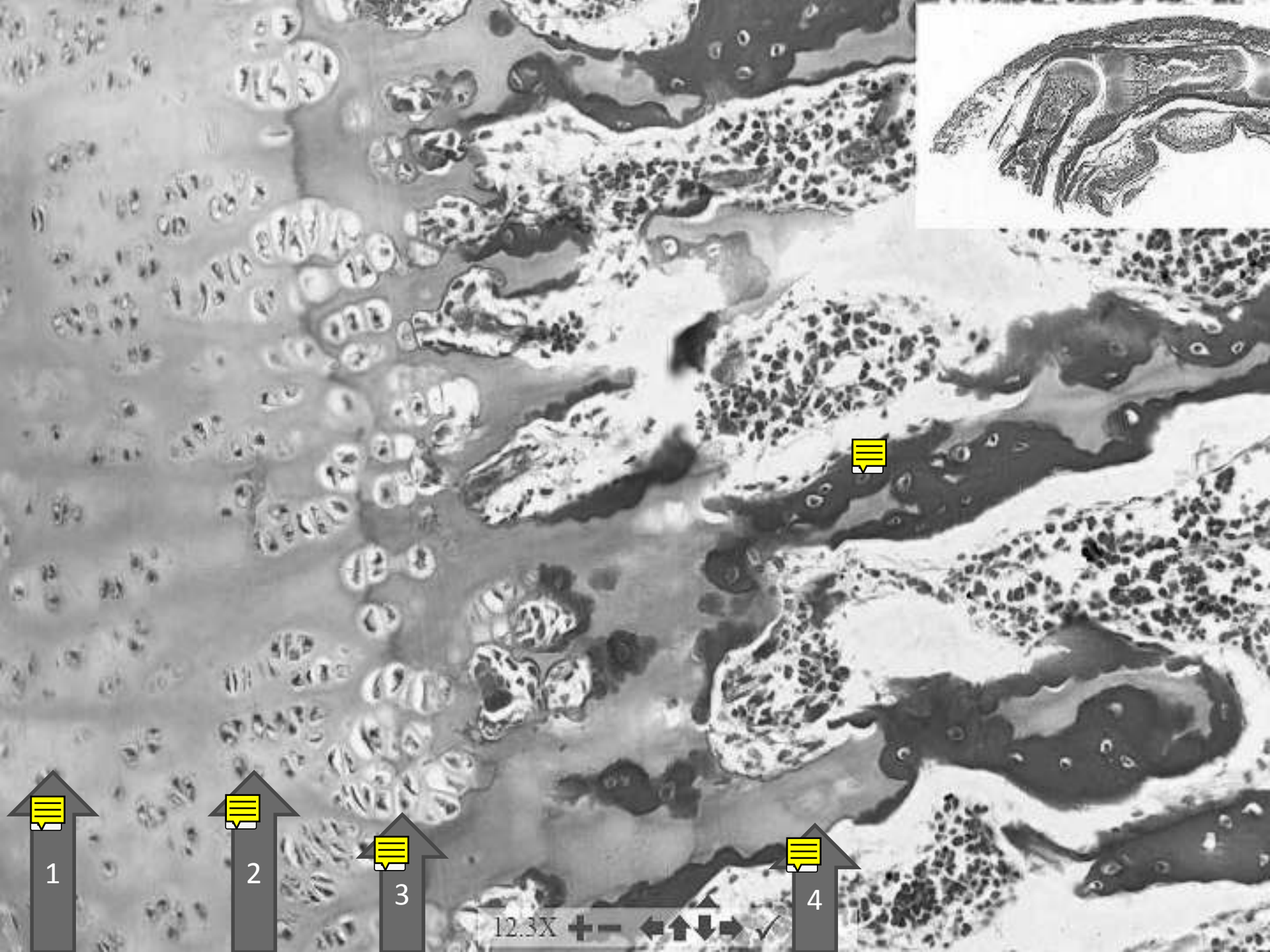


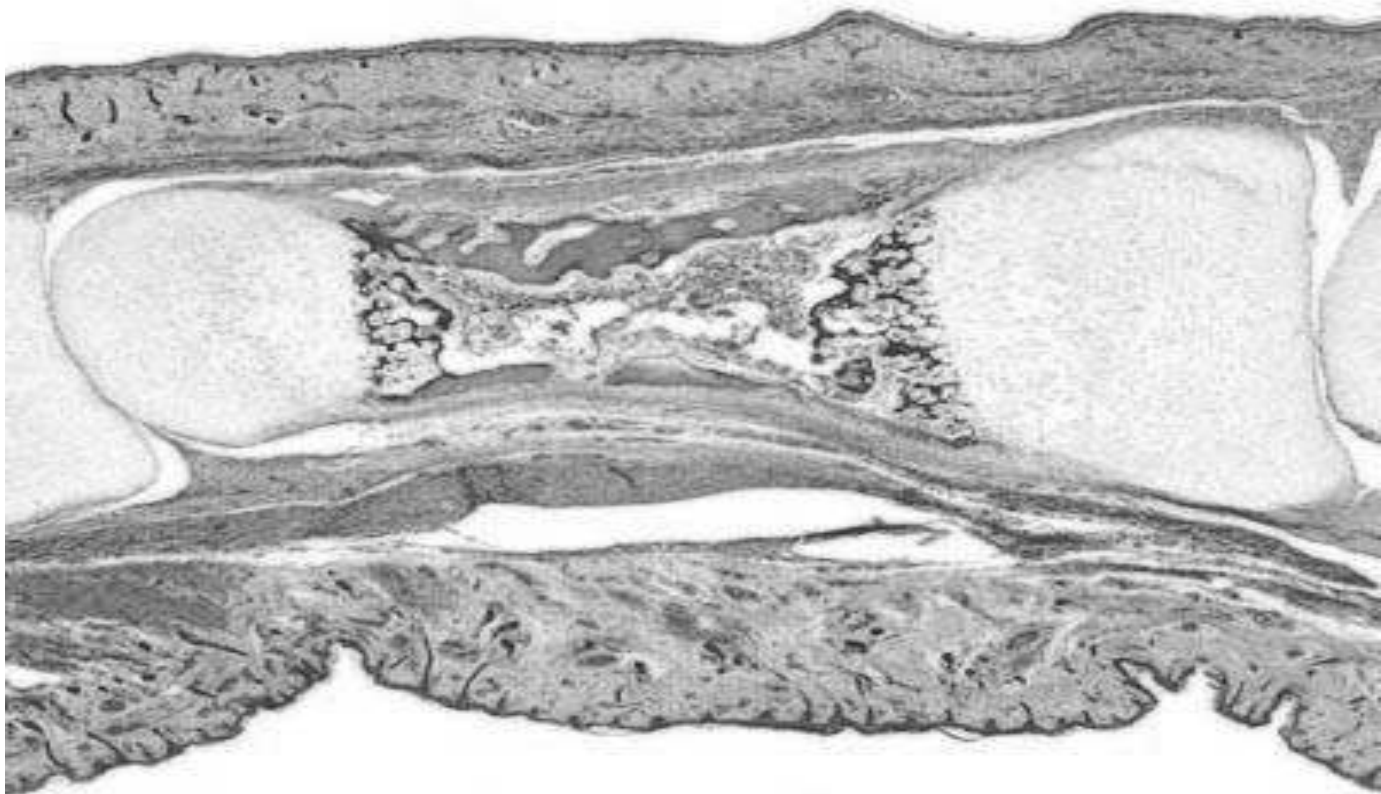




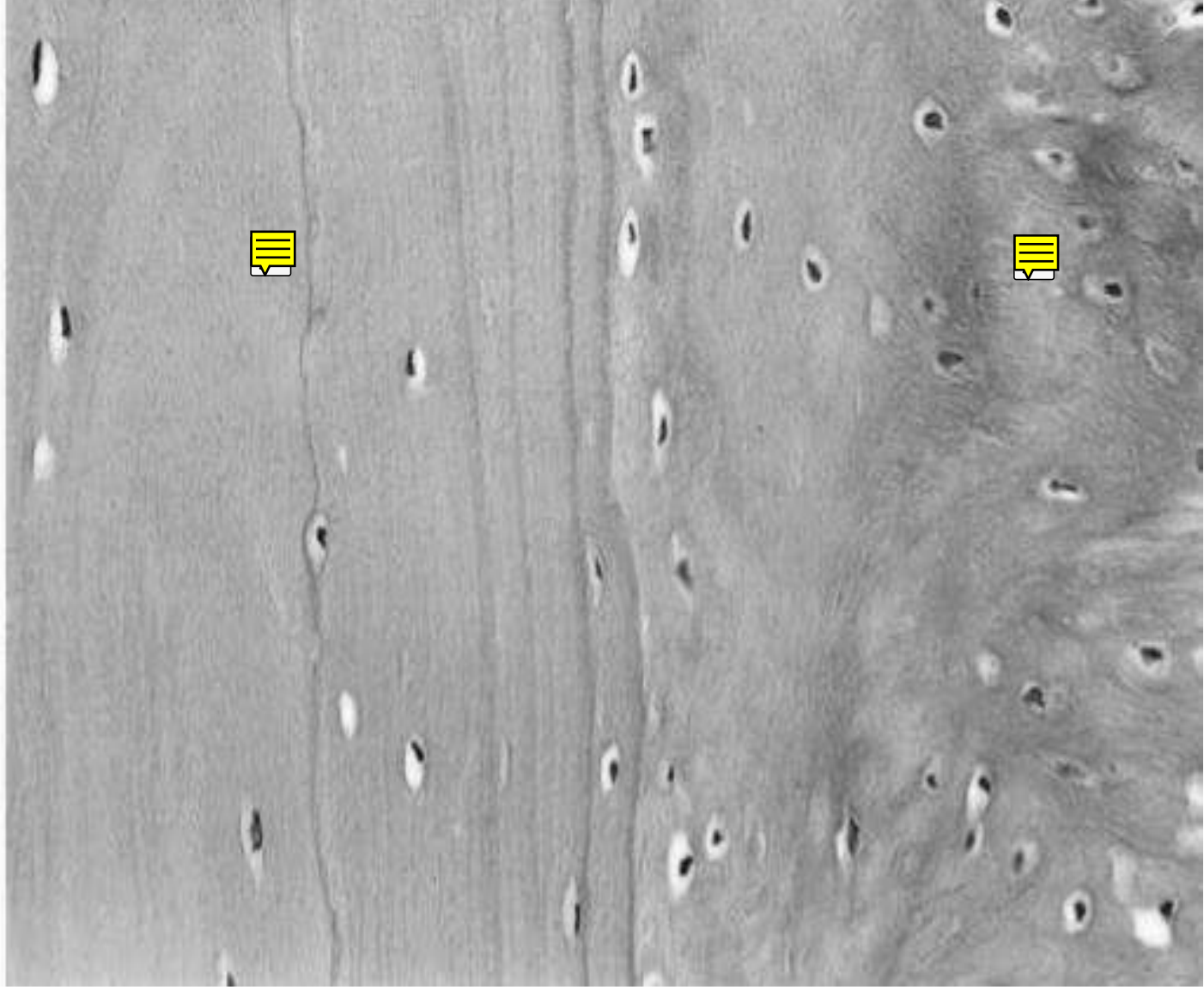


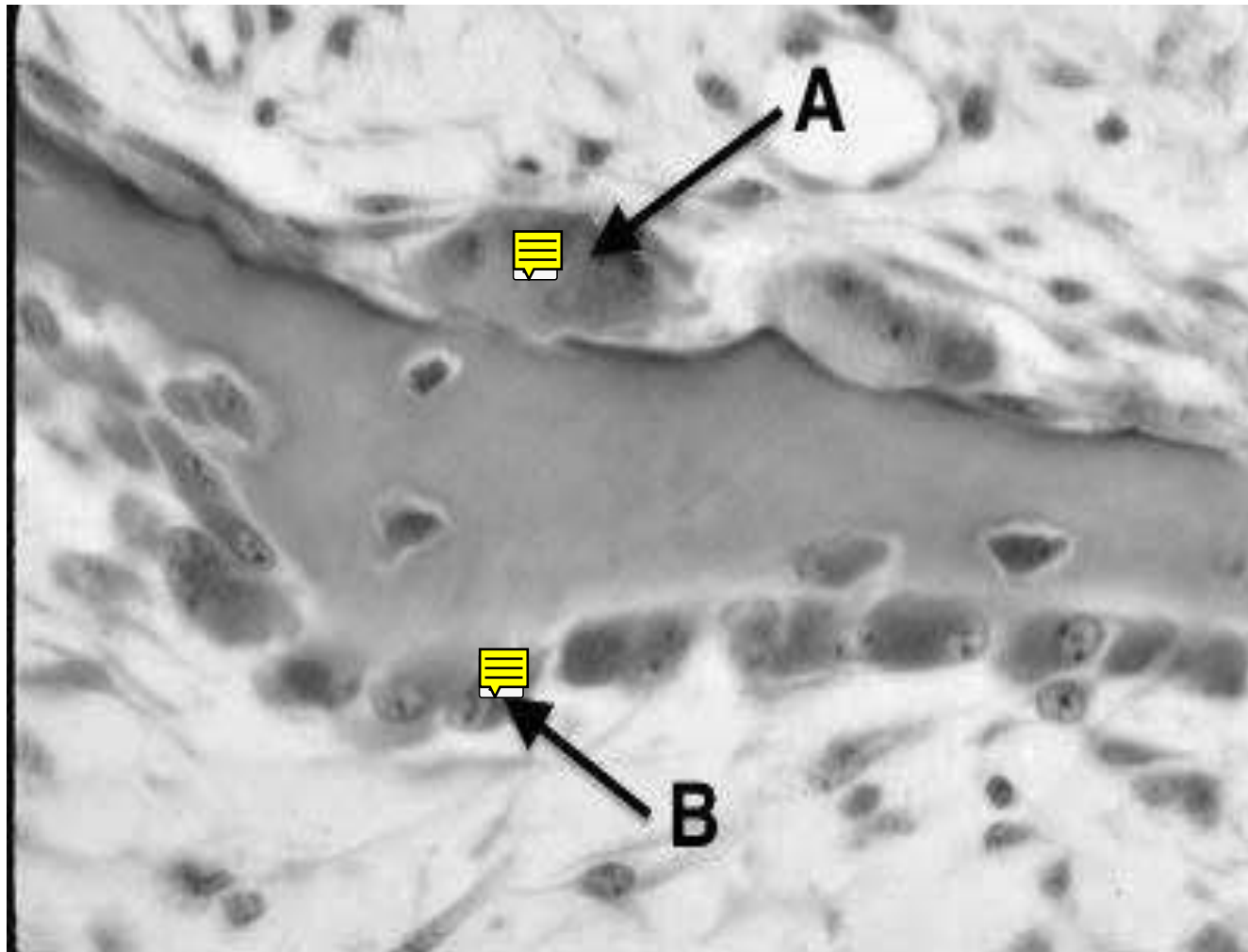










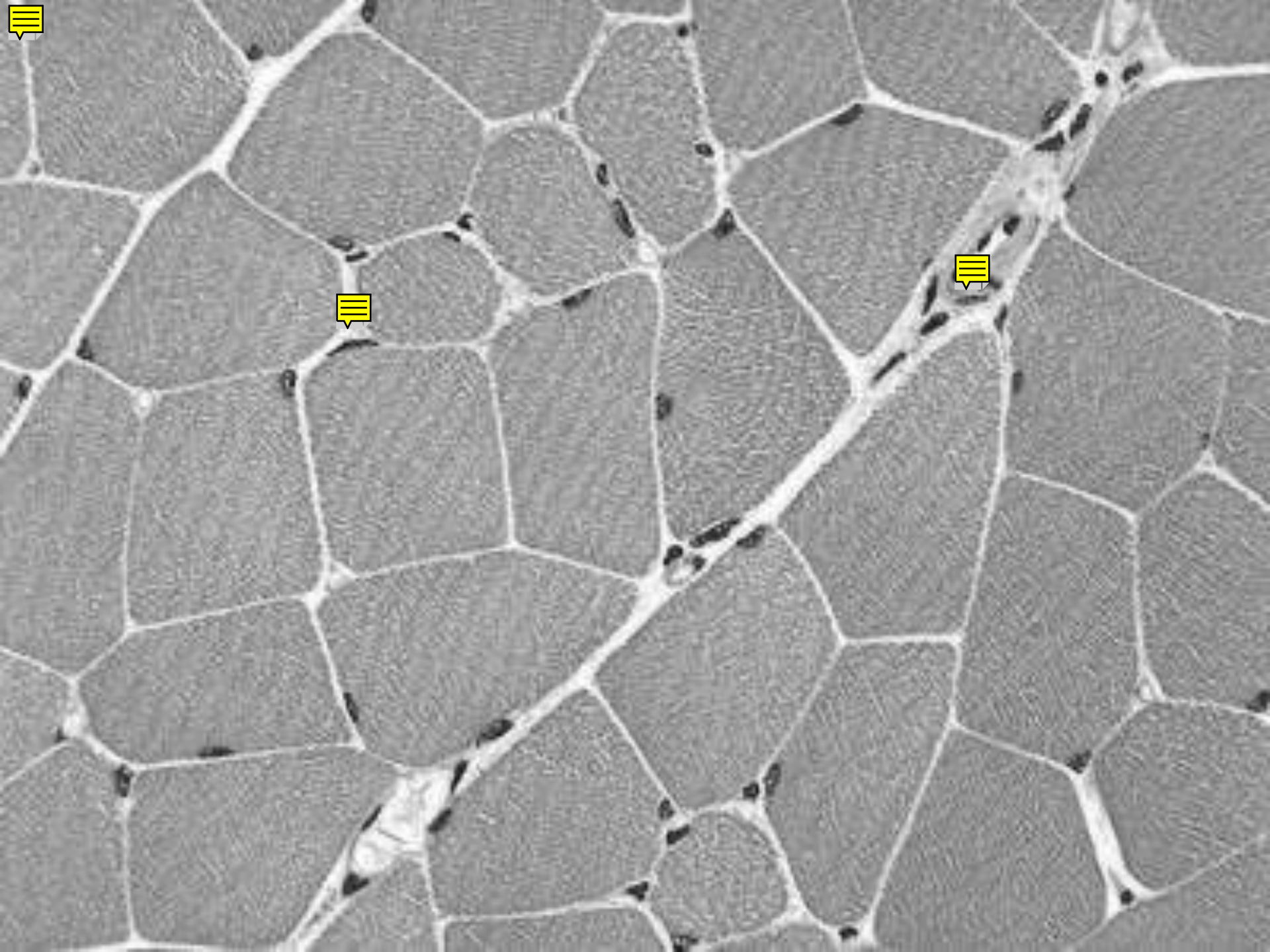


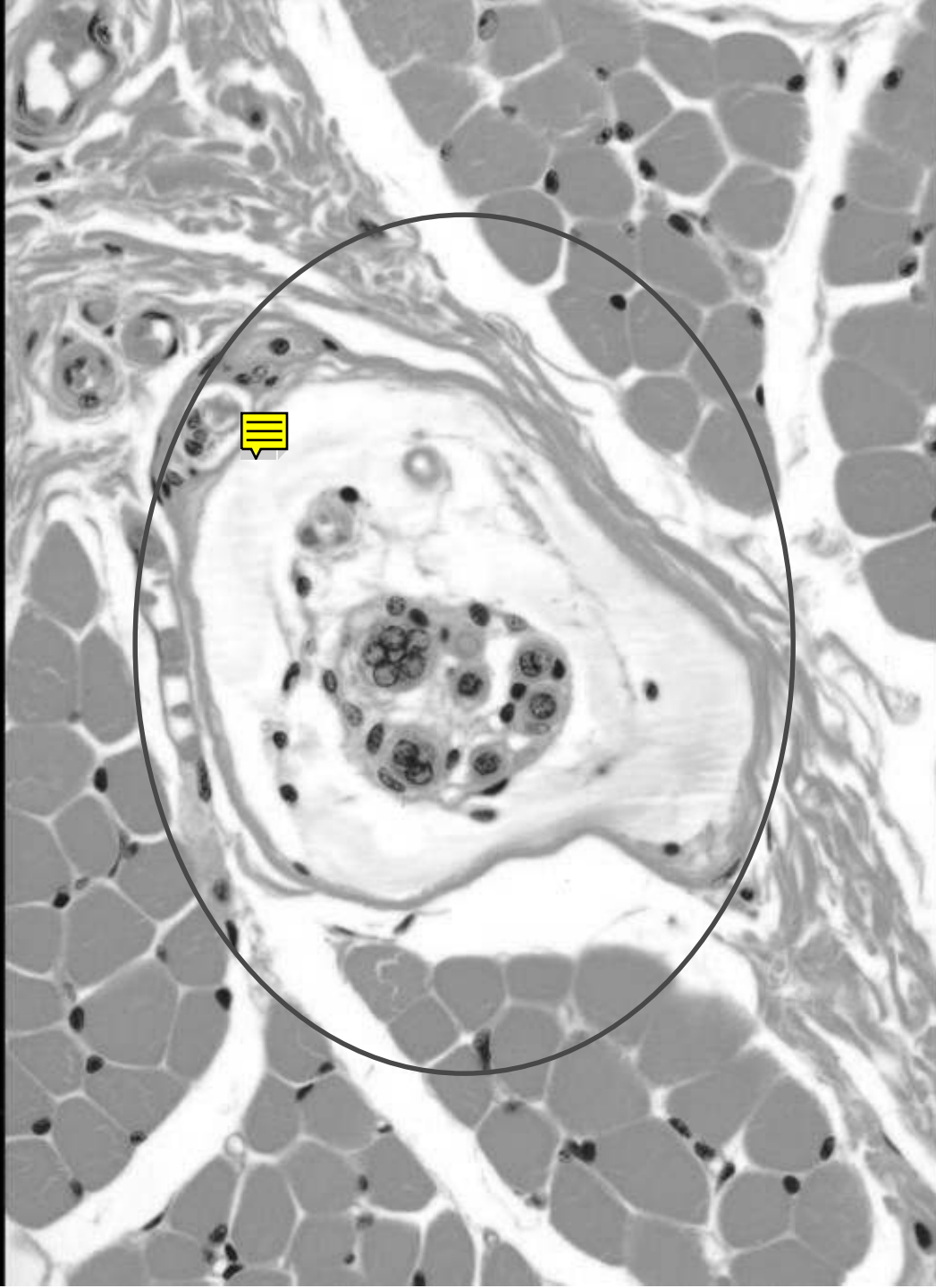


Muscle








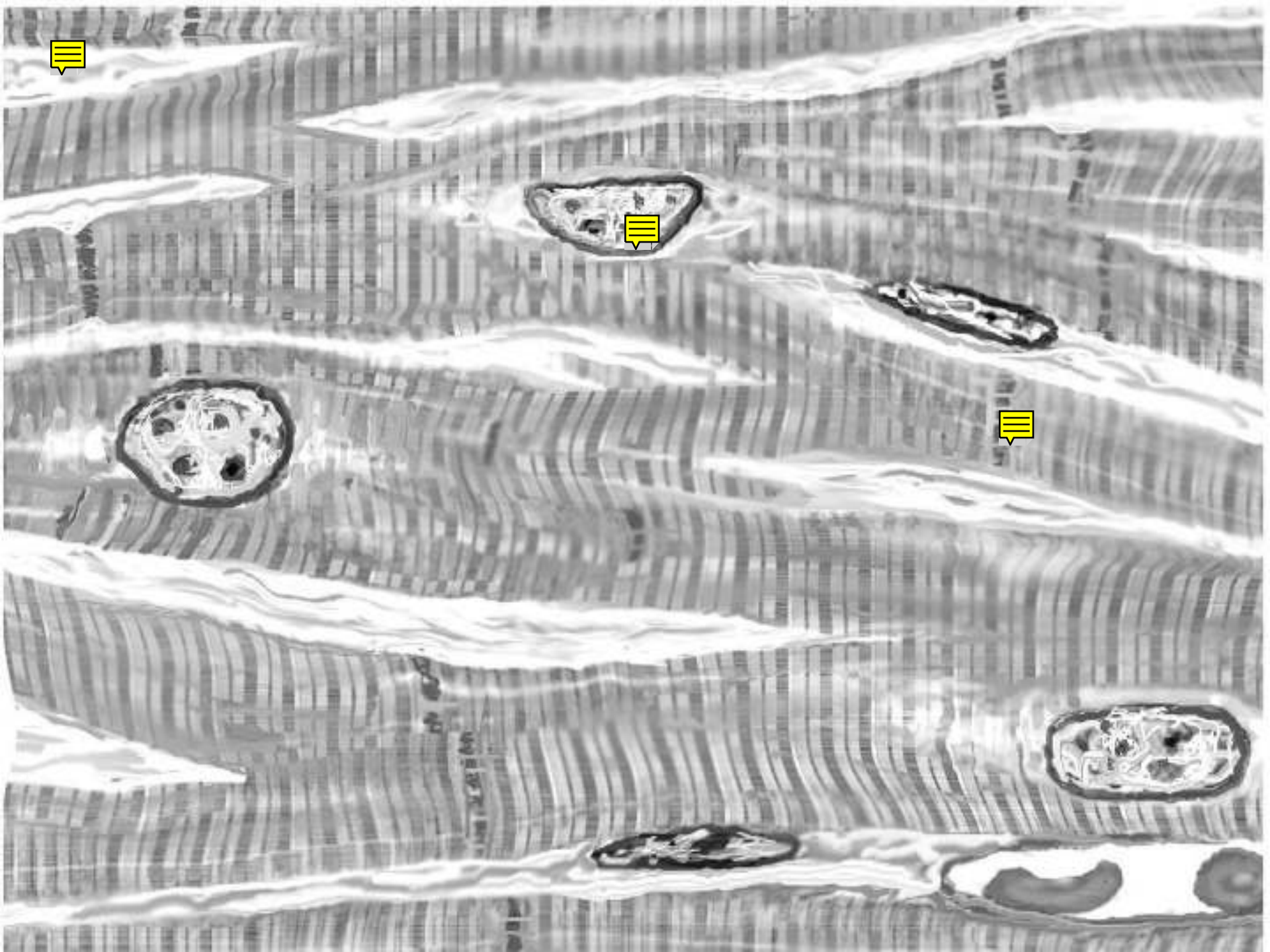


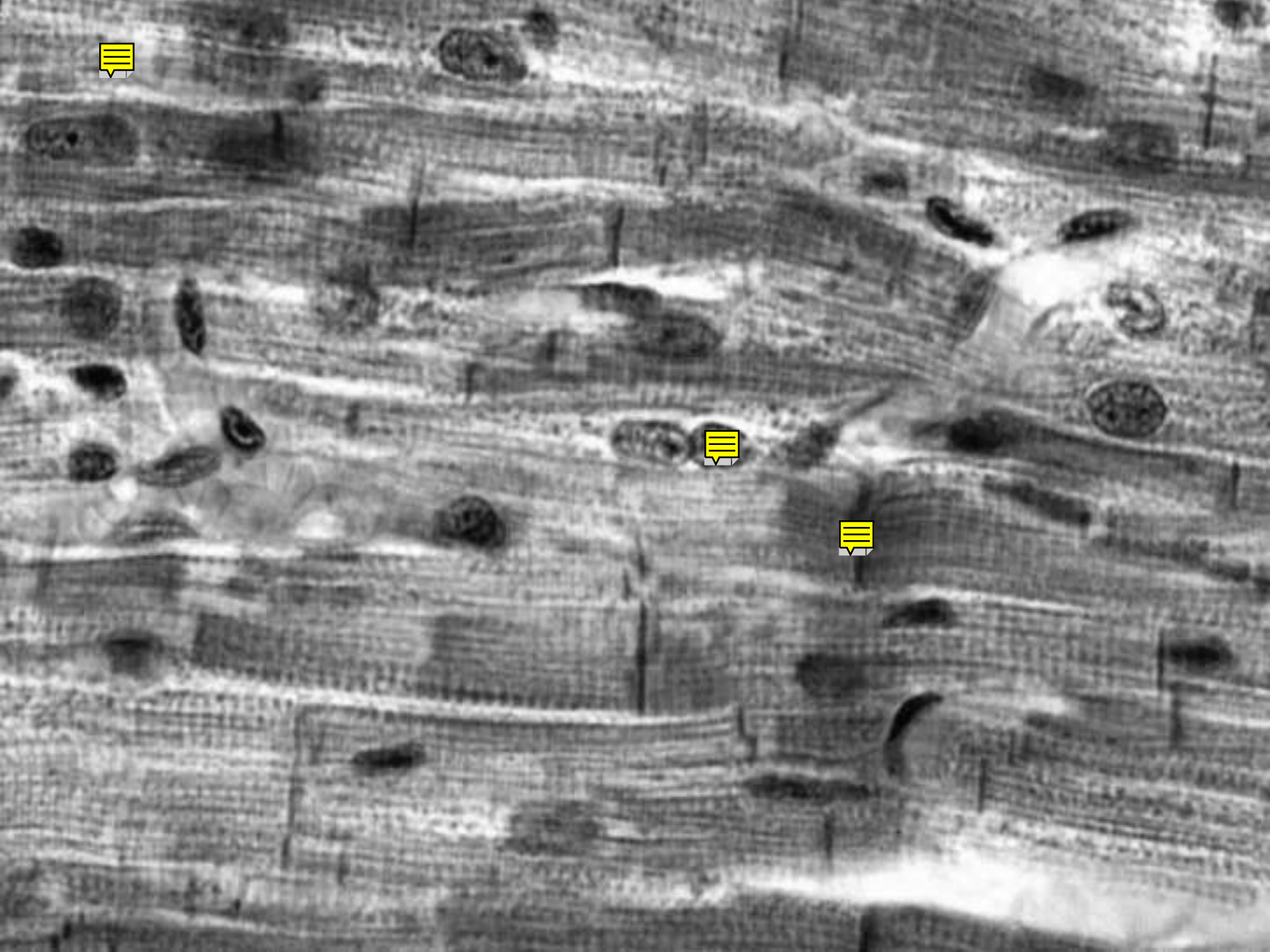




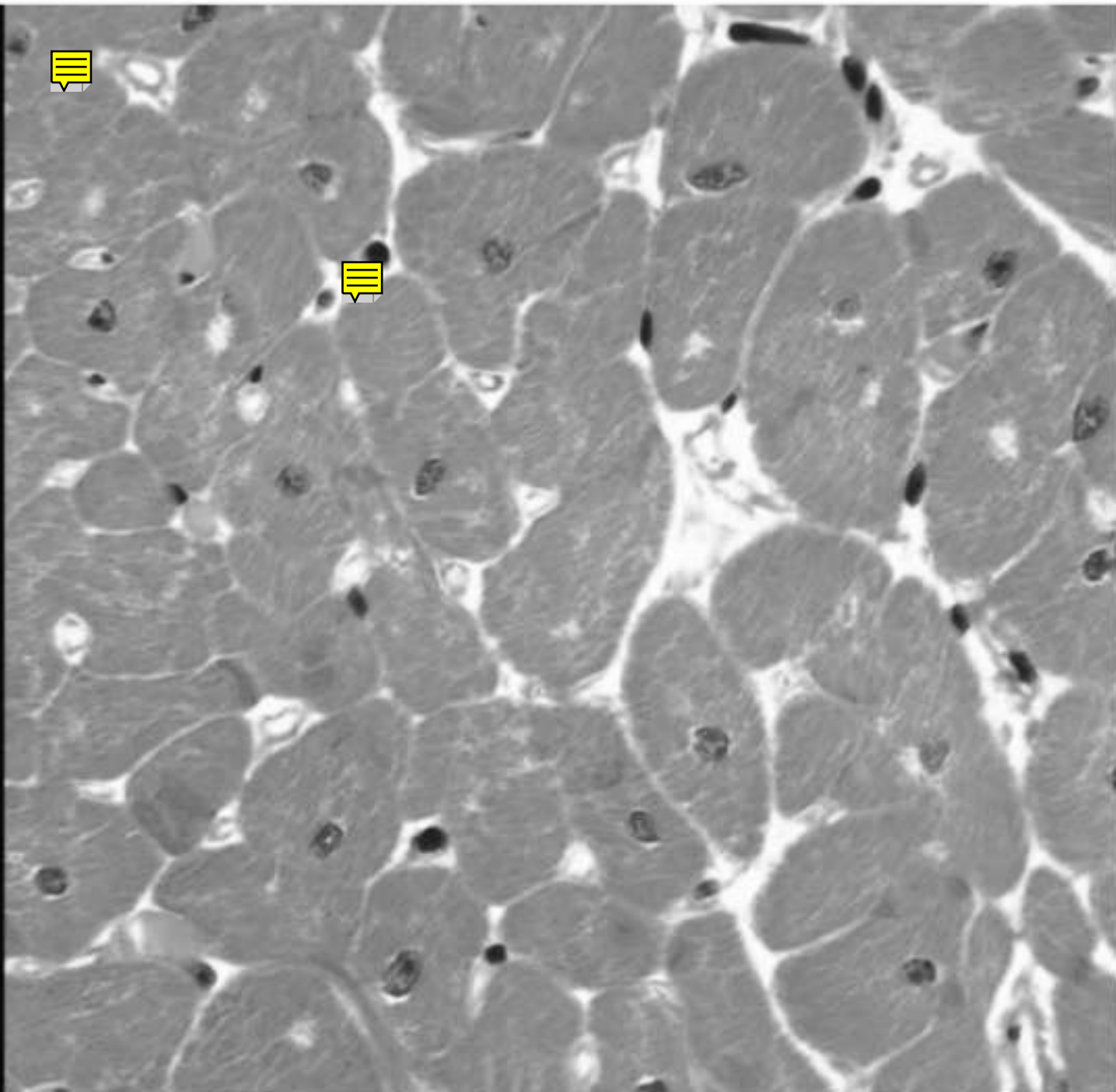



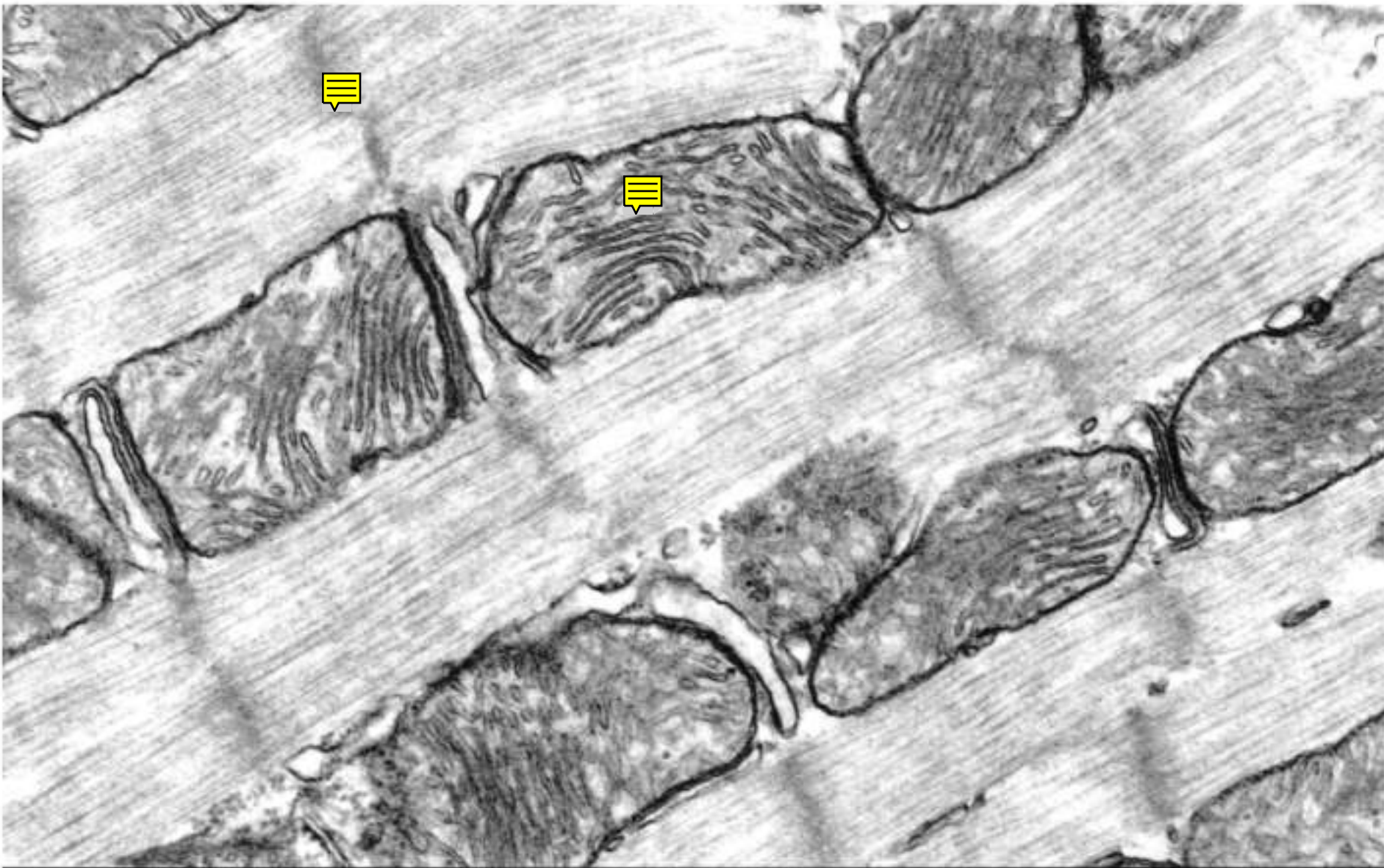




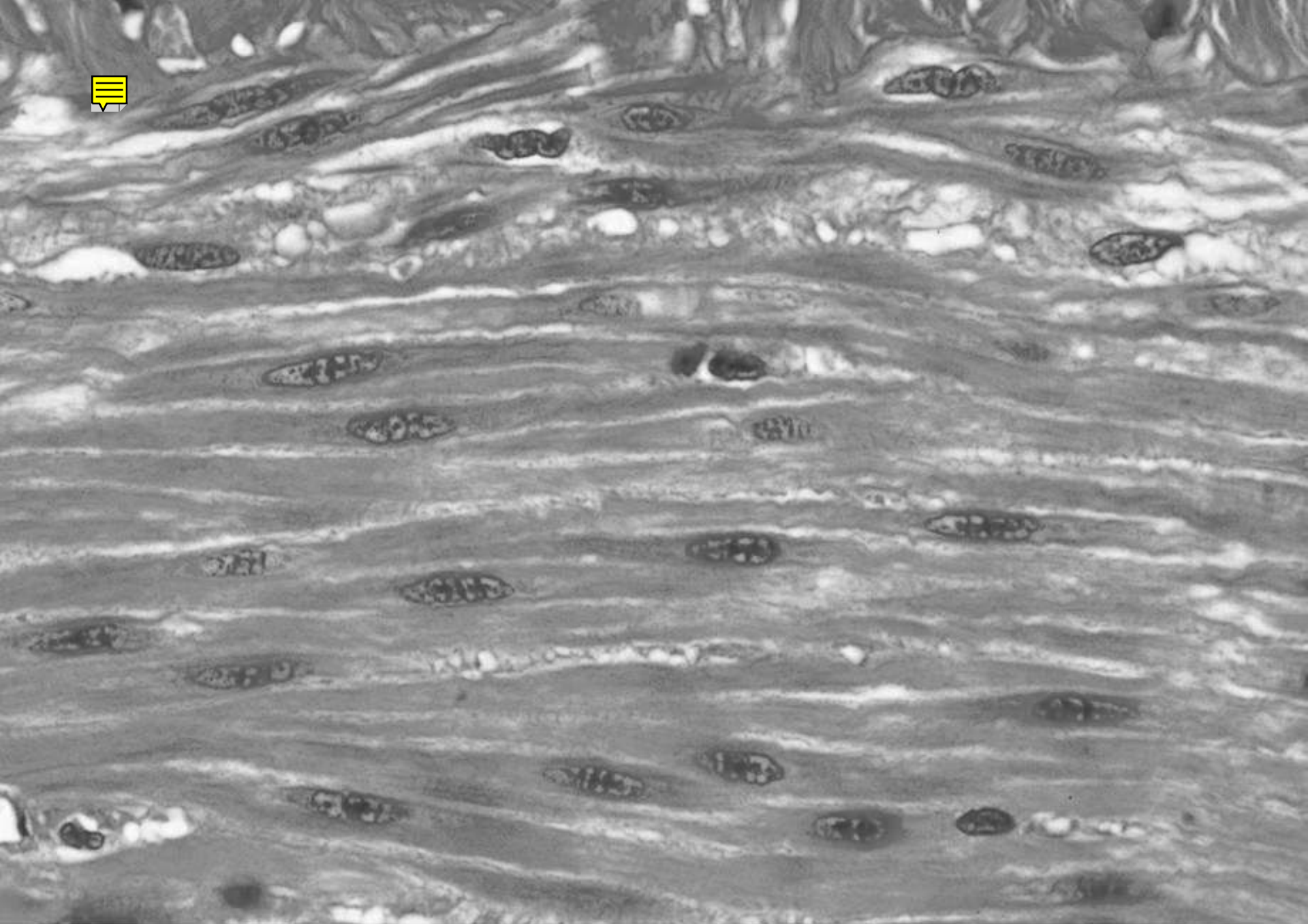







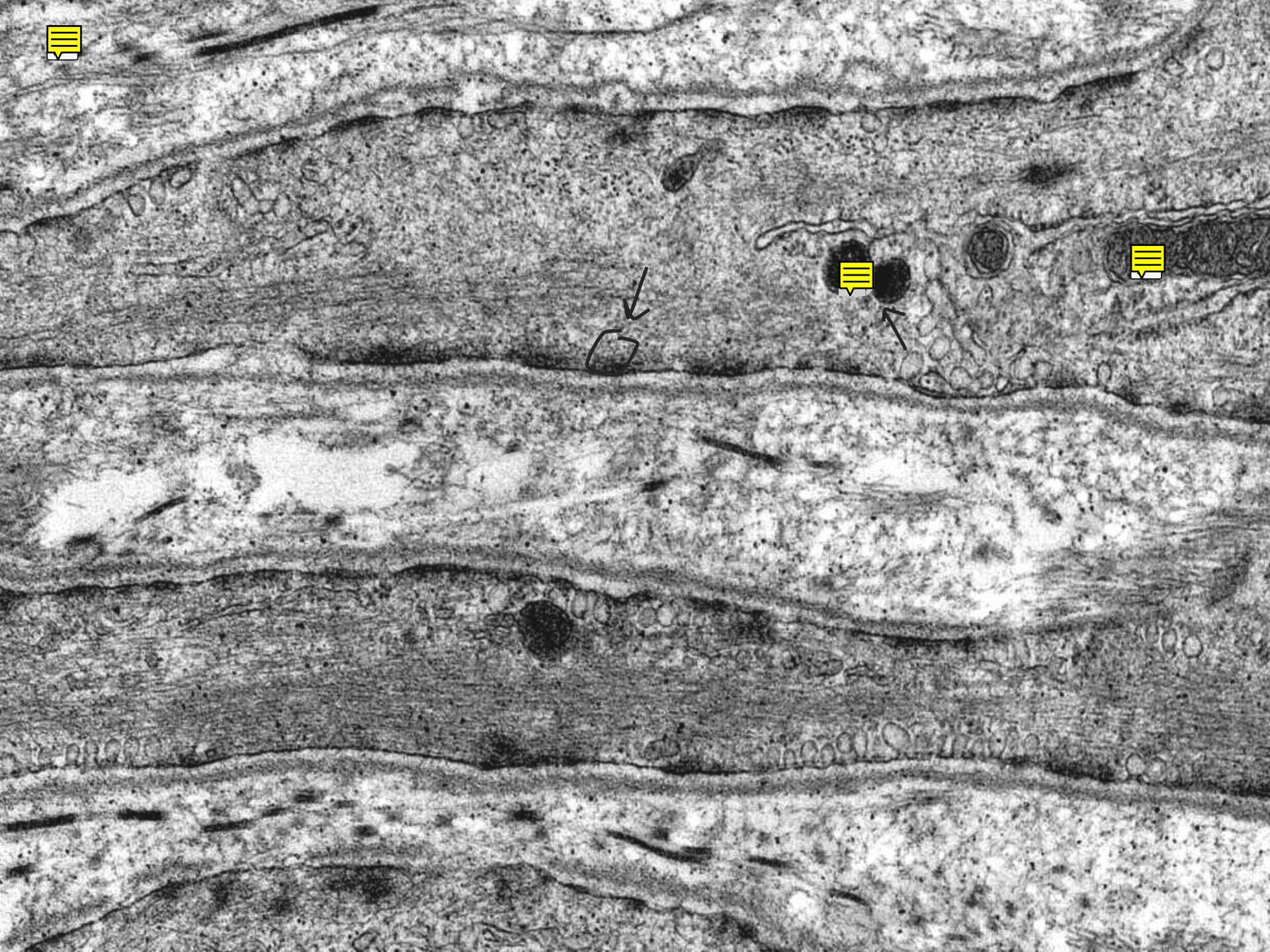












Skin



