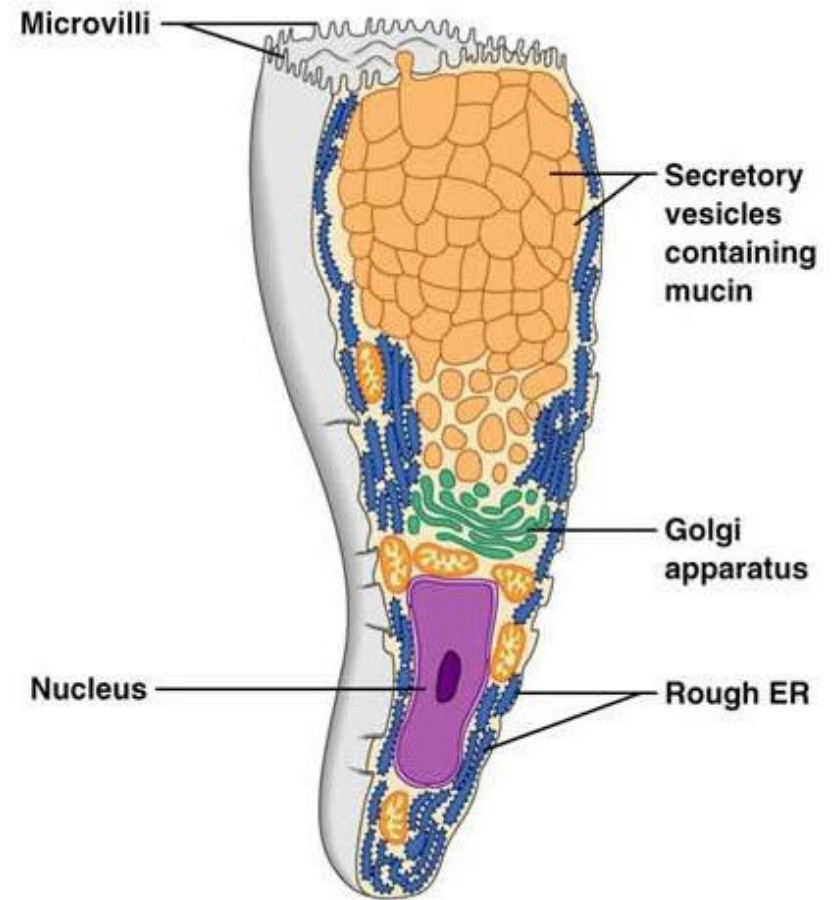


GLANDULAR EPITHELIUM



Glands

- **Definition:**

“Glandular epithelia are tissues formed by cells specialized to produce secretion.”

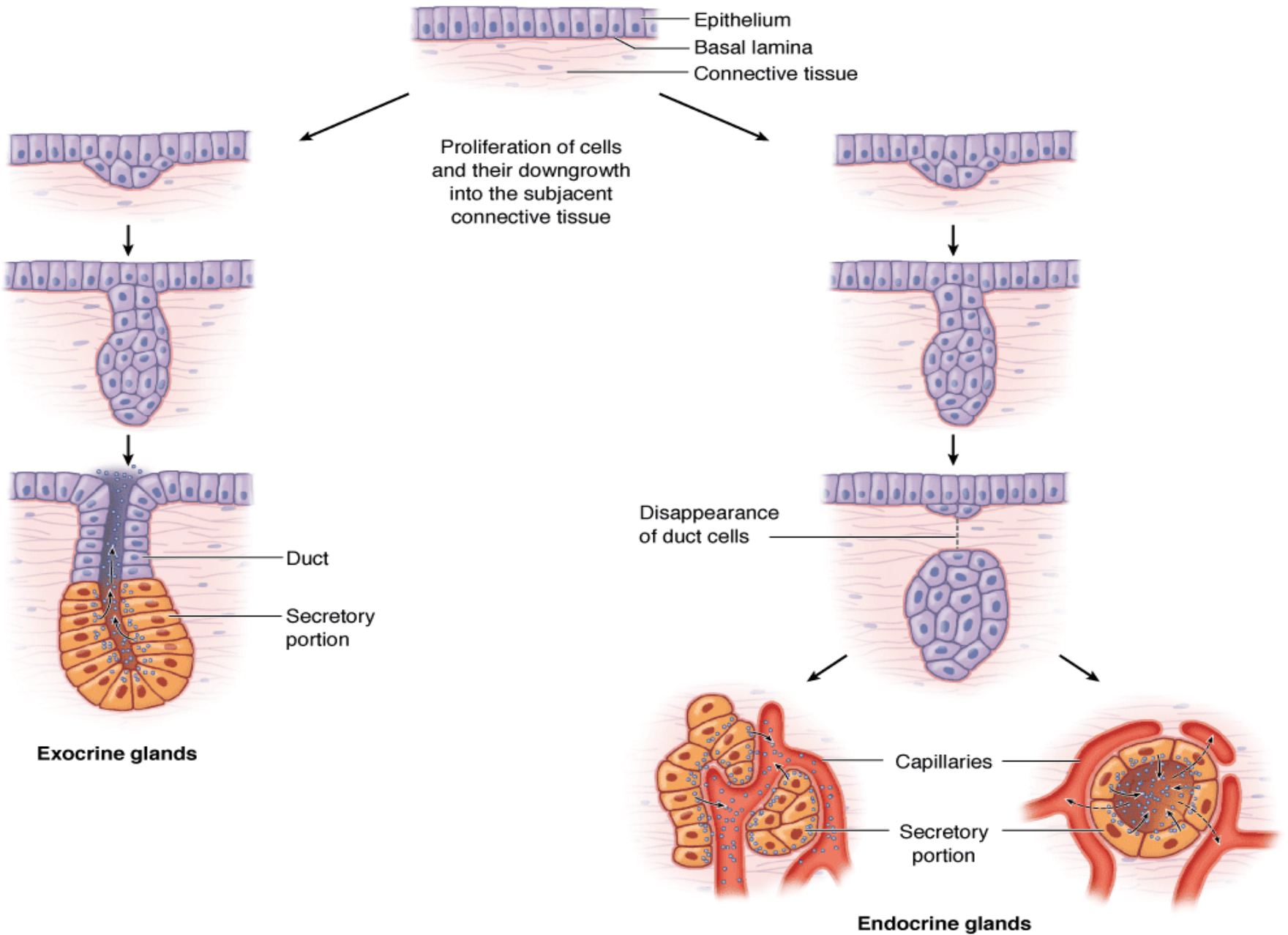
Glands

Glandular epithelial cells may synthesize, store, and secrete:

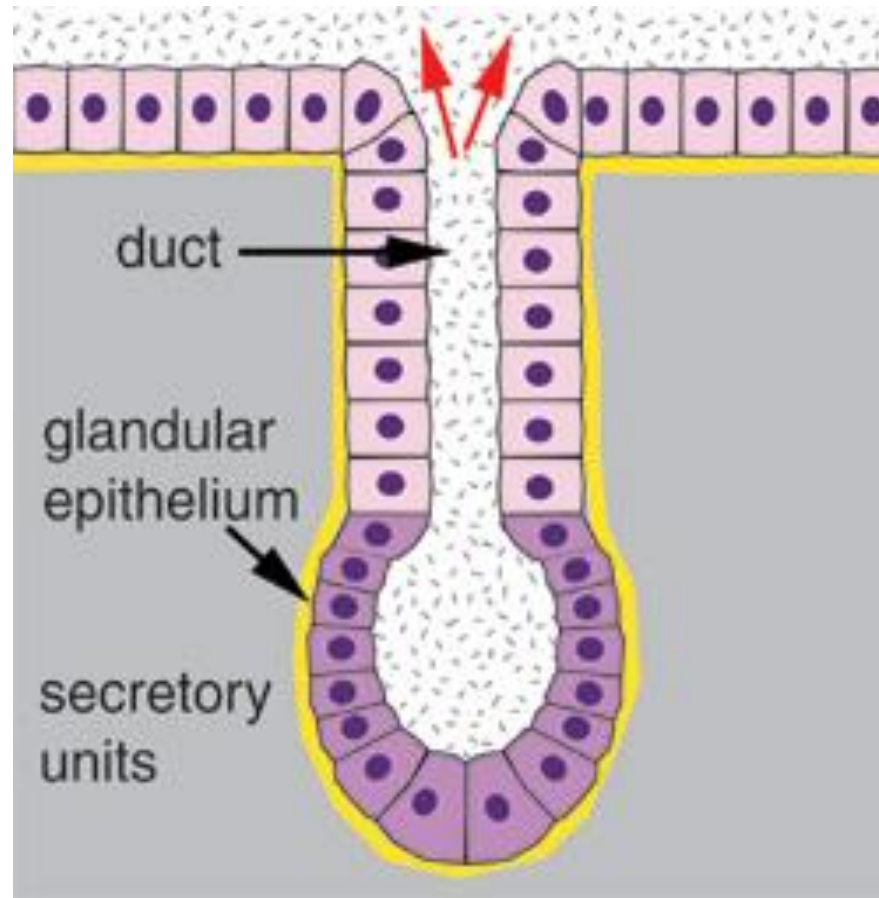
- **Proteins** (e.g; pancreas)
- **Lipids** (e.g; sebaceous glands)
- **Complexes of carbohydrates and proteins**
(e.g; salivary glands)
- The mammary glands secrete all 3 substances.

Development of glands

- Formation of glands from covering epithelia
- Epithelial cells proliferate and penetrate connective tissue followed by further differentiation.
- They may—or may not—maintain contact with the surface
- When contact is maintained, **exocrine glands** are formed
- Without contact, **endocrine glands** are formed



- **Exocrine glands** secrete substances to specific organ via duct systems.



Classification of glands:

- **Exocrine glands** (Gr. Exo, outside,+ krinein, to separate).

Release their products onto an epithelial surface, either directly or through a **duct** e.g; the **salivary glands**.

- **Endocrine glands** (Gr, endon, within,+ krinein)

Release their products (hormones) into the **blood stream**
e.g; **thyroid gland**.

- **Mixed variety:** some glands possess both **exocrine** and **endocrine** function e.g; **pancreas, liver cells**.

Exocrine glands

Major exocrine glands are:

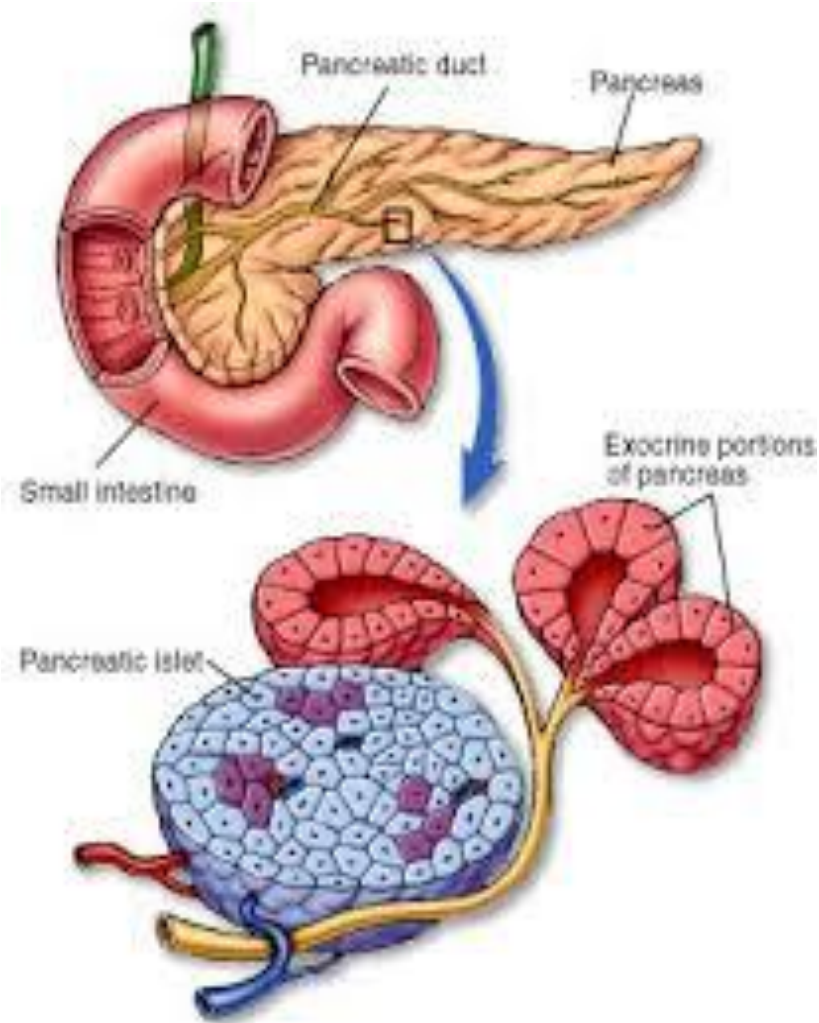
- Sweat glands
- Salivary glands
- Mammary glands
- Lacrimal glands

Endocrine glands

Major endocrine glands are:

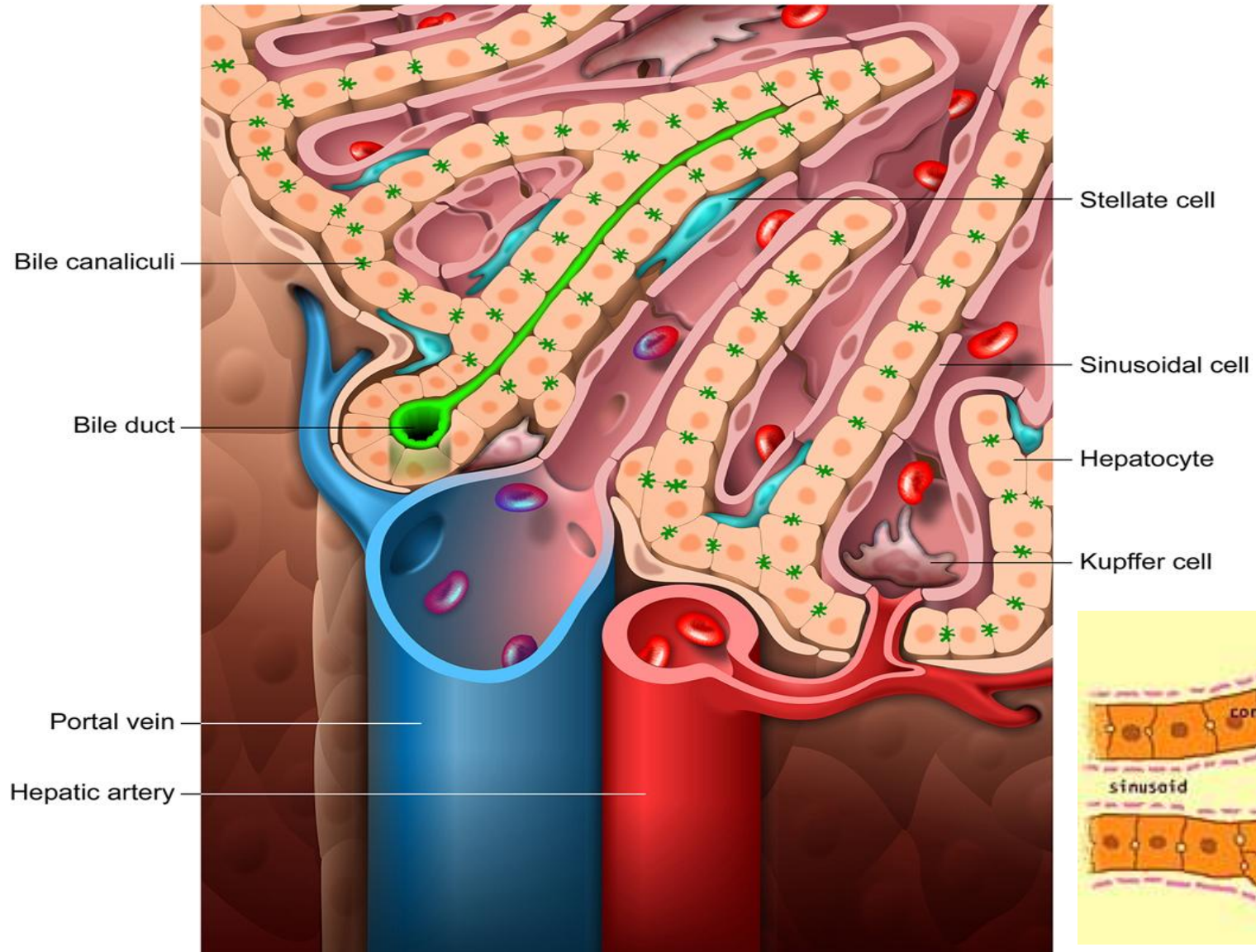
- Pituitary gland
- Thyroid gland
- Parathyroid glands
- Adrenal glands
- Ovaries
- Testes

Mixed gland: Pancreas



Contains both endocrine and exocrine parts.

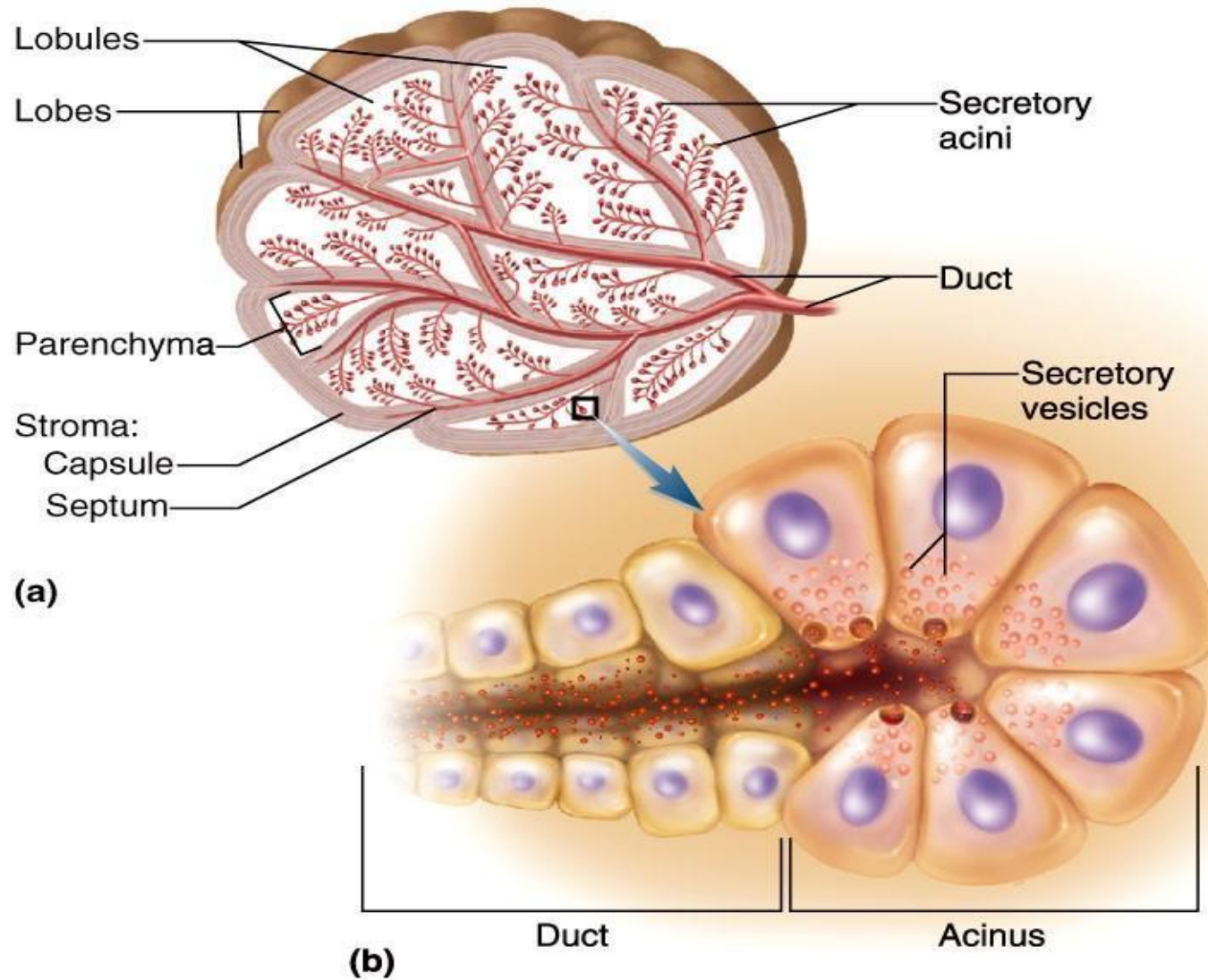
Mixed gland: Liver

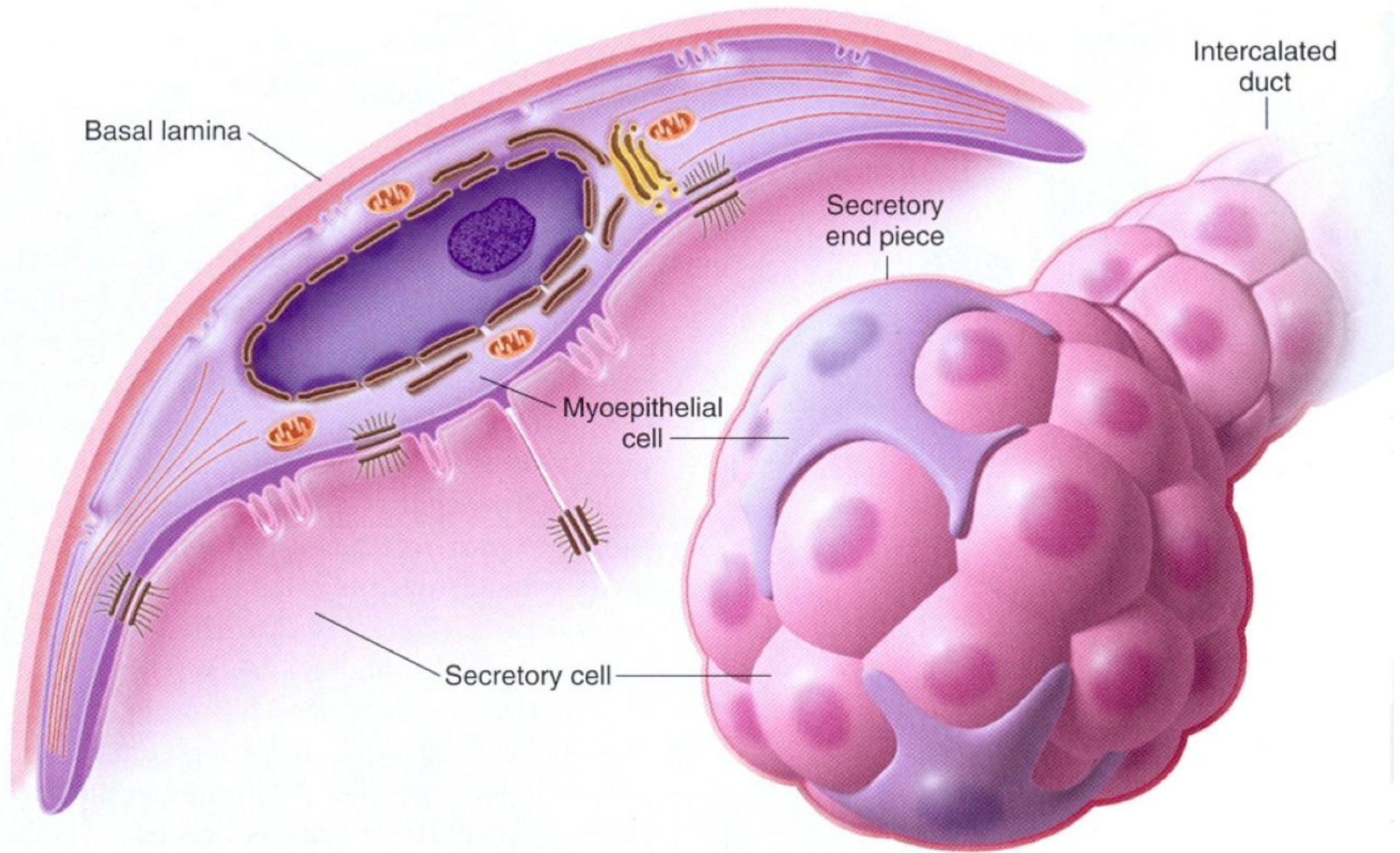


Contains both endocrine and exocrine parts.

General histological structure of exocrine glands

- **Externally** a gland is surrounded by a dense layer of connective tissue which forms **capsule** of the gland.
- From the capsule connective tissue septa extend into the gland, thereby dividing its substance into a number of lobes.
- Thinner septa subdivide each lobe into smaller lobules. Blood vessels and nerves pass along the connective tissue septa to reach the secretory elements.





Myoepithelial cells: Rich in actin and myosin, Help to propel secretory product into duct system

Glands might be classified according to the number of cells :

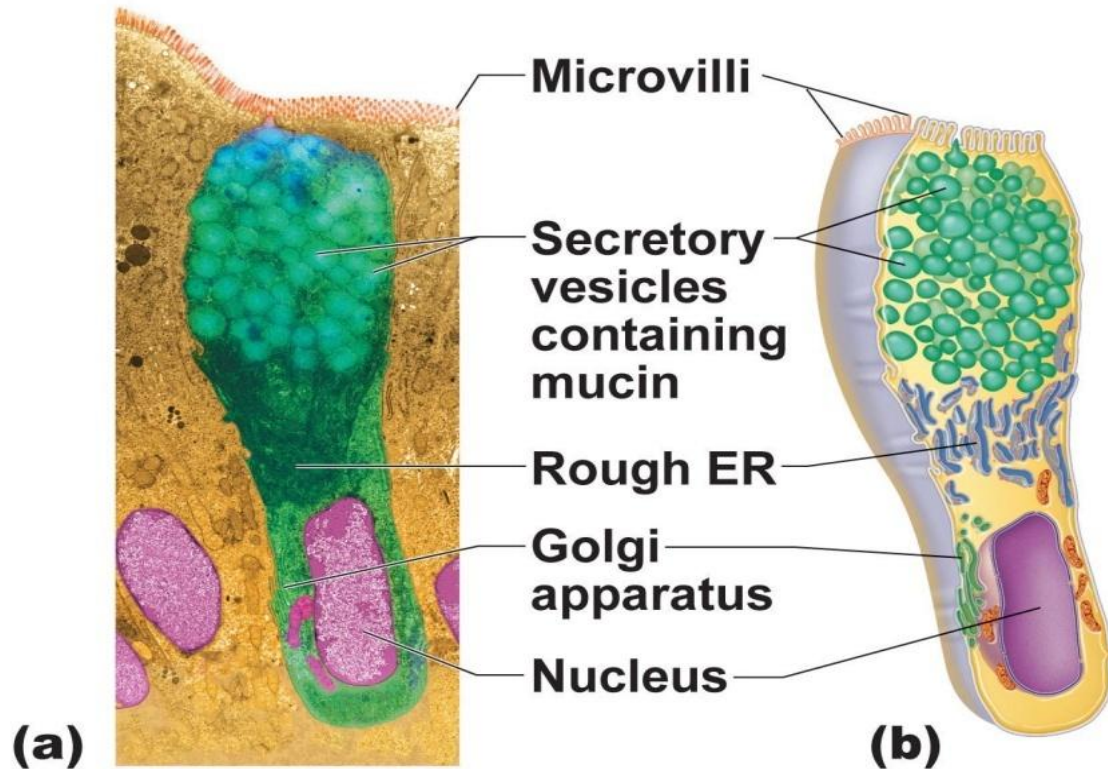
A. Unicellular glands

- **Goblet cells** which are present in the lining epithelia of intestine and the respiratory tract.

B. Multicellular glands

- **Salivary glands, lacrimal glands, sweat glands, ...**

Unicellular gland



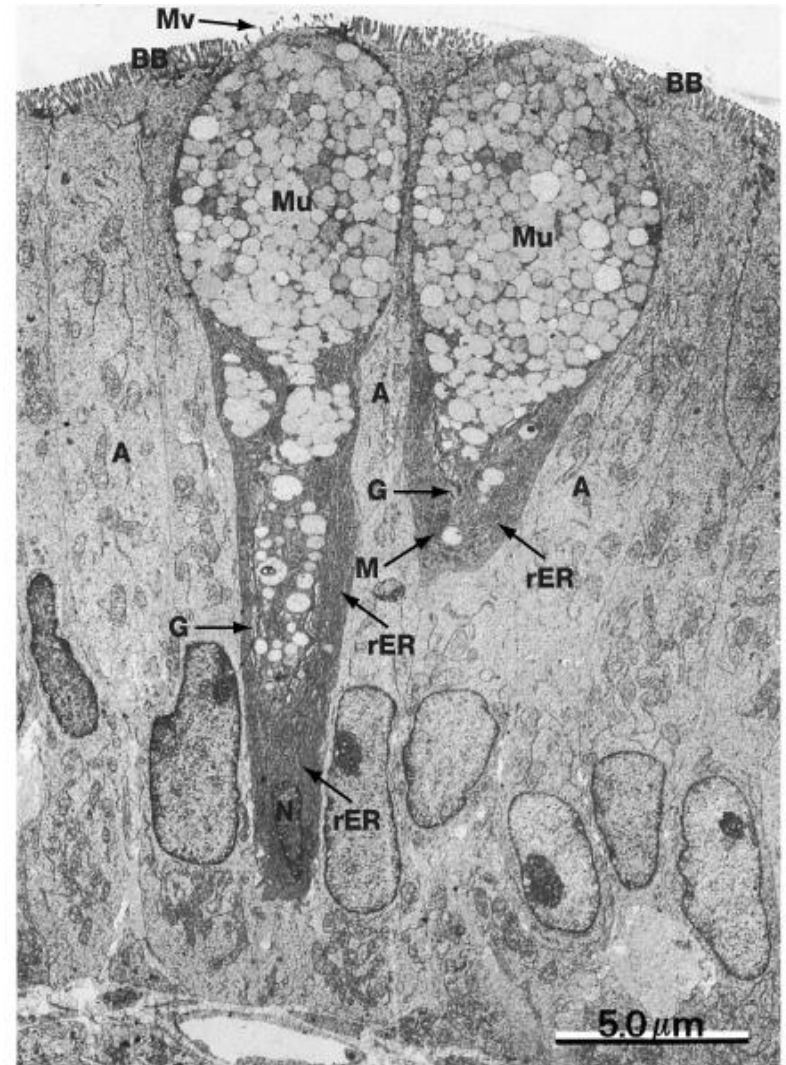
Copyright © 2010 Pearson Education, Inc.

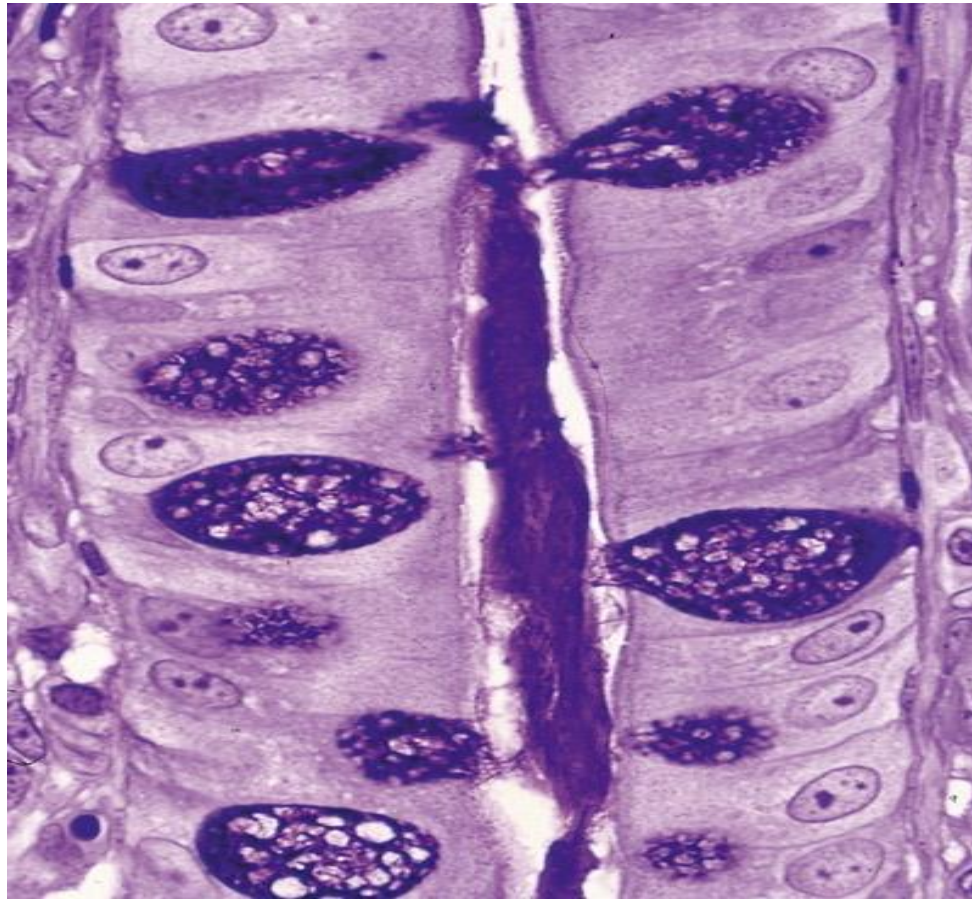
Mucus cells or goblet cells

Goblet cell

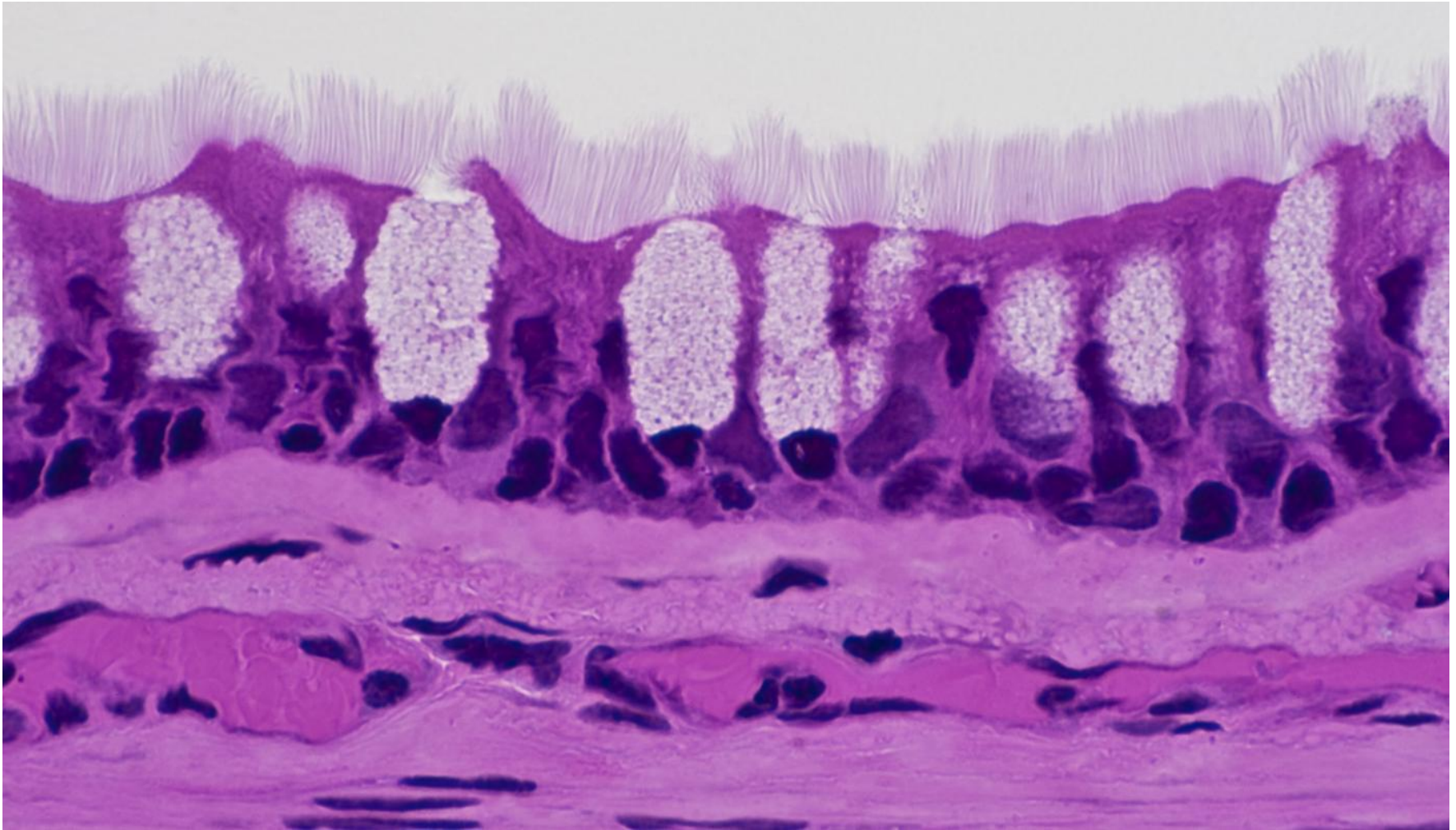
The goblet cell is **highly polarized** with the nucleus and other organelles concentrated at the base of the cell.

The remainder of the cell's cytoplasm is occupied by membrane-bound secretory granules containing **mucin**.





- **Goblet cells produce Mucin**
- Mucin + water → mucus
- **Protects and lubricates** many internal body surfaces.



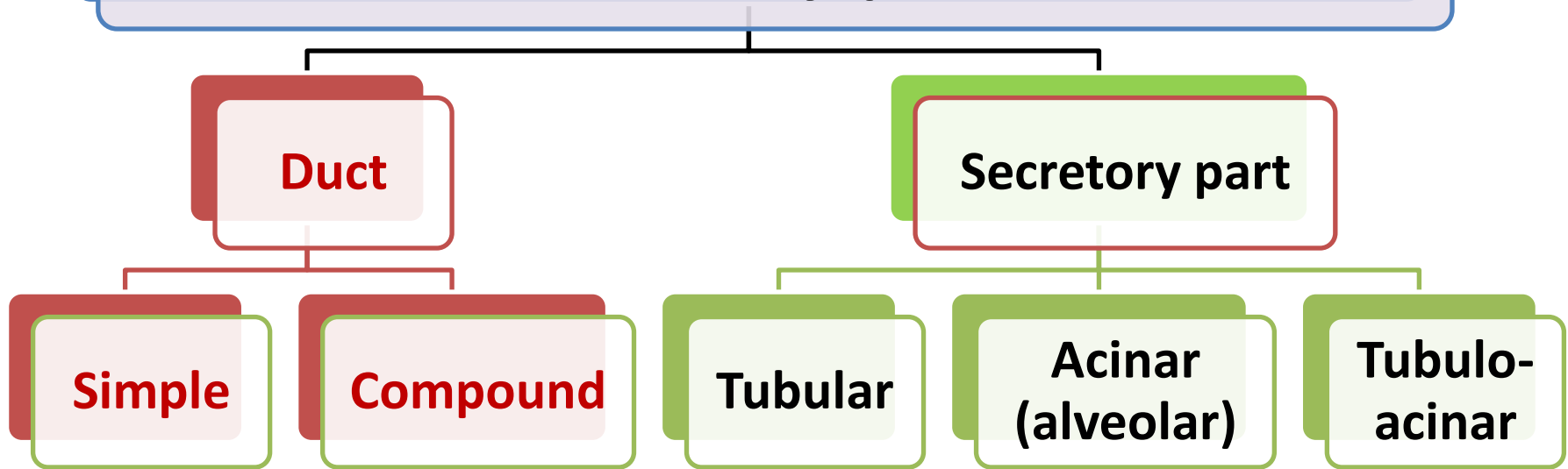
Goblet cells in the respiratory tract

Exocrine glands

These can also be classified on the basis of:

- Morphology of ducts and secreting portions.
- Nature of secretory product.
- Mode of secretion.

Classified according to the duct system and the secretory part



Morphology of ducts and secreting portions

■ Classified by structure of duct:

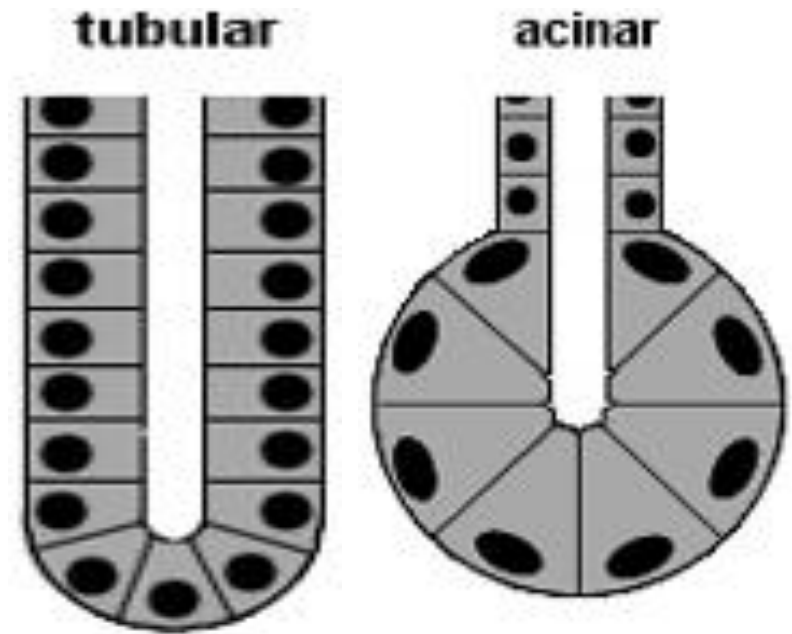
- Simple : “if a gland consists of a single secretory passage”.
- Compound: “ if a gland containing a branched duct system”.

■ Categorized by secretory unit:

- Tubular
- Acinar
- Tubulo- acinar

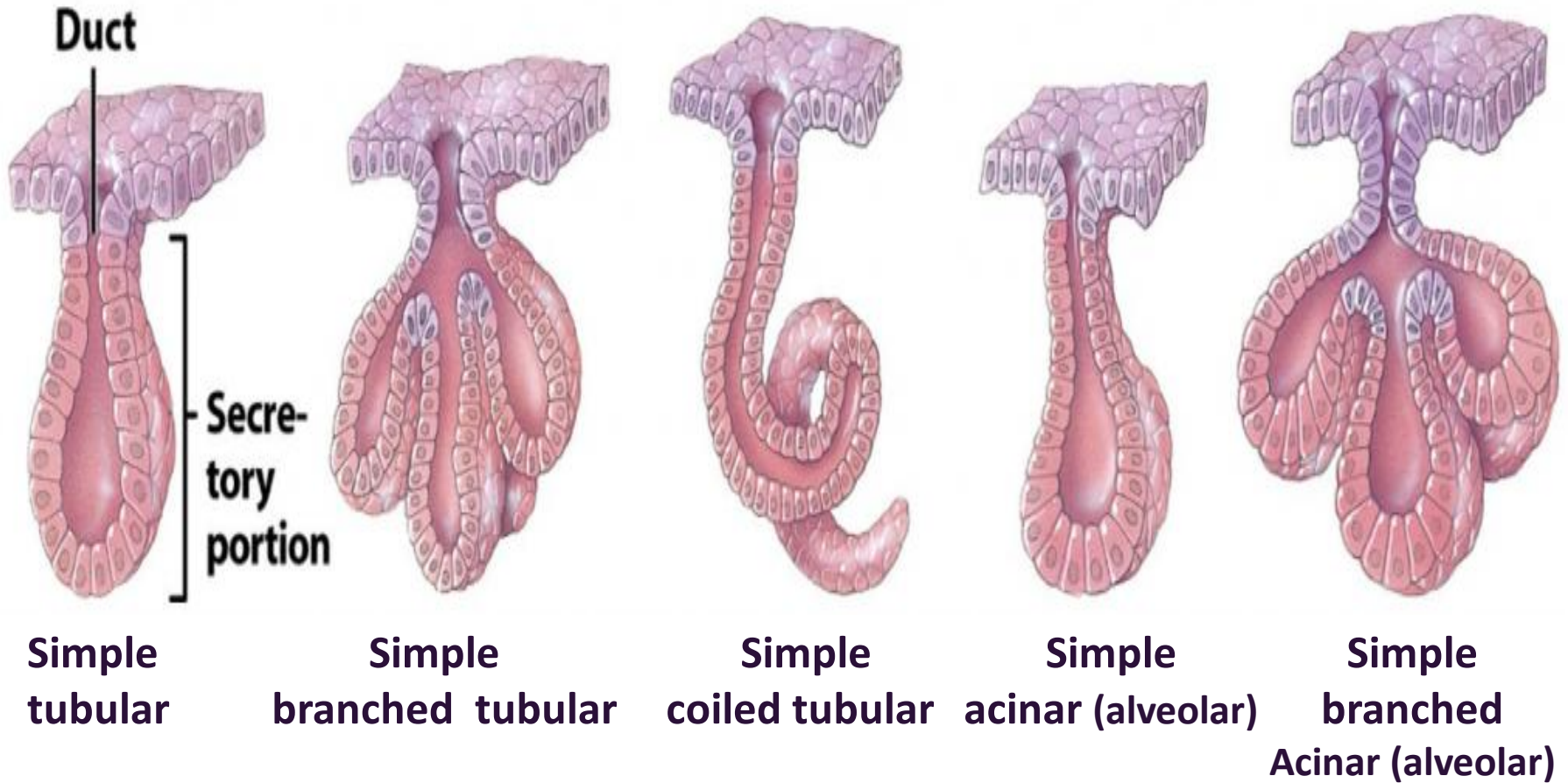
According to the shape of the secreting portion:

- **Tubular gland:**
 - Glands whose glandular cells form tubes, the tubes may be straight or coiled.
- **Acinar or alveolar gland:**
 - Glands whose glandular cells form sac-like pockets (called alveolus or acinus).



- **Tubulo- acinar glands:**
- In some glands when the secreting portions are neither typically tubular nor acinar, but combine certain features of both.
- A gland is **branched** if several secretory areas (tubular or acinar) share a duct.
- Note that “branched” refer to the glandular areas and not to the duct.


Simple exocrine glands



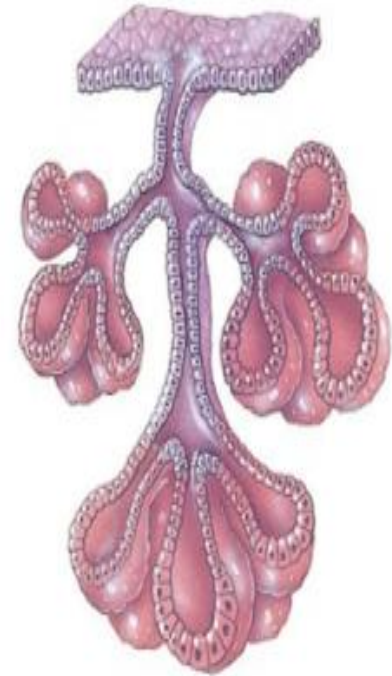
Compound exocrine glands



**Compound
tubular**



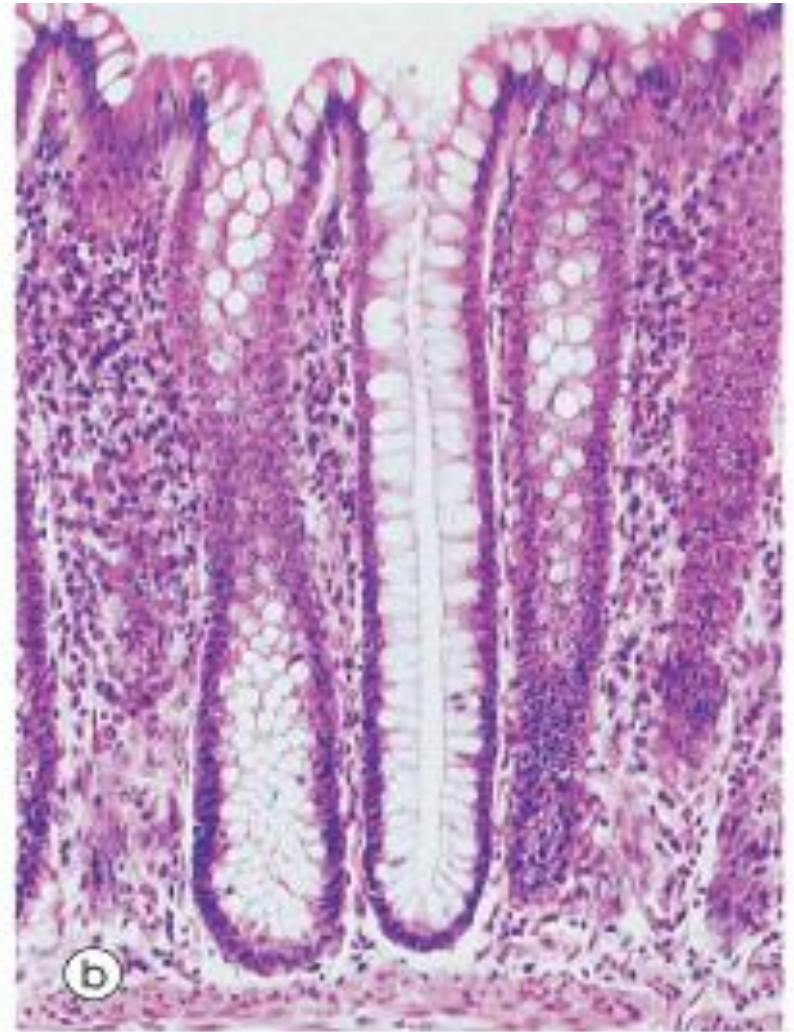
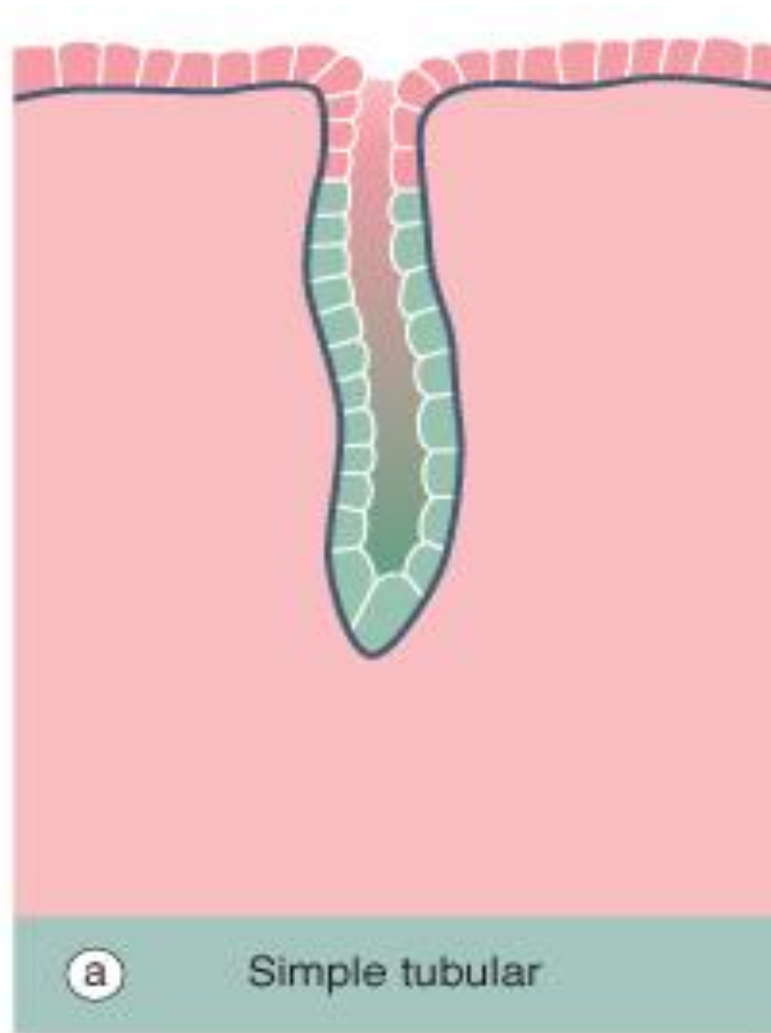
**Compound
acinar (alveolar)**



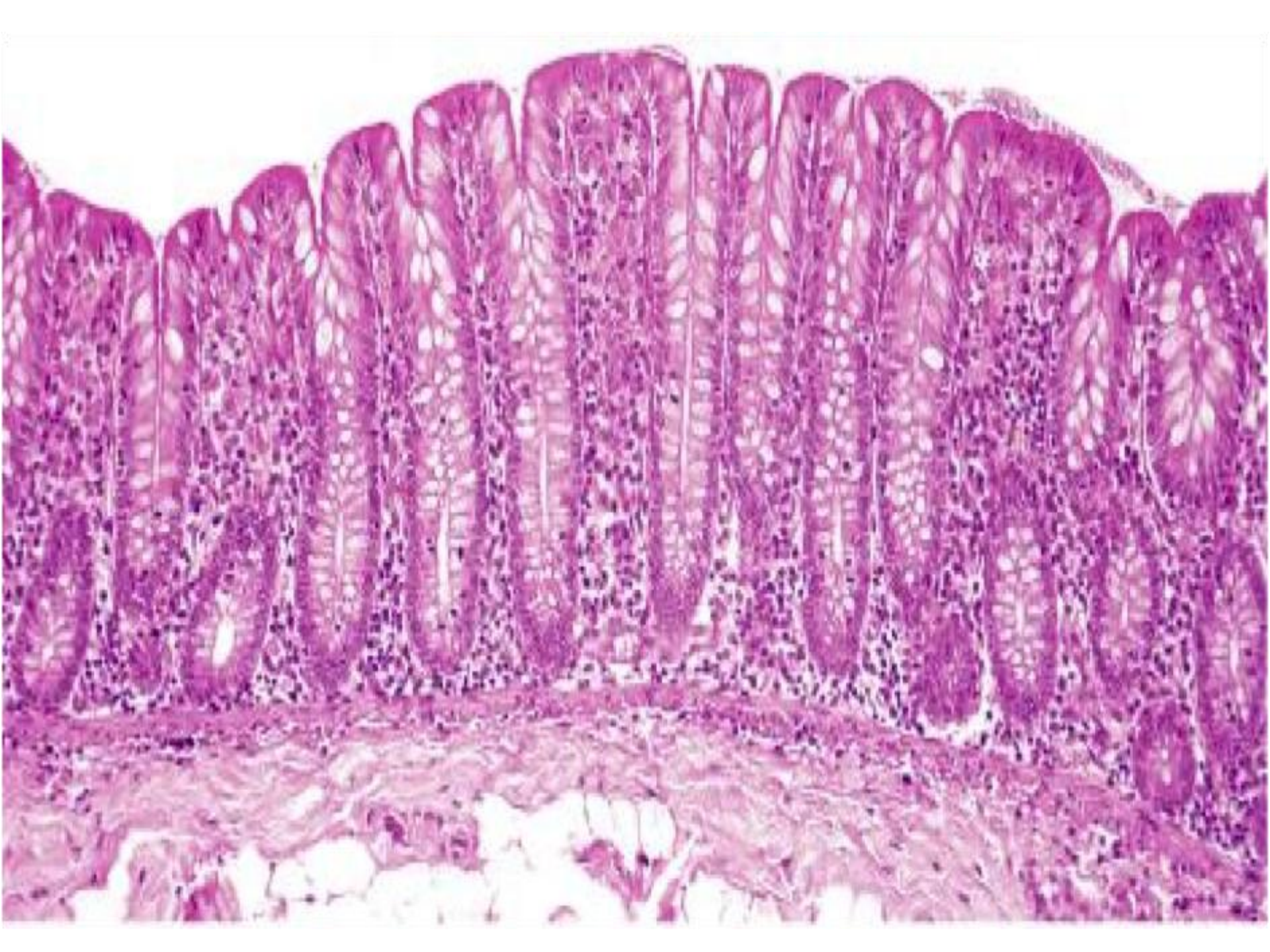**Compound
tubulo-acinar**

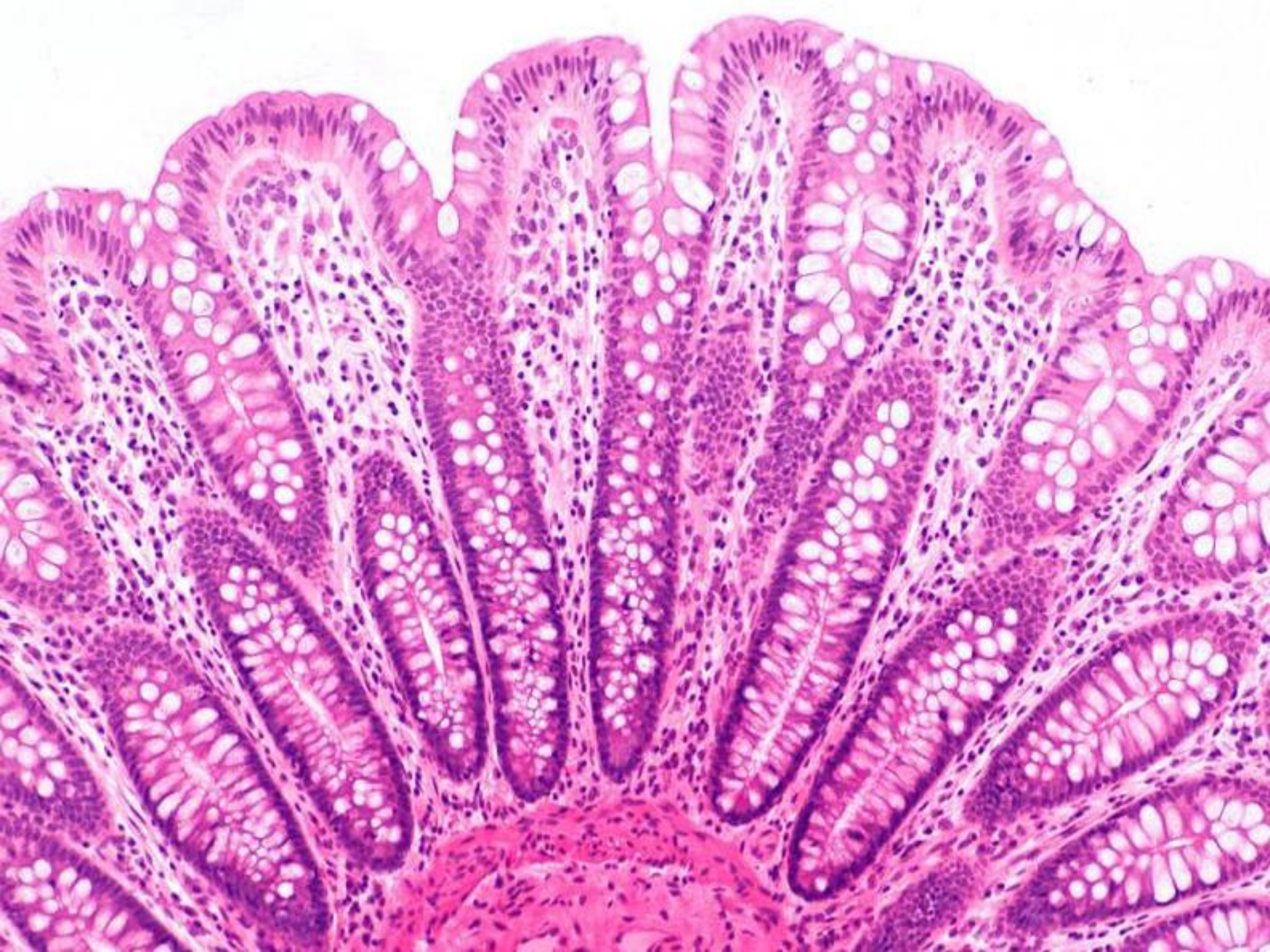Simple exocrine glands

Simple tubular

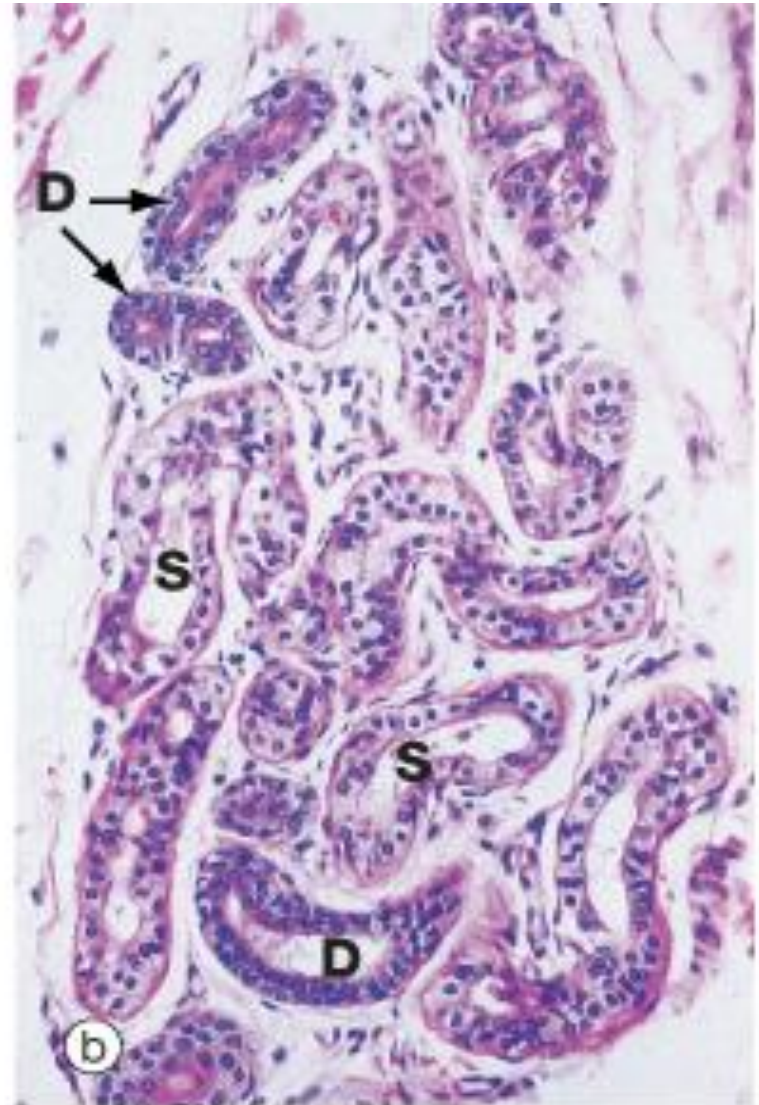


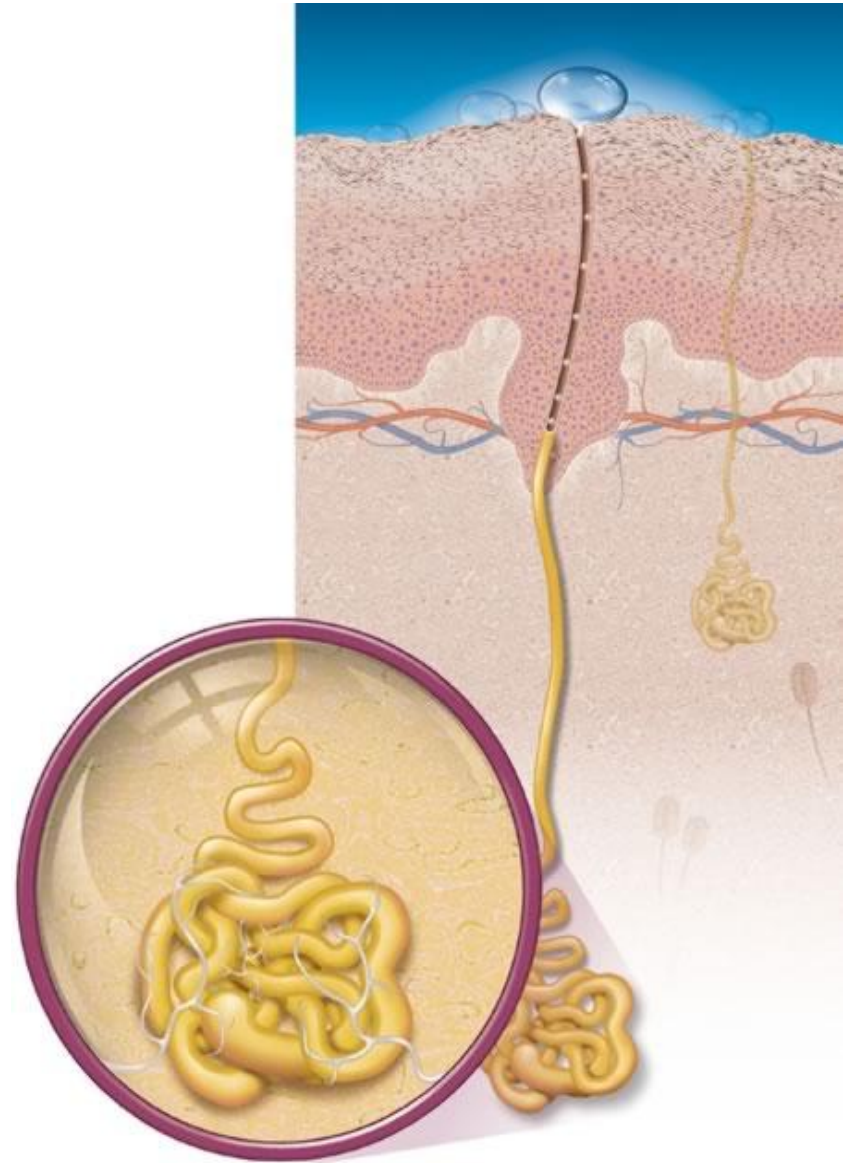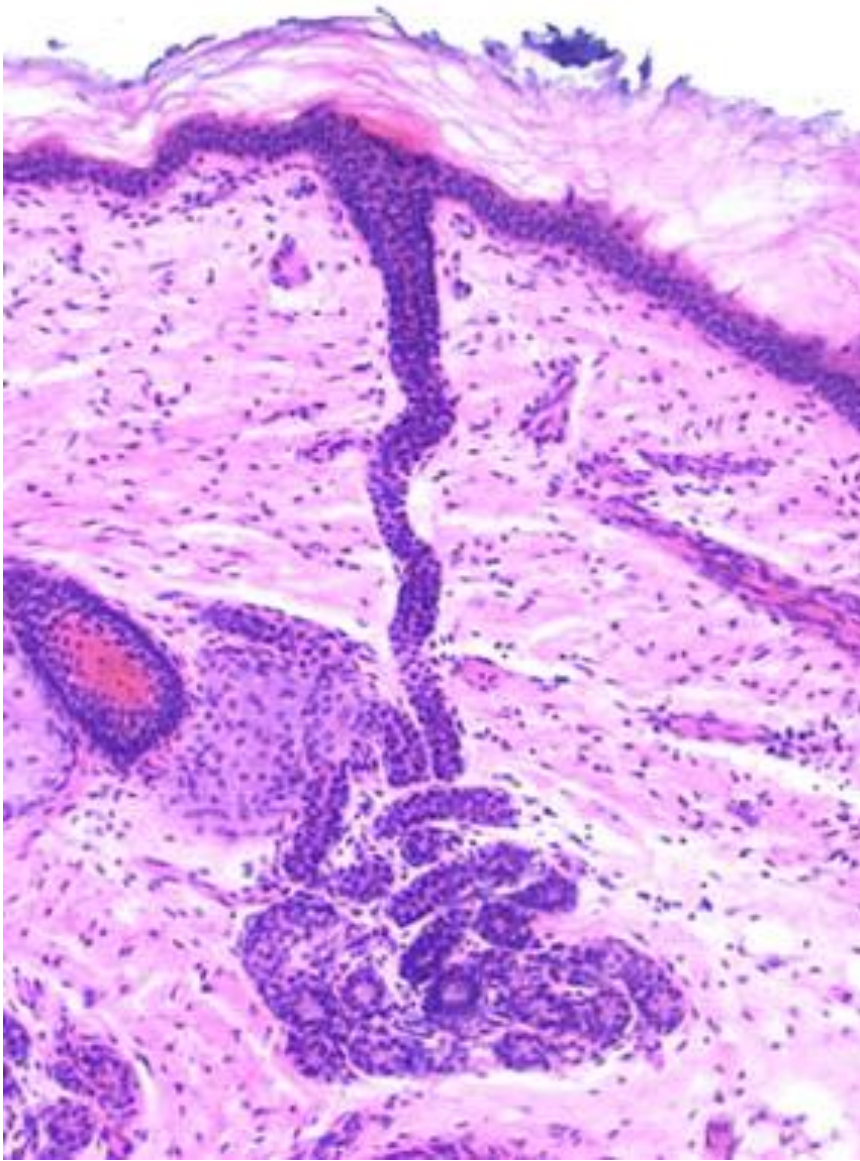
A single, straight tubular lumen into which the secretory products are discharged eg. mucus-secreting gland of the colon; **crypt of Lieberkühn**



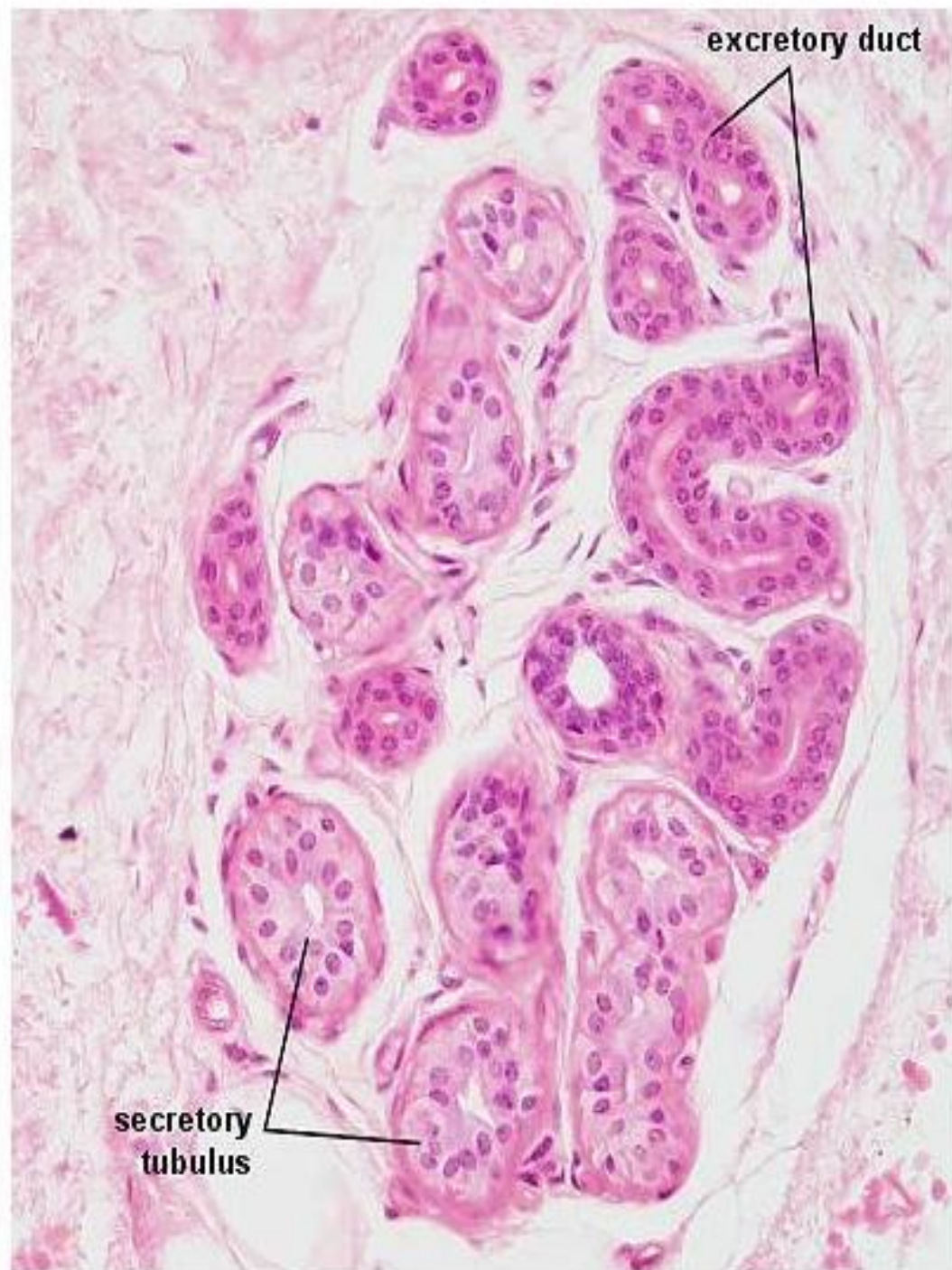
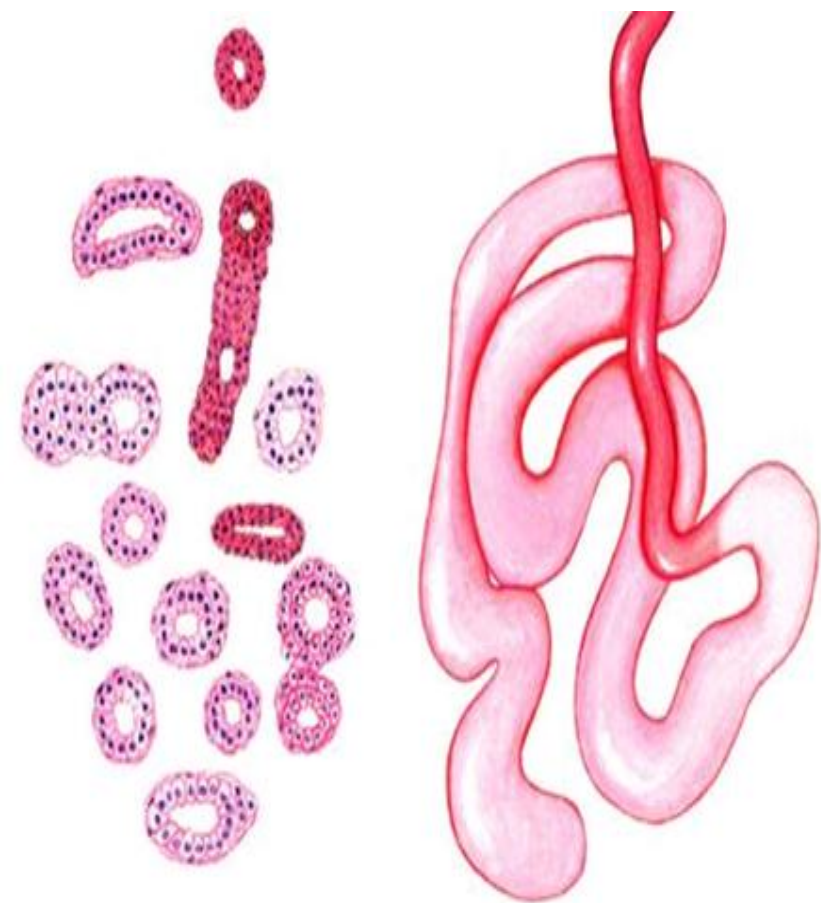


Simple coiled tubular

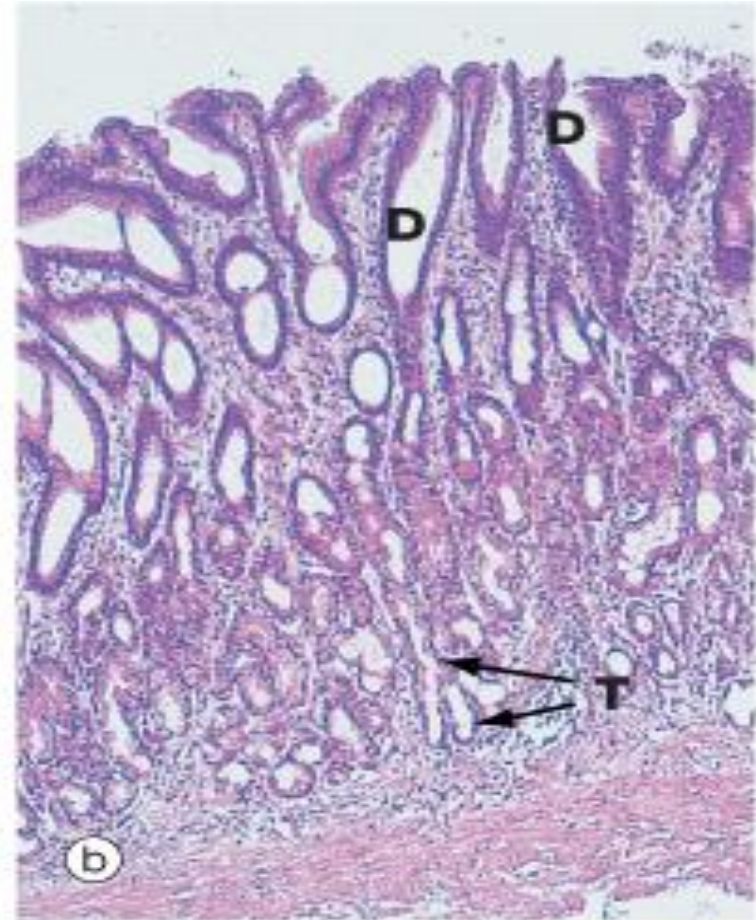
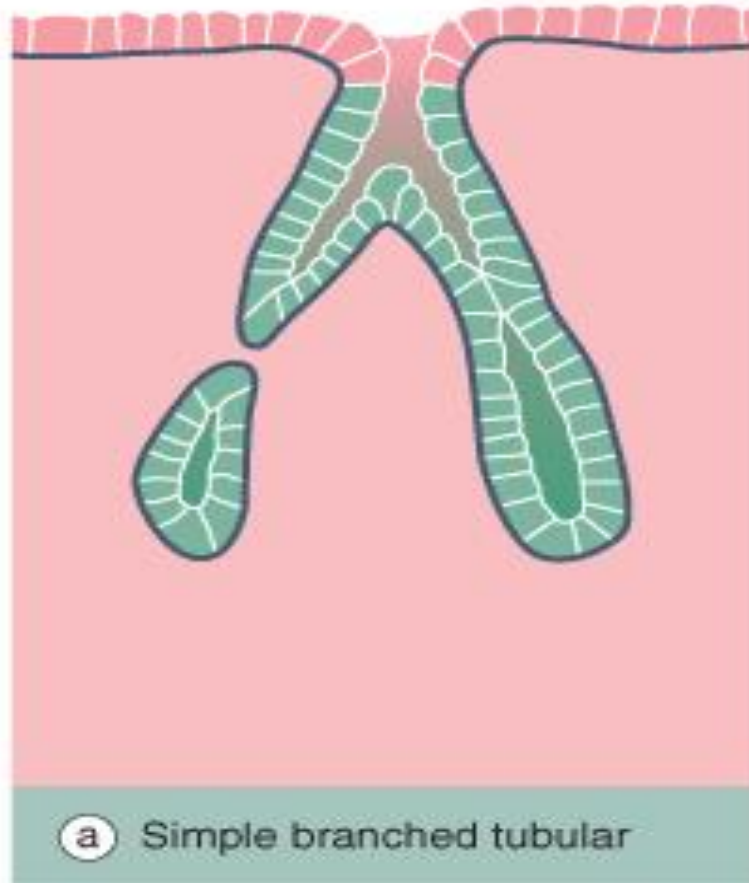



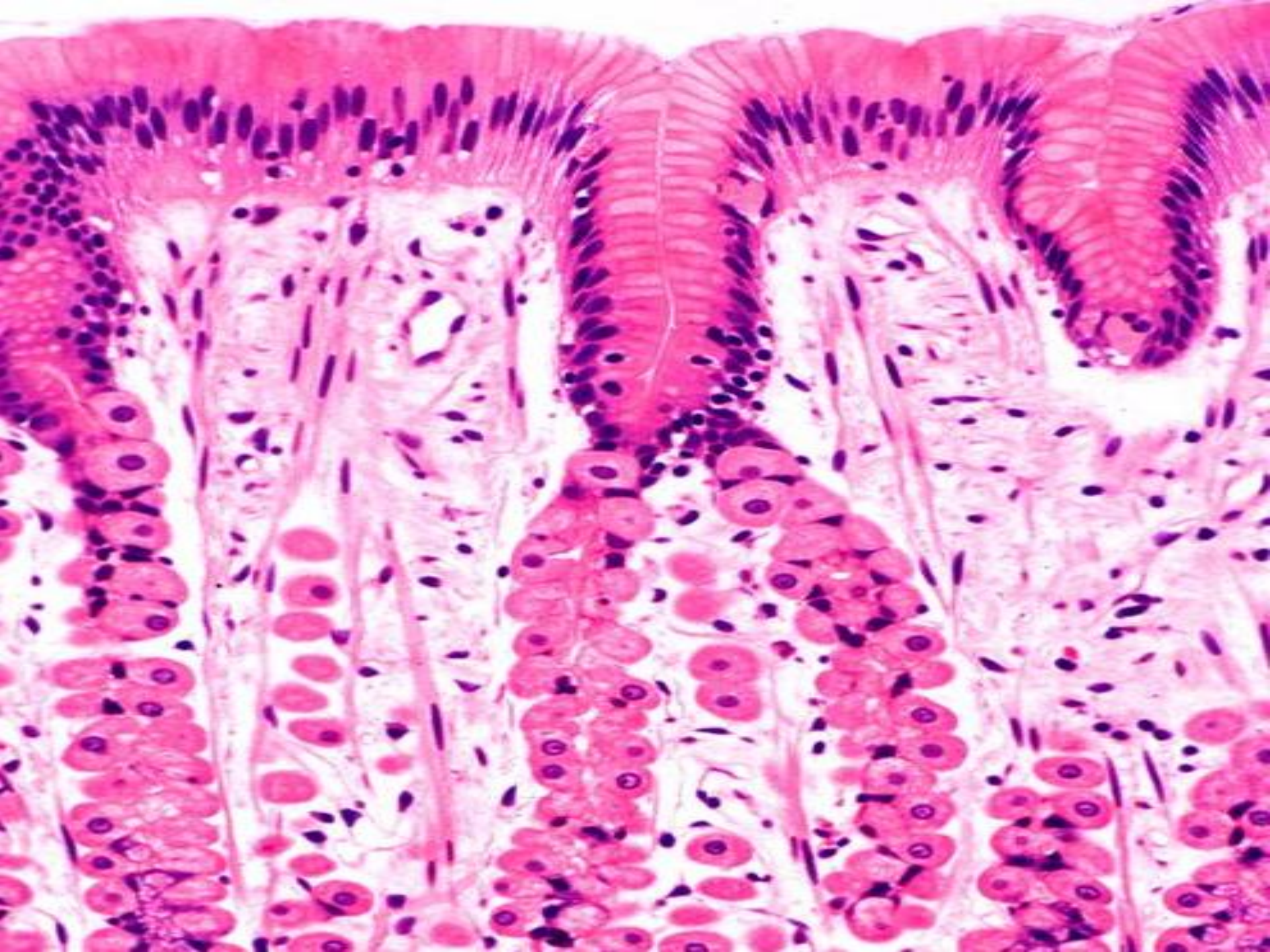A single tube, tightly coiled in 3 dimensions eg. Sweat glands



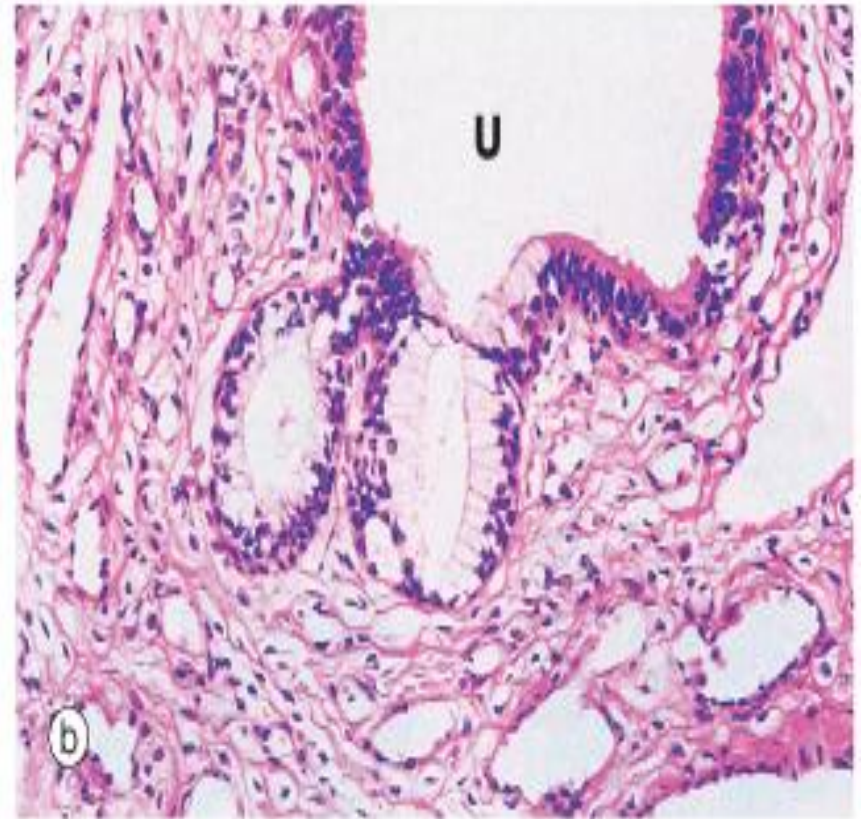
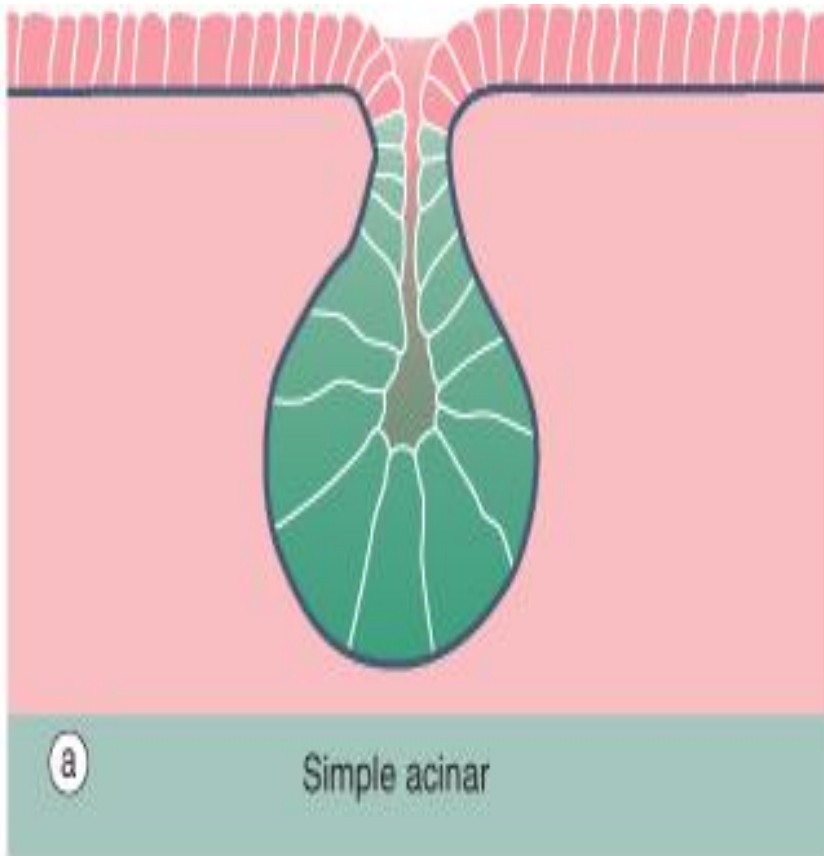
Simple branched tubular



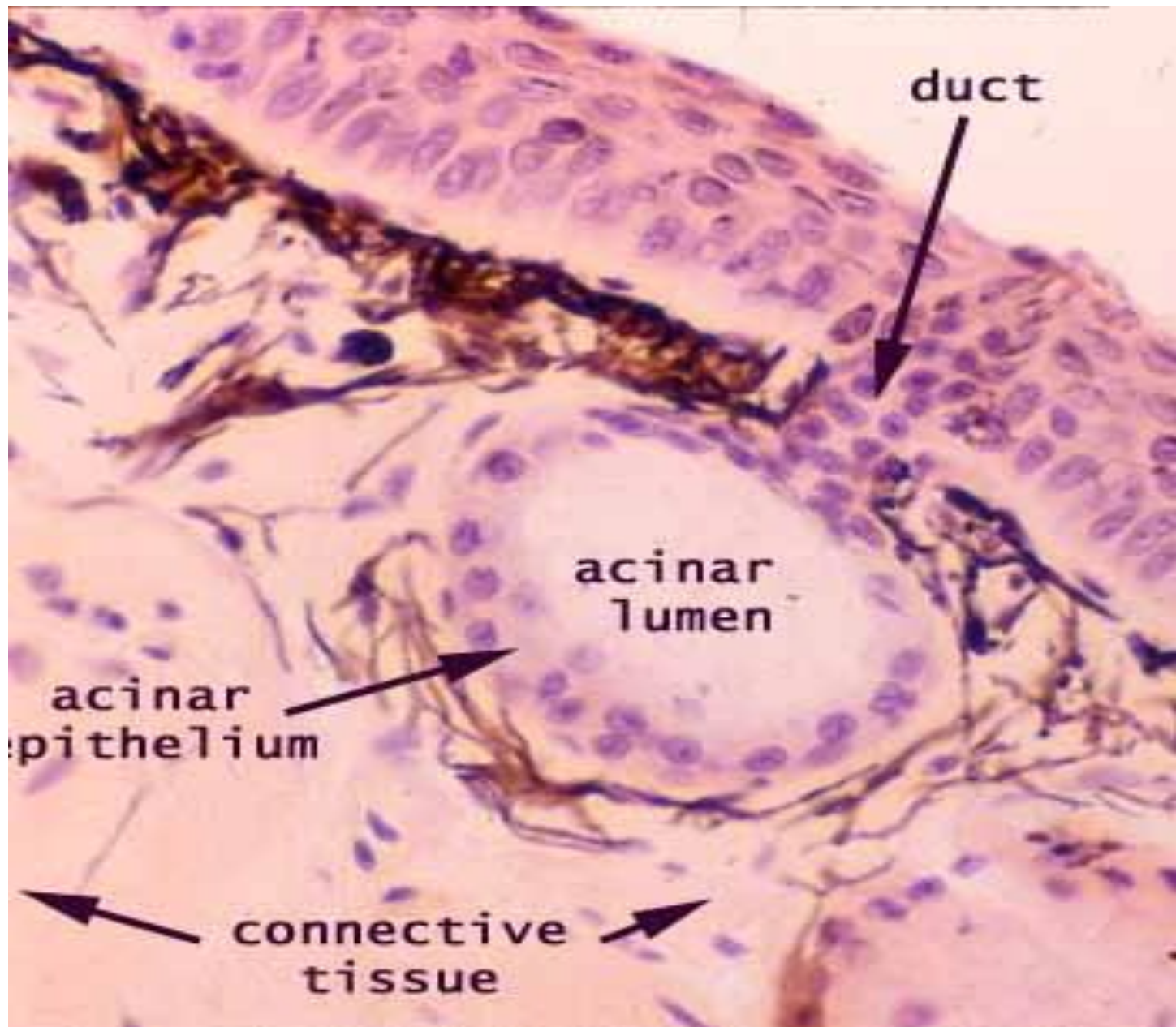
Several tubular secretory portions (T) converge onto a single unbranched duct (D)
eg. Mucus-secreting gland of **the stomach** and **uterus**



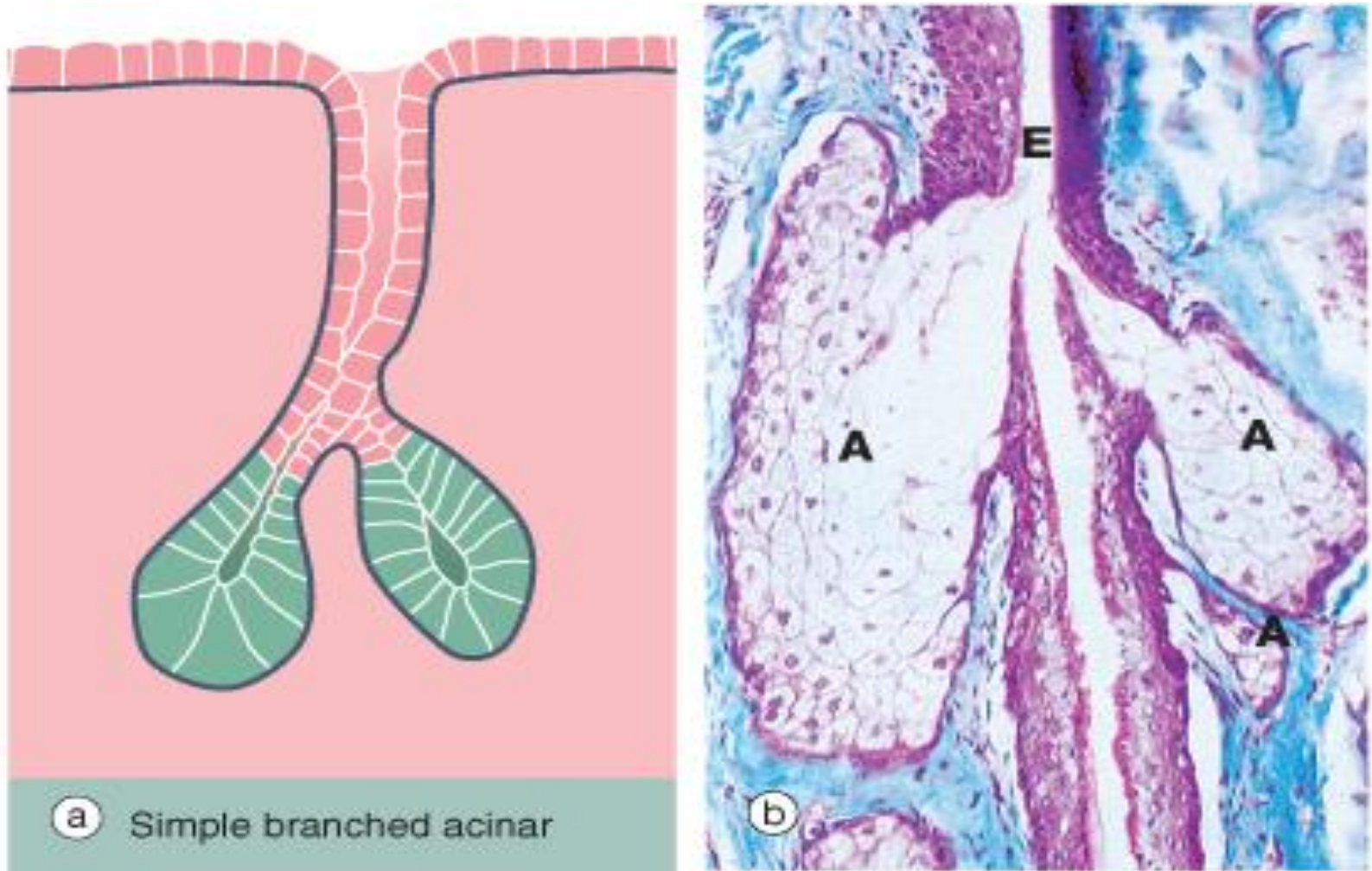
Simple acinar



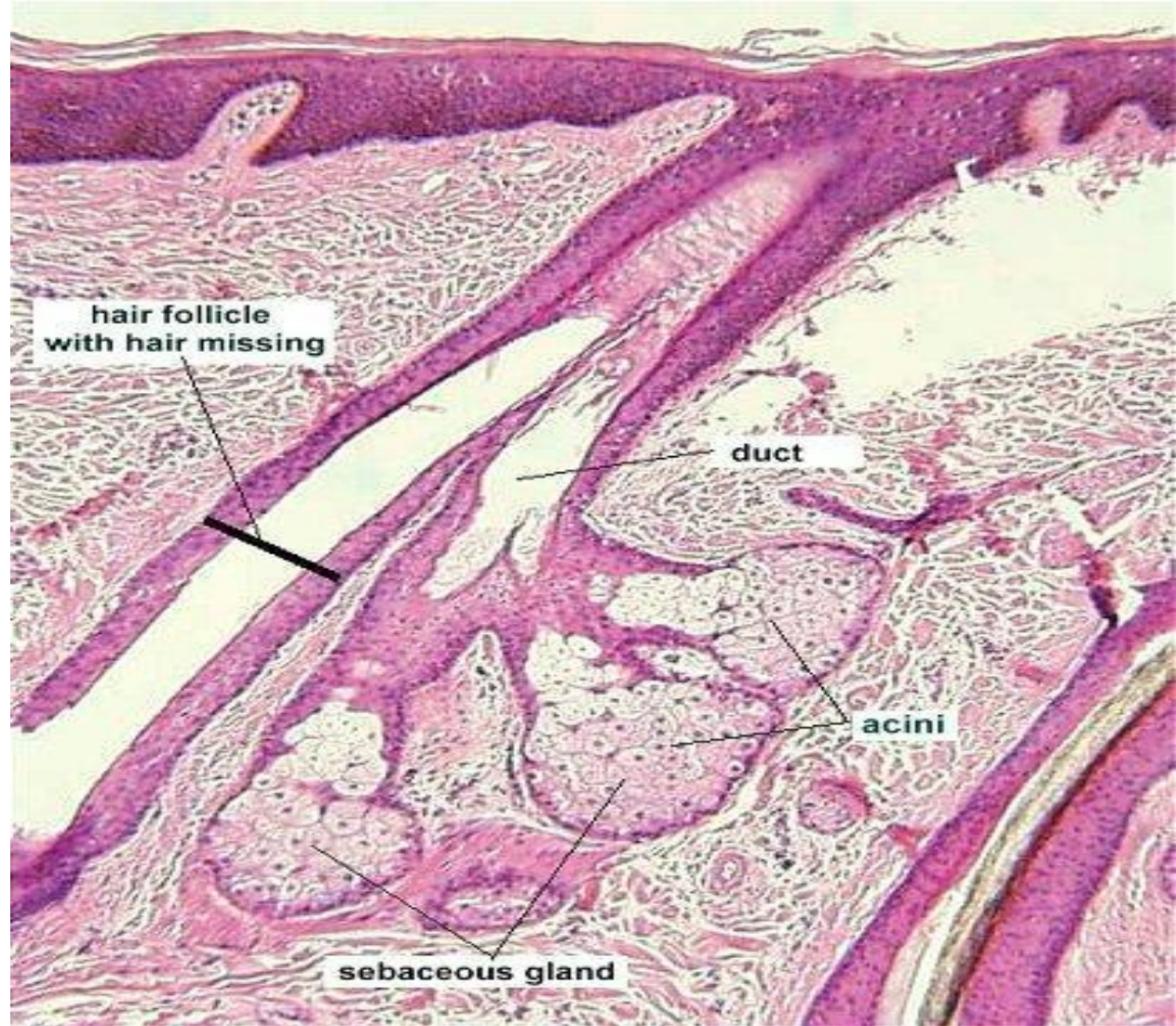
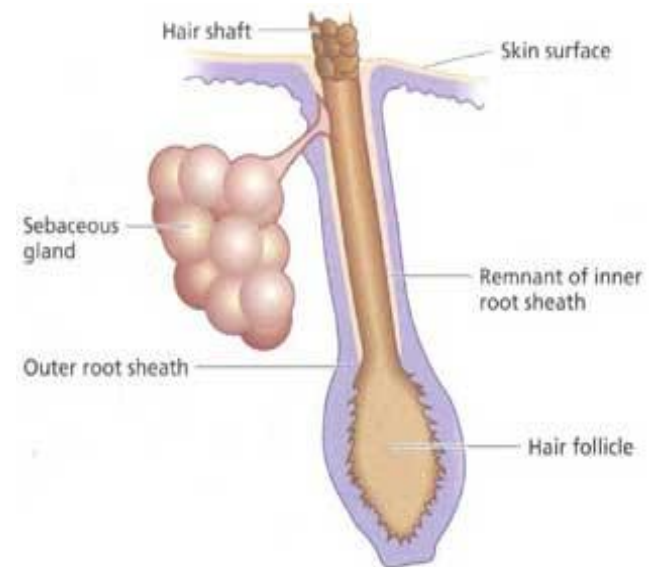
Occur in the form of pockets in epithelial surfaces. Lined by secretory cells eg. Small mucous glands along the **urethra**.

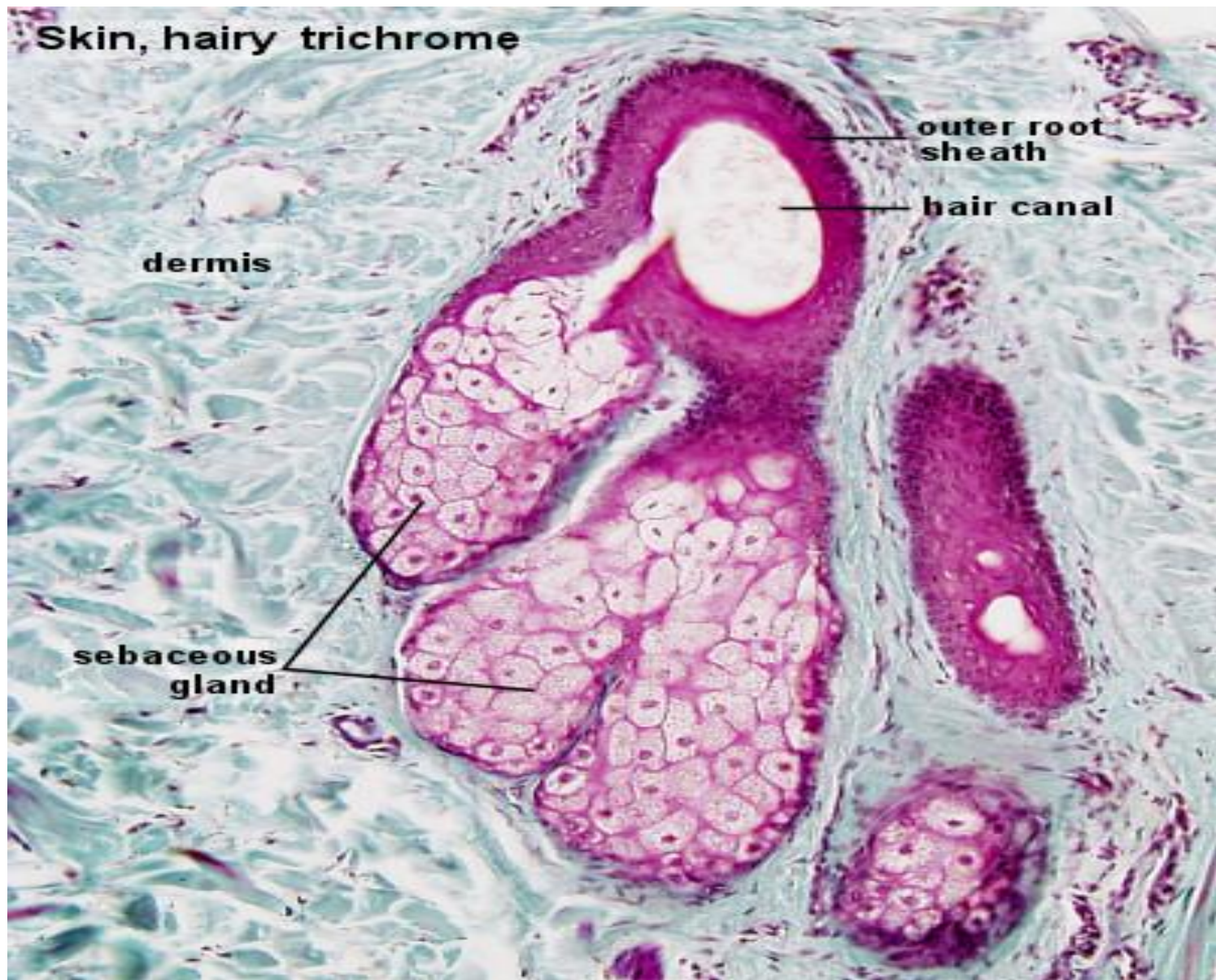


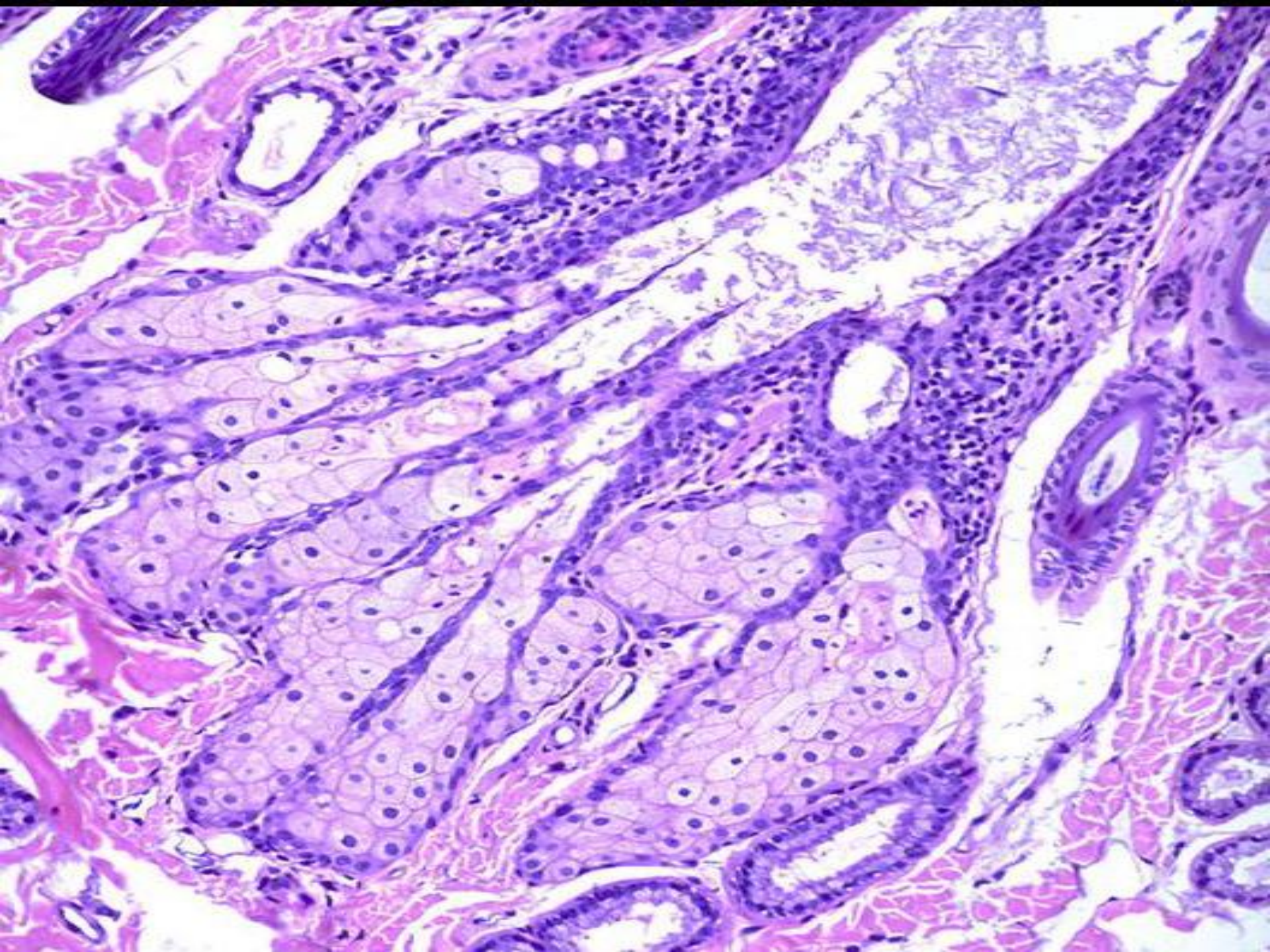
Simple branched acinar



Each gland consists of several secretory acini (A) that empty into a single excretory duct eg. **Sebaceous glands**, sebum secretion

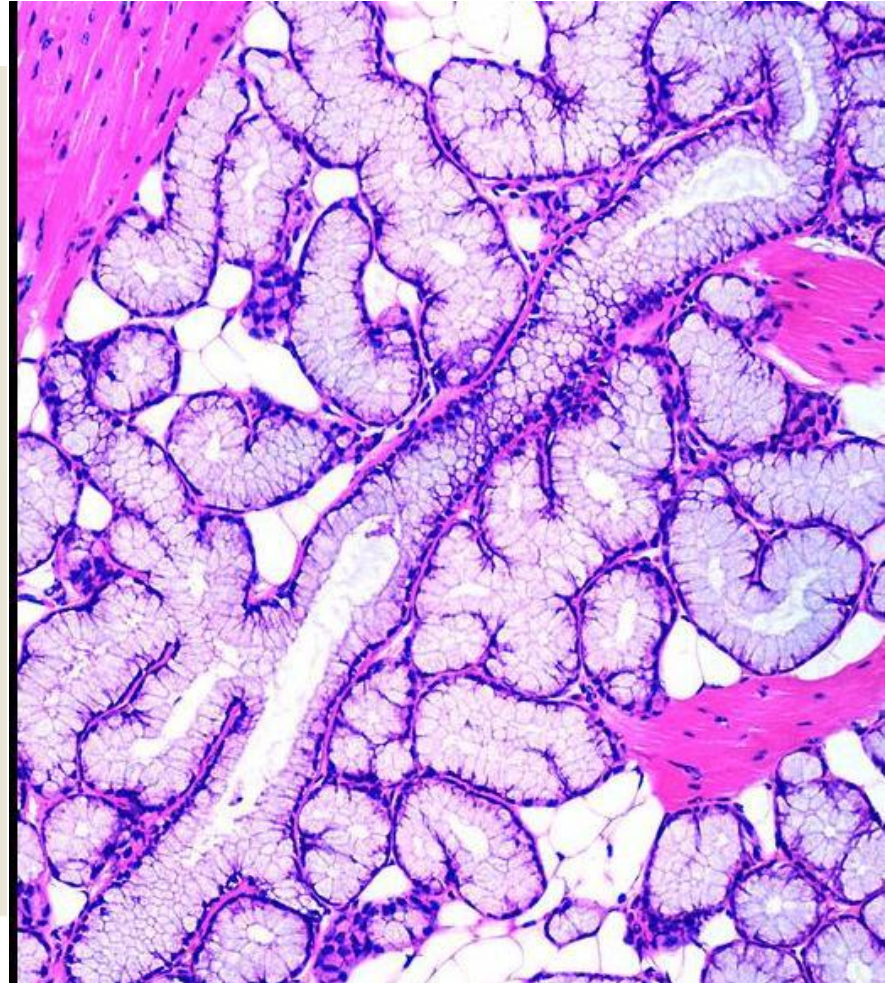
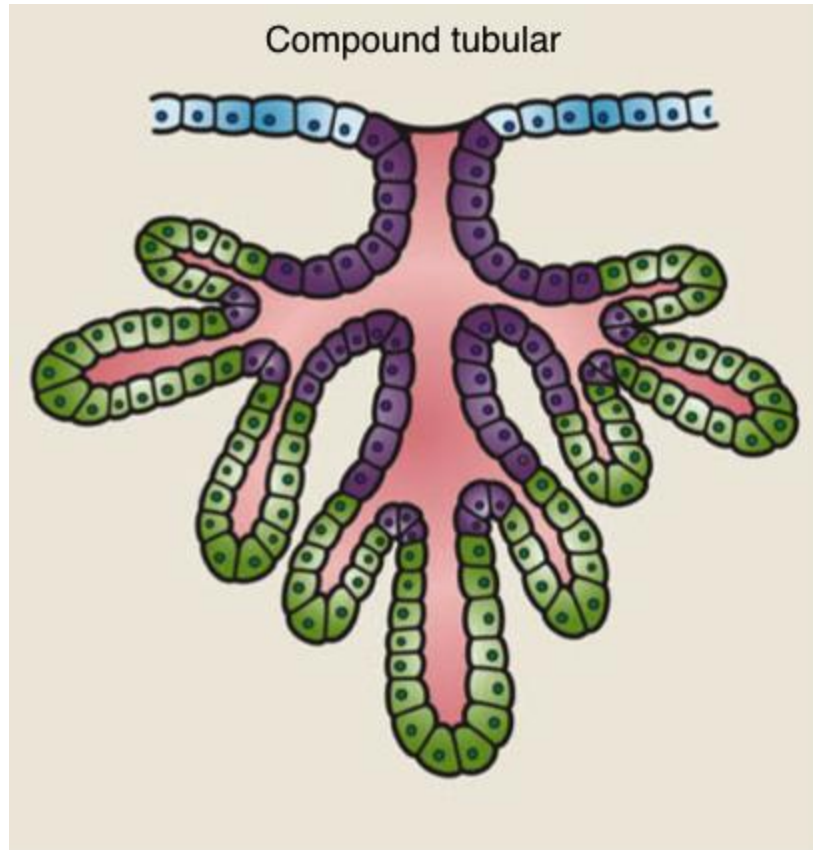




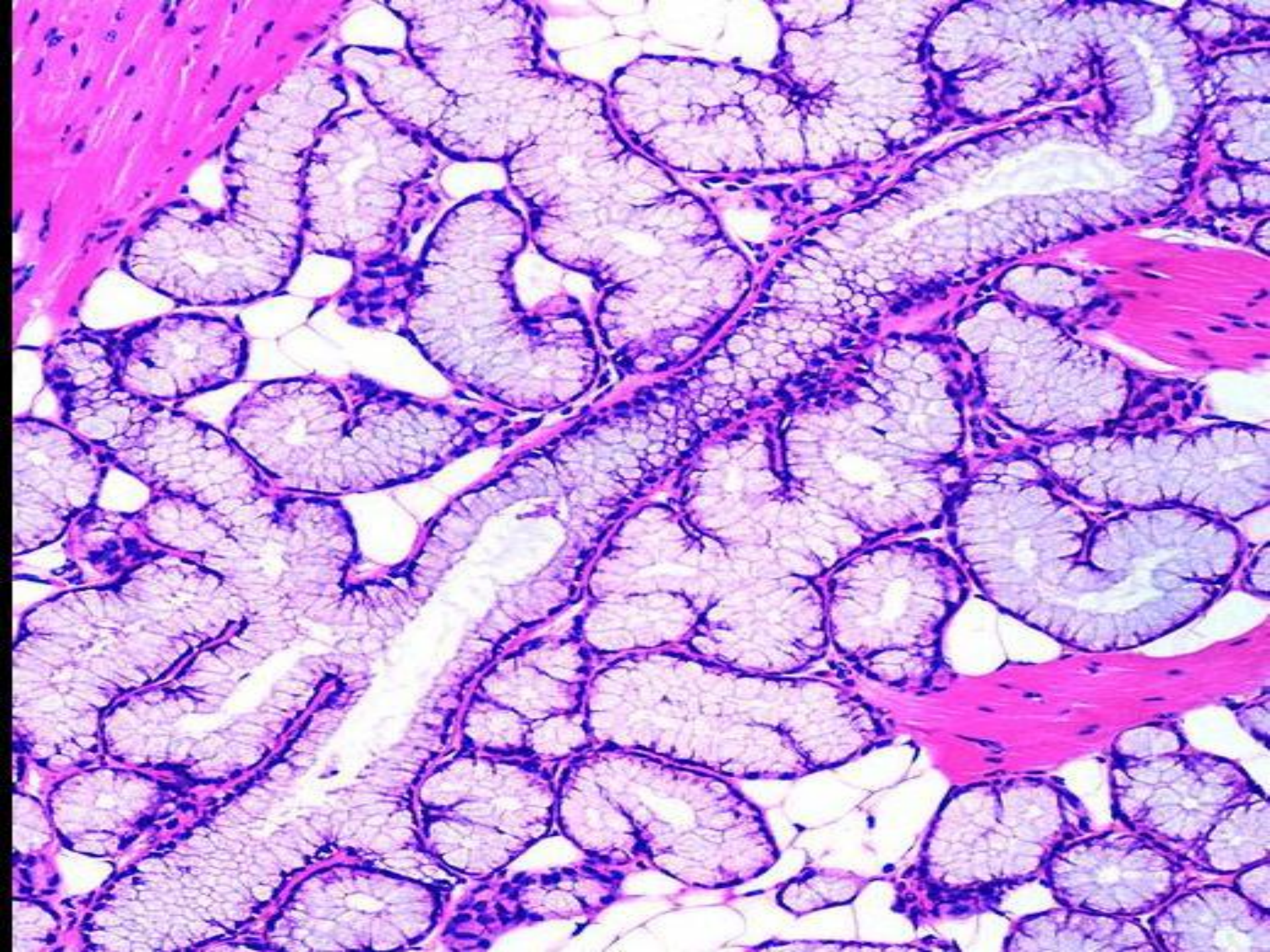


Compound exocrine glands

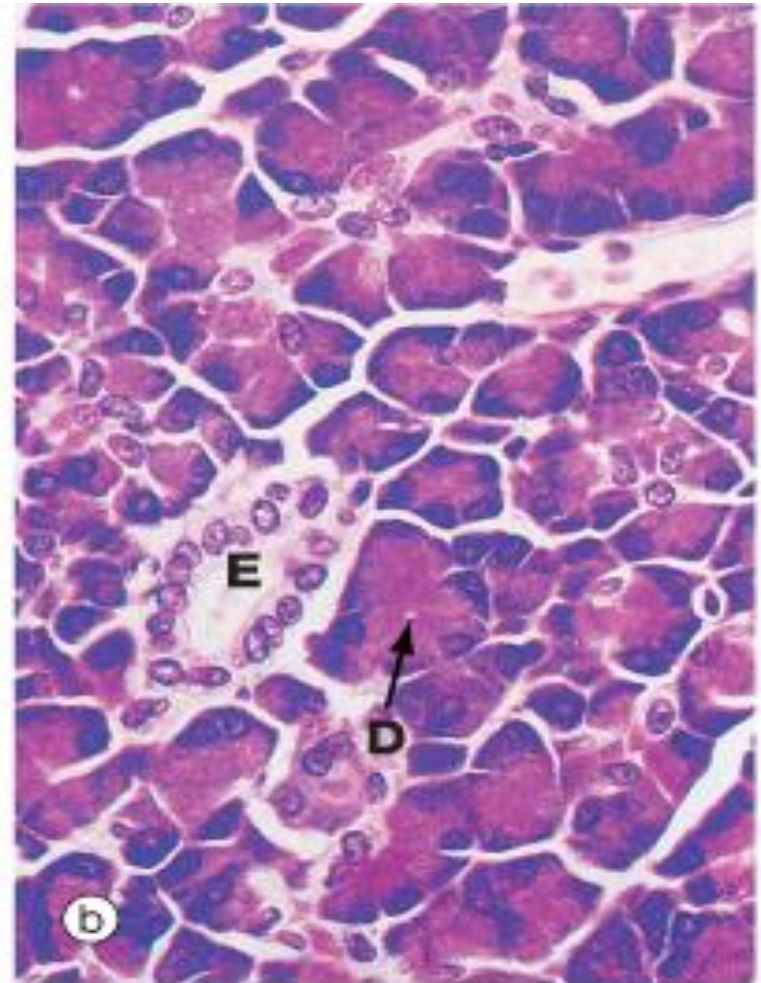
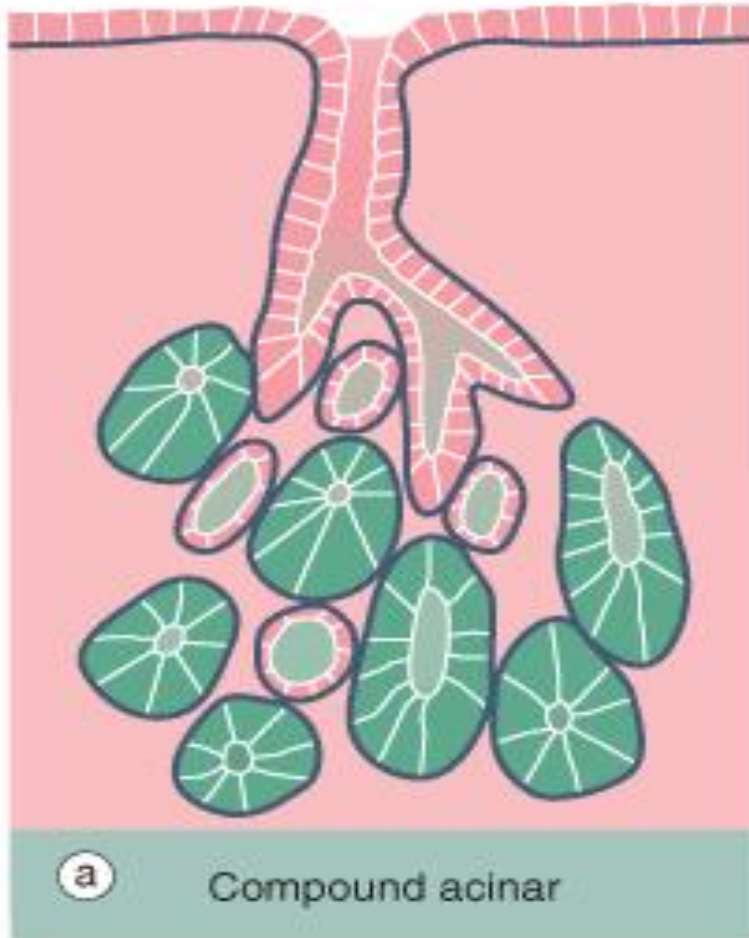Compound tubular



Secretory portion is branched and coiled and the duct system is also Branched (difficult to visualize) eg. **Brunner's gland of the duodenum**

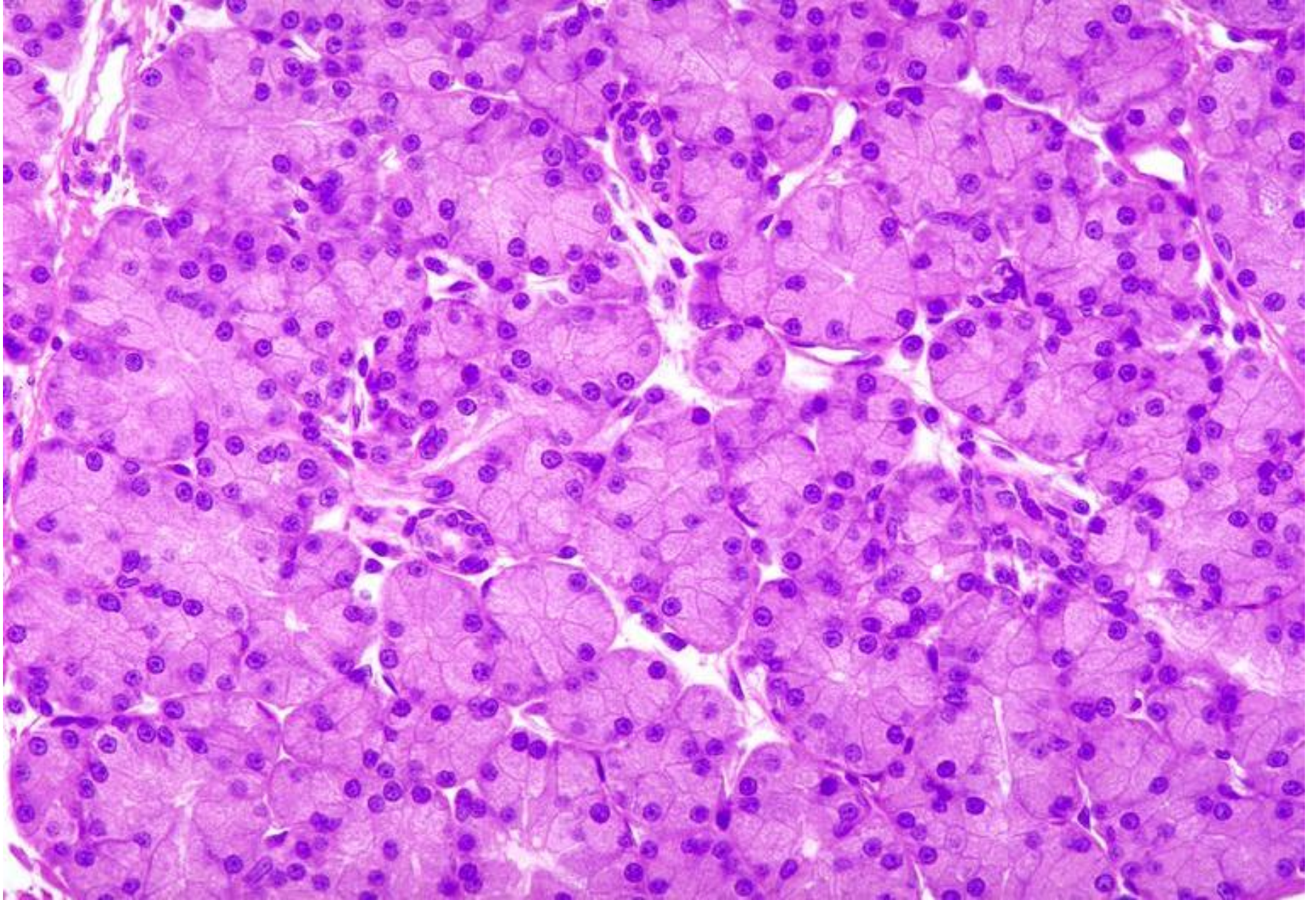


Compound acinar



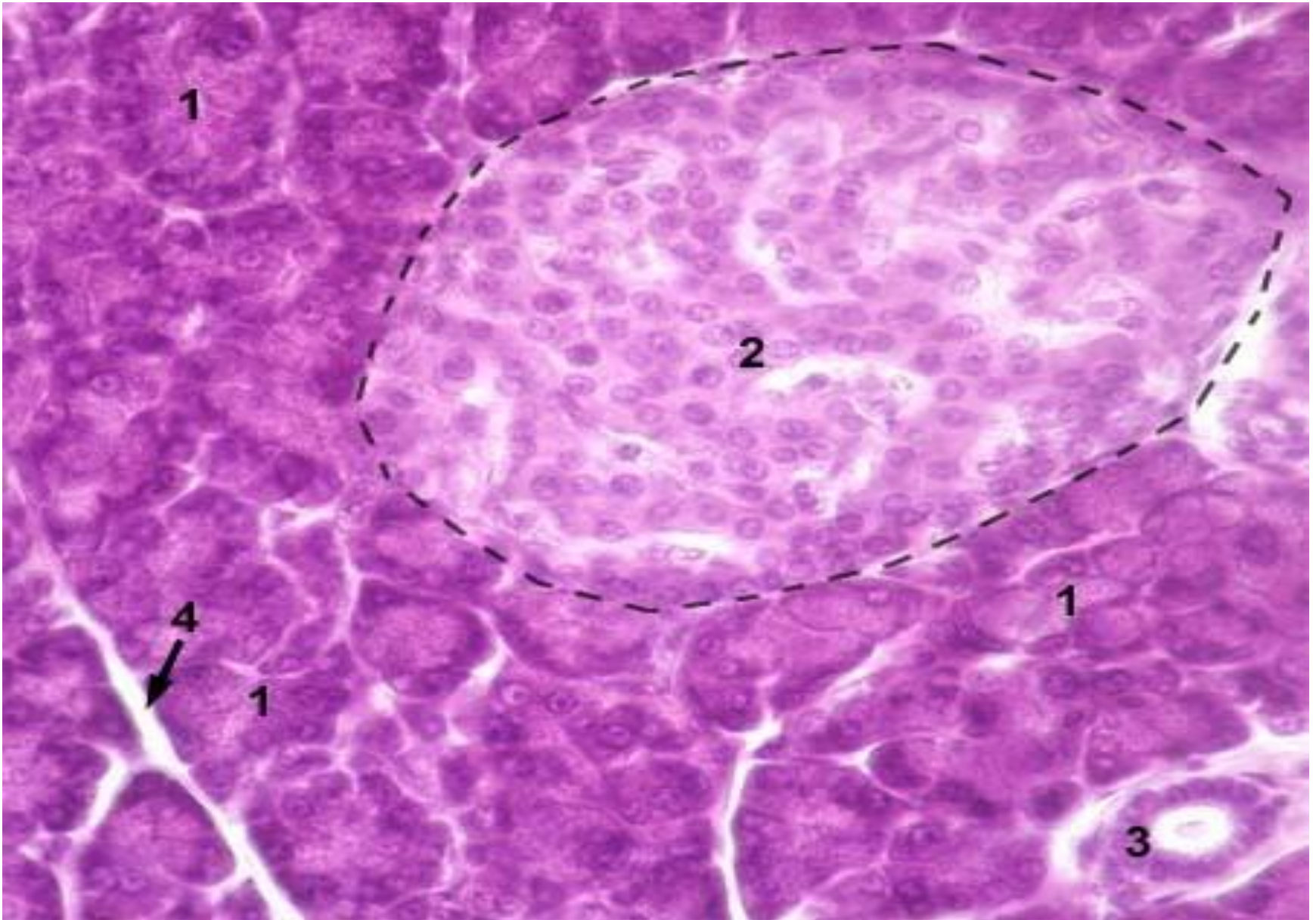
Secretory units are acinar and drain into a branched duct system
eg. **Exocrine pancreas**

Serous gland



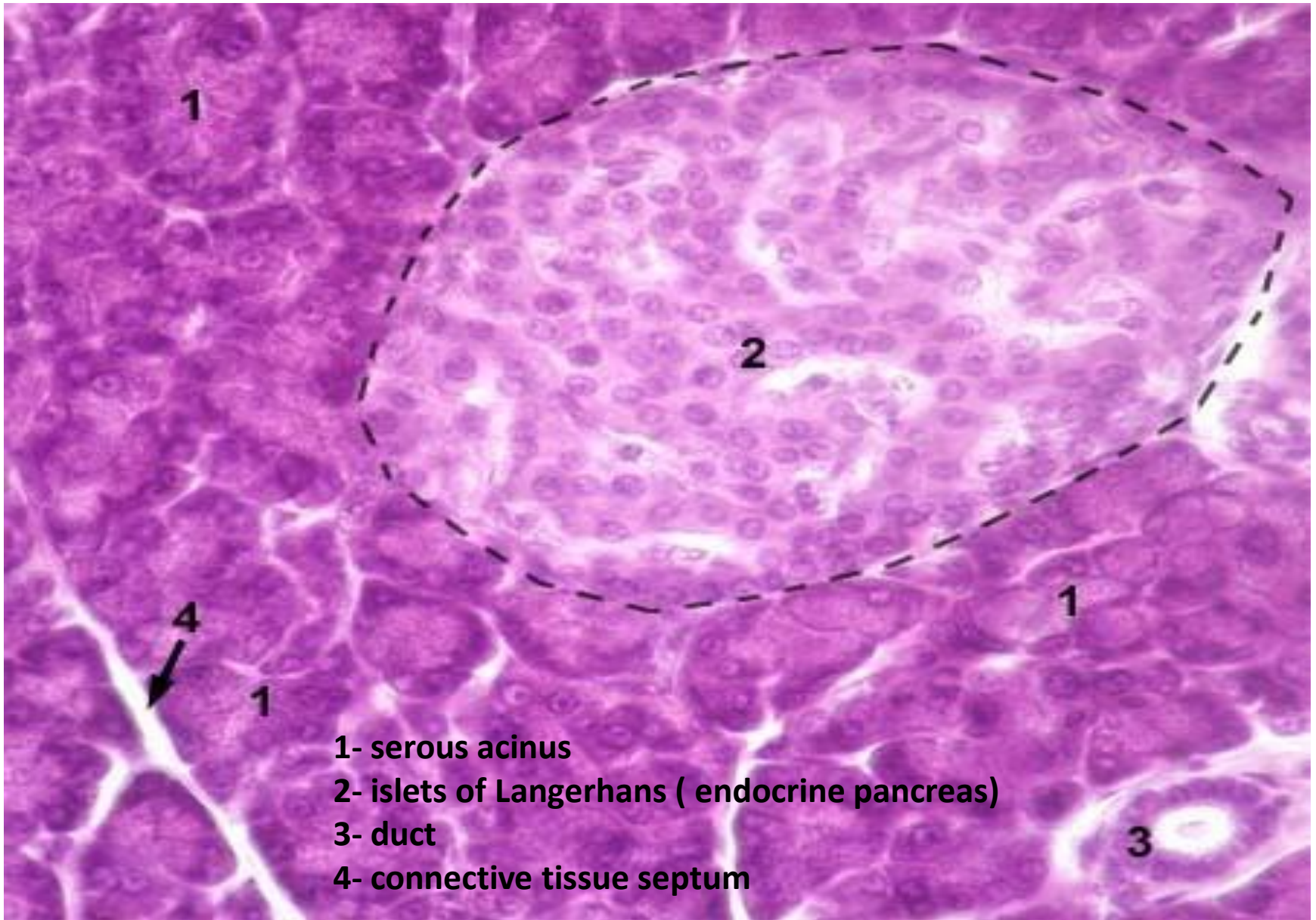
Parotid gland

Serous gland



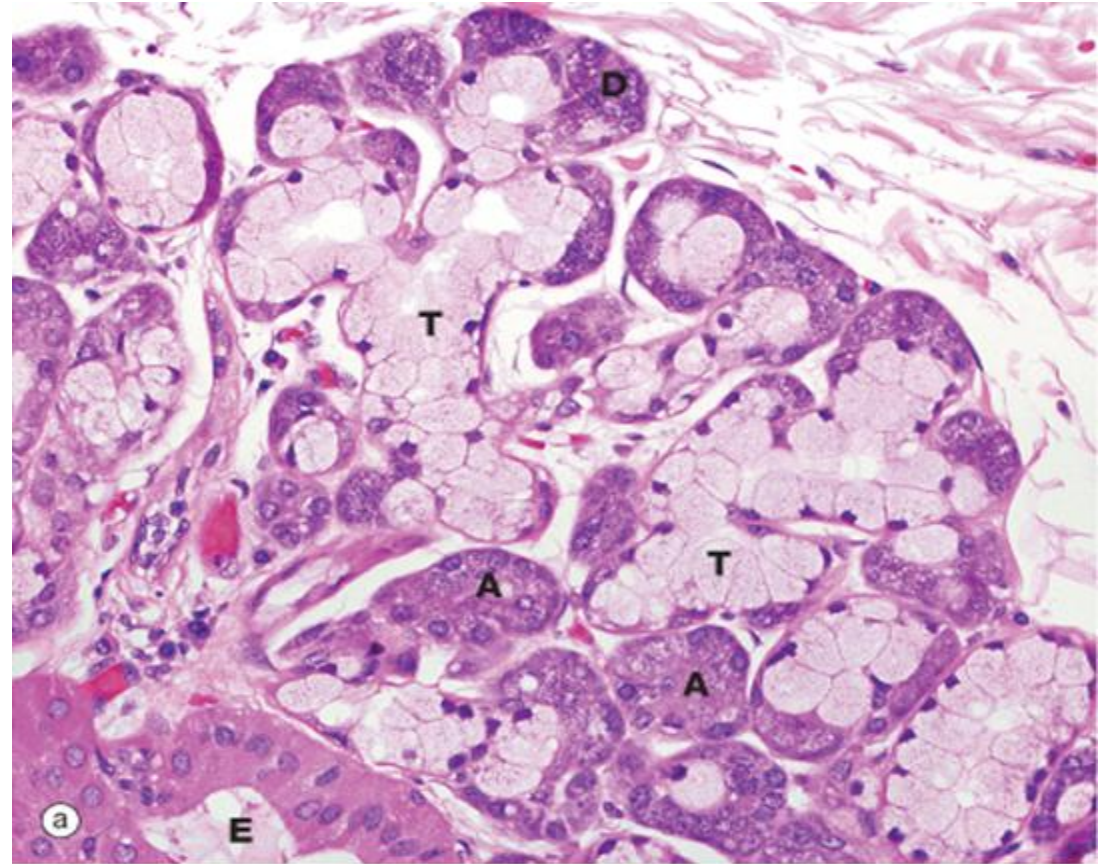
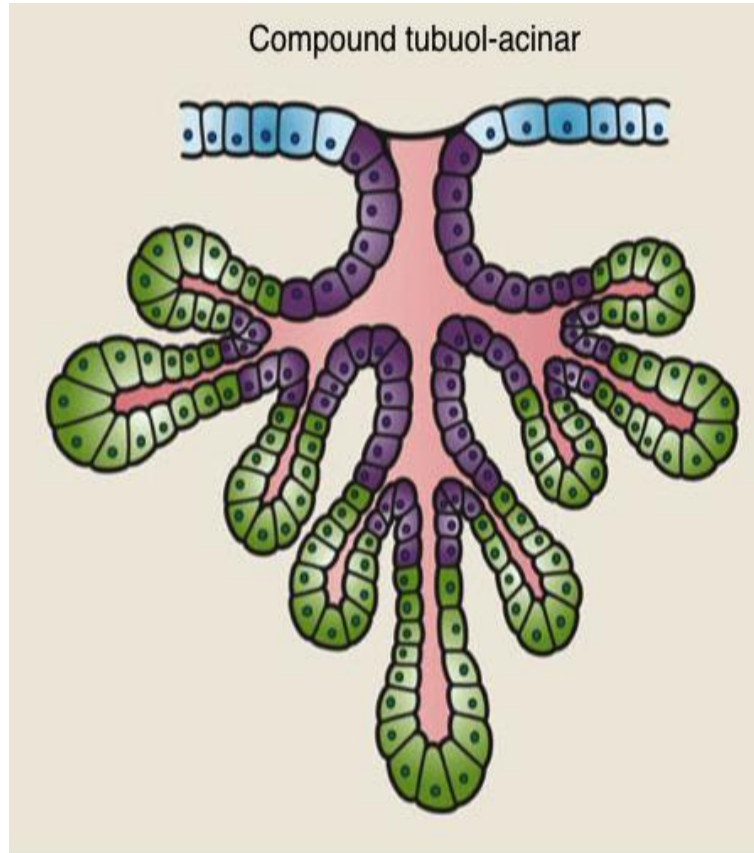
Pancreas

Serous gland



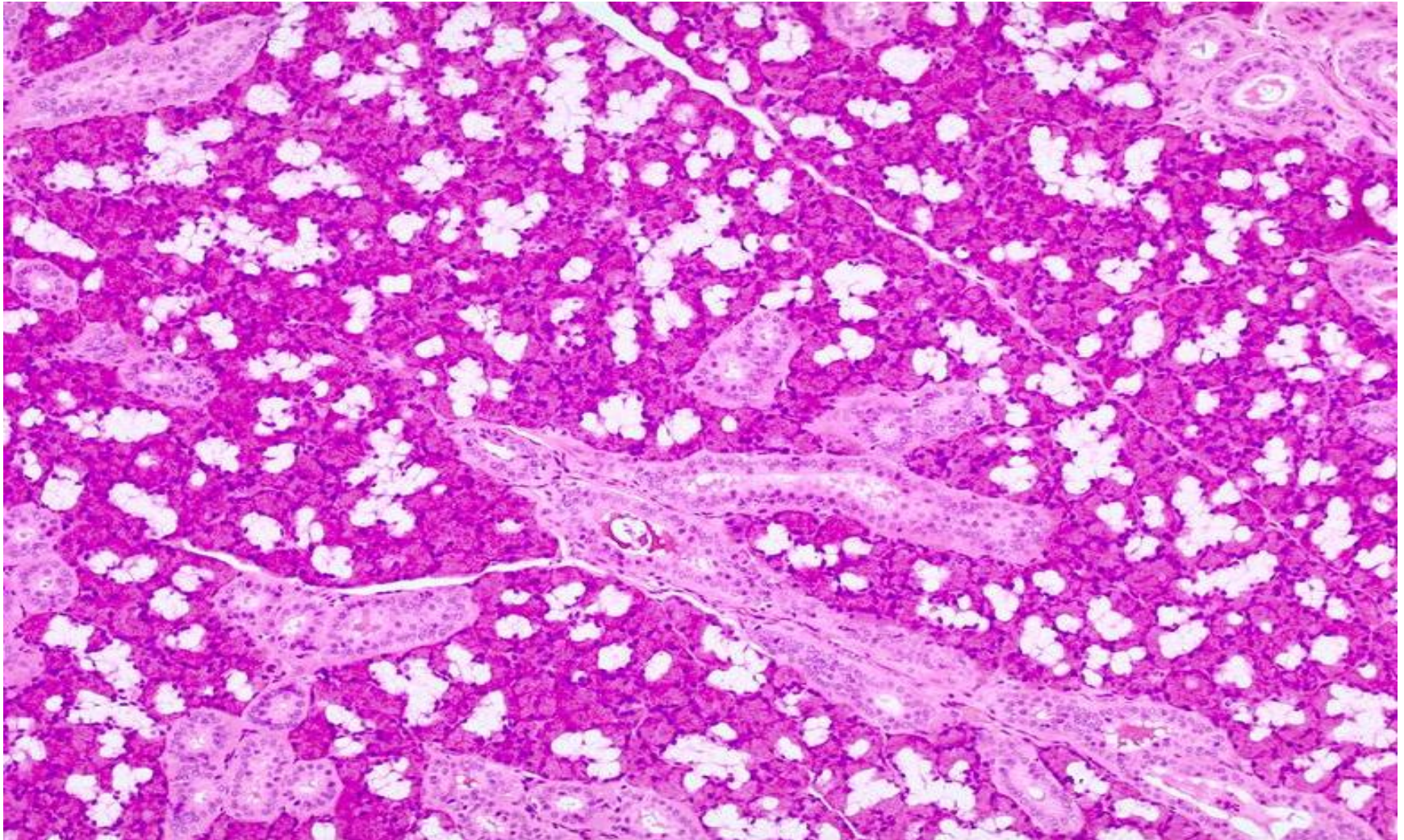
Pancreas

Compound tubulo-acinar



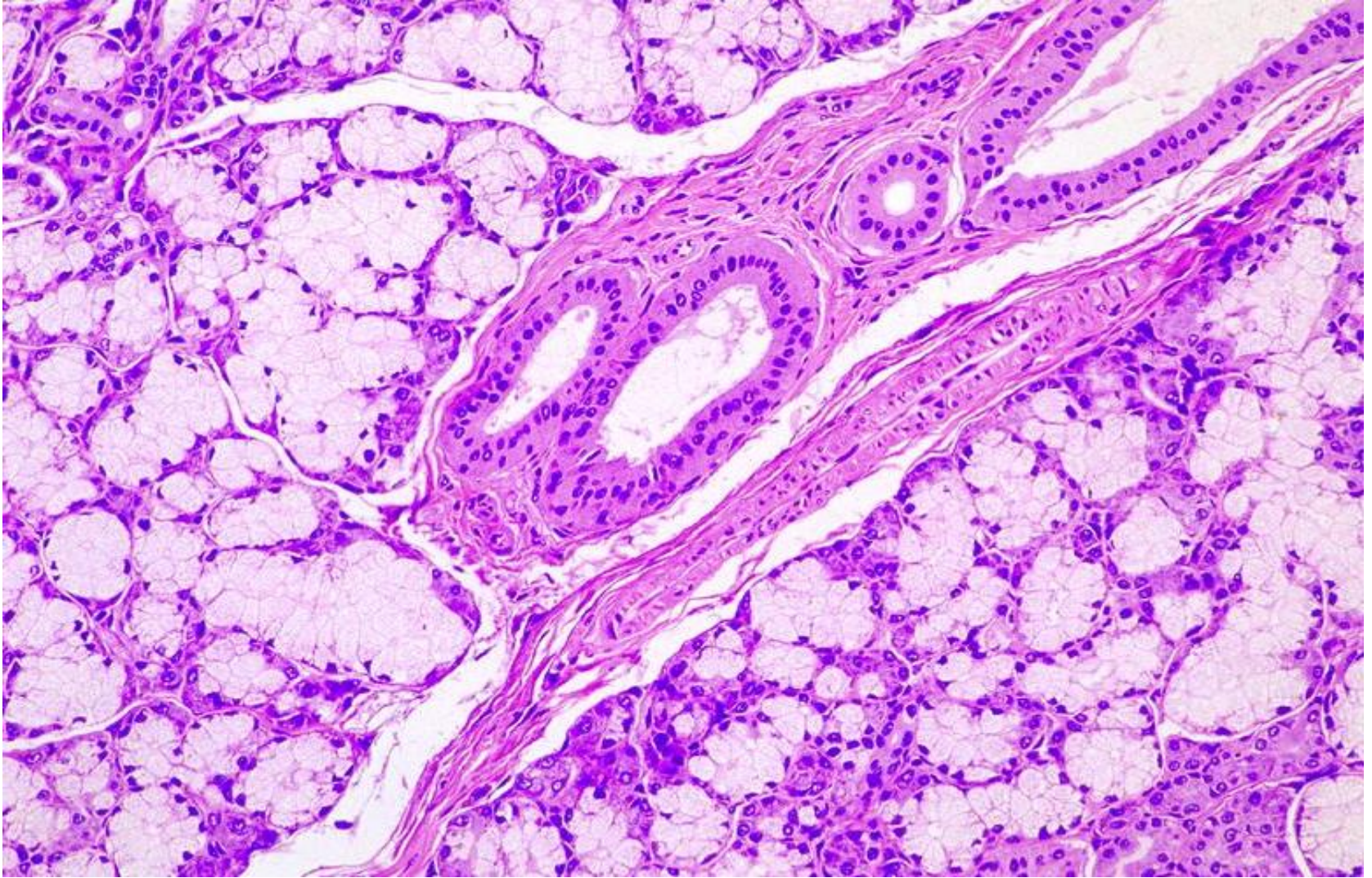
3 types of secretory units:
branched tubular, branched acinar and branched tubular with acinar end-
pieces called demilunes eg. **salivary gland**

Mixed gland: Seromucous gland



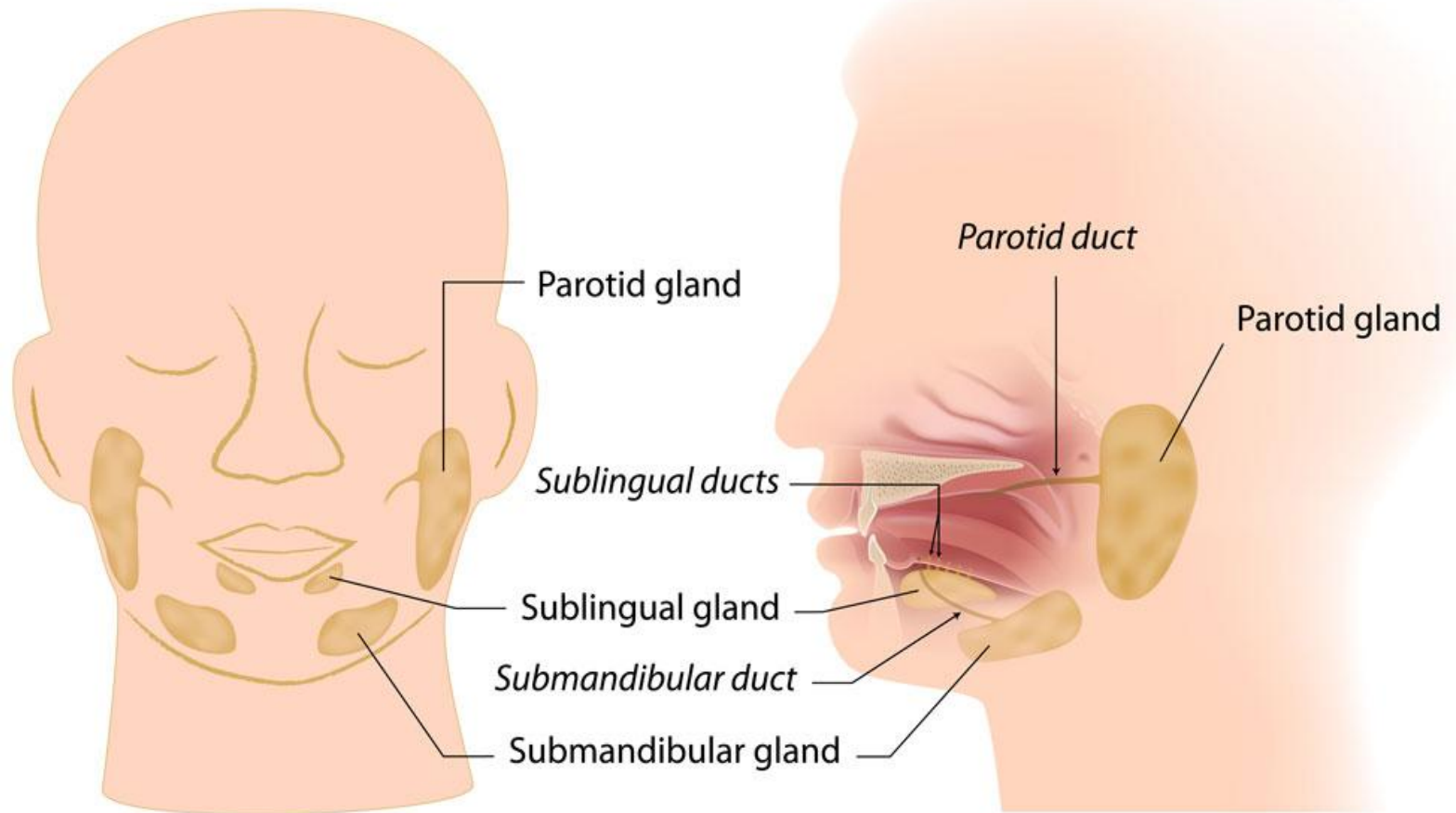
Submandibular gland

Mixed gland: Mucoserous gland

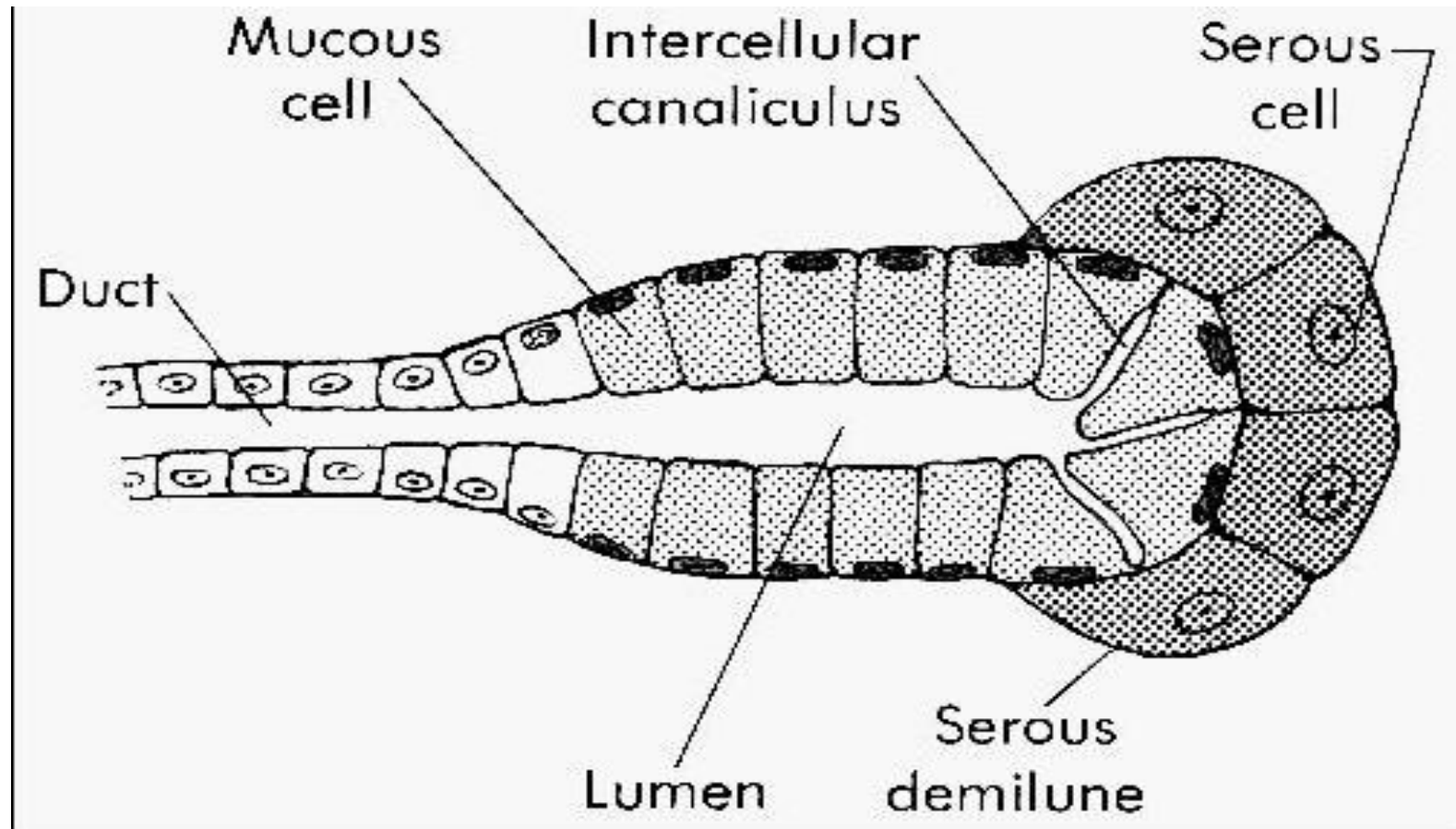


Sublingual gland

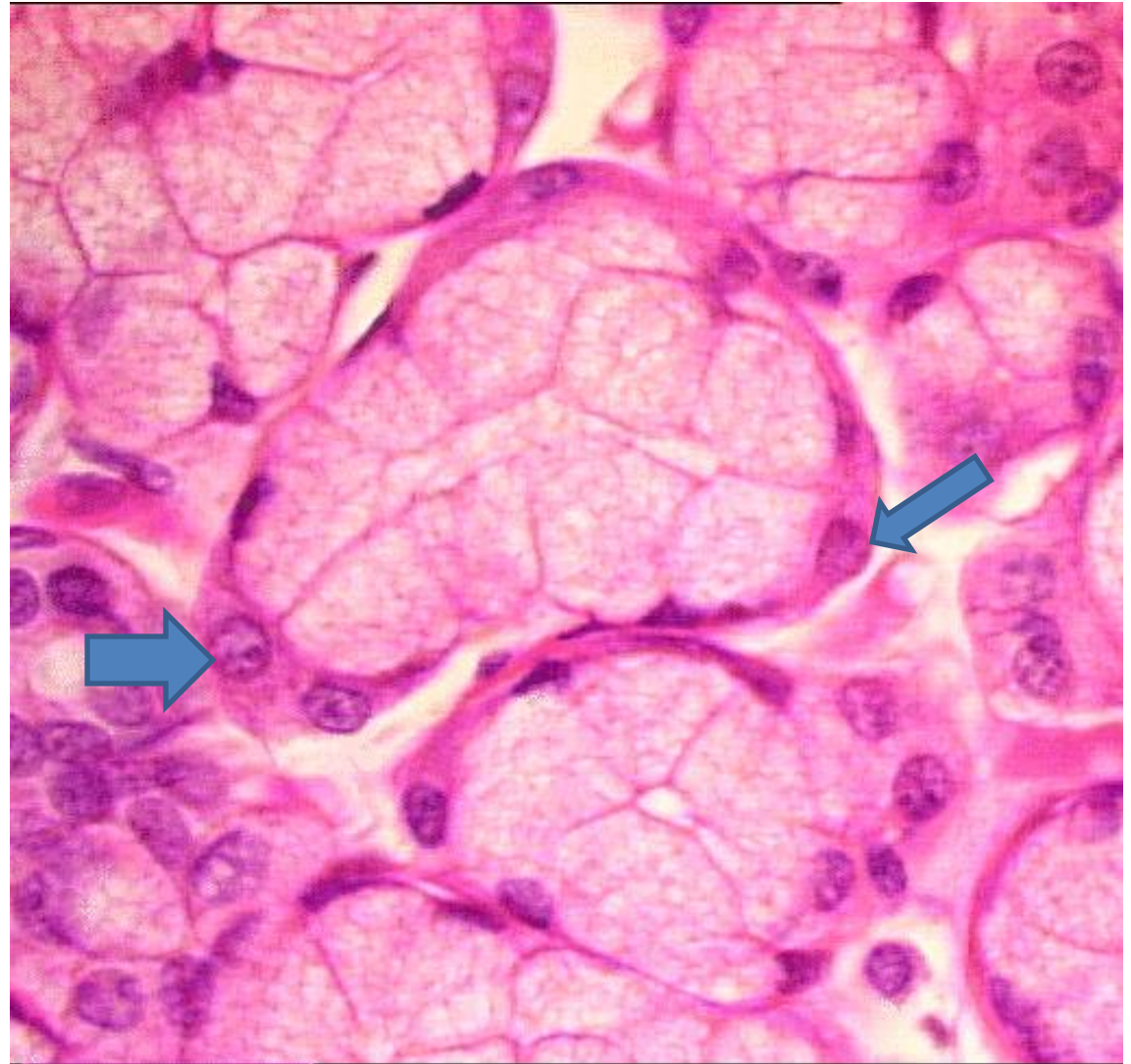
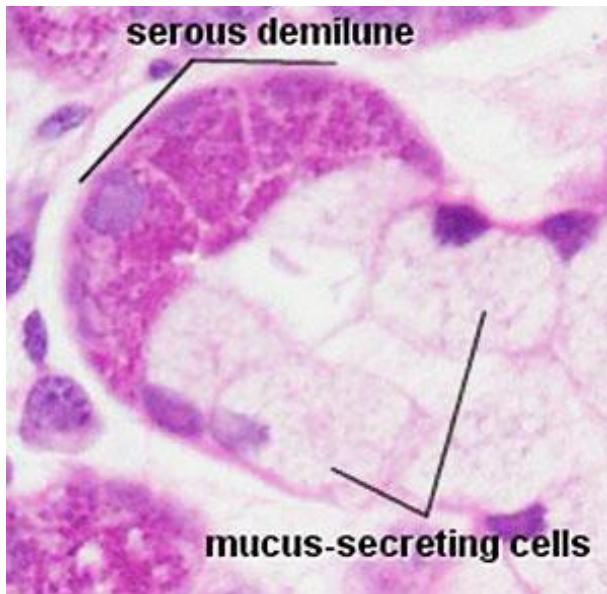
The Salivary Glands



Serous demilune



Serous demilune

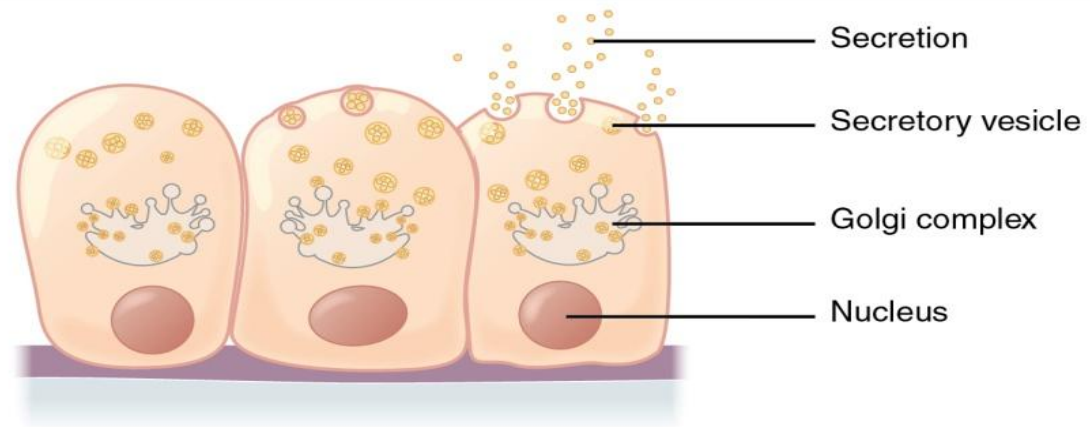


Classification on the basis of the mode of secretion

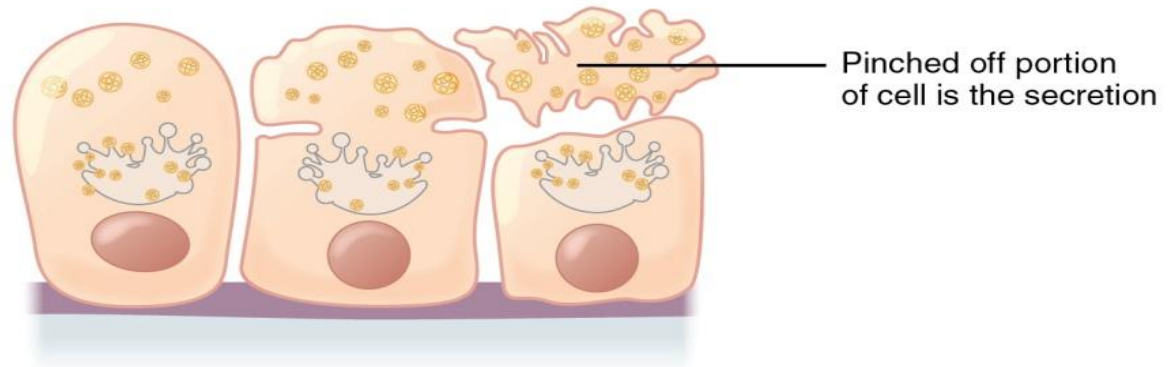
Classification on the basis of the mode of secretion:

- Depending on their **mode of secretion** i.e; the manner in which the secretory product is elaborated.
- The exocrine glands are classified into the following:
 1. **Merocrine (eccrine) glands**
 2. **Apocrine glands**
 3. **Holocrine glands**

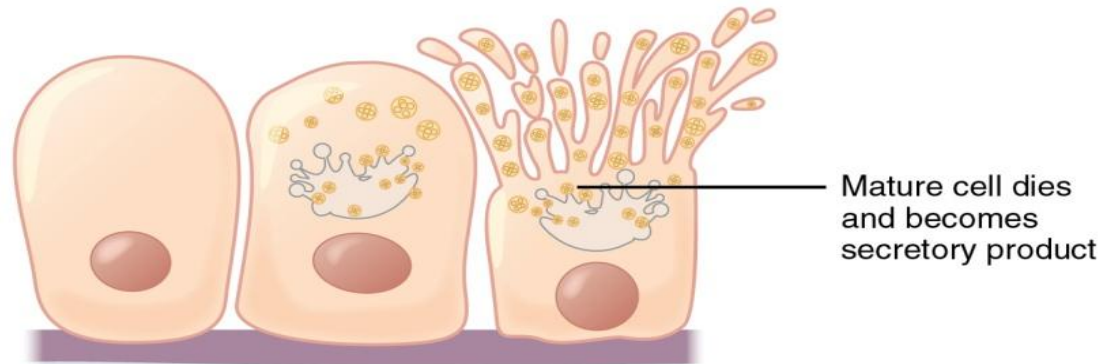
(a) Merocrine secretion

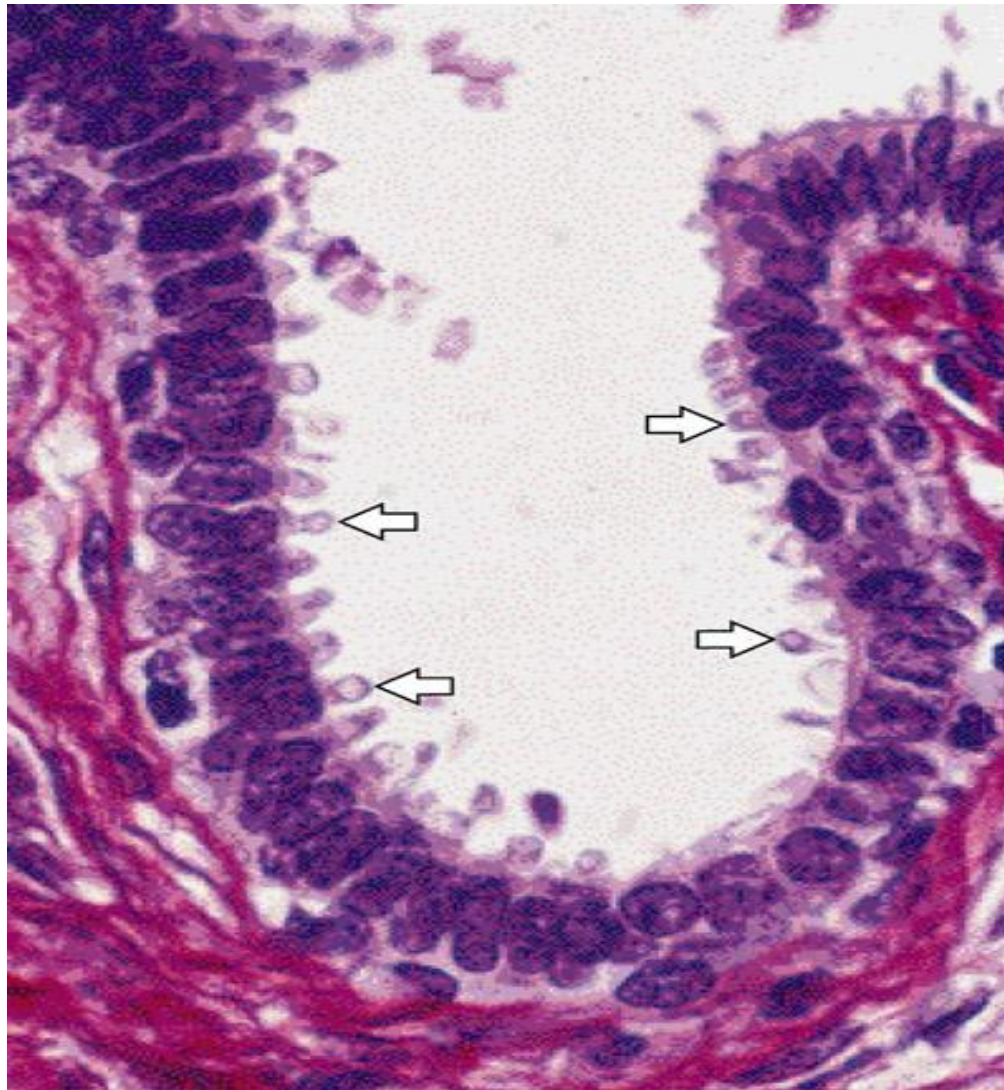


(b) Apocrine secretion



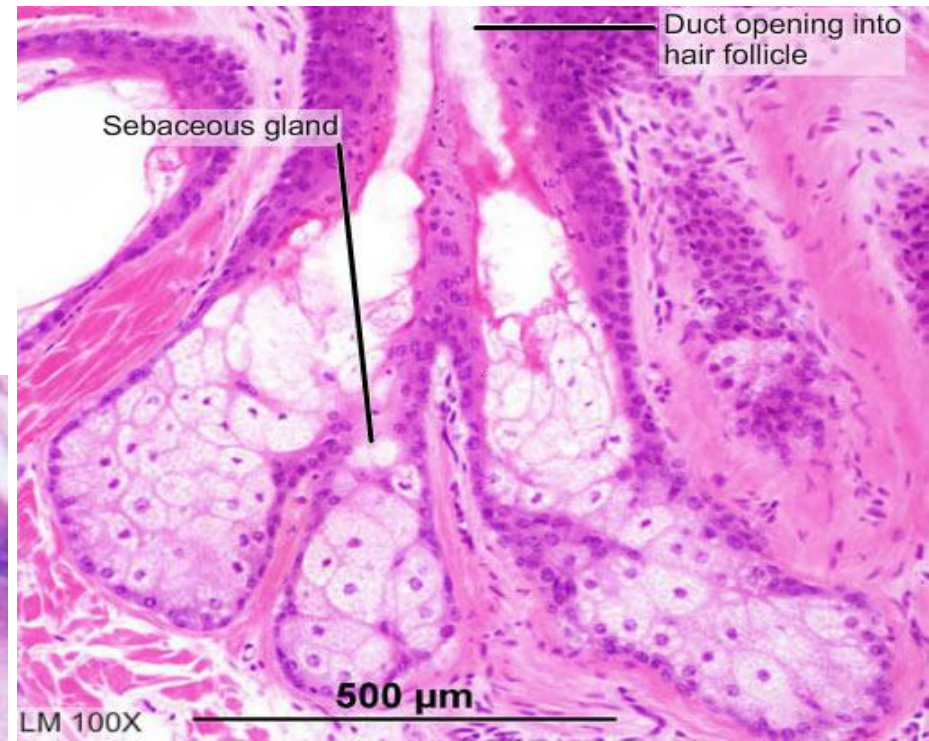
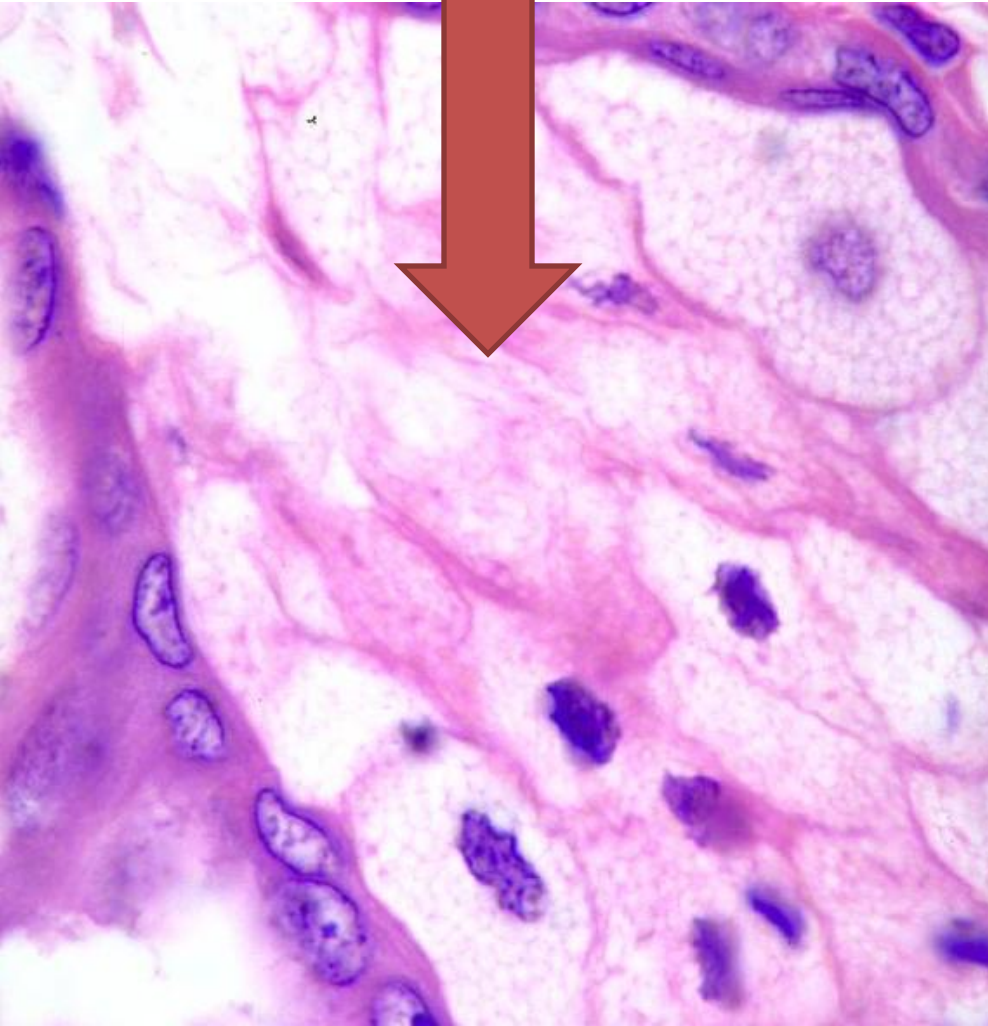(c) Holocrine secretion





Apocrine Mammary gland

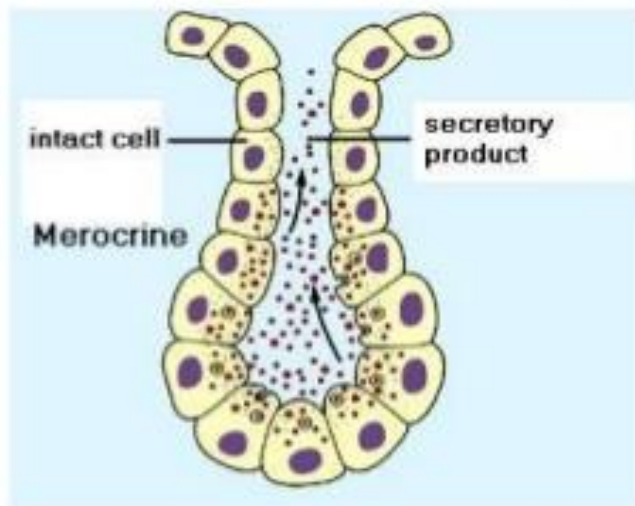
**Holocrine secretion
(Sebaceous gland)**



Types of sweat glands

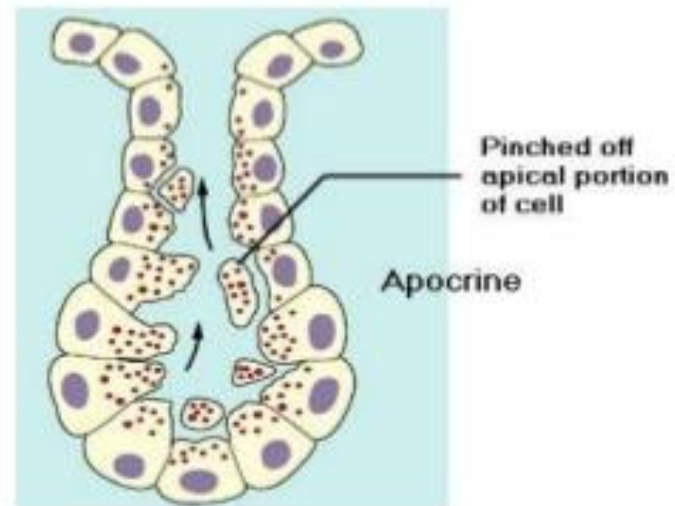
Eccrine sweat gland

- Merocrine secretion
- Empty directly onto skin surface
- Location: most all over body (esp. abundant on palms & soles: ~ 500/cm²)
- Clear, watery secretion (99% H₂O; rest NaCl + some waste products)

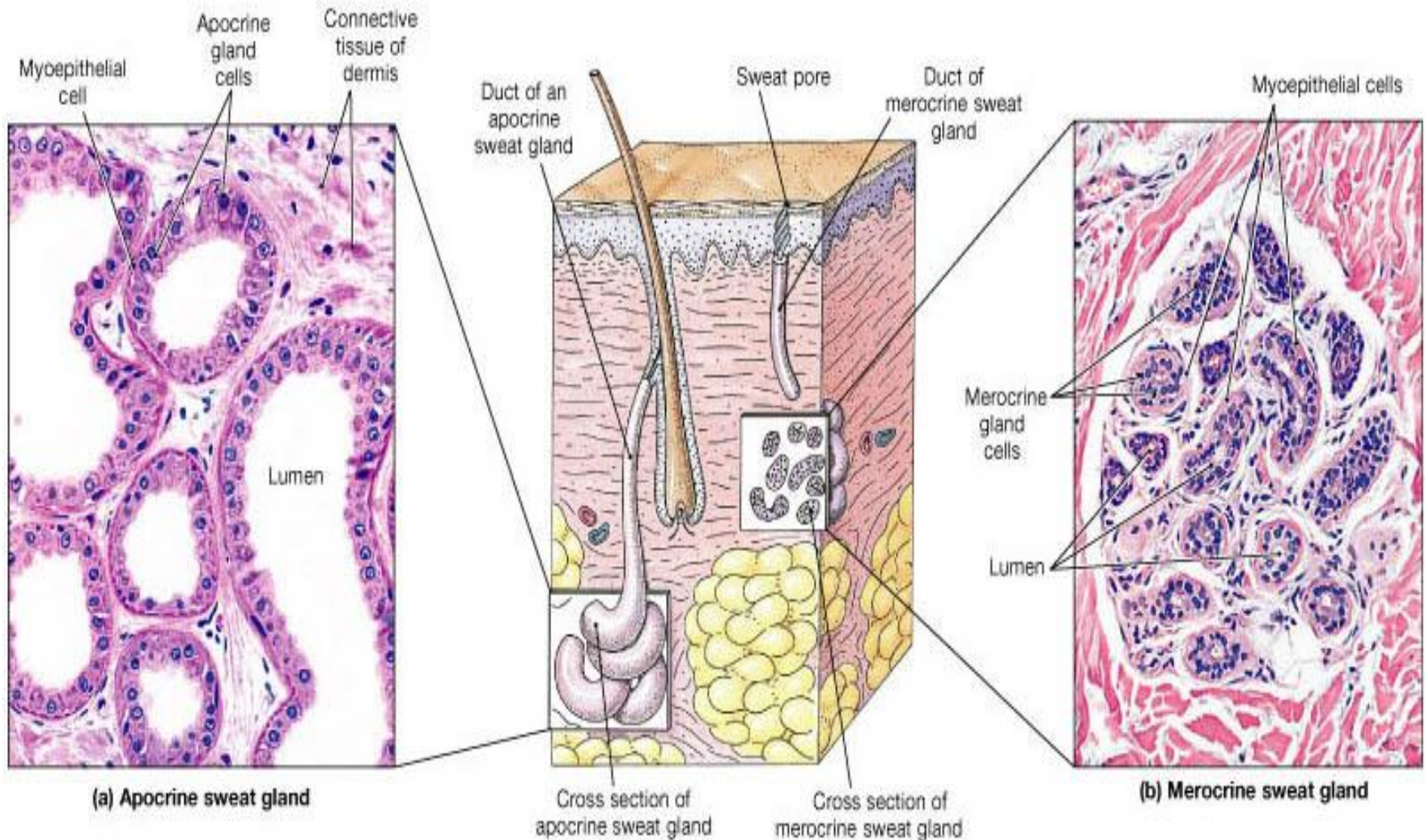


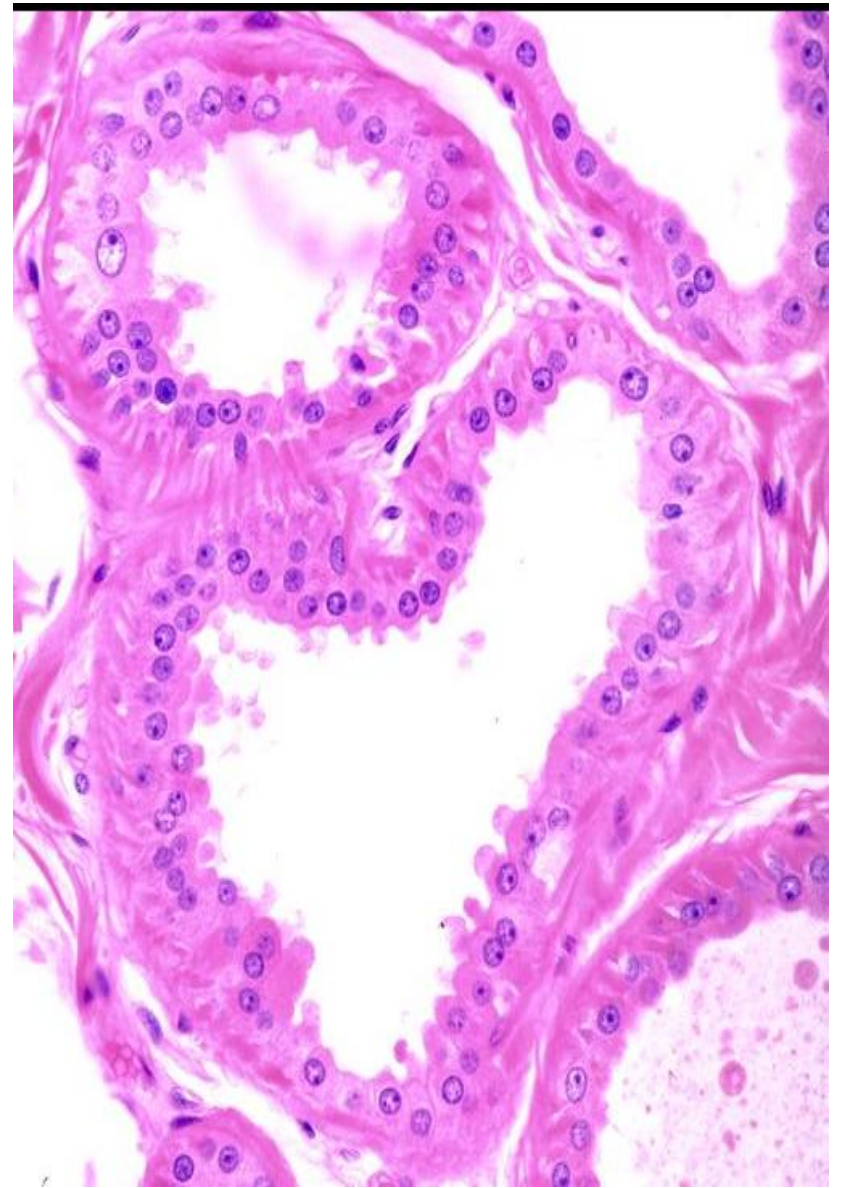
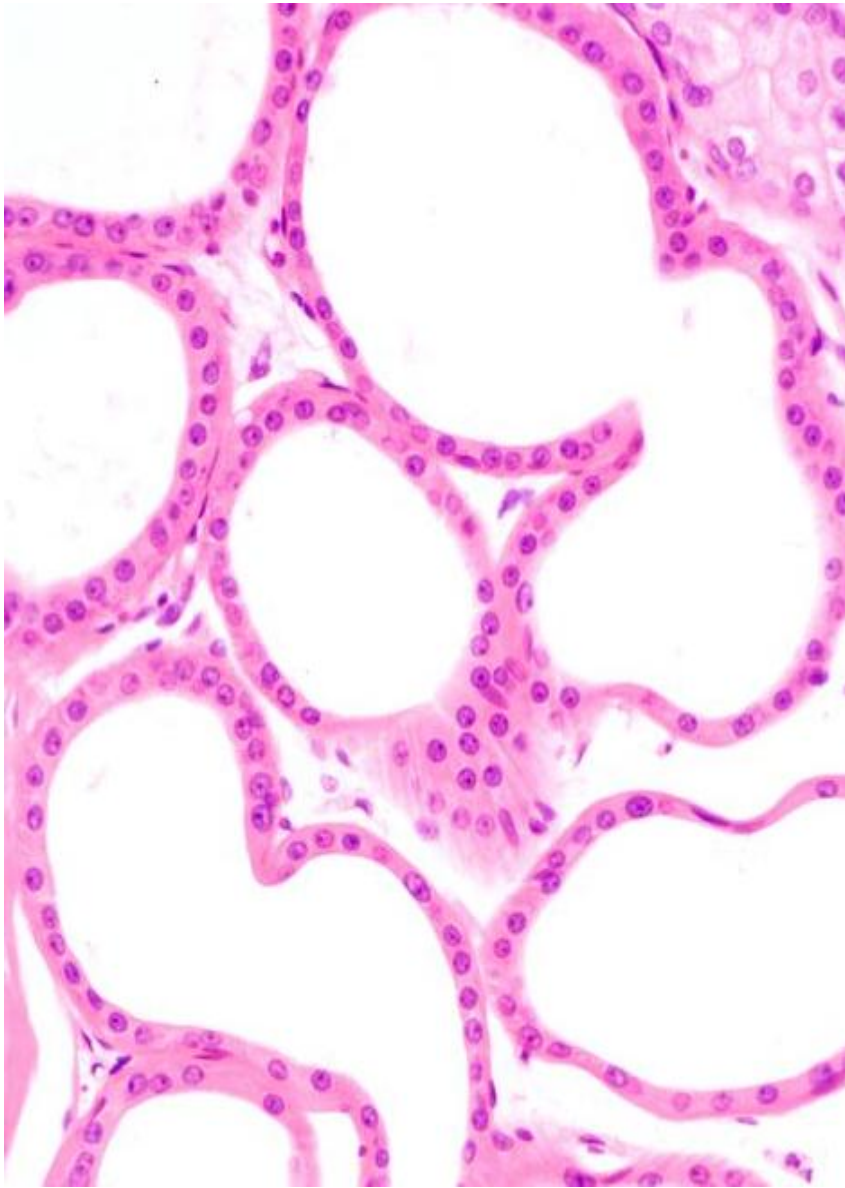
Apocrine sweat gland

- Empty into hair follicle
- Location: armpits, groin, nipples
- Viscous, cloudy secretion → good nutrient source for bacteria (odor !!)
- Secretion may contain Pheromones
- Secretion begins at puberty and is stimulated during emotional distress



Sweat glands



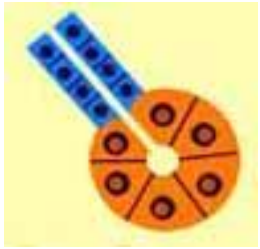


Apocrine sweat glands

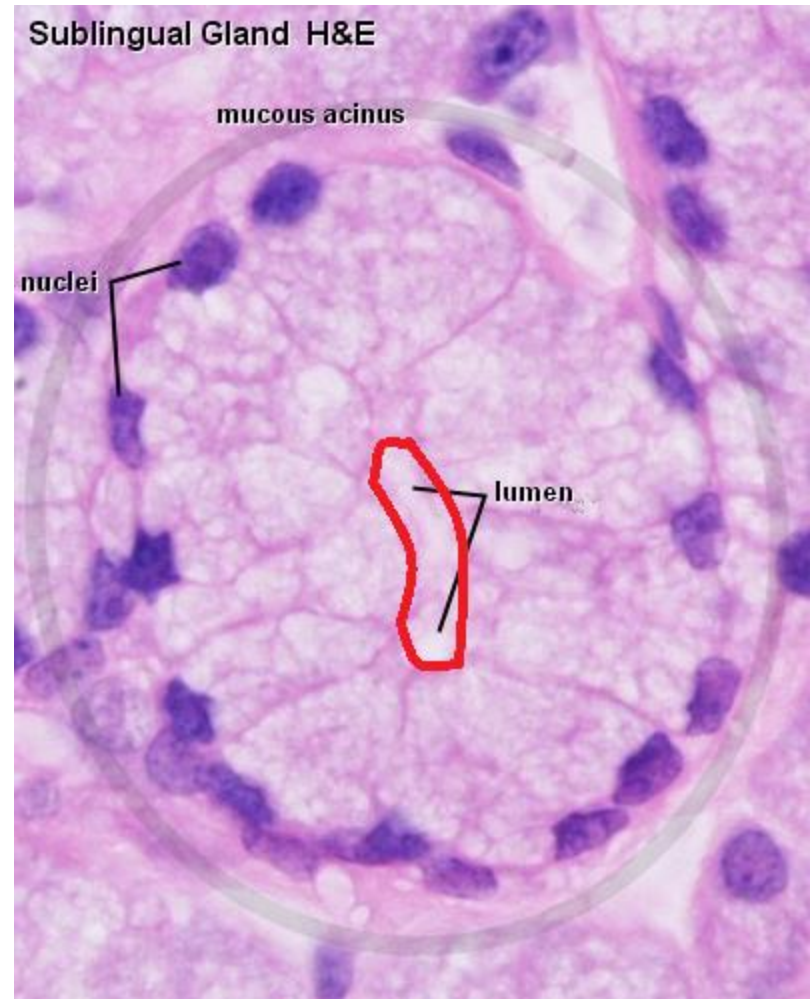
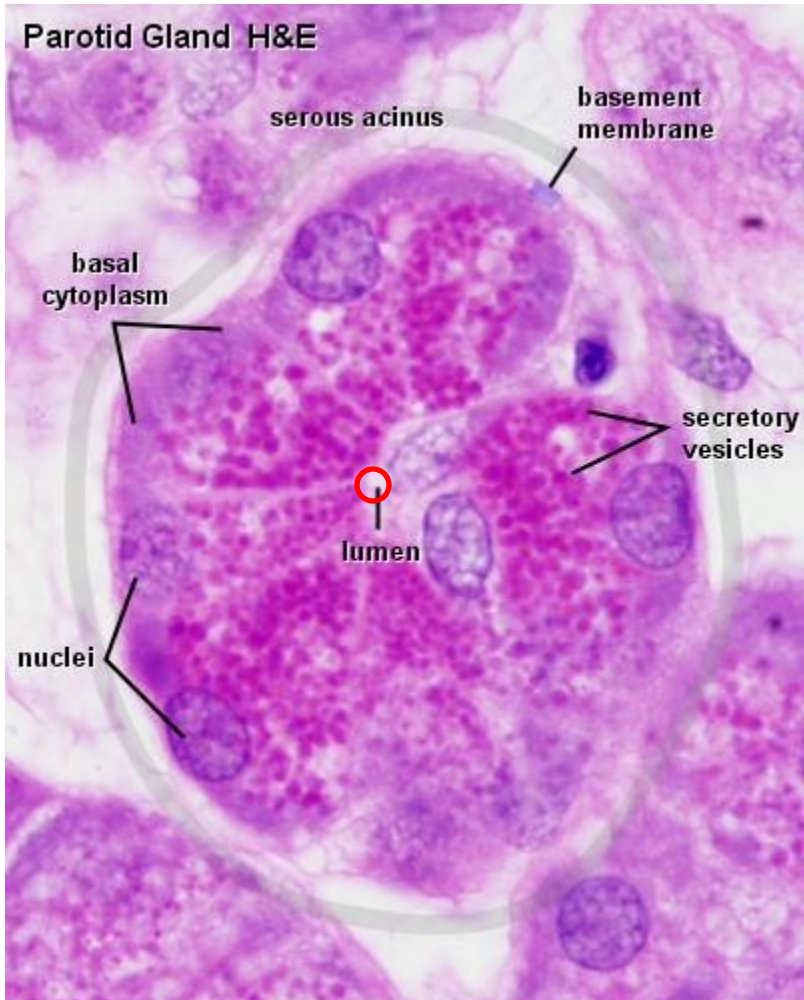
Classification on the basis of nature of secretory product

Classification on the basis of nature of secretory product

1. **Mucous glands:** these glands produce a viscid, slimy, carbohydrate-rich secretion which is called mucus,
e.g; goblet cells
2. **Serous glands:** these glands produce a thin, watery, protein-rich secretions, often high in enzymatic activity e.g; Exocrine pancreas, the parotid salivary gland.
3. **Mixed glands:** these glands produce both mucous and serous secretions e.g; the sublingual and submandibular salivary glands.



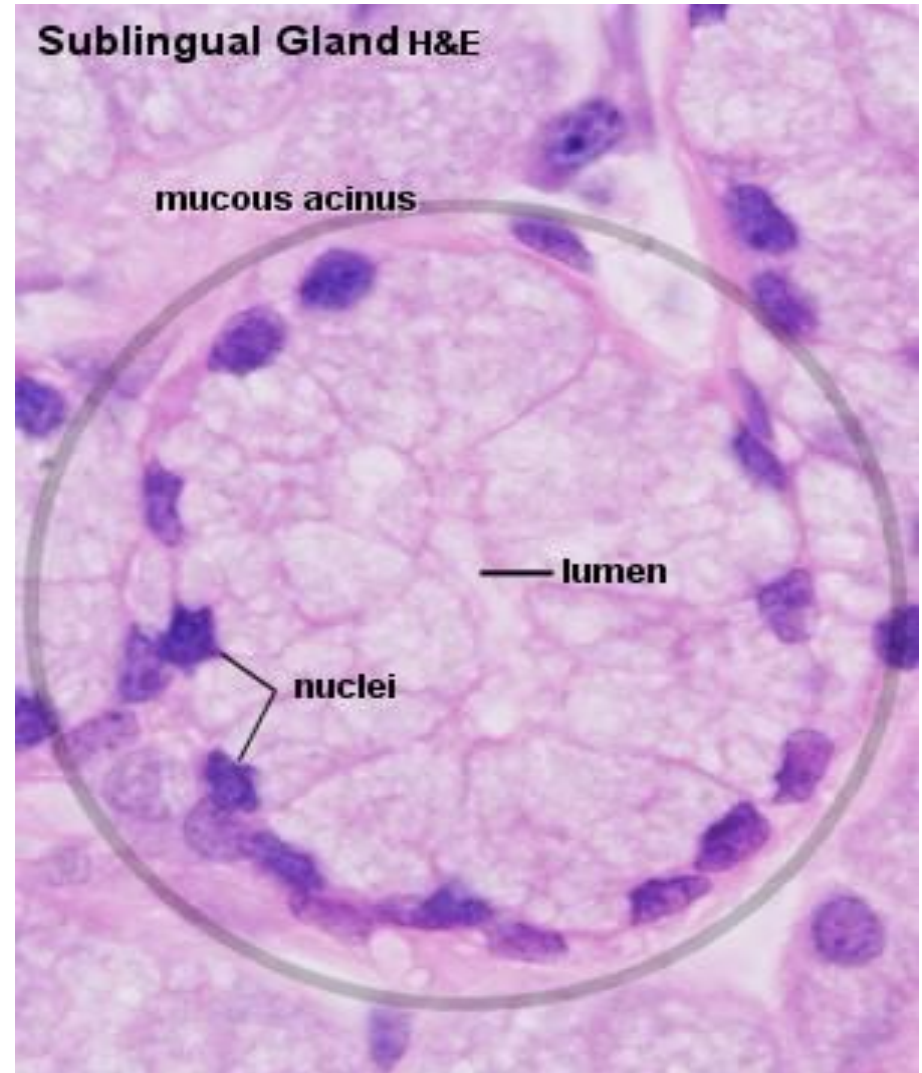
Serous cell Vs Mucous cell



Mucous cells are larger than serous cells, with flattened basal nuclei.

Most of the cytoplasm is filled with secretory granules containing mucinogen like that of goblet cells

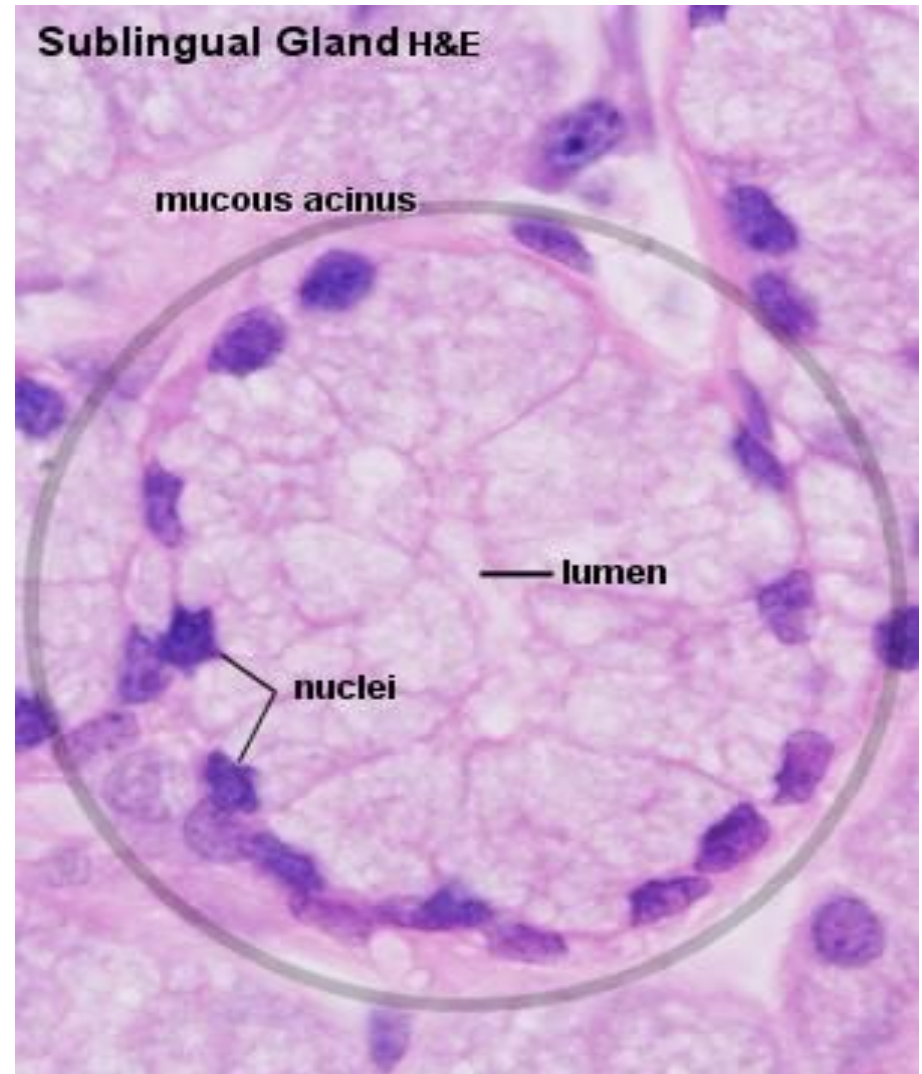
Distinguished by "empty"-appearing (i.e., poorly stained) apical cytoplasm



Mucous tubules

The lumens of **mucous tubules** are larger than those of serous acini.

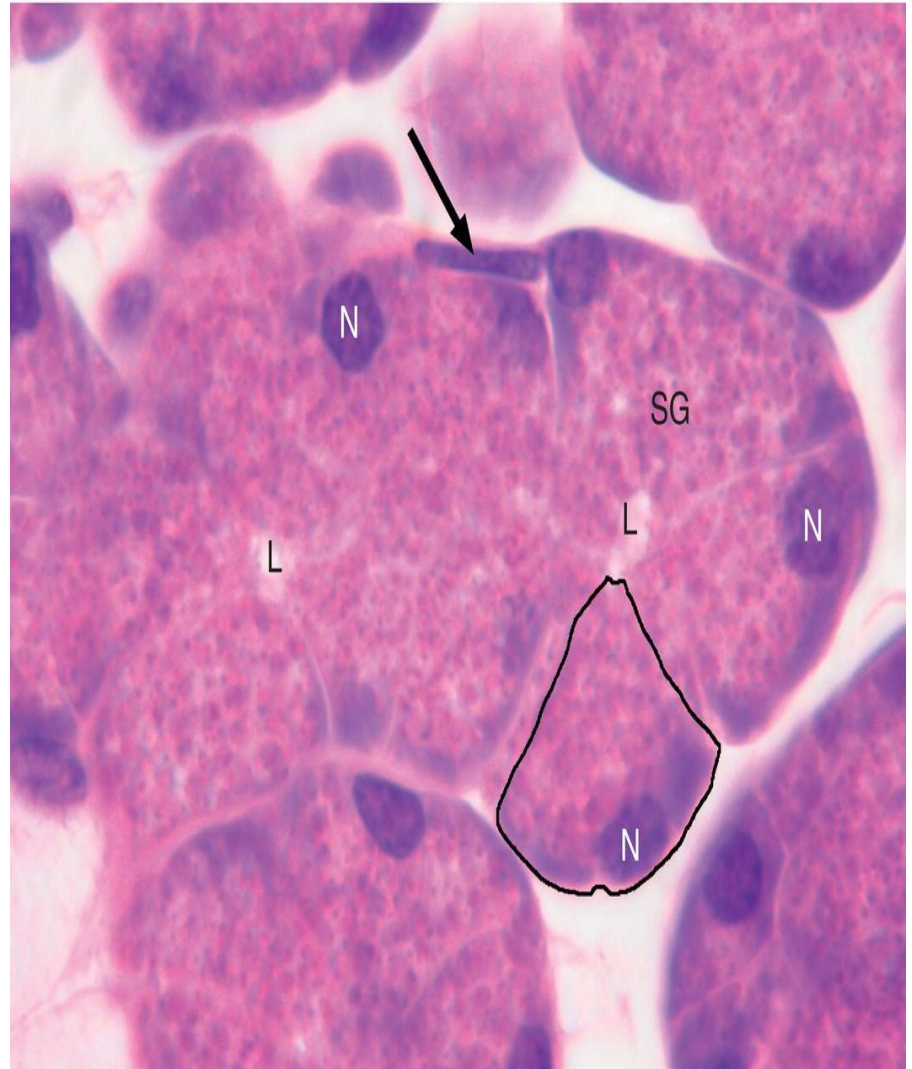
Much **connective tissue** surrounds the mucous tubules and ducts.



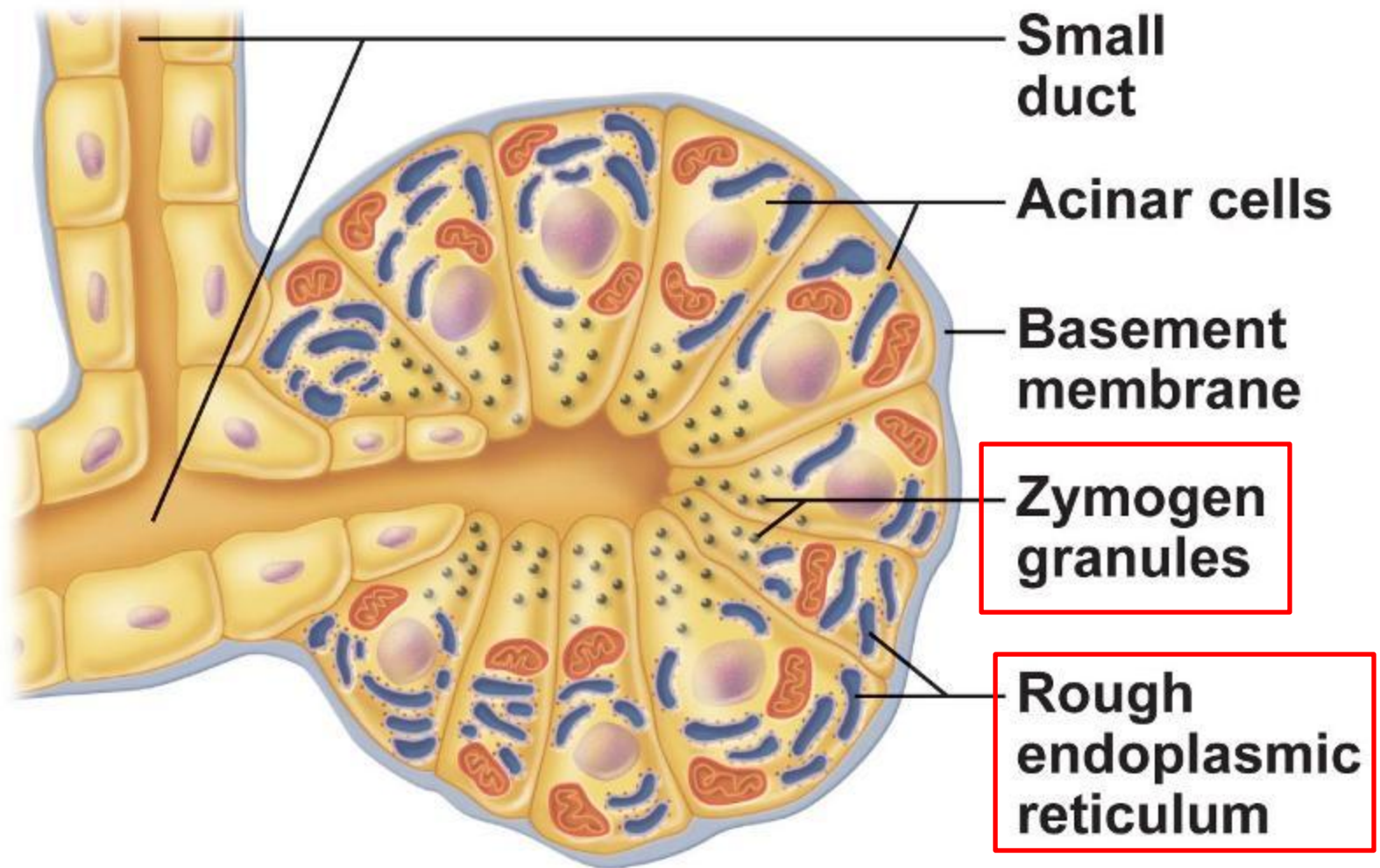
Mucous tubules

The acinar cells distinguished by basophilic basal cytoplasm and mostly eosinophilic secretory granules concentrated in apical cytoplasm

The **lumen** of an acinus is typically tiny

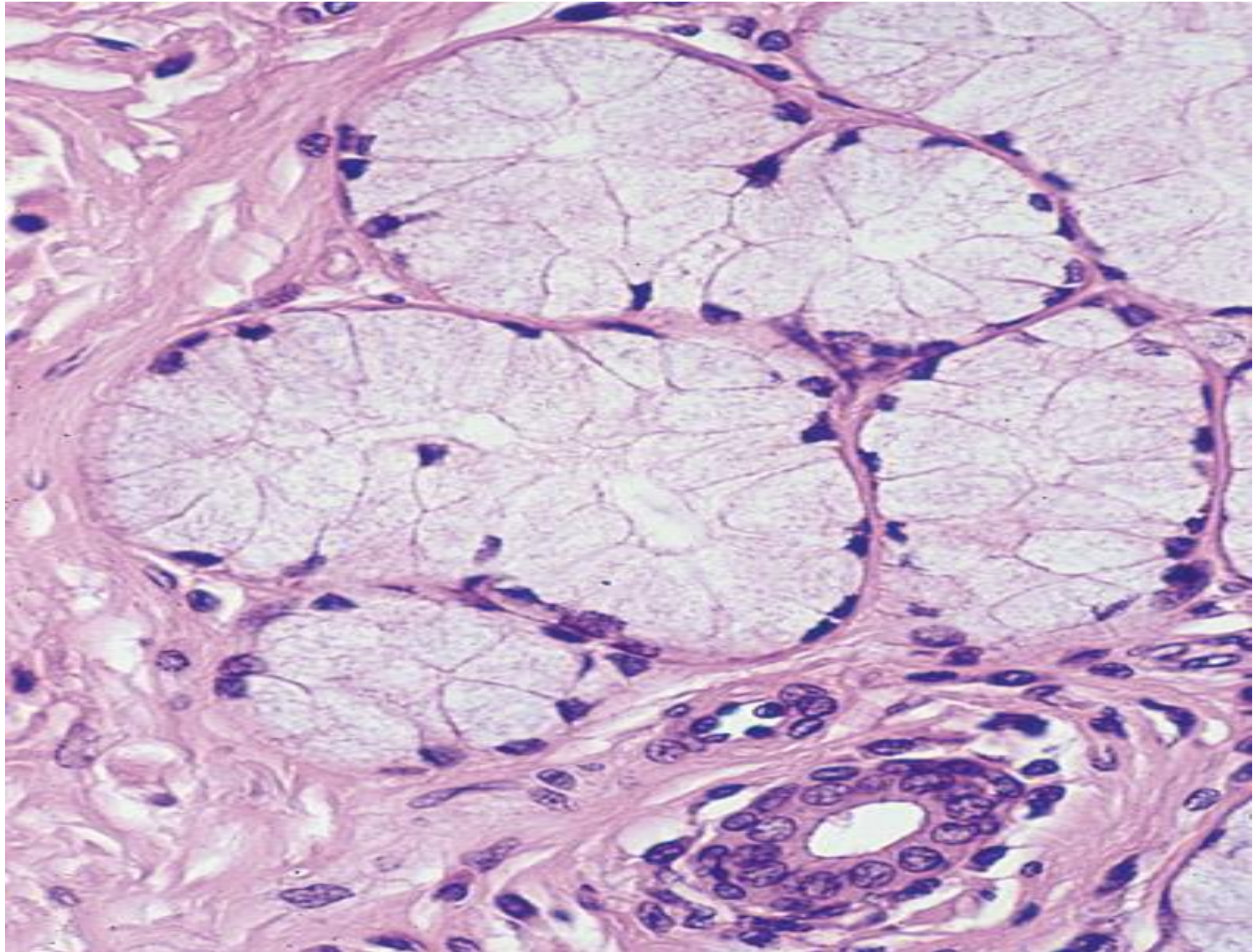


Serous acini

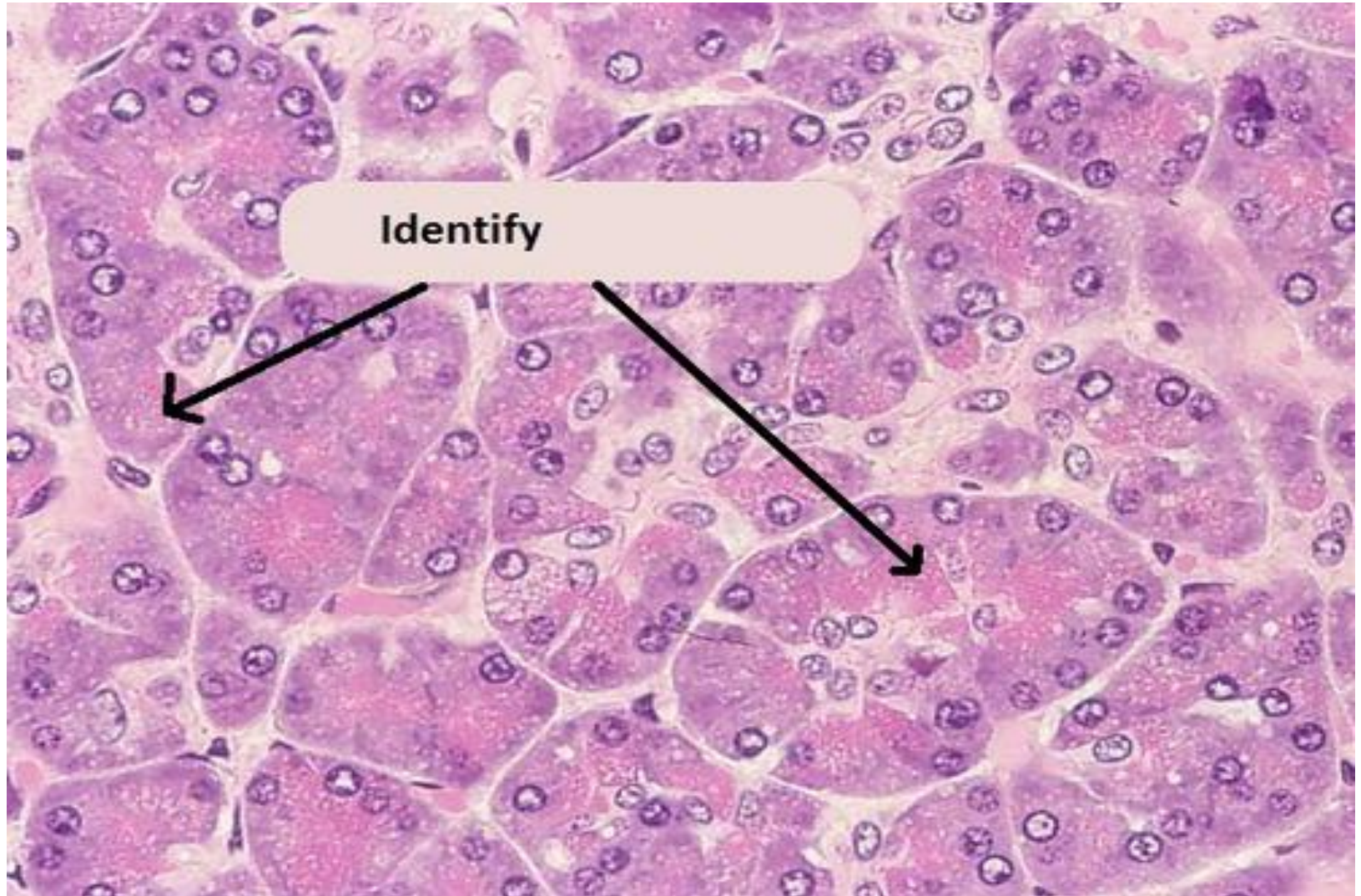


(a)

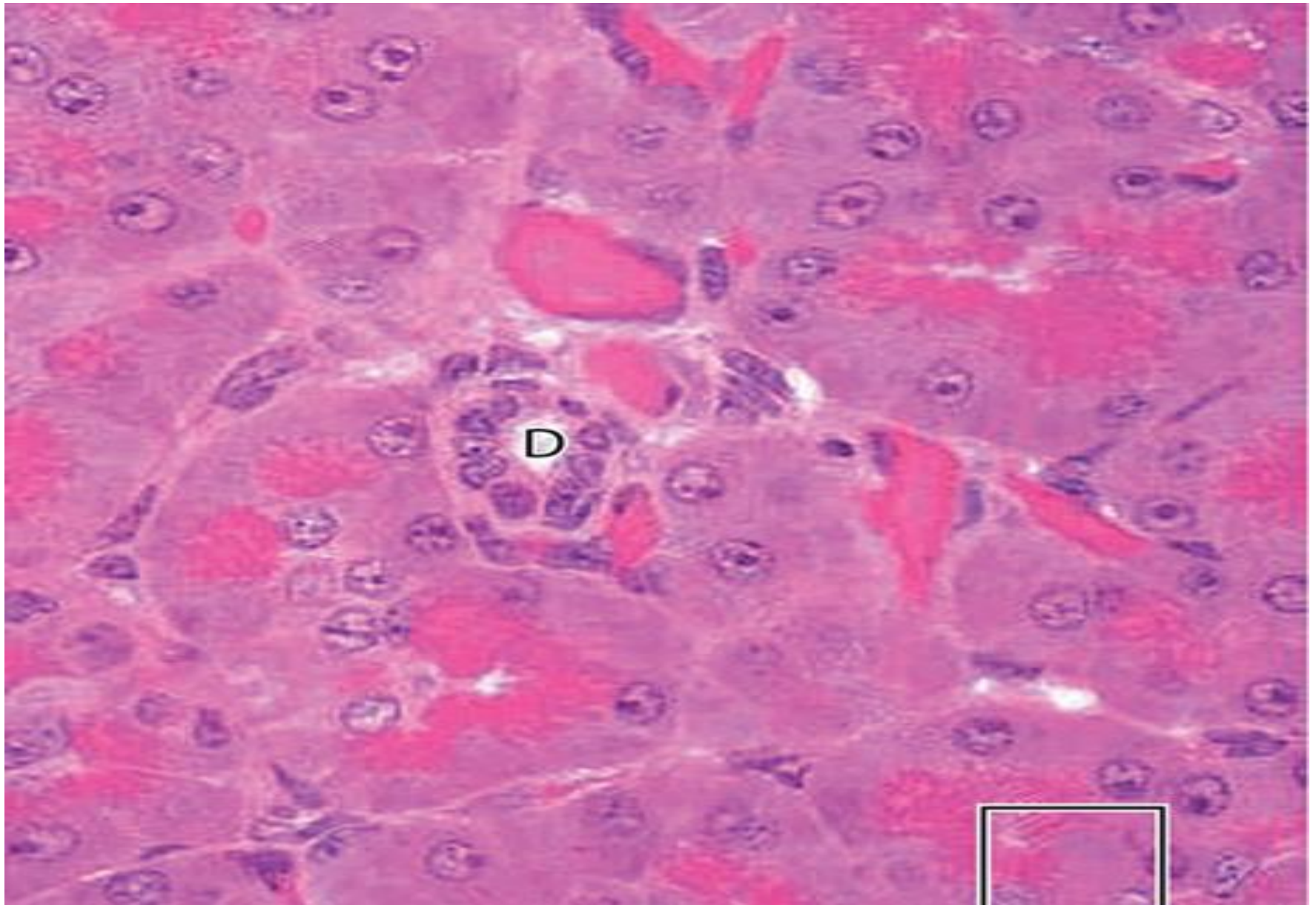
Mucous cells

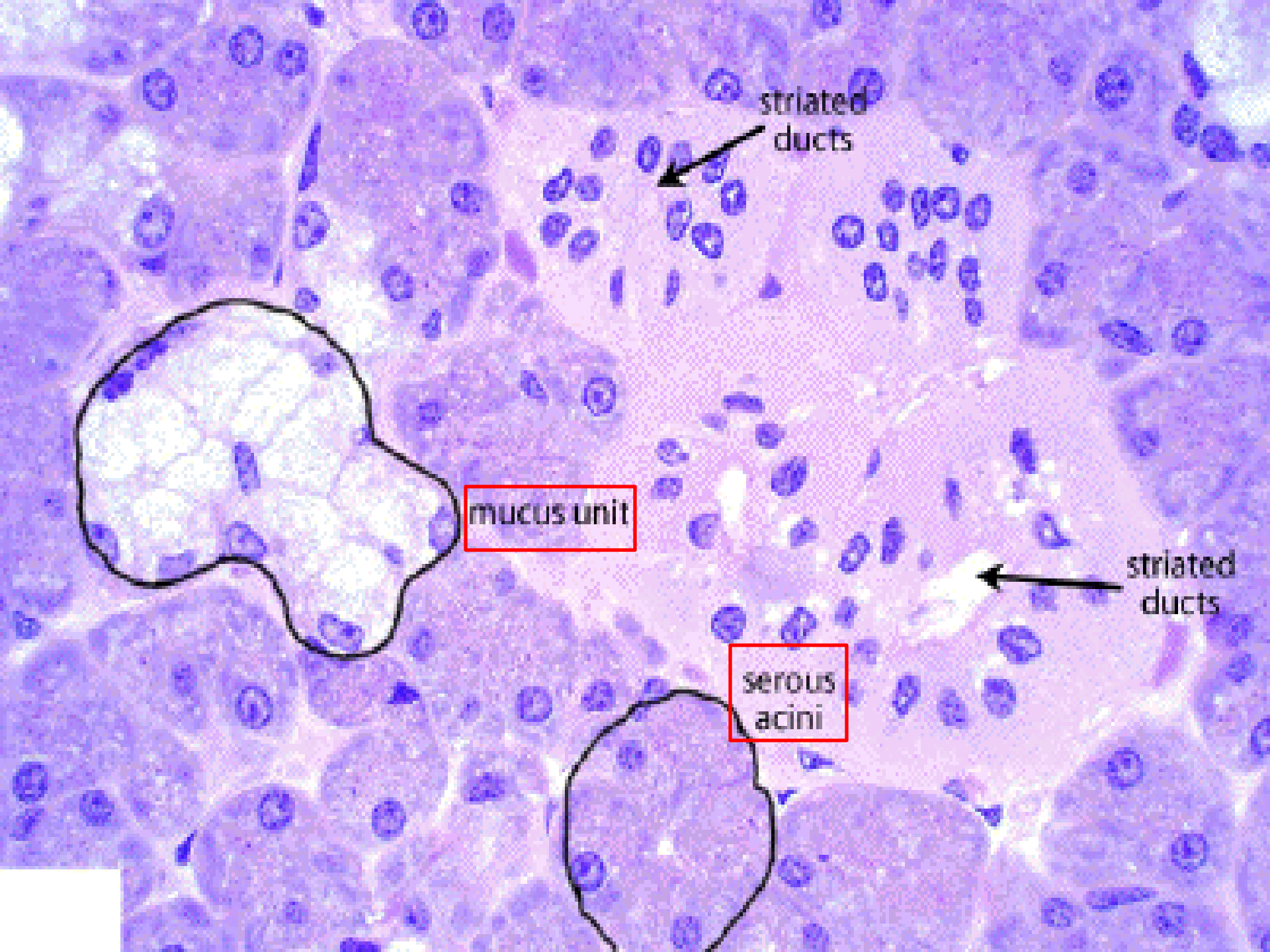


Serous cells



Serous or mucous cells????





striated
ducts

mucus unit

striated
ducts

serous
acini