HEMATOLOGY
&LYMPH SYSTEM

Pathology sheet

Number	8
Done BY	Abdullah Nimer
Correction	Dr. Ahmad Mansour
Doctor	Dr. Ahmad Mansour

Plasma cell myeloma (multiple myeloma)

• Common **lymphoid** neoplasm, present at old age (70 years average)

Remember: plasma cells are terminally differentiated B-lymphocytes that produces antibodies.

B-cells are formed in the bone marrow, then they different into one of two:

1- **Memory B-cells** in the marginal zone of the lymph node
2- **Plasma cells** that secrete anti-bodies

If there is a neoplasm with plasma cell differentiation it is called **plasma cell myeloma.**

*Why didn't we call it lymphoma or leukaemia?

Because it is **neither** lymphoma **nor** leukaemia.

-Leukaemia: neoplastic cells in the peripheral blood, Lymphoma happens in the lymph nodes. Plasma cell myeloma does not happen in peripheral blood or lymph nodes, **it happens in the bone marrow.**

*Note: if the neoplastic plasma cells are present in the peripheral blood with a percentage higher than %20 we don't call it plasma cell myeloma, we call it plasma cell leukaemia, which is a different disease (very aggressive and bad tumour and exceptionally rare).

• It is usually confined to bone and bone marrow and does not involve the peripheral blood. However, we can detect clonality by simple serum test **Electrophoresis**.

– Associated with **M proteins**.

– Associated with **lytic bone lesions**.

Electrophoresis: We place the serum proteins between two poles (positive and negative) which causes serum proteins to move and separate from each other until they stop at some point, according to their **size** and **charge**.

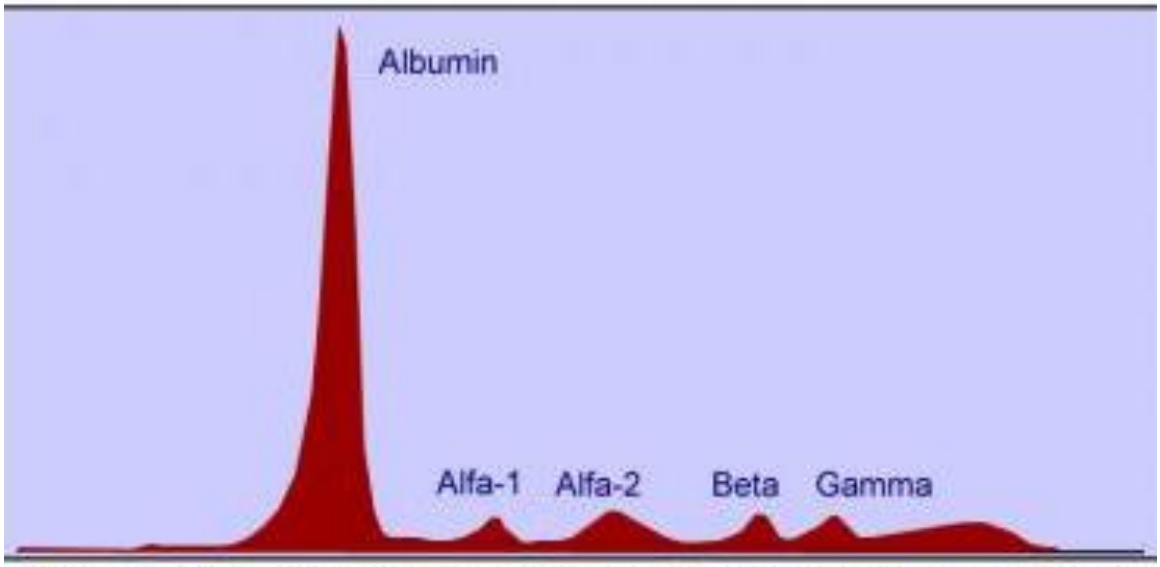

Normal serum protein electrophoresis diagram with legend of different zones

note in the figure above that the gamma region has low altitude and has wide base because it is composed of different classes of antibodies with different arrangements and different origins (polyclonal)

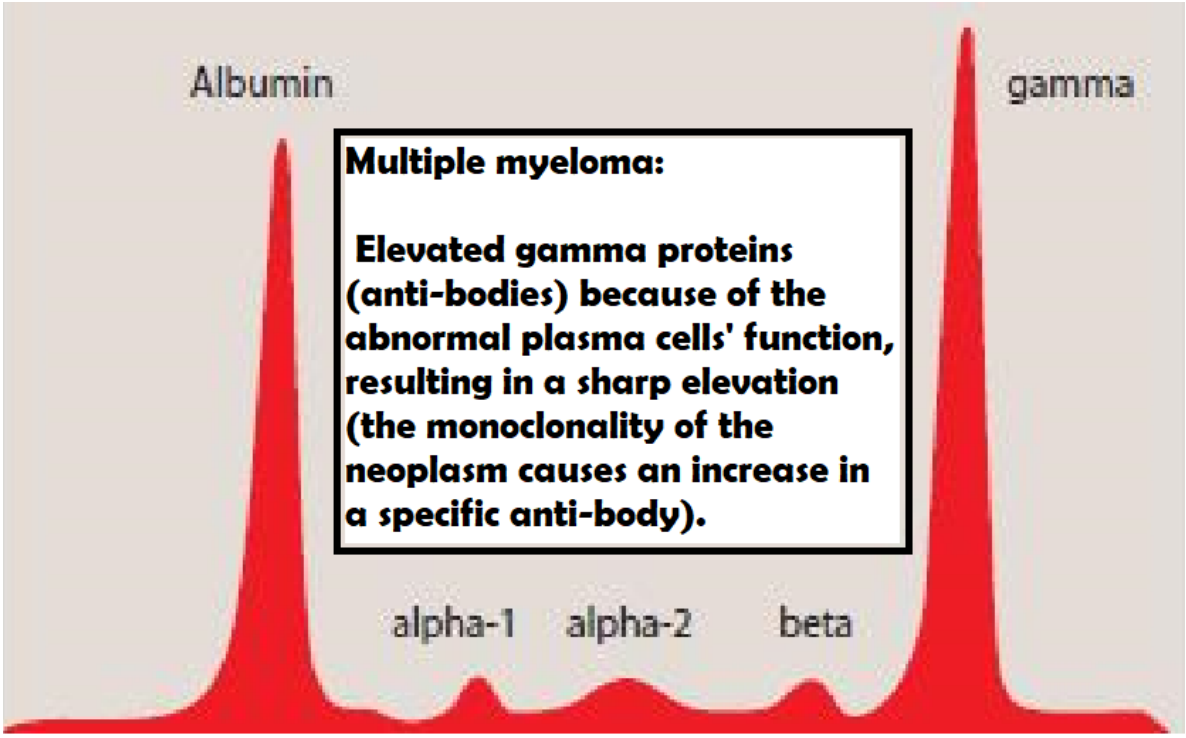

in constrast to the previous figure, this figure shows a sharp peak composed of one class of antibody (monoclonal) it shows higher-than-normal amount of antibody and at the same it is sharply peaked and narrow indicating clonality polyclonal=benign

monoclonal=malignant

The most common M proteins are **IgG, IgA and light chains** (with no association with heavy chains)

– Rarely others.

– Light chains (Lambda or kappa) are **secreted in urine** (unlike IgG and IgA which are not filtered through the kidney and can be seen only in plasma)

• **Bence Jones protein**: are simply light chains of anti-bodies in the urine of a multiple myeloma patient.

Pathogenesis

• **B cell neoplasm of terminally differentiated B lymphocyte (plasma cell).**

– Several translocation involving **IgH, cyclin D1 and D3 as well as *MYC*.**

– Cyclin D1 is not specific for mantle cell lymphoma as it can be seen in plasma cell myeloma.

It affects		
The bone	The immune system	The kidneys
• Releases factors such as RANKL that increase osteoclastic activity. **• Other factors that decrease osteoblastic activity.** **• Net result is:** **– Lytic lesions** **– Pathologic fractures (sometimes called secondary fractures)** **– Hypercalcemia (due to the resorption of bones)**	• Functional antibodies are markedly decreased (it is true that antibodies are increased in general, but most of them are inactive). – Increase risk of bacterial infections (The most common cause of death in multiple myeloma patients).	• Obstructive casts composed of Bence jones proteins (light chains) in the distal tubules. • Deposition of light chain in the glomeruli causing: – Light chain disease. – Amyloidosis. • Hypercalcemia resulting in renal stones. • Bacterial pyelonephritis

Morphology:

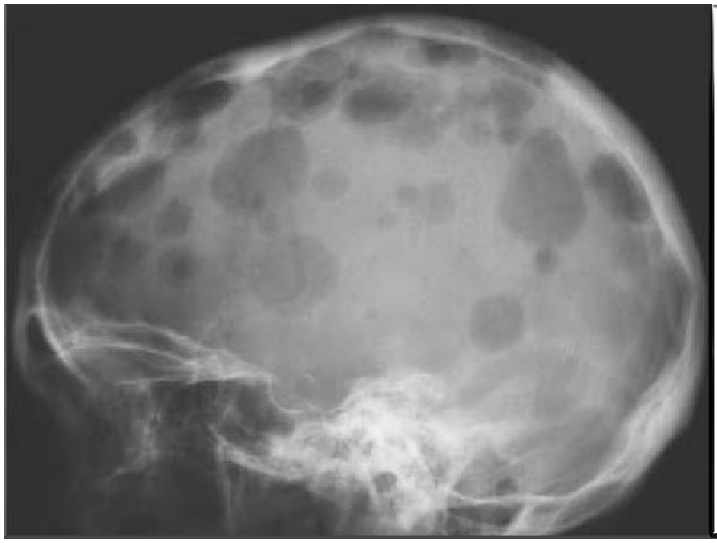

Lytic lesions:

most common in cenral axial bones such as the skull and the vertebra (still it can happen anywhere).
caused by increase osteoclasic activity and decreased osteoplastic activity (increased RANKL activity).

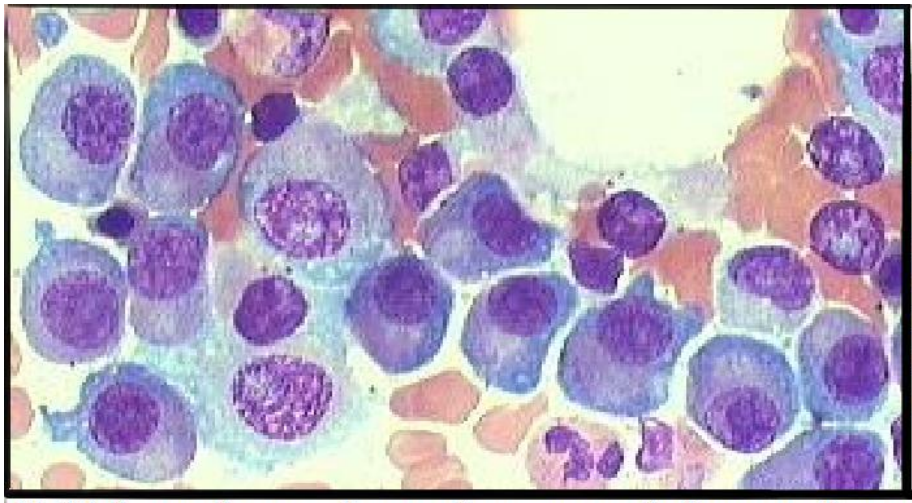

Plasma cells: have abundant basophilic cytoplasm, prominent perineuclear hof, round eccentric nucleus with coarse chromatin (clock-face)

Multiple myeloma cells may have normal plasma cell appearance and may have an abnormal appearance (binucleation, large size and vacules - which might be cytoplasmic or nuclear)

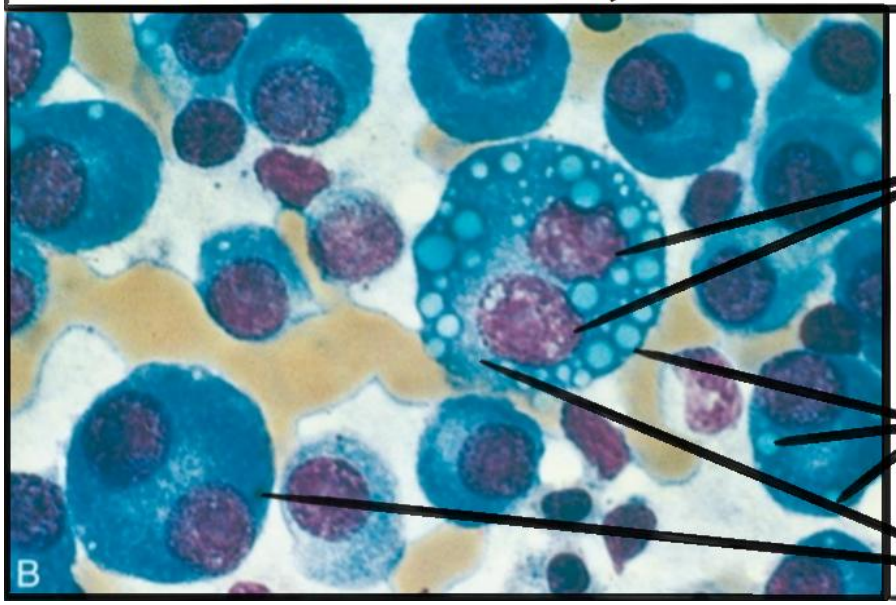

Binucleation

Vacules

Large size

-What does these vacuoles contain?

Anti-bodies.

Clinical manifestations:

• **Bone pain** and **pathologic fractures**.

• **Hypercalcemia**: neurological manifestations – Confusion, lethargy and weakness.

• **Recurrent bacterial infections – The most common of death.**

• **Renal dysfunction (at least %50 of the patients) – Second most common cause of death.**

Lab findings:

• M protein, but:

-1% are **non-secretors** (they don't secret anti-bodies), they present with the same clinical manifestations but their electrophoresis will be **negative**.

• Elevated **creatinine or urea** (because of the renal dysfunction).

• Elevated **calcium levels.**

• Anemia, **thrombocytopenia** and **leukopenia** (if a large portion of the bone marrow is involved)

► Median survival time for multiple myeloma is 4-7 years.

► No cure (yet).

Hodgkin lymphoma (very important):

• One of the **most common diseases**, present at young age and it is curable.

• Different from other B cell lymphoma

– it has characteristic cells called: **Reed-Sternberg cells (RS cells).**

– can present in **single lymph node** or a **group of contiguous lymph node.**

• **B cell origin**

Two major subtypes

• **Classic HL (4 classes):**

– Nodular sclerosis

– Mixed cellularity

– Lymphocyte-rich (very rare)

– Lymphocyte-depleted (very rare)

• **Nodular lymphocyte predominant HL (NLP HL)**

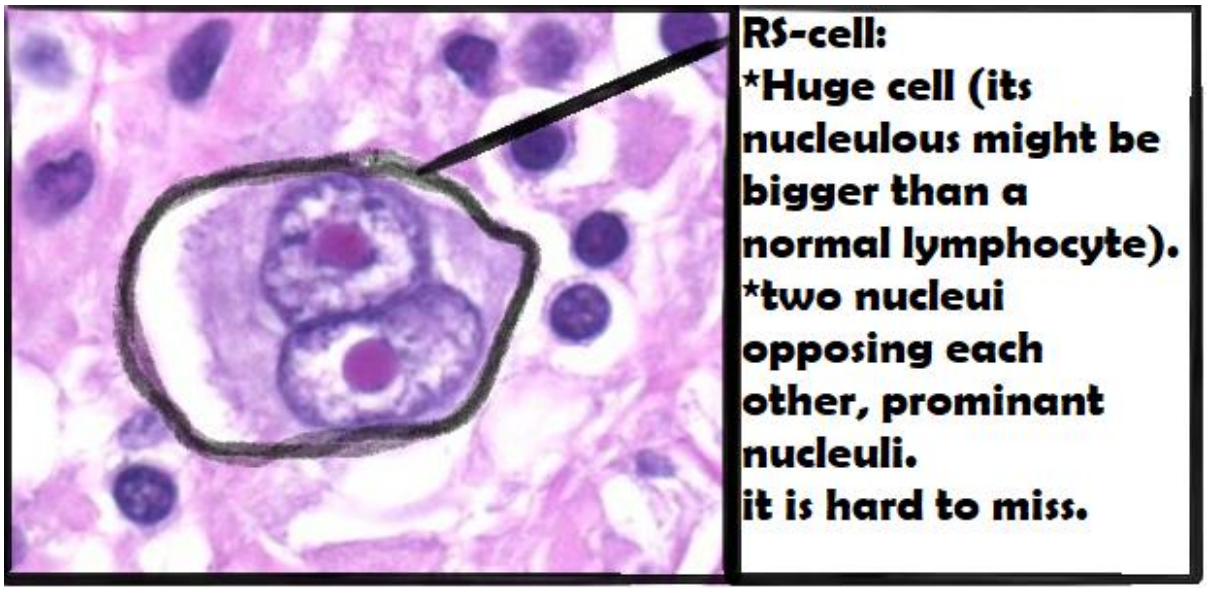

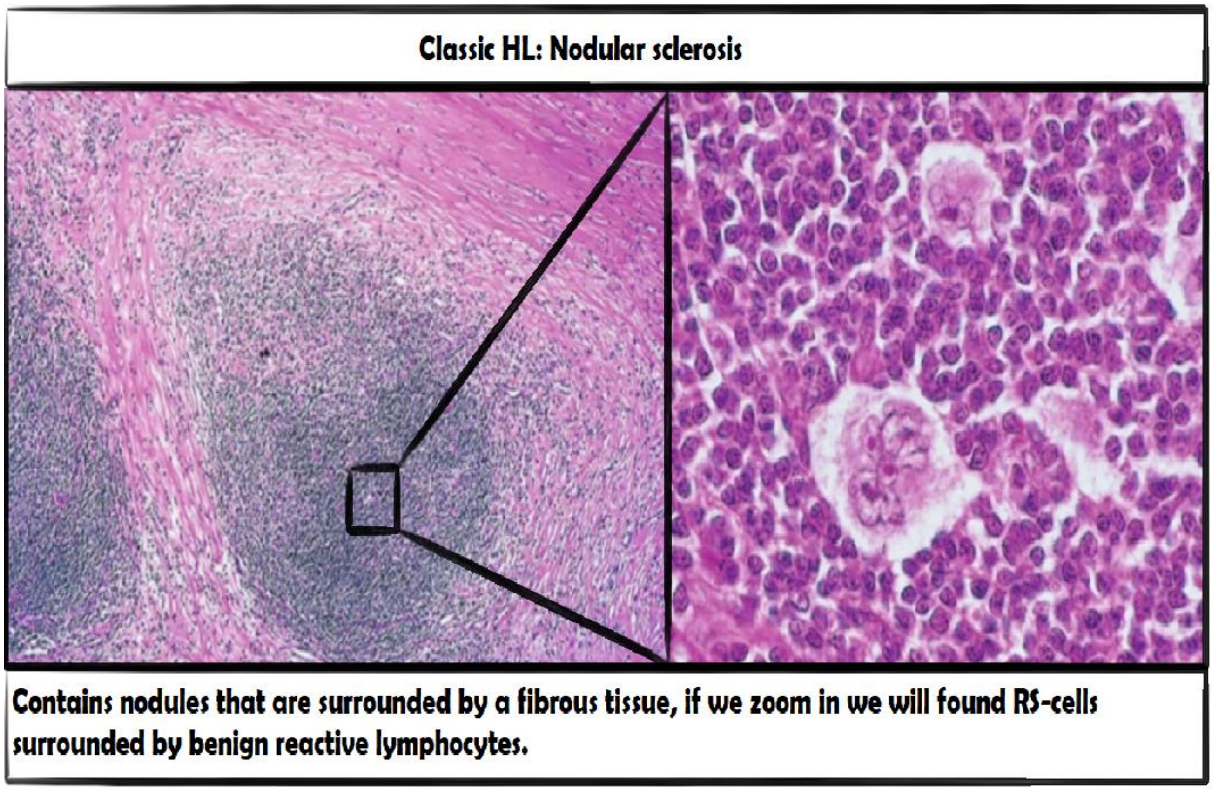

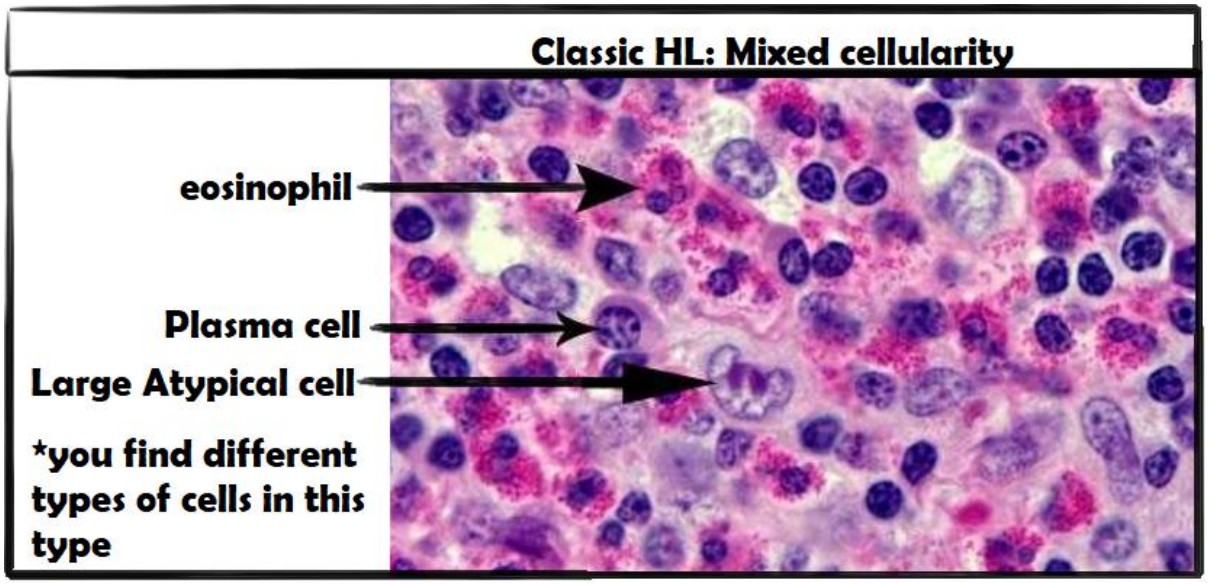

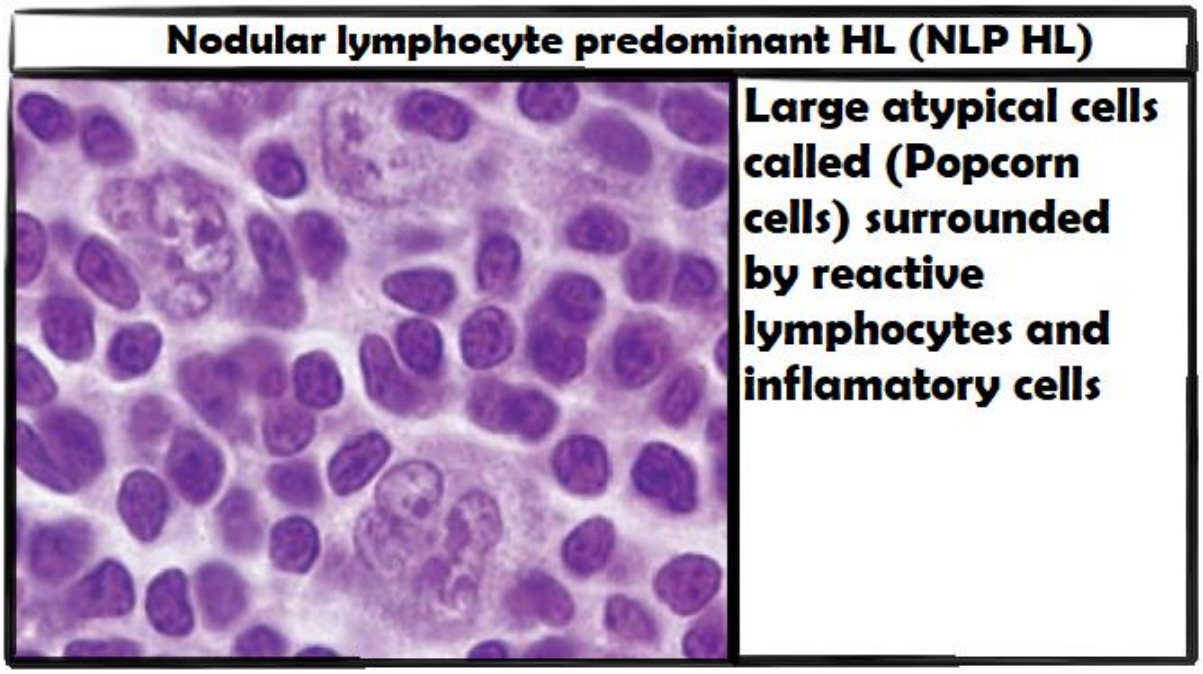

Immunophenotype	
Classic HL	**NLP HL**
– CD30+, CD15+. **– pax5 weakly positive, negative for other B cell markers** **– Negative for T cell markers** **– Negative for CD34**	**–Negative for CD30** **–Negative for CD15** **–Positive for B cell markers** **–Negative for T cell markers** **–Negative for CD34**

*Question: what marker is not helpful in the differentiation between the two types?

Answer: **pax5**

Remember that:

• The vast majority of cells in a lymph node with HL are **benign**.

• **RS cells secrete**:

– **IL5** recruiting eosinophils (not typically found in the lymph nodes, when you find them search for RS-cells to confirm HL).

– **IL13** to promote their own growth.

– **TGF-B** resulting in fibrosis.

– **PDL1 and PDL2** to inhibit T cell function.

• They are **neoplastic B cells**.

Clinical manifestations:

• Presents at young age – still could affect any age

• Single lymph node or a region of lymph nodes – Cervical and mediastinal are the most common.

• Rarely involves tonsils, Waldeyer ring or extra-nodal sites.

• Spreads in a contiguous manner.

Hodgkin Lymphoma	Non-Hodgkin Lymphoma
More often localized to a single axial group of nodes (cervical, mediastinal, paraaortic)	More frequent involvement of multiple peripheral nodes
Orderly spread by contiguity	Noncontiguous spread
Mesenteric nodes and Waldeyer ring rarely involved	Mesenteric nodes and Waldeyer ring commonly involved
Extranodal involvement uncommon	Extranodal involvement common

Staging of HL:

Stage	Distribution of Disease	Five-year survival
I	Involvement of a single lymph node region (I) or involvement of a single extralymphatic organ or tissue (I_E)	**More than %90 (Most cases are stage I and II)**
II	Involvement of two or more lymph node regions on the same side of the diaphragm alone (II) or with involvement of limited contiguous extralymphatic organs or tissue (II_E)	
III	Involvement of lymph node regions on both sides of the diaphragm (III), which may include the spleen (III_S), limited contiguous extralymphatic organ or site (III_E), or both (III_{ES})	**%50**
IV	Multiple or disseminated foci of involvement of one or more extralymphatic organs or tissues with or without lymphatic involvement	

Mycosis fungoides and Sezary syndrome:

• **MF:** a form of cutaneous **T cell lymphoma** – neoplastic T-lymphocytes which are **CD4 positive and CD8 negative**.

• **Sezary syndrome**: similar to MF with the addition of **generalized exfoliative erythroderma and circulating tumour cells in the blood.**

MF has three stages:

1- **erythrodermic rash**
2- **plaque phase**
3- **Tumour phase**

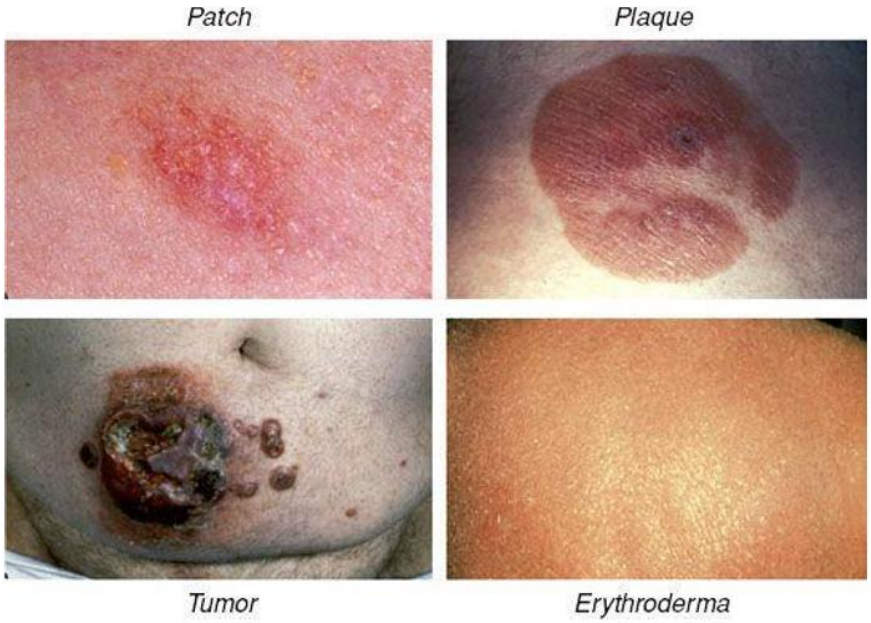

Patch: localized redness/ **Plaque**: can be felt (palpated)/ **Tumor**: causes necrosis/ **Erythroderma:** generalized redness.

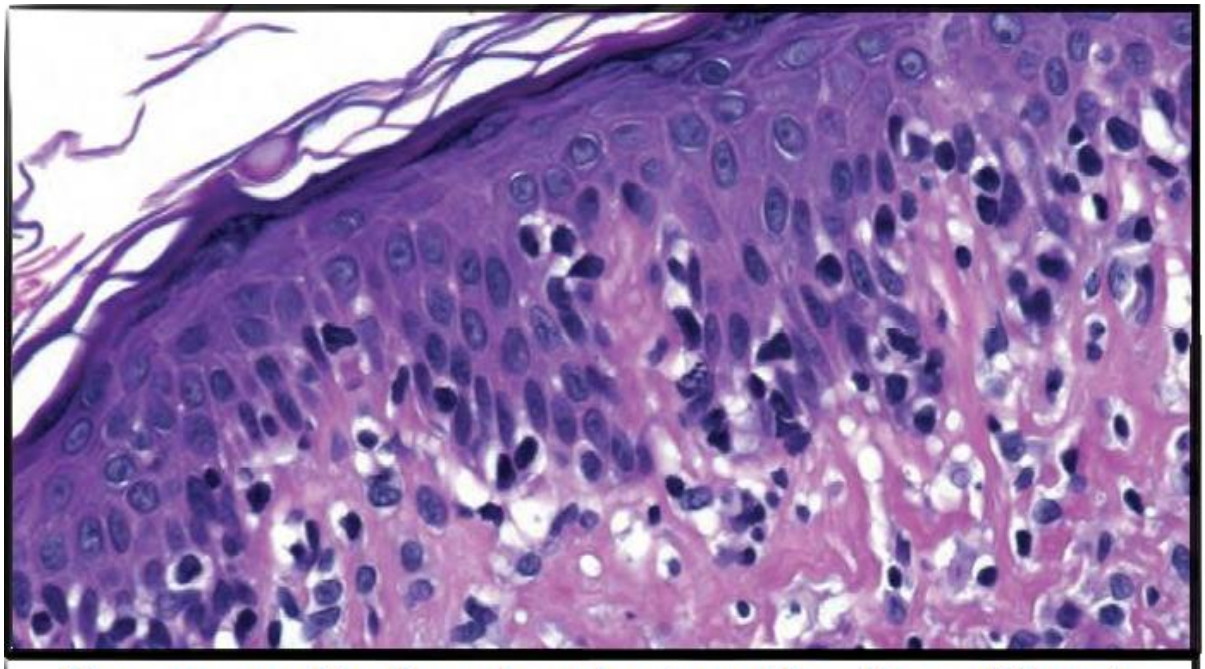

You can see the lymphocytes invading the epidermis which does not happen normally, indicates MF

Prognosis:

• Prolonged survival if still in early stages.

• Tumor stage, visceral involvement or Sezary syndrome have a bad prognosis (1-3 years to live).

Histiocytic neoplasms:

• **Rare**.

• The most important one is **Langerhans cell histiocytosis** (previously known as histiocytosis X)

• **Langerhans cells**: immature dendritic cells in the skin and other organs, present antigens to T cells.

• Affects children less than 2 years of age.

• Involves skin, bone, lungs, spleen, or bone marrow.

• Could be **unifocal or multifocal.**

• Associated with **BRAF** mutation (not specific since it is found in melanoma, hairy cell leukaemia, and thyroid tumours).

Remember that: plasma cell myeloma doesn't occur in young patients, while histiocytosis occurs in very young patients. Both cause lytic lesions especially in the skull.

Morphology:

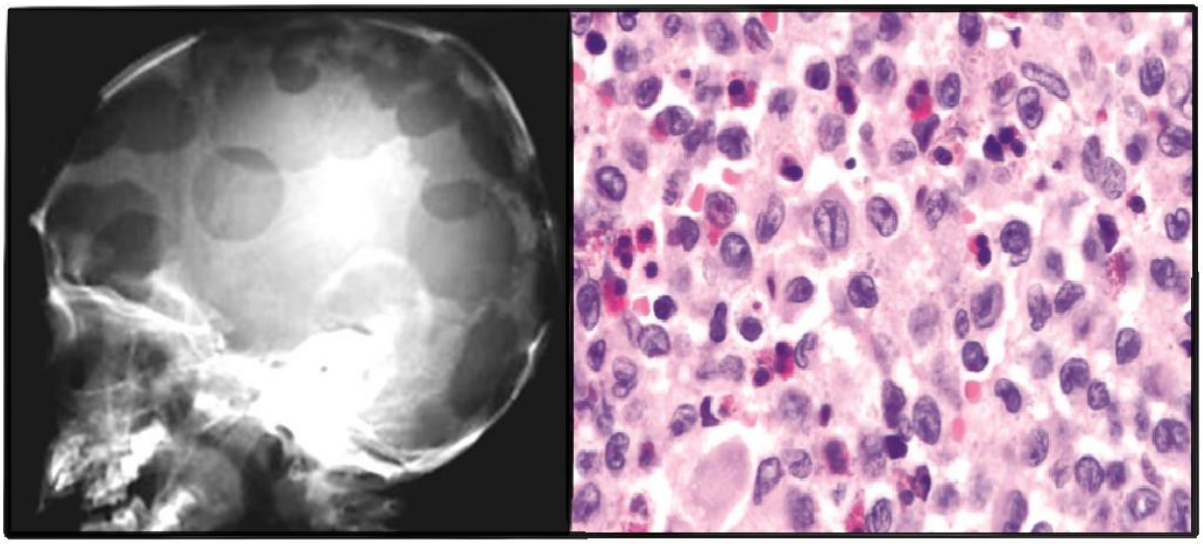

*Lytic lesions.

*sheets of medium sized cells.

*Eosinophils (found in both histiocytosis and HL).

*Langerhans cell histiocytosis cells have the appearance of **a coffee bean**.

Immunophenotype:

• Positive for:

CD68, CD163, langerin and **CD1a**.

*(**CD1a** is the most important one and most specific for Langerhans cell differentiation, you cannot diagnose this disease without CD1a).

Questions:

1) RS cells in classic HL are of

a– T cell origin

b– B cell origin

2) M proteins and Bence jones proteins are composed of

a– Abnormal albumin

b– Clonal Immunoglobulins

c– Abnormal ferritin

d– Abnormal glycoproteins

e– Abnormal ceruloplasmin

3) The most specific marker for Langerhans cell differentiation is:

a– CD68

b– CD163

c– Langerin

d– CD1a

e– CD20

4) One of the following tumors is a T cell neoplasm:

a– Mantle cell lymphoma

b– Langerhans cell histiocytosis

c– Sezary syndrome

d– DLBCL

5) Neoplastic cells in all the following are positive for CD30, except:

a– Nodular cellularity classic HL

b– Mixed cellularity classic HL

c– Lymphocyte-rich classic HL

d– Lymphocyte-depleted classic HL

e– Nodular lymphocyte predominant HL

Answers				
1	**2**	**3**	**4**	**5**
b	**b**	**d**	**c**	**e**