Cell Overview

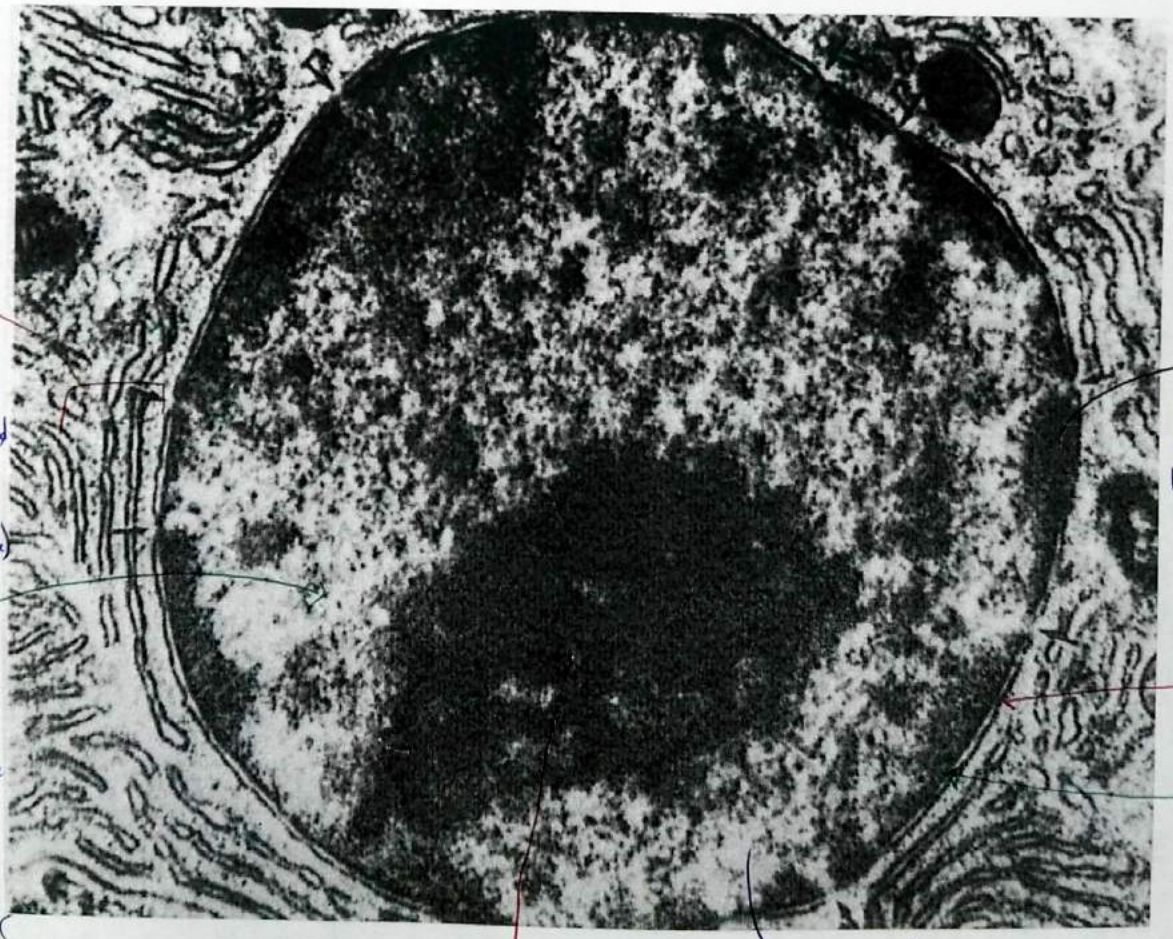

rER (rough endoplasmic riticulum) continuous with nucleus (outer membrane)

nucleo plasm: which is the medium where all the contents of nucleus are embeded (between nucleolus and membrane)

nucleolus: structure at the center of nucleus (prominant nucleolus => active cell) → وجود نوية (nucleolus) يعني أن خلية تصنع ribosomes أي أنها نشطة

electron dense area forms hetrochromatin

outer membran

inner membrane

Less stain area, forms eurochromatin (singal to active cells)

* E.M: ultra-celluler structures of the cell (high magnification)
* LM (microscope): display more than one cell (low magnification)

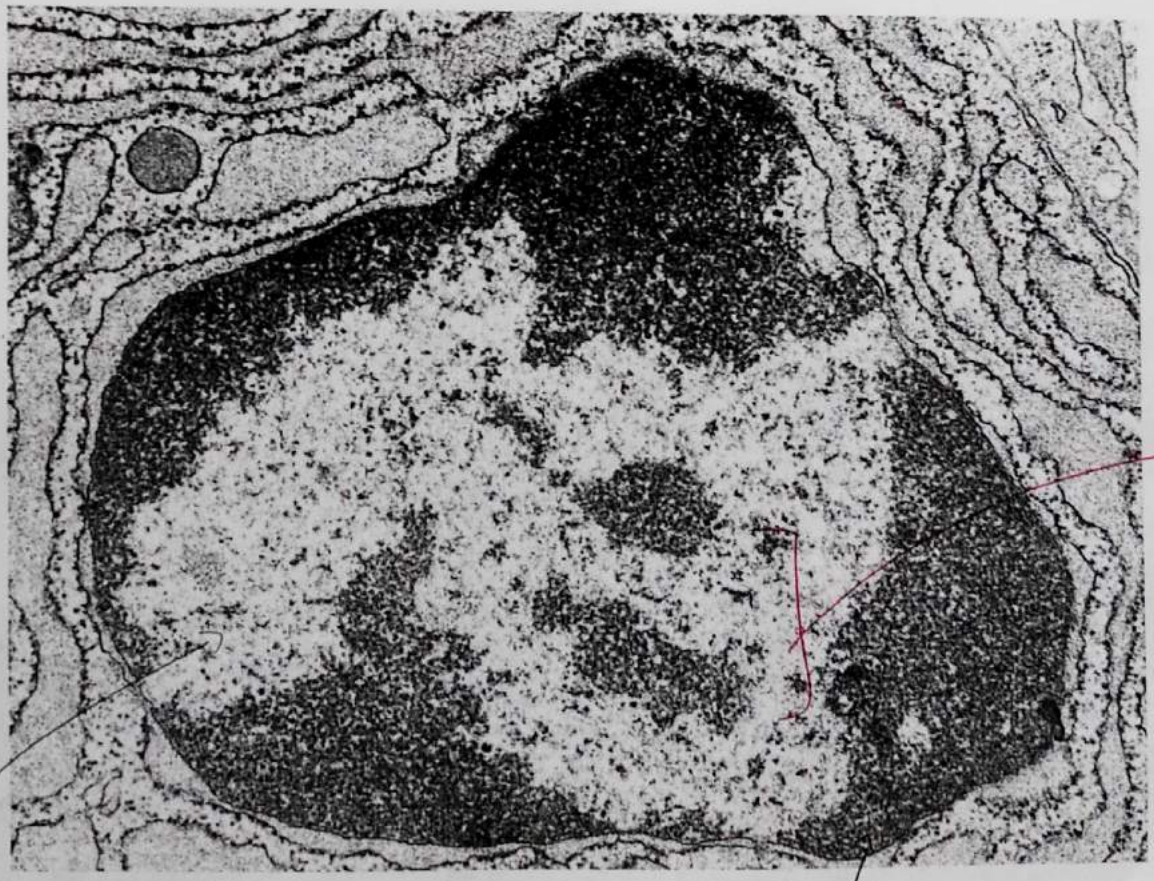

⊗ وجود أكثر من نوية (nucleolus) وكمية كبيرة من euchromatain
دليل على أن الخلية نشطة

Cell membrane

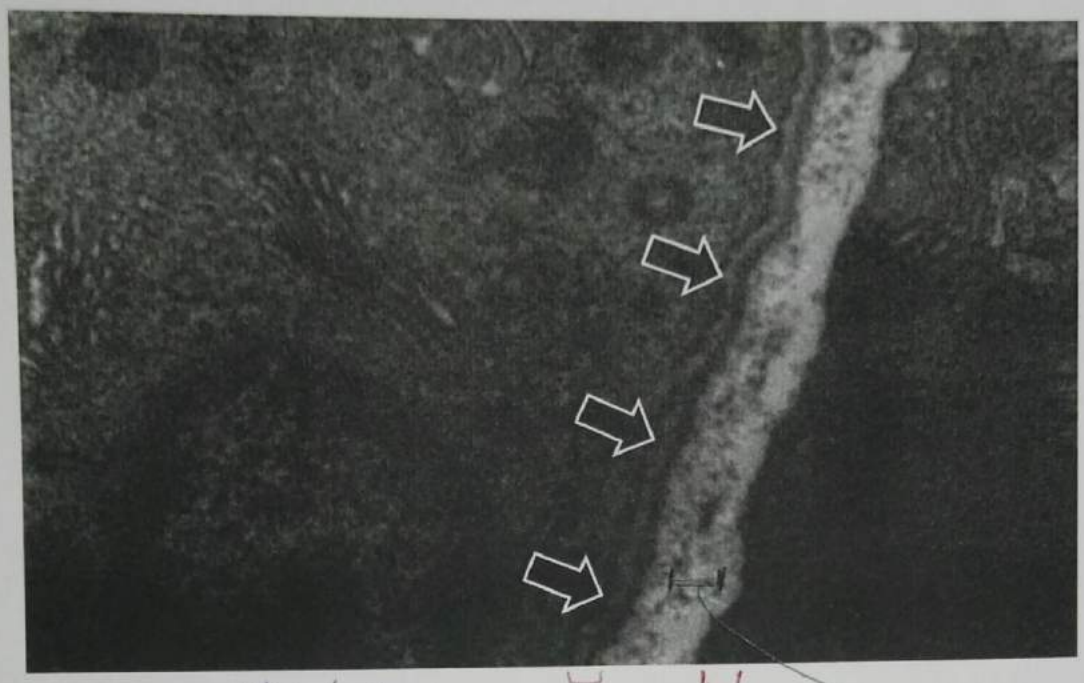

* cell membrane appears like triluminar appearance under EM (black - white - black) cell membranes for 2 cells

inner membrane between outer

ECF : extracellular fluid

Cell membrane

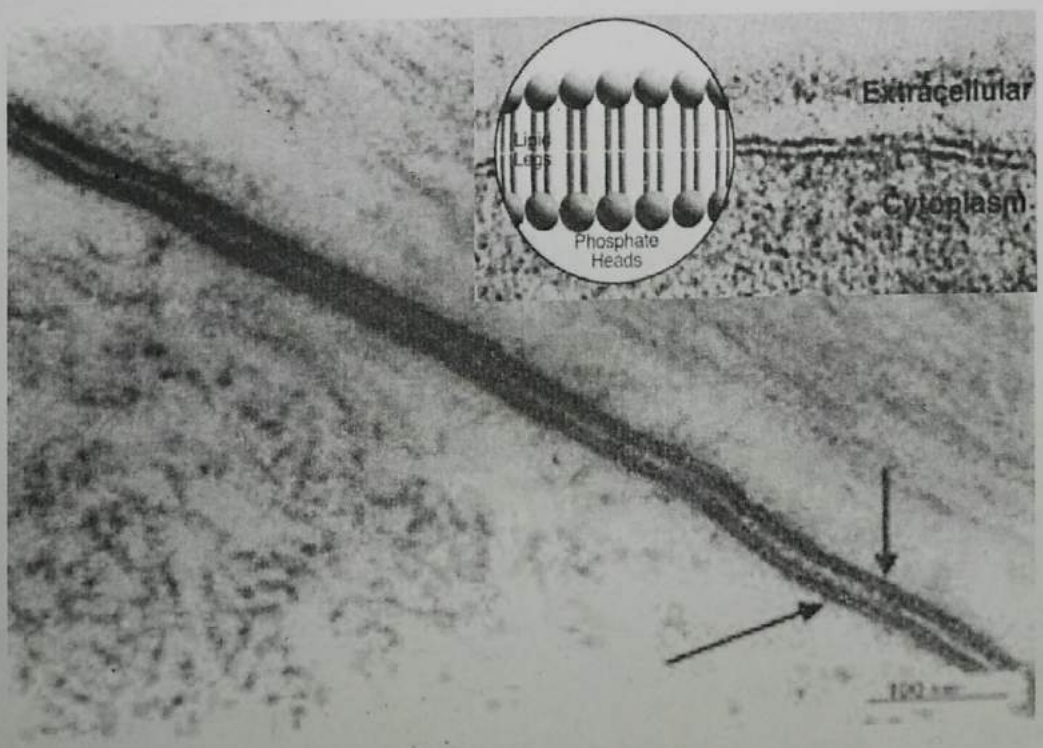

we stain the membrane with osmotetroxide, so the Hydrophilic region will be stained

Glycocalyx & Microvilli

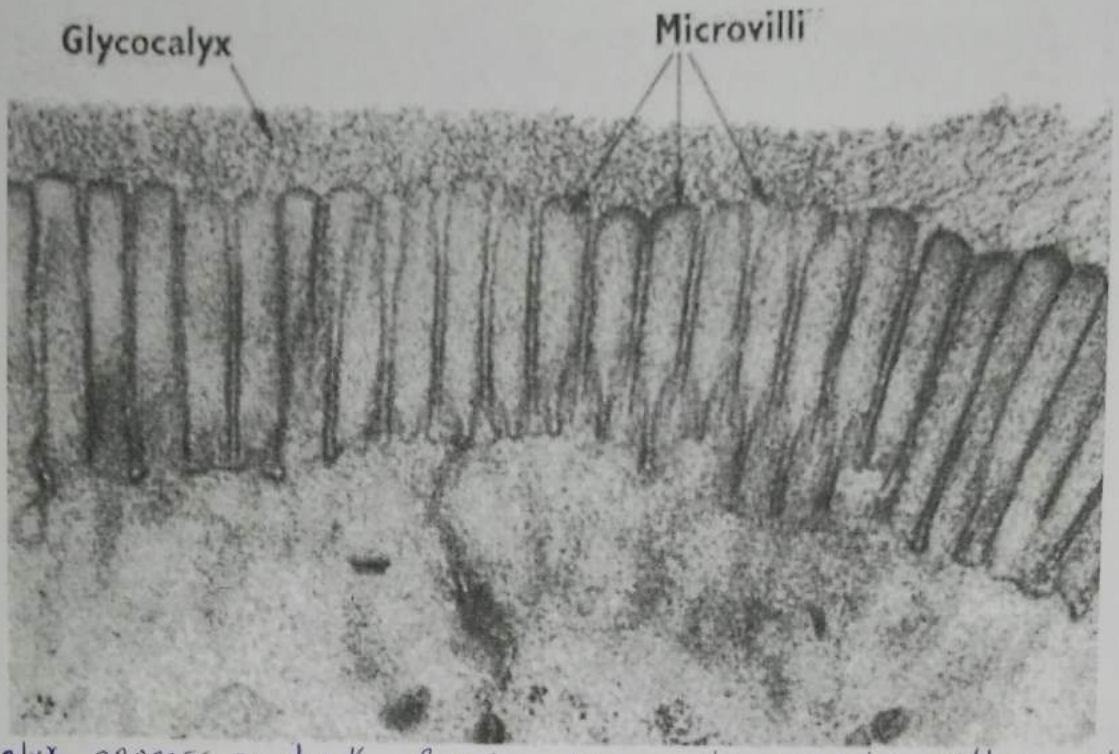

* Glycocalyx appears as dark & pale because it connects either with lipids or proteins

* plasma membrane folds to increase the area of secretion and absorption

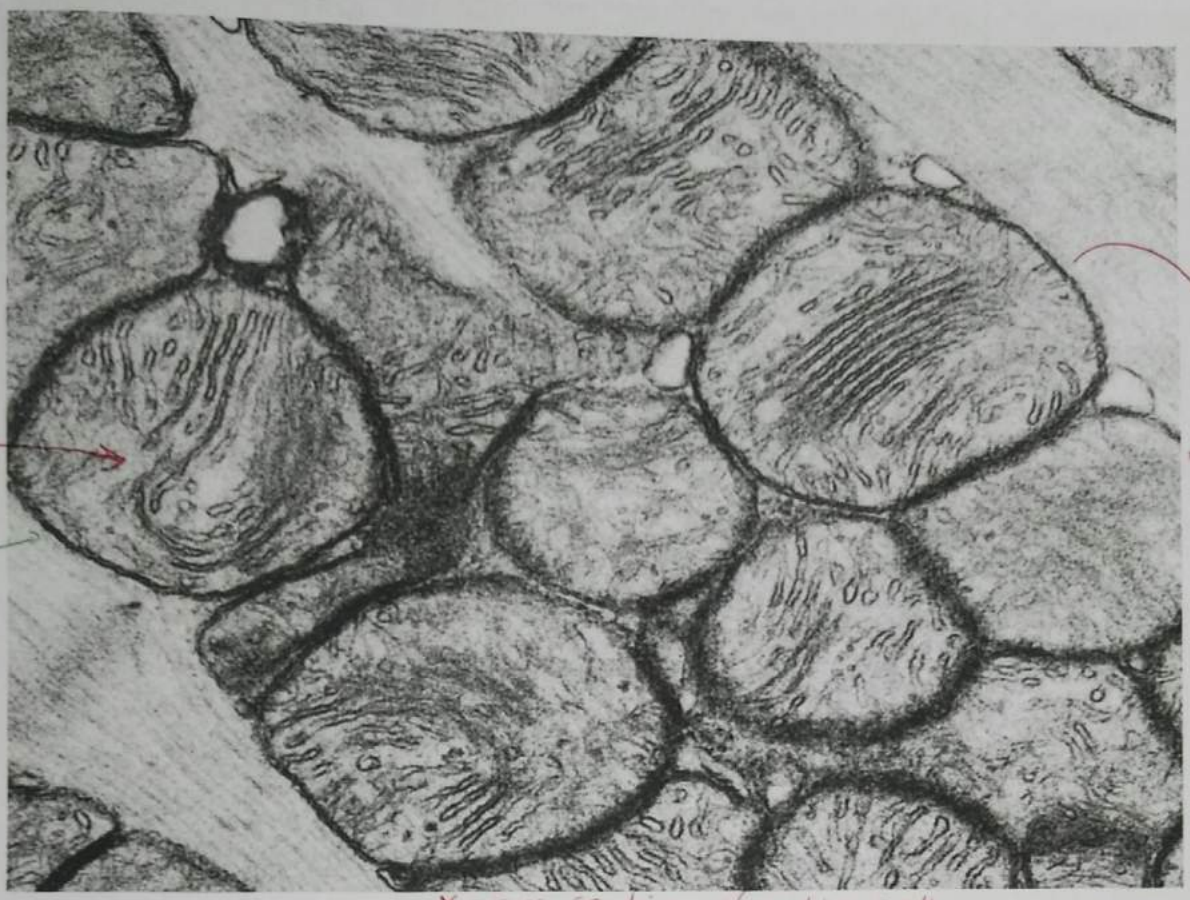

*cross section of active cell

*high amounts of mitochondria = active cell * mitochondria → rod shaped / cylinder shape

* high amount of mitochondria is needed to produce ATP which used in secretion and transport.

* rER
rough
endoplasmic
reticulum



1- flat 2- parallel to each other 3- stacked 4- contains ribosomes attached to it

SER
(smooth)

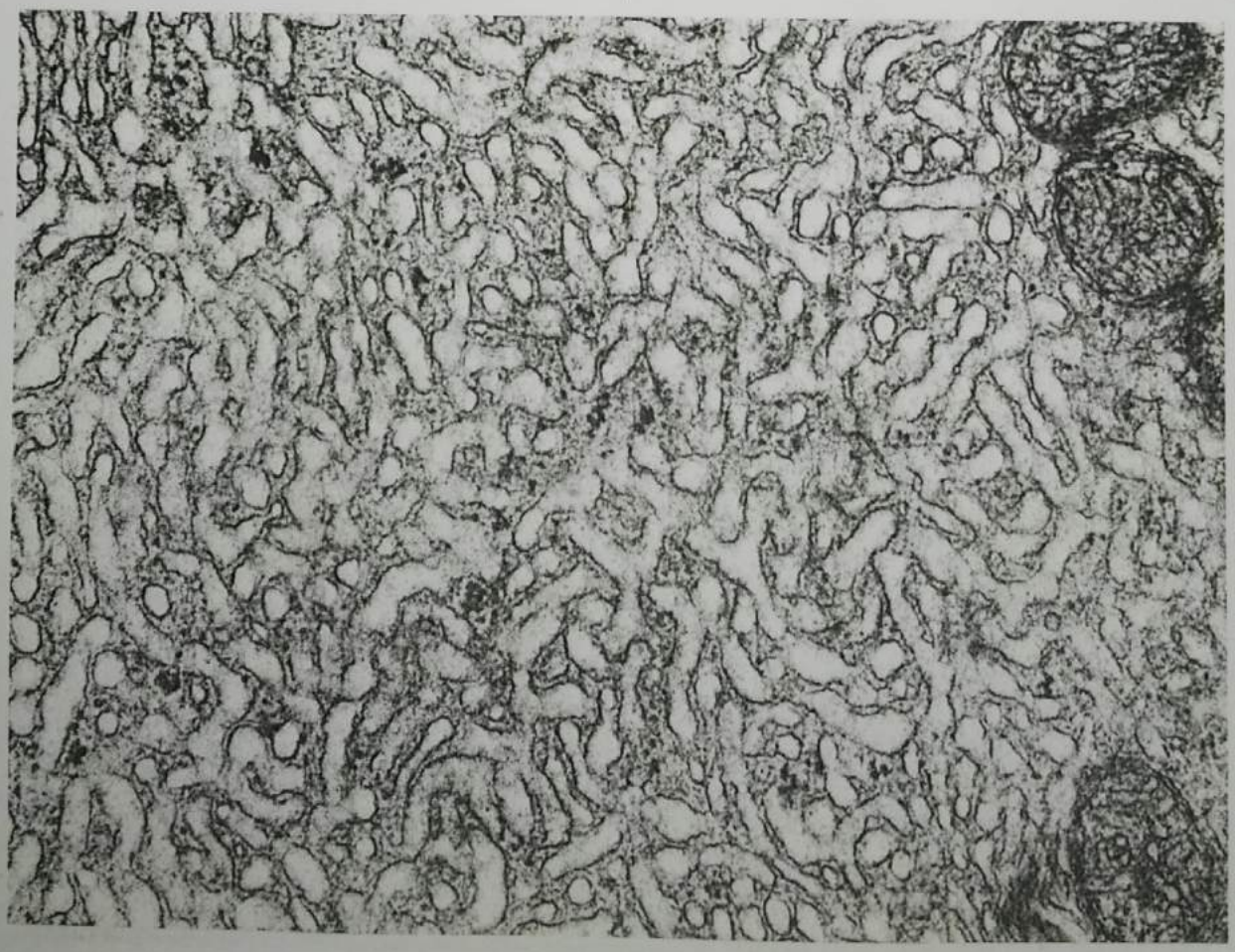

1- tubules 2- storage of Ca^{2+} 3- synthesis of lipids

golgi apparatus

1- flat cristern 2- less in quantity (5-10)
3- curved not parallel 4- No ribosomes
5- assosiated with high number of visciles and vacuola

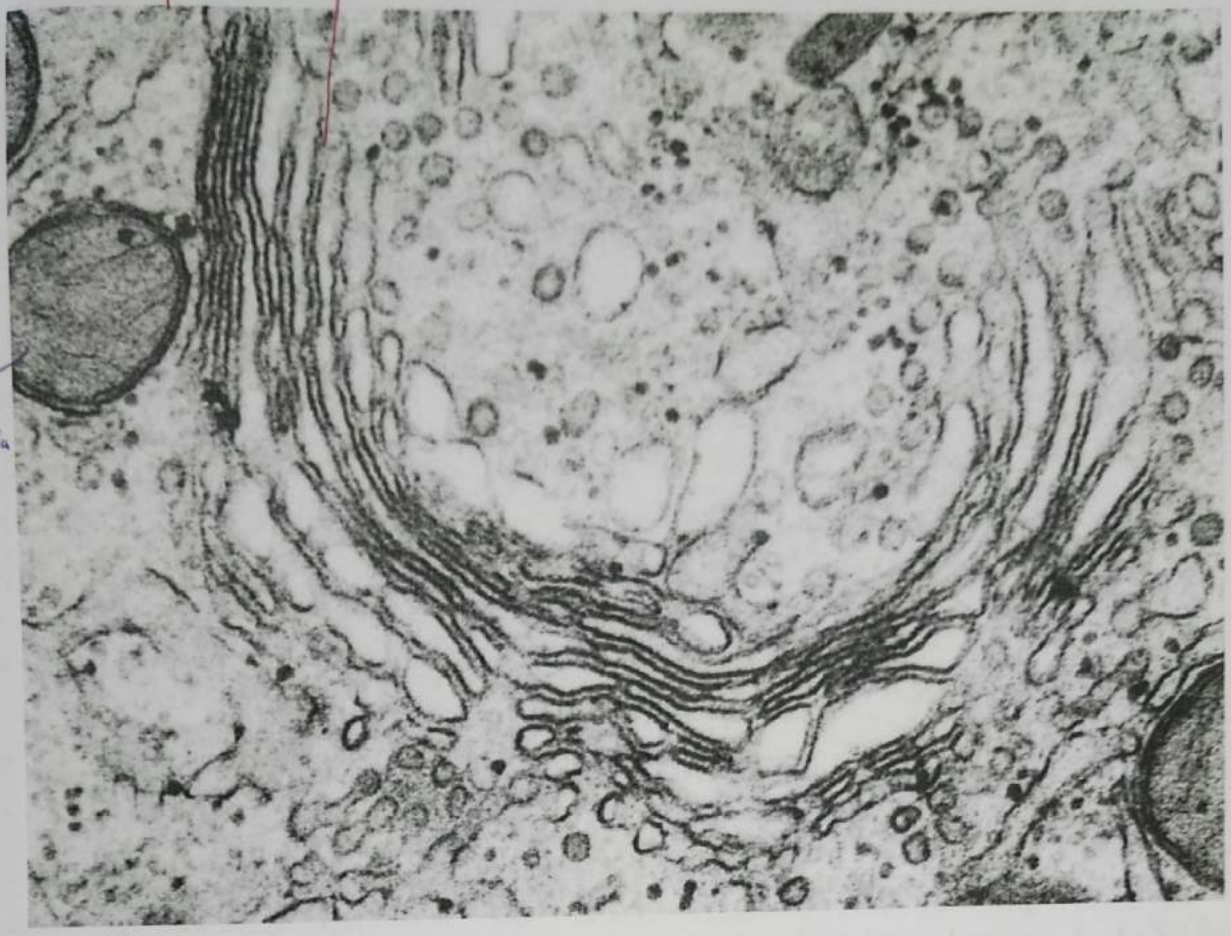

mitochondria

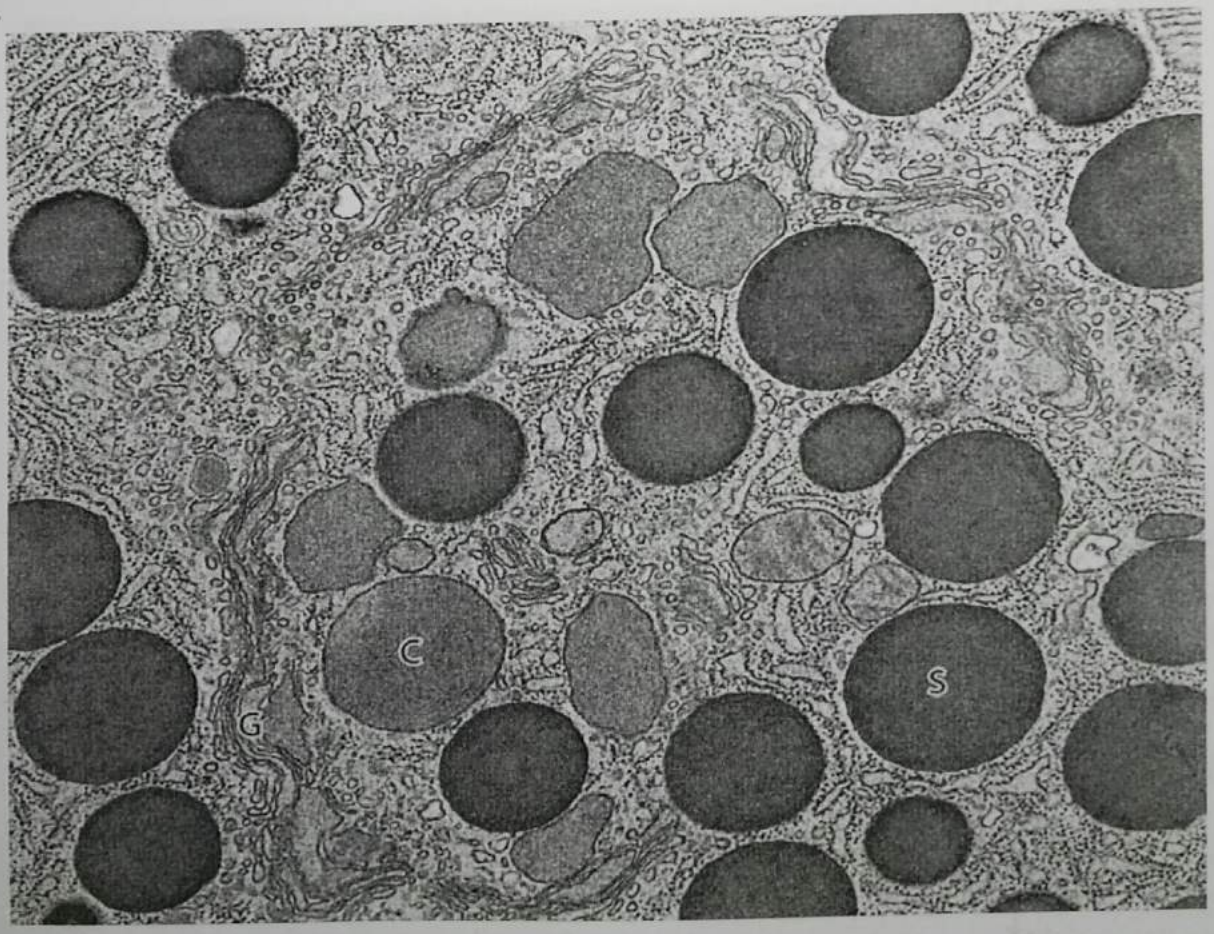

* secretory visciles or Lysosome depending on the type of the cell

Primary lysosomes

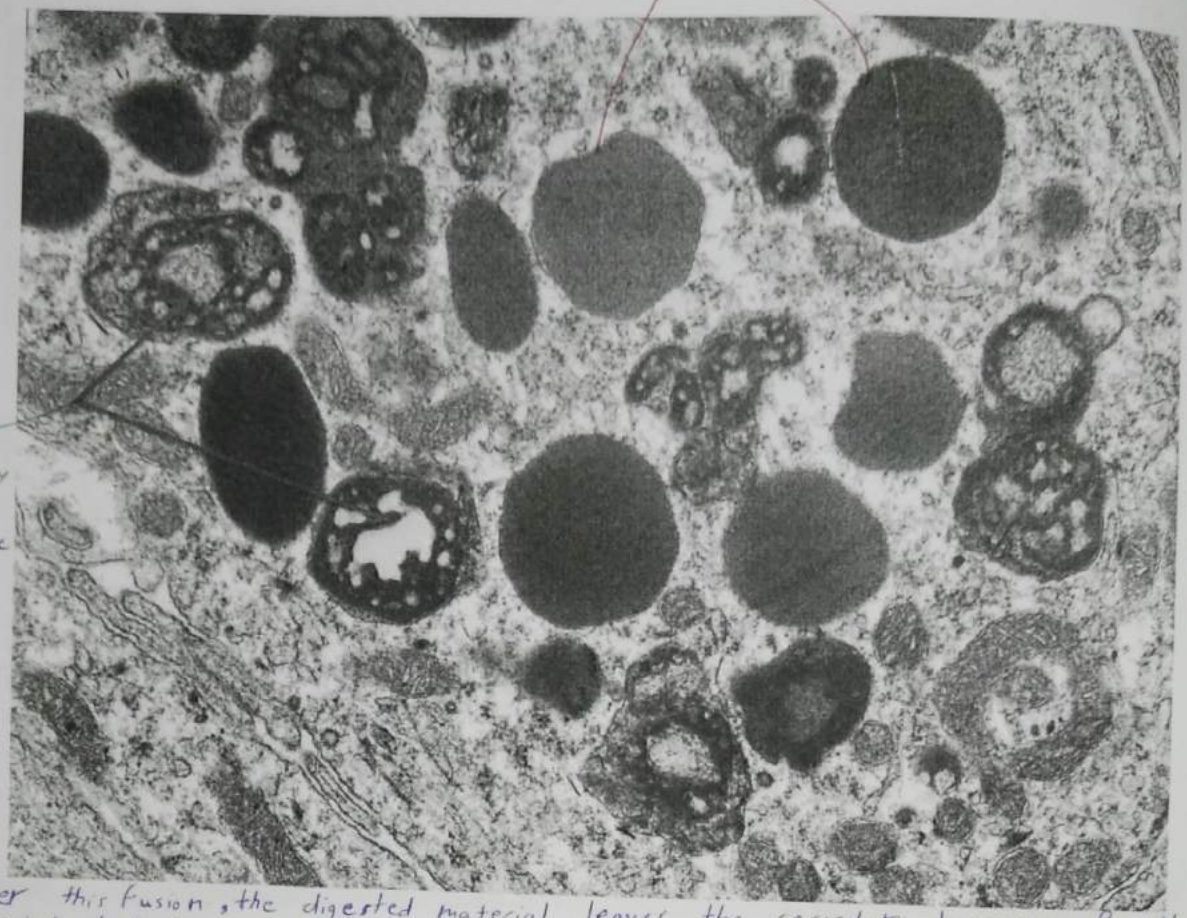

Secondary

after the fusion between primary & vesicles

* after this fusion, the digested material leaves the secondary lysosome & the remain material (which is undigestable) forms the residual body or tertiary lysosome

Polysome
or
Polyribosome

* active cell ⇒ because of polysome and nucleolus (contains euroeromatin)

Light microscopic appearance of cellular organelles

Basophilic

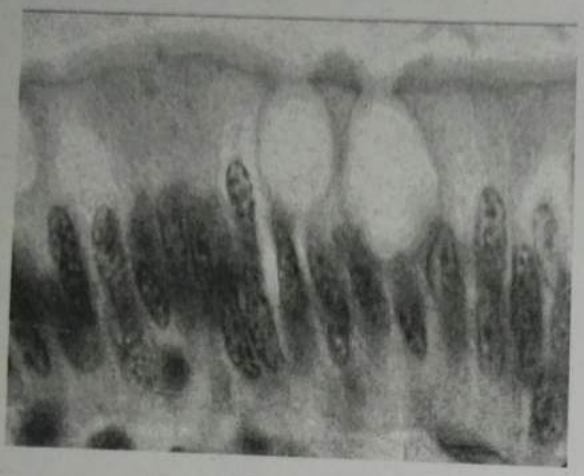

- Basophilic structures are stained by basic dyes:
  - Basic dyes are **positive**
  - Basophilic structures are **negative** (ex. DNA, RNA, ribosomes, RER)
- Mnemonic:

  Basophilic = **B**lue

Acidophilic (Eosinophilic)

- Acidophilic structures are stained by acid dyes:
  - Acid *dyes* are **negative**
  - Acidophilic structures are **positive** (ex. Proteins, collagen, cytoplasm)
- Eosinophilic = Pink

Eosin (H&E)

- Pink
- Stains Eosinophilic structures ex. Proteins, collagen, mitochondria (cytoplasm)

Hemotoxylin (H&E)

- Blue, purple or blackish
- Stains Basophilic structures ex. DNA, ribosomes, RNA
  - Euchromatin is DNA in USE. It is spread out, diffuse, and less stained.
  - Heterochromatin is condensed DNA, and stains dark blue.

*each nucleus represents a cell

Heterochromatic and Euchromatic Nuclei

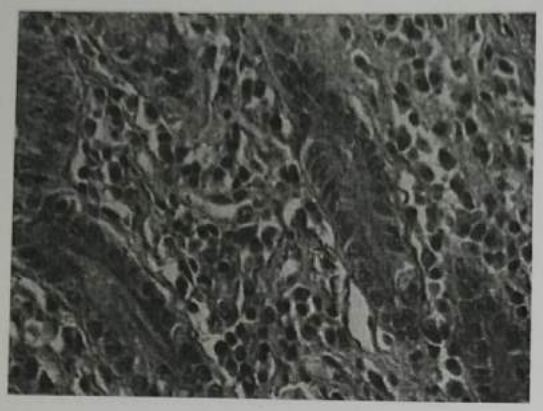

represnt heterochromatain & nucleolus (nucleus)
=> inactive

black arrows

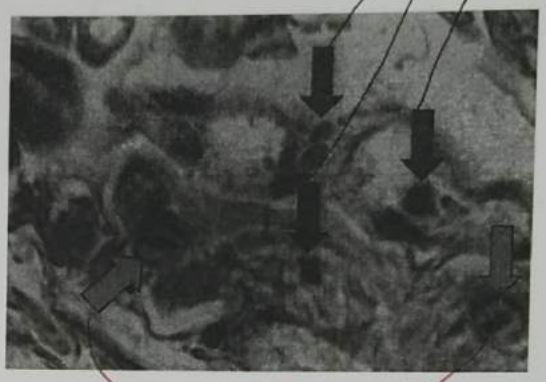

red arrows

represent euro chromatain & nucleolus (nucleus) stained less than heterochromatain => active

Periodic Acid Schiff &Hematoxylin (PAS)

- Pink, Magenta
- Stains carbohydrates and carb. rich macromolecules ex. Glycogen, mucin, basement membrane, etc.
- If you see PAS, think CARBOHYDRATES.

* carbohydrates have (CHO) and (PAS) is an oxidation agent for CHO so it convert CHO into (aldehyde) + schiff => produce magenta

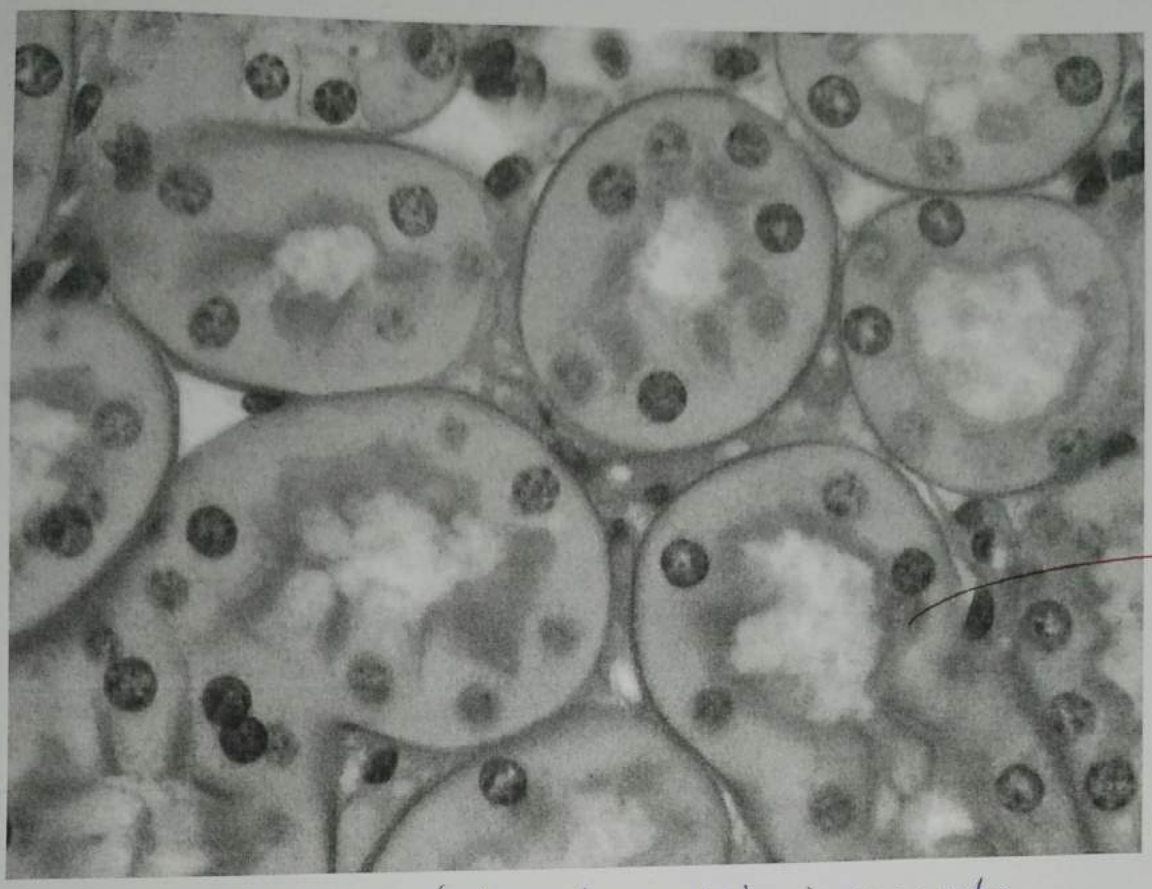

glycocalyx

*rich in carbohydrates (glycocalyx + PAS) → magenta

H&E vs. PAS

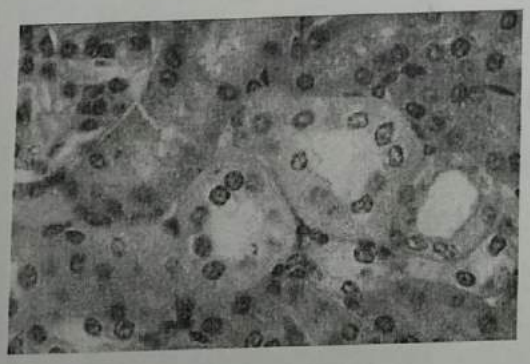

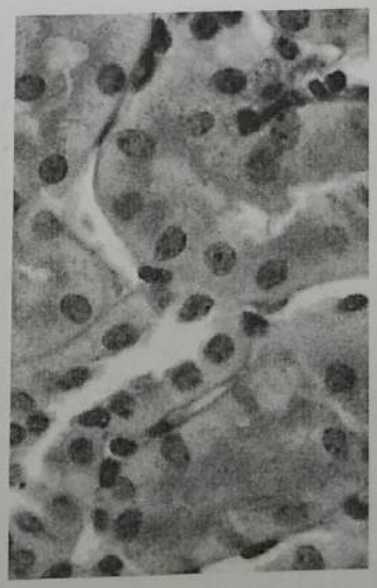

Question 1

- How would you describe the structure at the pointer?
  a) Eosinophilic
  b) Basophilic
  c) Negatively charged
  d) Positively charged

Question 1

- How would you describe the structure at the pointer?
  a) Eosinophilic
  b) Basophilic
  c) Negatively charged
  d) Positively charged

Question 2

- The pink regions are eosinophilic due to:

a) Endosomes
b) rER
c) Cytosolic proteins
d) Golgi
e) Cilia

Question 3

- The pink regions are eosinophilic due to:

a) Endosomes
b) rER
c) Cytosolic proteins
d) Golgi
e) Cilia

Question 4

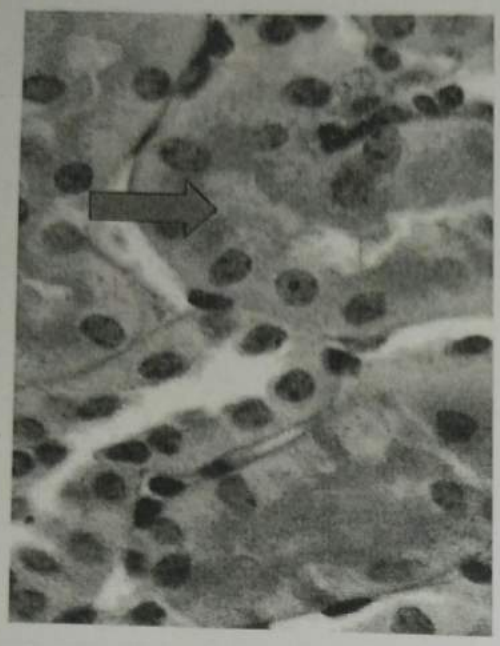

- The apex of this cell stains positively because of

a) Ribosomes
b) Carbohydrates
c) Fats

Question 4

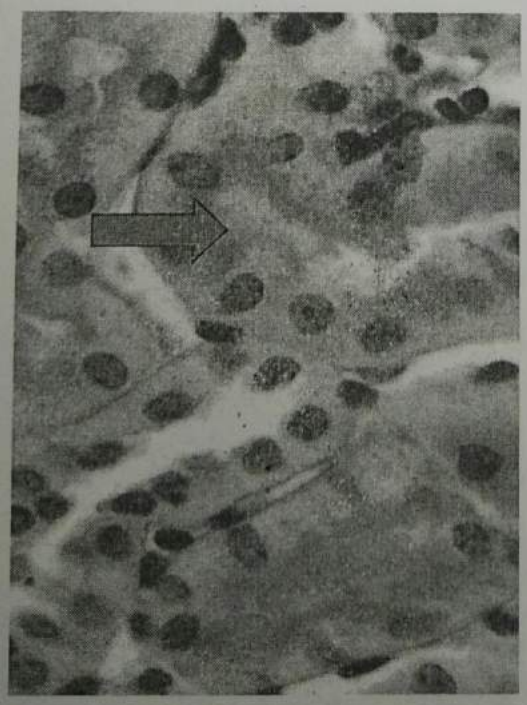

- The apex of this cell stains positively because of

a) Ribosomes
b) Carbohydrates
c) Fats

Now ... Examine a number of different slides and note the features that they all have in common: nucleus, nucleolus, chromatin, cell membrane and cytoplasm

Notice the following in each slide:

Shape of the cells

Cytoplasm

- Staining reaction
- Granules

Nucleus

- Staining reaction
- Nucleolus
- Position
- Chromatin

---

red blood cells

النواة غير ظاهرة

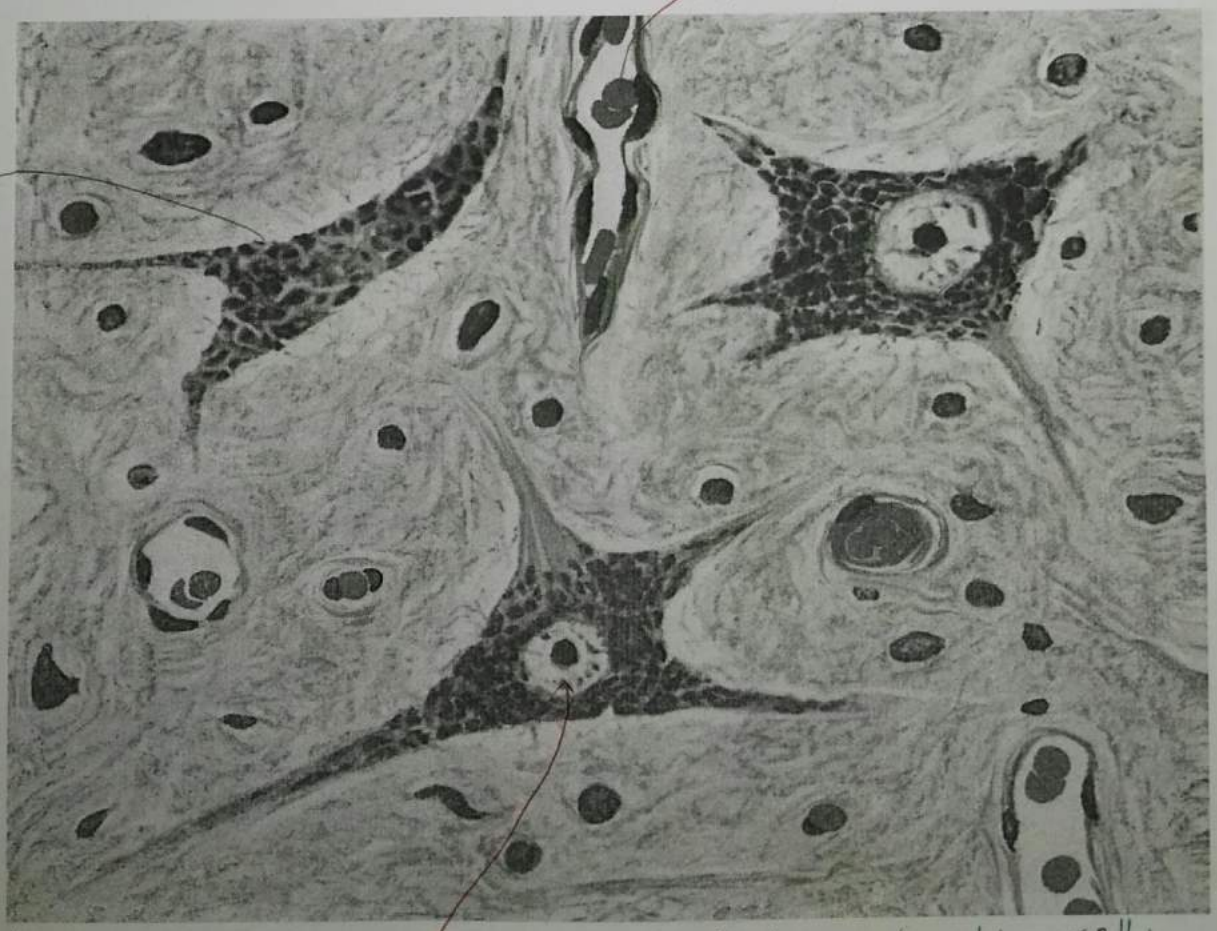

nucleus

* Basophilia inside the cytoplasm
=> rER & ribosomes

* features of active cell :-
* light stained nucleus
* prominant
* many organelles

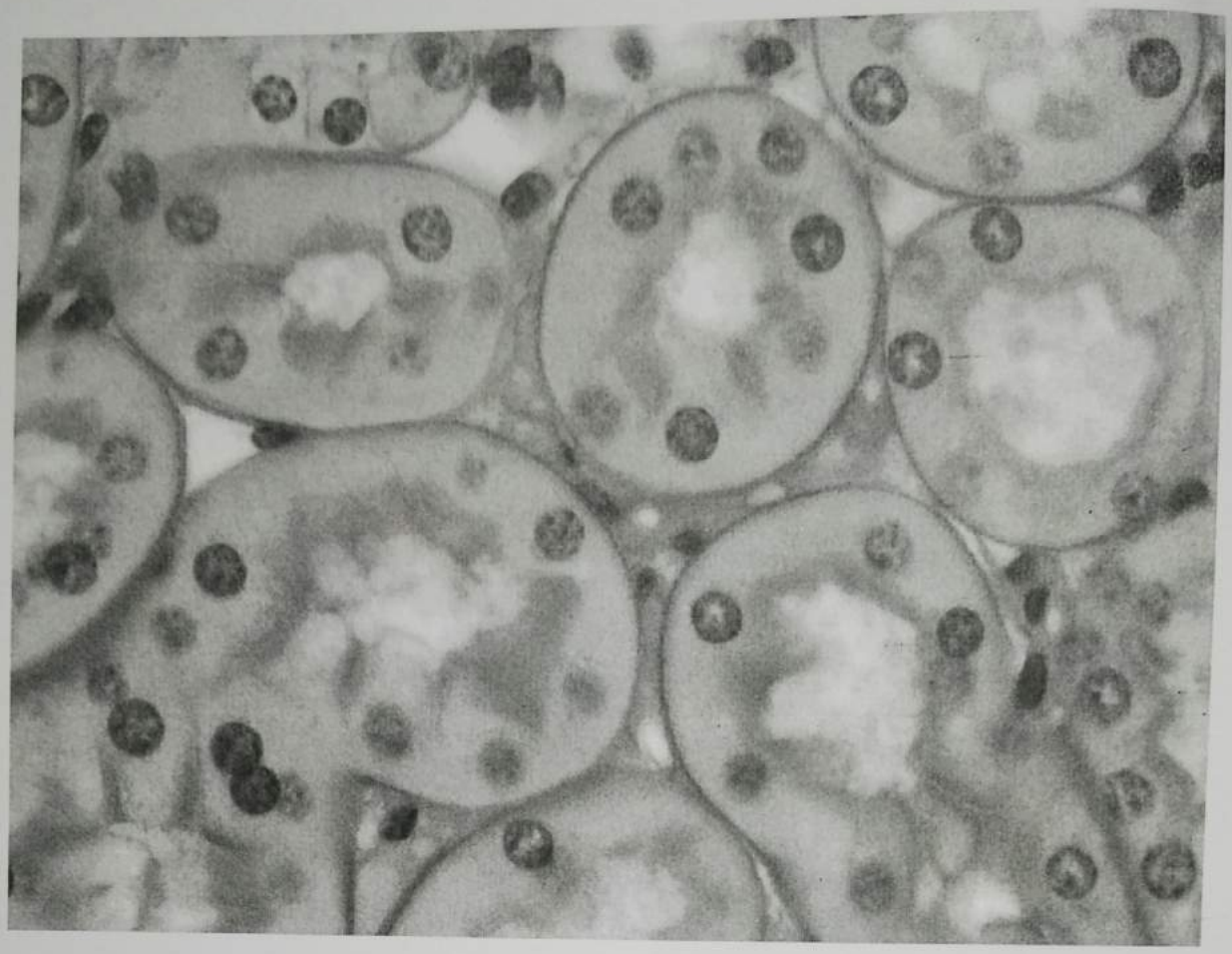

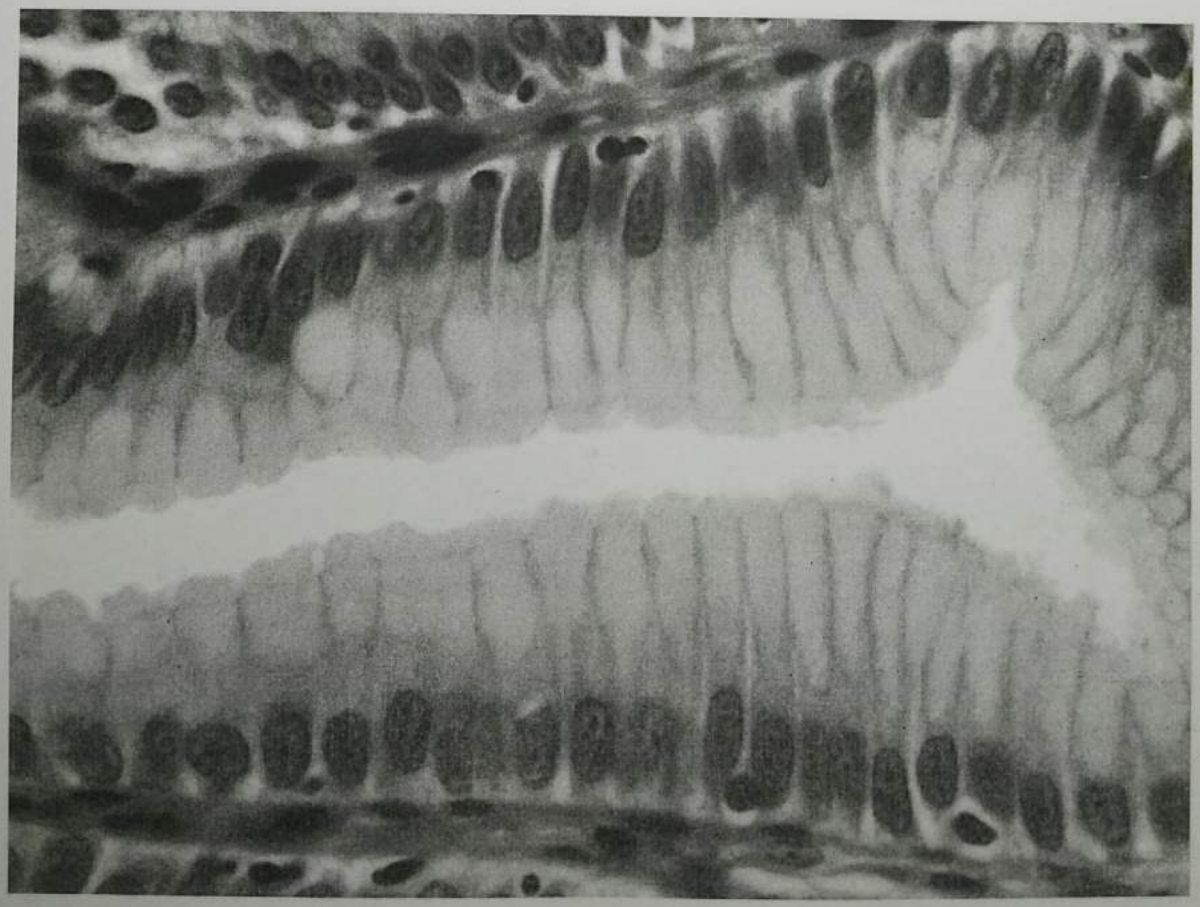

* tall cells ⇒ nuleus elongated

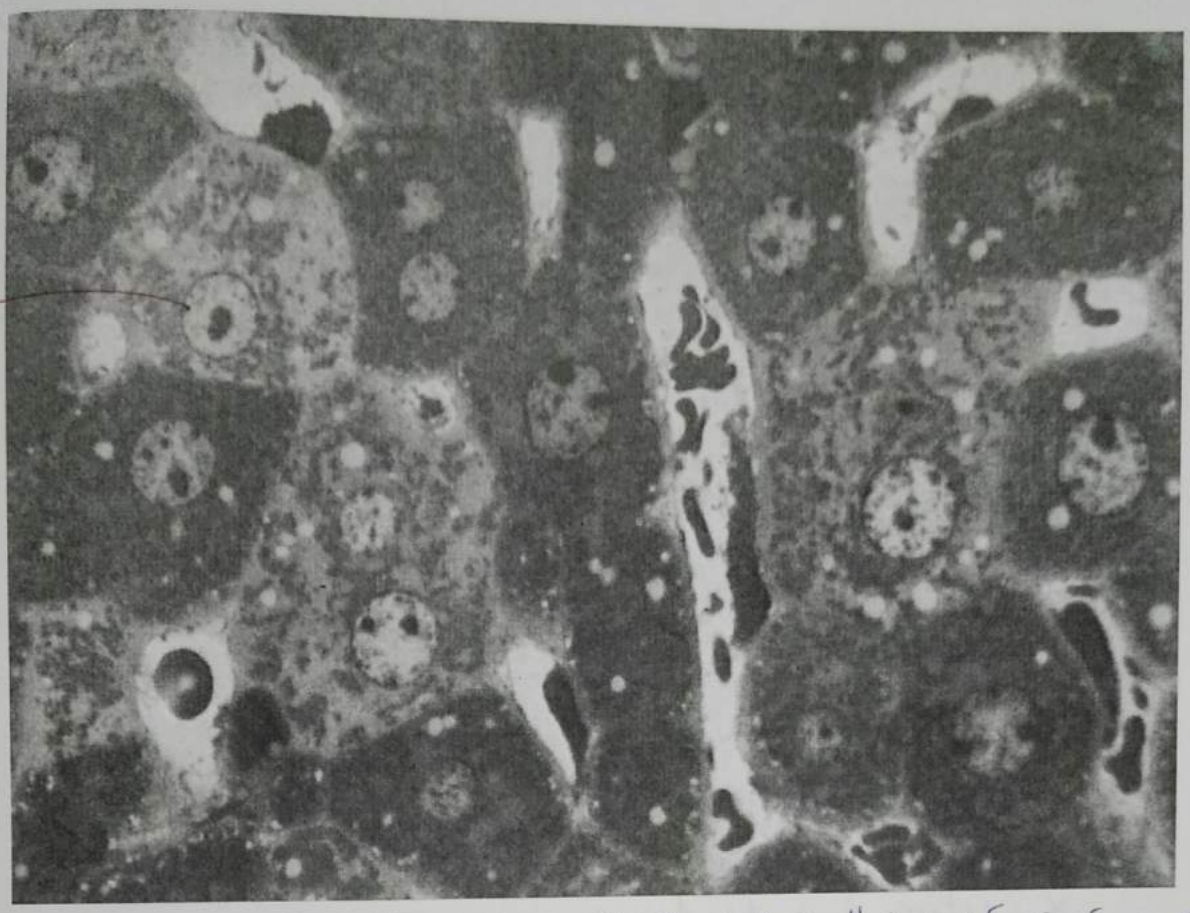

nucleus

وجود كمية كبيرة من السيتوبلازم والنواة ⇐ الخلية نشطة

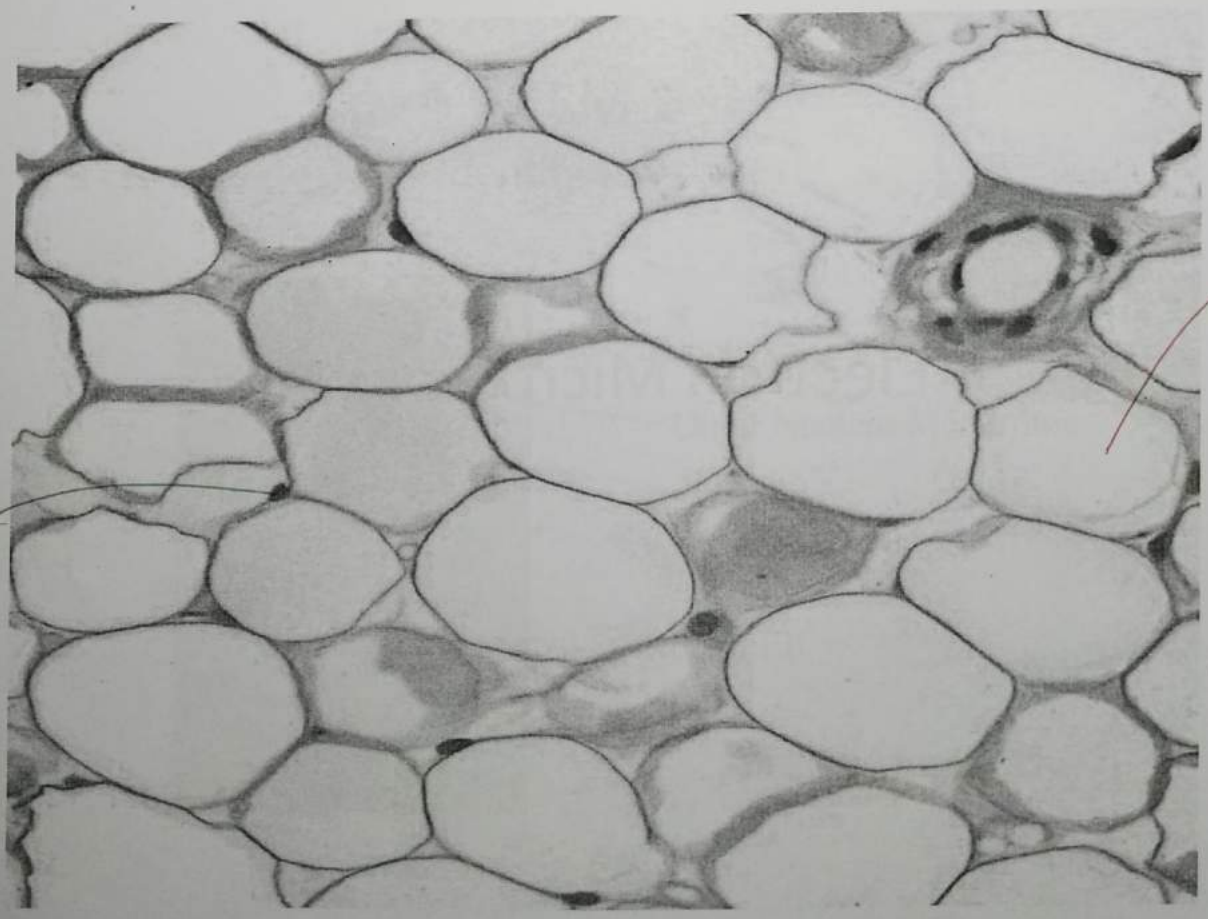

اللون الأبيض (الفراغ) بسبب مادة Xylene عندما حُضِّر النسيج تم إذابة Lipids

النواة طرفية

* adipose cells store inside them : fats and lipids

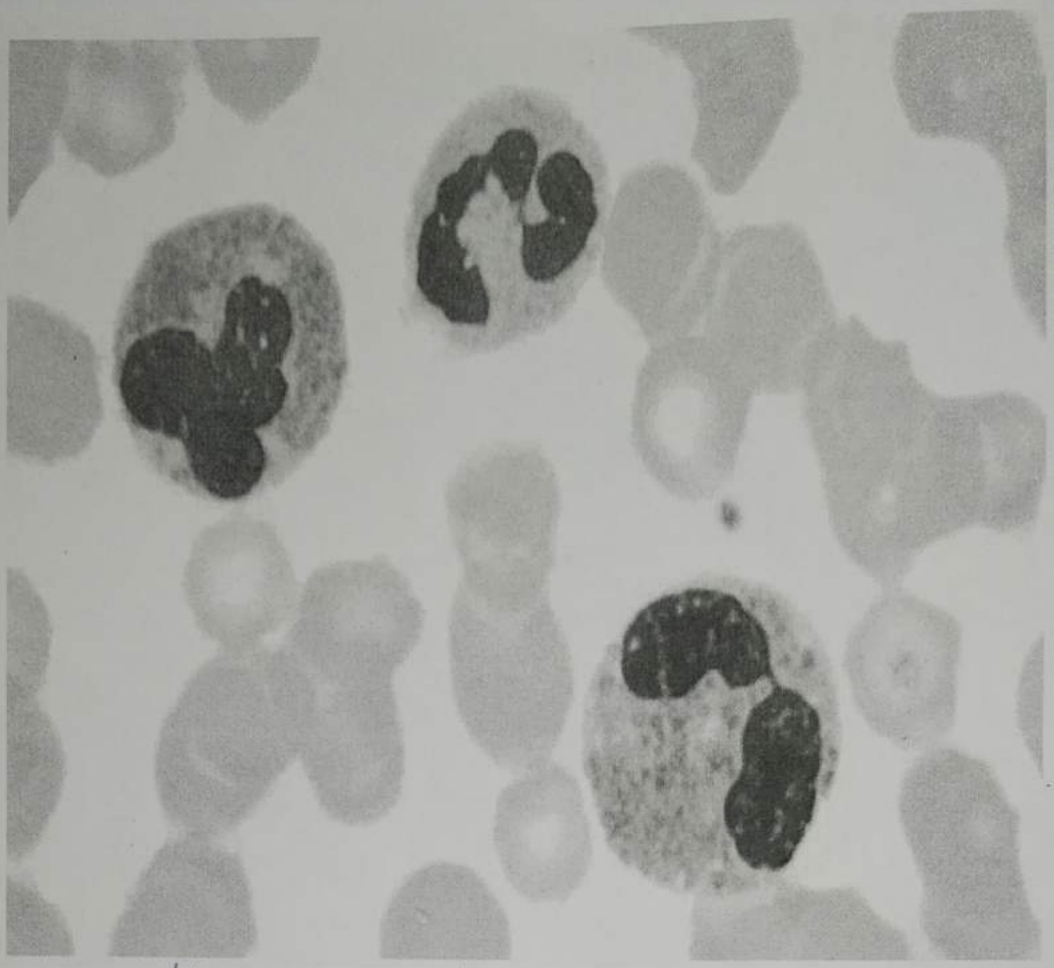

* section from blood => النواة مقسمة

Electron Microscopy

EM 1

Identify structures



EM 1

Identify structures

EM1, Q1

Proteins that are made here may end up at which of the following sites:

a) Outside the cell
b) Golgi Apparatus
c) Plasma Membrane
d) All of the above
e) None of the above

EM1, Q1

Proteins that are made here may end up at which of the following sites:

a) Outside the cell
b) Golgi Apparatus
c) Plasma Membrane
d) All of the above
e) None of the above

EM2

- Active or inactive cell?

EM2

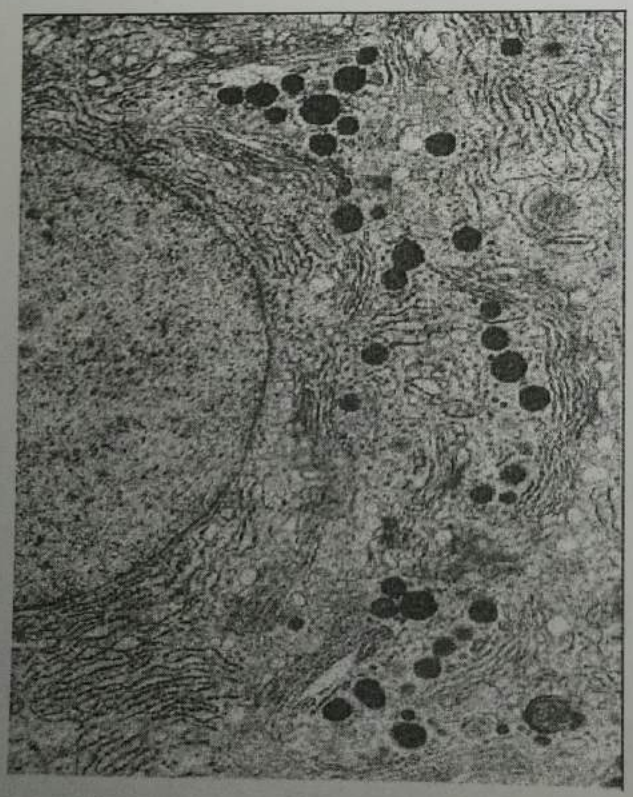

- Active or inactive cell?
  - ACTIVE