Histology

● Sheet ○ Slide

number 2

Done by Yazan Sbeih Hijazeen

Correction Dina Dahabreh

Doctor Mohammed Mohtaseb

* All of Slide 2 (stomach, small intestine) + Slide 3 (large intestine, appendix) till page 8.

Stomach

-We should always relate the histology of any structure to its function.

-The stomach is a mixed exocrine-endocrine organ that digests food and secretes hormones.

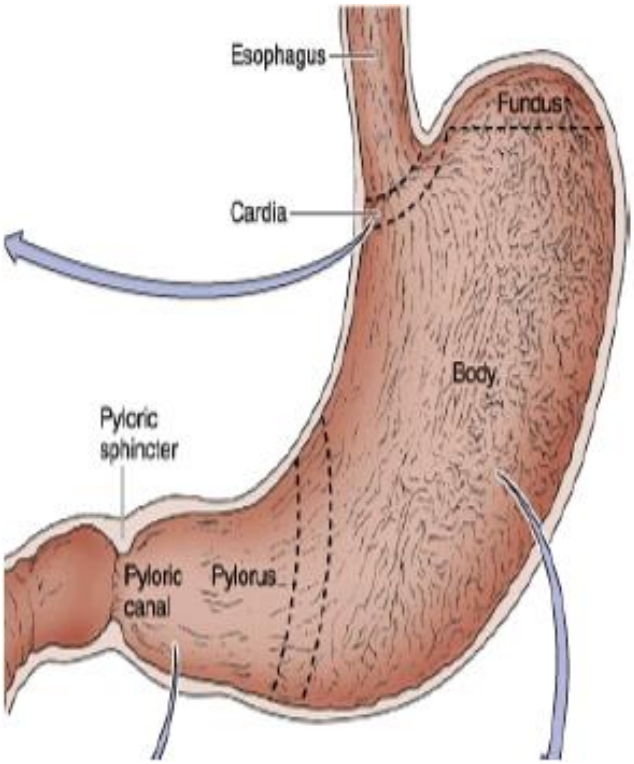

*Main functions:

1) Continue the digestion of carbohydrates initiated in the mouth

2) Add an acidic fluid to the ingested food (gastric juice)

3) Transform it by muscular activity into a semi-liquid viscous mass (**chyme**)

Note: It takes 2 to 4 hours for the food to be evacuated from the stomach.

4) Promote the initial digestion of proteins with the enzyme **pepsin**

5) Produce a gastric lipase that digests triglycerides with the help of lingual lipase.

-Gross inspection reveals four regions: **cardia, fundus, body,** and **pylorus.** (Each region differs in its histology, except for the fundus and body which are identical in microscopic structure)

- The main function of pylorus is alkalization of the acidic chyme.

- The mucosa and submucosa of the undistended stomach lie in longitudinally directed folds known as **rugae.** When the stomach is filled with food, these folds flatten out.

*Layers of the GIT:

1) Mucosa 2) Submucosa 3) Muscularis externa 4) Serosa

*The mucosa is divided to three sublayers:

1) **Surface lining epithelium** that invaginates to various extents into the lamina propria, forming gastric pits (can be seen by the magnifying glass).

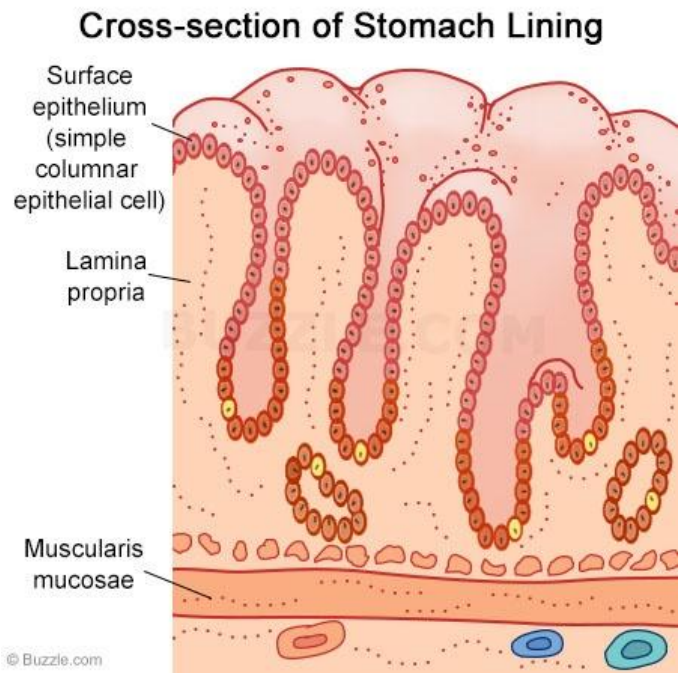

- Bicarbonate, secreted by the surface epithelial cells into the mucous gel, forms a pH gradient ranging from 1 at the gastric luminal surface to 7 along the epithelial cell surface. Surface epithelial cells also form an important line of defense due to their function in mucus production, intracellular tight junctions, and the ionic transporters that maintain intracellular pH and bicarbonate production, important for gel alkalization.

2) **Lamina propria** of the stomach is composed of loose connective tissue interspersed with smooth muscle and lymphoid cells. It also contains gastric glands.

3) **Muscularis mucosae,** 3 ribbons of smooth muscle separating the mucosa from the underlying submucosa; Change the shape of the lumen.

-Numerous small circular or ovoid invaginations of the epithelial lining are observed. These are the openings of the gastric pits.

-Emptying into the gastric pits are branched, tubular glands (cardiac, gastric, and pyloric) characteristic of each region of the stomach.

-The epithelium covering the surface and lining the pits is a **simple columnar epithelium,** without goblet cells, and all the cells secrete alkaline mucus. This mucus consists primarily of water (95%), lipids, and glycoproteins, which in combination, form a hydrophobic protective gel.

* The gastric glands have 5 types of cells:

1) Stem cells → Mitosis and regeneration of dead cells

2) Mucous Cells → Mucus

3) Parietal cells → Hydrochloric acid

4) Chief cells → Pepsinogen

5) Enteroendocrine cells → Gastrin

* Classifying the regions of stomach histologically:

a) Cardia

b) Fundus and Body

c) Pylorus

a) Cardia

- If we take cross-sections from the cardia, the body and the pylorus in order to differentiate between them. In the cardia, the ratio of the glands in the lamina propria to the gastric pits is almost 1:1. The lining epithelium is the same

Also, the glands contain neither chief nor parietal cells since both HCl and pepsinogen are not required here.

-The cardia is a narrow circular band, 1.5–3 cm in width, at the transition between the esophagus and the stomach.

-Its mucosa contains simple or branched tubular cardiac glands. The terminal portions of these glands are frequently coiled, often with large lumens.

- Most of the secretory cells produce mucus and lysozyme (an enzyme that attacks bacterial walls).

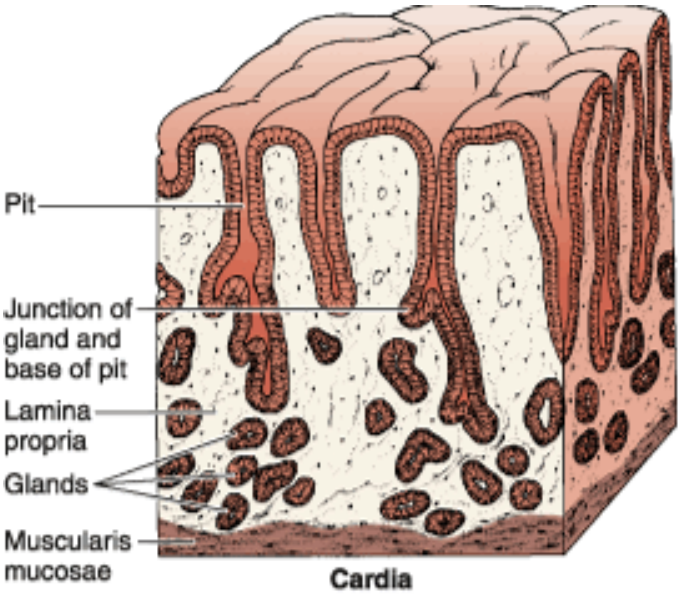

b) Fundus and Body

- The regions where digestion and mixing the ingested food (chyme) with enzymes occur.

- The lamina propria of the fundus and body is filled with branched, tubular **gastric glands,** three to seven of which open into the bottom of each gastric pit.

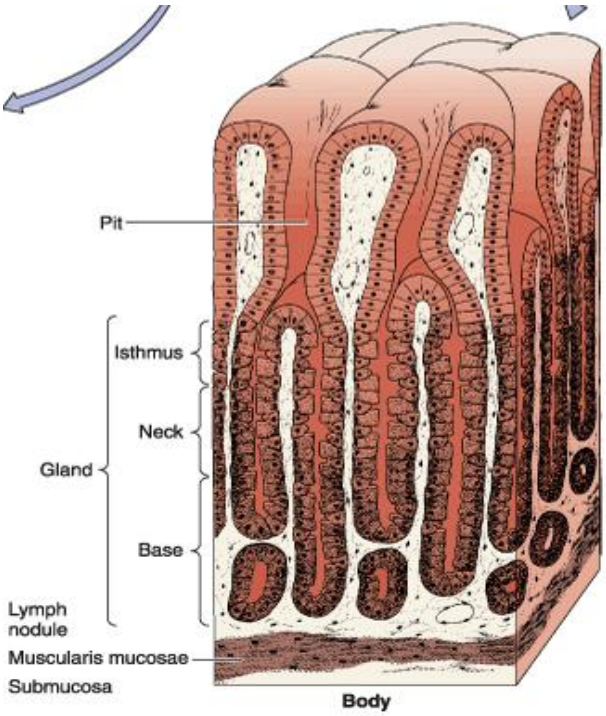

- The gland occupies around three fifths (3/5) of the lamina propria, the rest is dilated gastric pits (wide and short so secretions reach the surface quickly).

* Each gastric gland has three distinct regions: **the isthmus, neck, and base**.

- The **isthmus**, close to the gastric pit, contains differentiating mucous cells that will migrate and replace superficial mucous cells, undifferentiated stem cells, and oxyntic (parietal) cells.
- The **neck** of the glands consists of stem, mucous neck (different from the mucous cells in the isthmus), and parietal cells.
- The **base** of the glands primarily contains parietal and chief (zymogenic) cells.

- Enteroendocrine cells are dispersed in the neck and base of the glands.

*The 5 types of cells in the glands in more details:

i. **Stem cells**

Found in the isthmus and **neck** regions but few in number, stem cells are low columnar cells with oval nuclei near the bases of the cells. These cells have a high rate of **mitosis**; some of them move upward to replace the pit and surface mucous cells (renewal of cells), which have a turnover time of 4–7 days.

Other daughter cells migrate more deeply into the glands and differentiate into mucous neck cells, parietal, chief, and enteroendocrine cells.

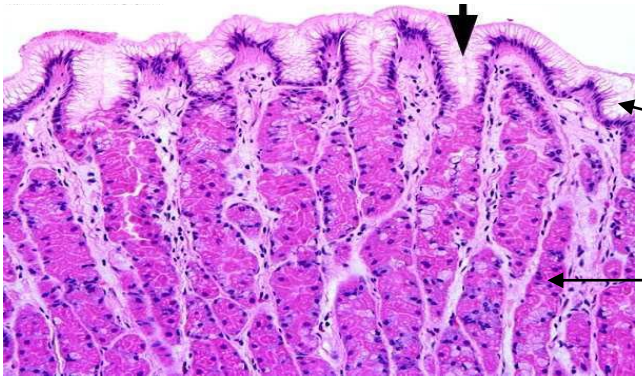

ii. Mucous neck cells

Mucous **neck** cells are present in clusters or as single cells between parietal cells in the necks of gastric glands. Their mucus secretion is quite different from that of the surface epithelial mucous cell

They are irregular in shape, with the nucleus at the base of the cell and the secretory granules near the apical surface.

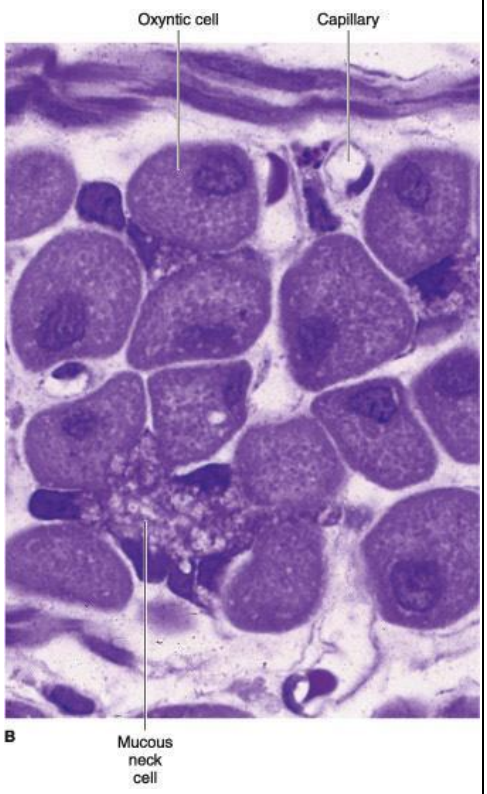

iii. Parietal (Oxyntic) Cells

Parietal cells are present mainly in the upper half of gastric glands (**neck** and above/ between isthmus and neck). They are rounded or pyramidal cells, with one **centrally** placed spherical nucleus and intensely **eosinophilic** cytoplasm, and sometimes **binucleated**.

They contain mitochondria and a deep, circular invagination of the apical plasma membrane, forming the intracellular canaliculus.

<u>In the resting cell</u> (inactive) a number of **tubulovesicular structures** can be seen in the apical region just below the plasmalemma. At this stage, the cell has few microvilli.

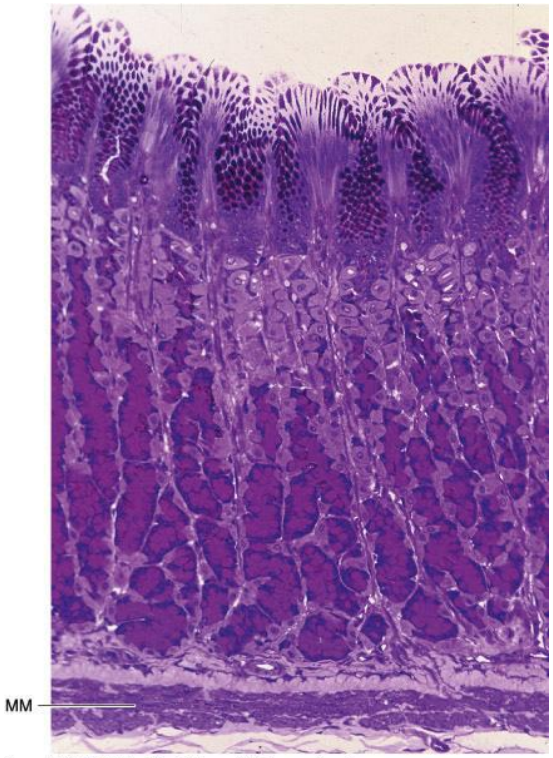

When stimulated (active) to produce H+ and Cl–, tubulovesicles fuse with the cell membrane to form the **intracellular canaliculi** and more microvilli, thus providing a generous increase in the surface of the cell membrane.

Parietal cells also produce an intrinsic factor which helps in absorbing vitamin B12 in the ileum.

* Slide 2/page 12 explains the biochemical process of releasing HCl by the parietal cells.

iv. Chief (Zymogenic) Cells

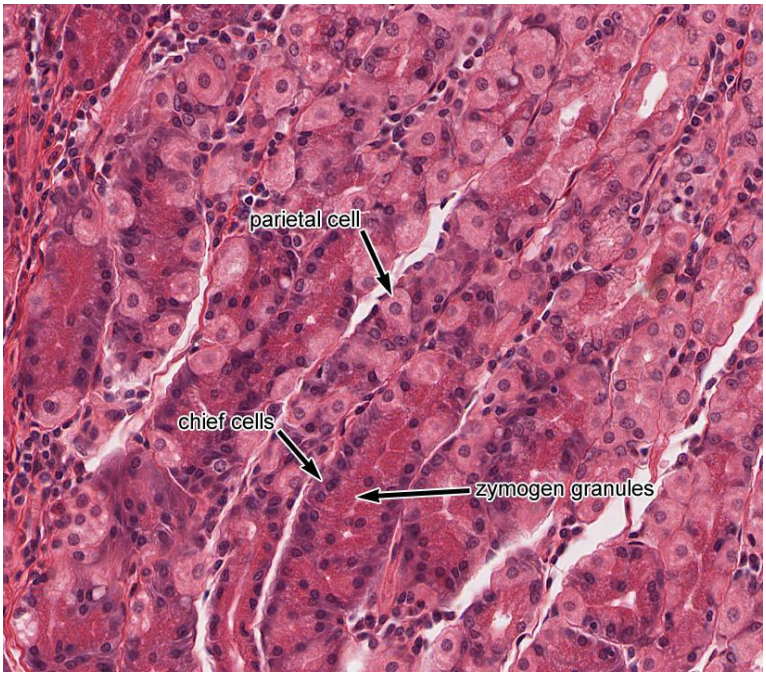

Chief cells predominate in the lower region of the tubular glands (basal).

Their basophilia is due to the **abundant rough endoplasmic reticulum (ribosomes)**. The granules in their cytoplasm contain the inactive enzyme pepsinogen.

The precursor pepsinogen is rapidly converted into the highly active proteolytic enzyme pepsin after being released into the acid environment of the stomach.

There are seven different pepsins in the human gastric juice, which are aspartate endoproteinases of relatively broad specificity active at pH < 5.

In humans, chief cells also produce the enzyme lipase.

v. Enteroendocrine Cells

Found in the neck and bases of gastric glands.

It functions in the secretion of hormones such as gastrin.

In the fundus of the stomach, **5-hydroxytryptamine (serotonin)** and **Gastrin** are the principal secretory products.

In the stomach, the G pyloric cells produce Gastrin that lead to the Stimulation of gastric acid secretion and Gastric mucosal growth.

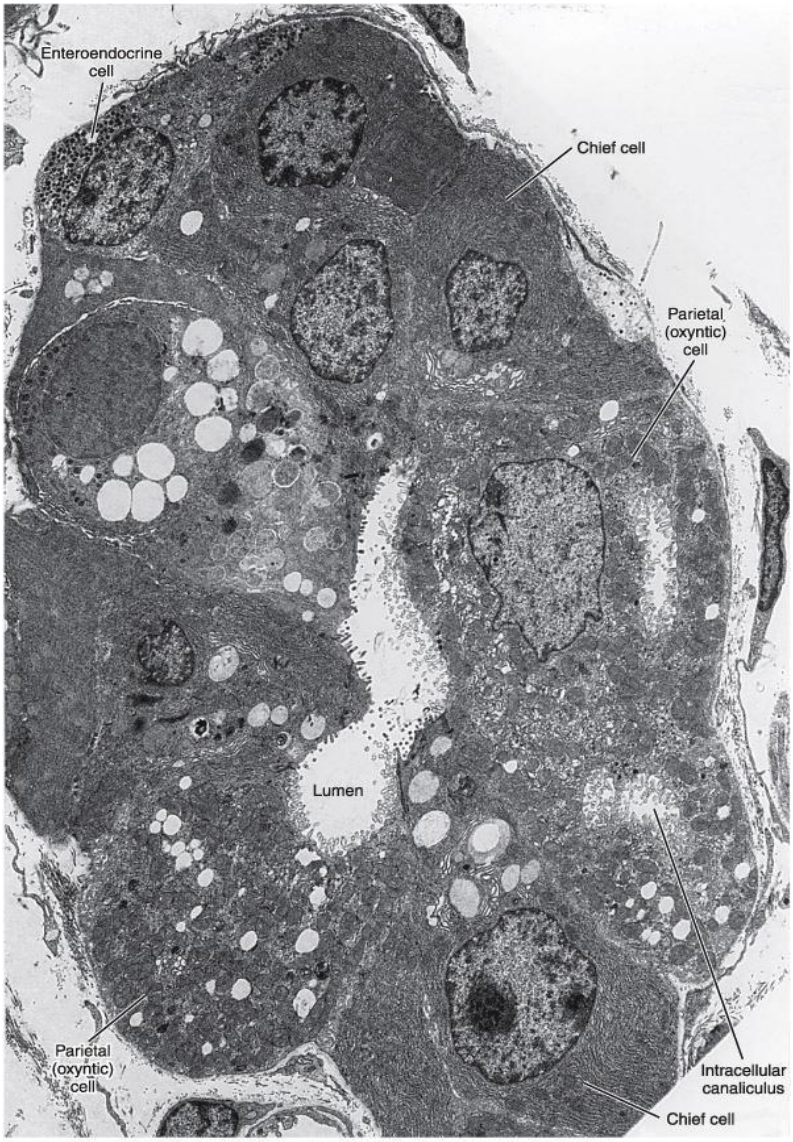

* Stem cells and enteroendocrine cells cannot be seen under the light microscope, in contrast to mucous, parietal and chief cells which can.

c) Pylorus

It has deep gastric pits into which the branched, tubular pyloric glands open. Compared with the glands in the cardiac region, pyloric glands have longer pits and shorter coiled secretory portions.

These glands secrete mucus as well as appreciable amounts of the enzyme lysozyme.

Gastrin (G) cells (which release **gastrin**) are enteroendocrine cells intercalated among the mucous cells of pyloric glands.

No chief and parietal cells.

In the lamina propria, there are aggregations of lymph nodules. (Immunity)

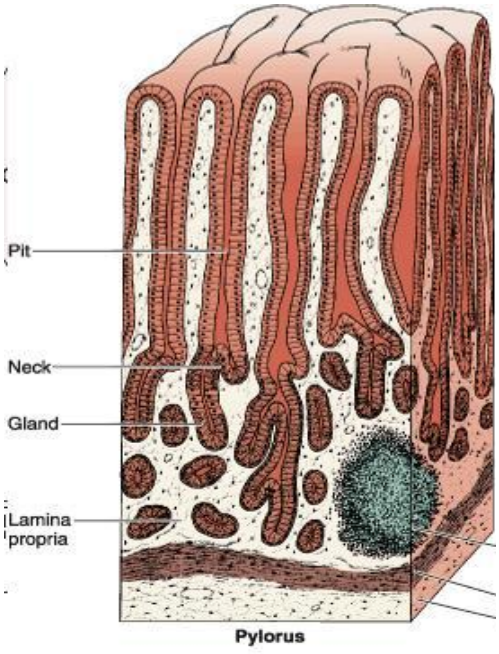

Parasympathetic stimulation, the presence of nutrients such as amino acids and amines in the stomach, and distention of the stomach wall directly stimulate the G cell to release gastrin, which in turn activates the parietal cell, increasing acid secretion.

Other enteroendocrine cells (**D cells**) secrete **somatostatin,** which inhibits the release of some other hormones, including gastrin.

Secretion of somatostatin is stimulated by HCl, counterbalancing the acid secretion.

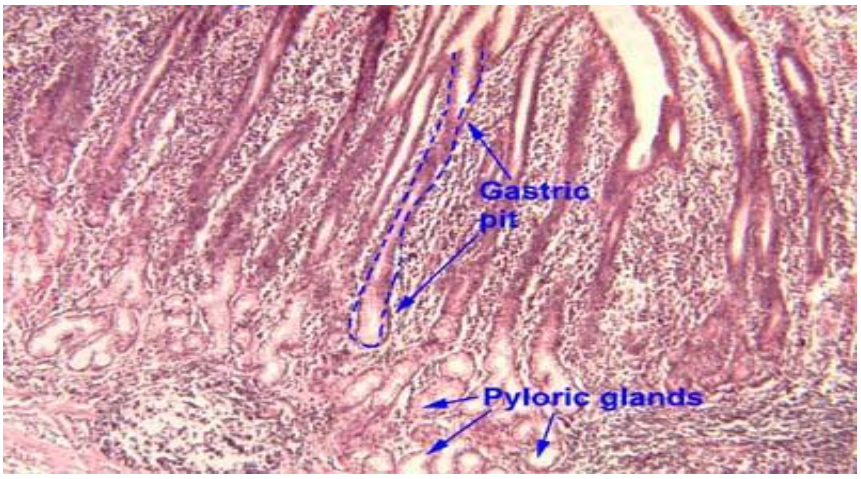

The remaining layers

The **submucosa** is composed of dense connective tissue containing blood and lymph vessels; it is infiltrated by lymphoid cells, macrophages, and mast cells. It also contains Meissner's plexus.

The **muscularis externa** is composed of smooth muscle fibers oriented in three main directions; the external layer is longitudinal, the middle layer is circular, and the internal layer is oblique. At the pylorus, the middle layer is greatly thickened to form the **pyloric sphincter.**

The stomach is covered by a thin **serosa;** as it is an intraperitoneal organ. (Also called mesothelium)

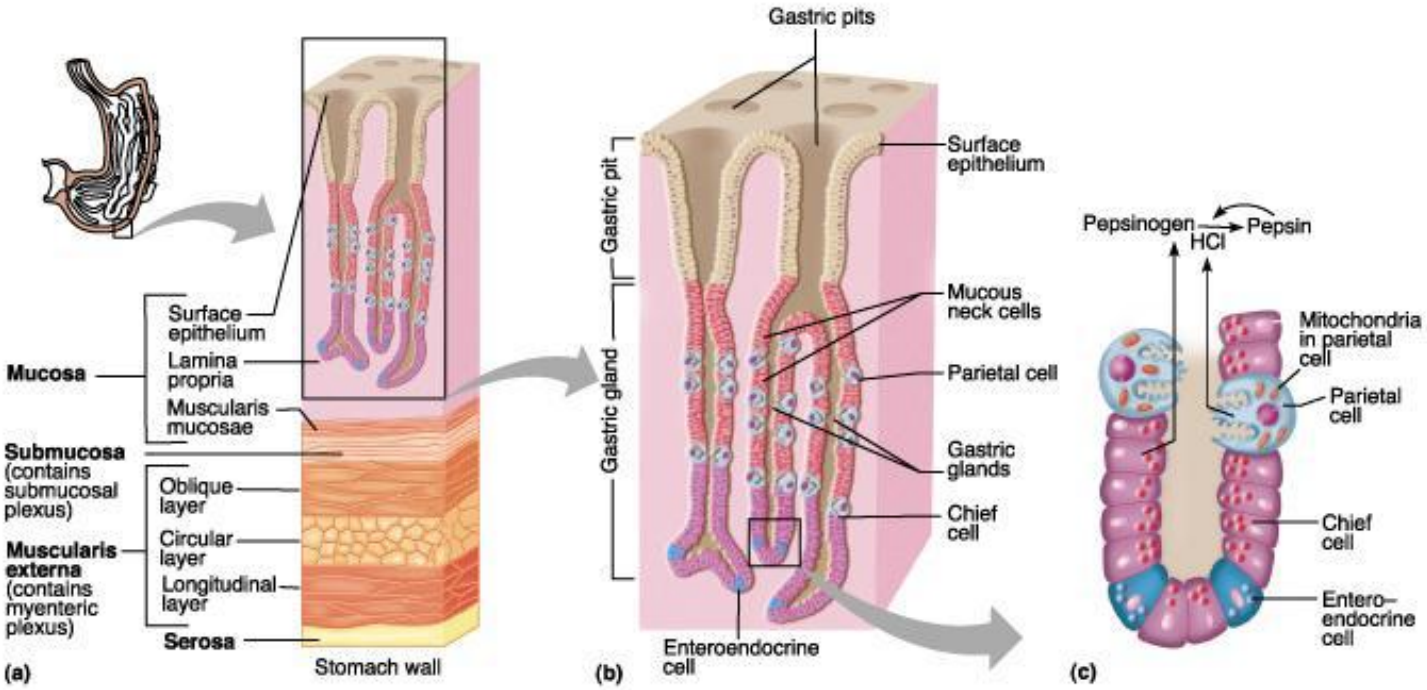

Small Intestine

-The small intestine is the site of terminal food digestion, nutrient absorption, and endocrine secretion; processes of digestion are completed in the small intestine, where the nutrients (products of digestion) are absorbed by cells of the epithelial lining.

The small intestine is relatively long (approximately 5m) and consists of three segments: the **duodenum**, **jejunum**, and **ileum.**

Duodenum is retroperitoneal (posterior abdominal wall) except for the first and last inches; it receives the pancreatic duct and the common bile duct. The posterior wall of duodenum is covered with adventitia, while the anterior wall is covered with serosa. The main function of jejunum and ileum is different, which is the absorption of nutrients. The jejunum and ileum are covered with serosa.

***Special features that increase the surface of the intestinal lining:**

1) The lining of the small intestine shows a series of permanent folds, **plicae circulares.** The plicae are most developed in, and consequently a characteristic of, the jejunum. Increases the surface for absorption.

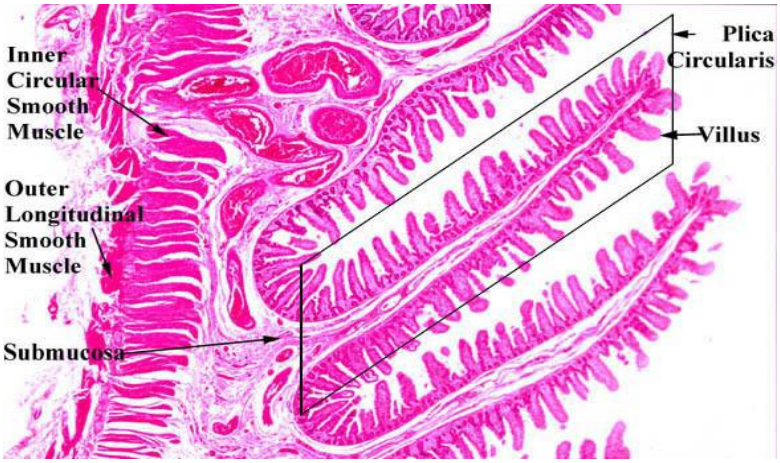

2) **Intestinal villi** are 0.5 to 1.5 mm long outgrowths of the mucosa (epithelium plus lamina propria) projecting into the lumen of the small intestine. In the duodenum they are leaf-shaped, gradually changing into

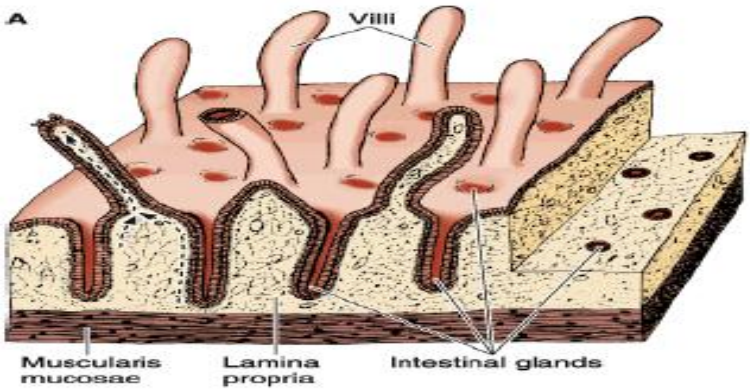

finger-like shapes as they reach the ileum.
Ileum submucosa contains Peyer's patches (lymphatic nodules) prominent and numerous in the ileum.

3) **Microvillus** is a cylindrical protrusion of the apical cytoplasm that is approximately 1 m tall by 0.1 m in diameter; consists of the cell membrane enclosing a core of actin microfilaments associated with other cytoskeletal proteins

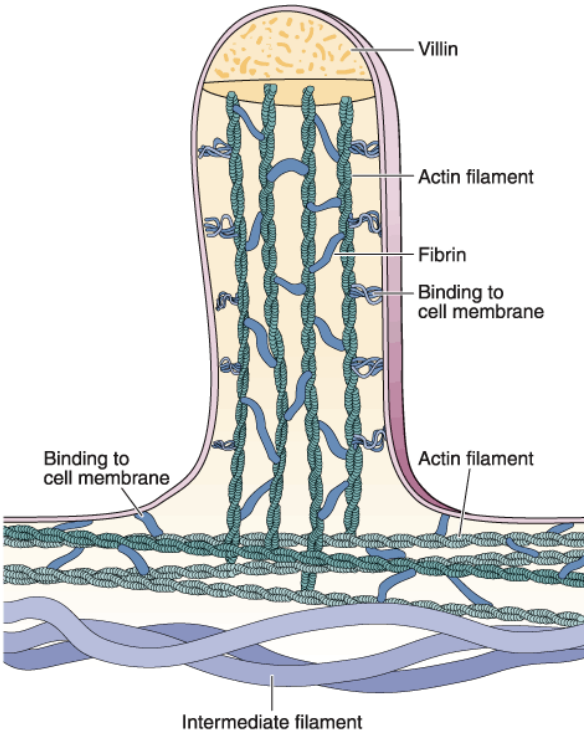

* The influence of each structure in increasing the surface area:

- Plicae increase the intestinal surface 3-fold.
- Villi increase it 10-fold.
- Microvilli increase it 20-fold.

Together, these processes are responsible for a 600-fold increase in the intestinal surface, resulting in a total area of 200 m^2 .

Intestinal glands and their cells:

Between the villi are small openings of simple tubular glands called **intestinal glands** (also called **crypts of Lieberkühn**). The epithelium of the villi is continuous with that of the glands; **simple columnar epithelium** (absorption) **with goblet cells**.

* The intestinal glands contain: **stem cells**, **absorptive cells**, **goblet cells**, **Paneth's cells**, and **enteroendocrine cells**. No parietal or chief

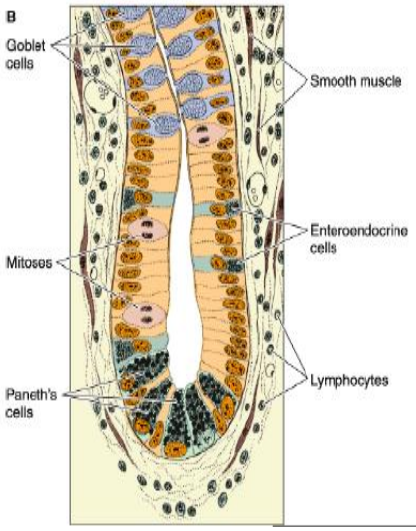

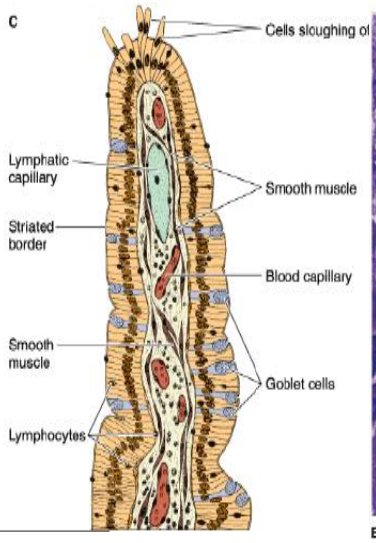

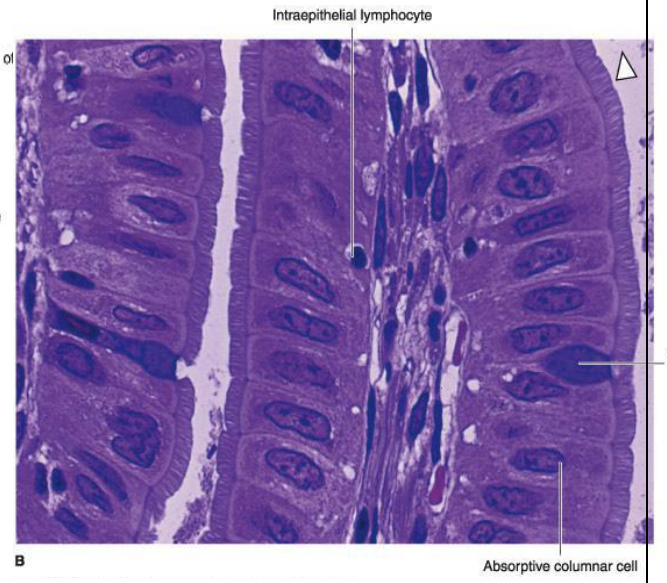

cells.

<u>Absorptive cells</u>: simple columnar cells, each with an oval nucleus in the basal half of the cell. At the apex of each cell is a homogeneous layer called the **striated (brush) border.** When viewed with the electron microscope, the striated border is seen to be a layer of densely packed **microvilli.**

[Each absorptive cell is estimated to have an average of 3000 microvilli, and 1 mm^2 of mucosa contains about 200 million of these structures]

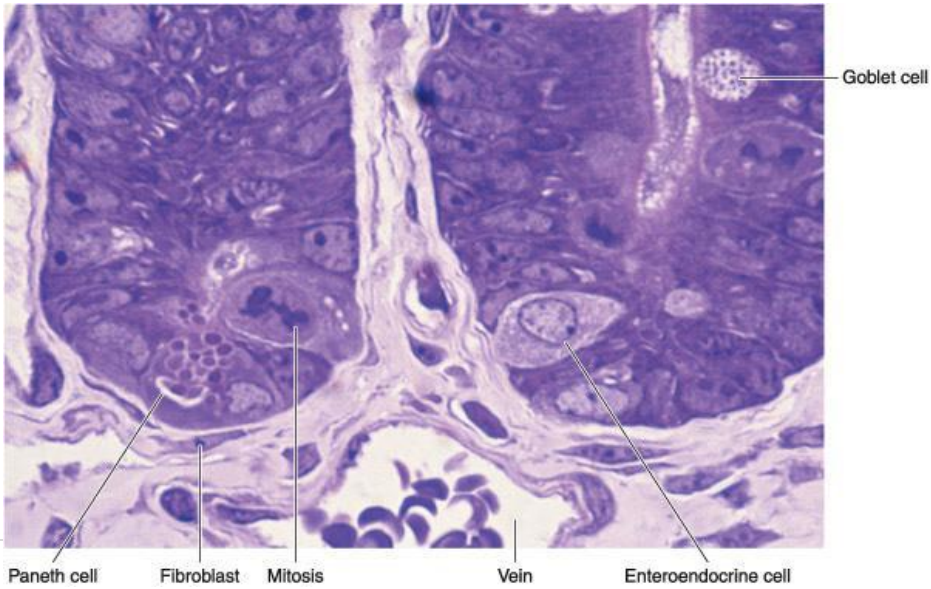

Goblet cells: are interspersed between the absorptive cells; increase in number as they approach the ileum. These cells produce acid glycoproteins of the mucin type to form mucus, whose main functions are to protect and lubricate the lining of the intestine, and help in dissolving food substances.

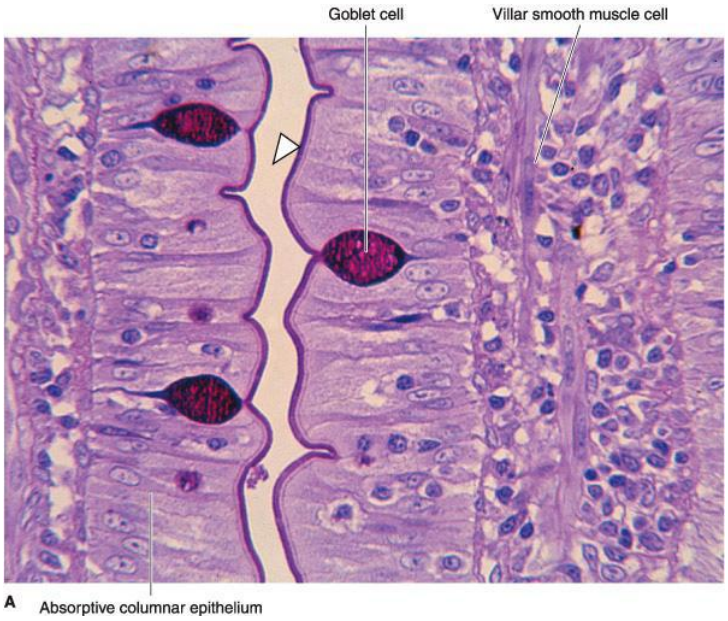

Paneth's cells: are exocrine cells with eosinophilic secretory granules in their apical cytoplasm; found in the **basal** portion of the intestinal glands; secrete Lysozyme which has antibacterial activity (by digesting the cell walls of some bacteria) and may play a role in controlling the intestinal flora.

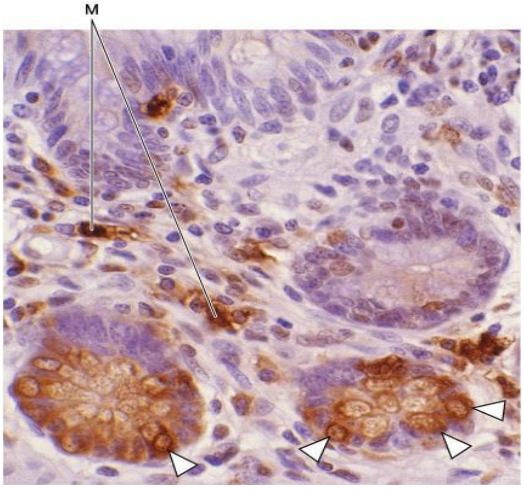

*We have already talked about stem cells and enteroendocrine cells.

Immunology of GI:

* The very large mucosal surface of the gastrointestinal tract is exposed to many potentially invasive microorganisms. So, it developed many defensive mechanisms:

a) Secretory immunoglobulins of the IgA are the first line of defense
b) Intercellular tight junctions that make the epithelial cells a barrier to the penetration of microorganisms

c) Antibody-secreting plasma cells, macrophages, and a very large number of lymphocytes located in both the mucosa and the submucosa. Together, these cells are called the **gut-associated lymphoid tissue (GALT)**.

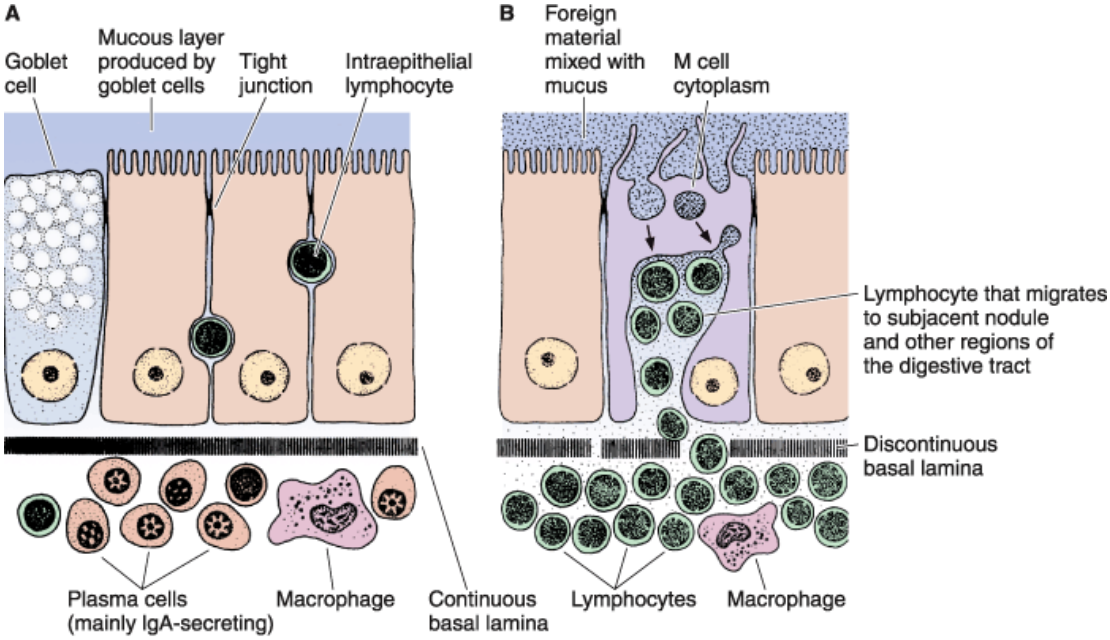

d) M (microfold) cells

Are specialized epithelial cells overlying the lymphoid follicles of Peyer's patches.

The presence of numerous basal membrane invaginations that form pits containing many intraepithelial lymphocytes and antigen-presenting cells (macrophage).

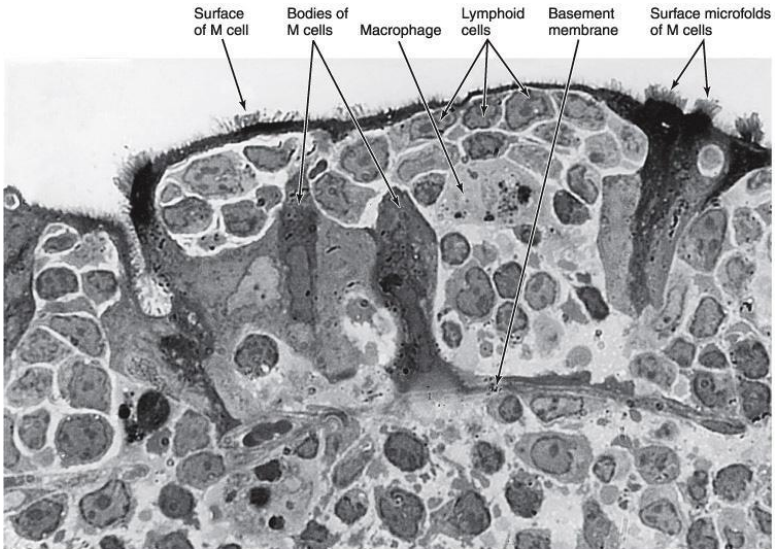

M cells can endocytose antigens and transport them to the underlying macrophages and lymphoid cells, which then migrate to other compartments of the lymphoid system (nodes). Basement membrane under M cells is discontinuous, facilitating transit between the lamina propria and M cells.

Remaining layers in small intestine

Lamina propria: Composed of loose connective tissue with blood and lymph vessels, nerve fibers, and smooth muscle cells. The lamina propria penetrates the core of the intestinal villi.

Muscularis mucosae: Smooth muscle cells are responsible for the rhythmic movements of the villi, which are important for absorption; this movement is the result of the contraction of smooth muscle cells running vertically between the muscularis mucosae and the tip of the villi. These contractions occur at the rate of several strokes per minute and have a pumping action on the villi that propels the lymph to the mesenteric lymphatics.

*The only organs in the GIT with glands in their submucosa are the duodenum and the esophagus. In the duodenum, these glands are **Brunner's glands** (or duodenal glands)**.** The product of secretion of the glands is distinctly alkaline (pH 8.1–9.3), acting to protect the duodenal mucous membrane from the effects of the acid gastric juice and to bring the intestinal contents to the optimum pH for pancreatic enzyme action.

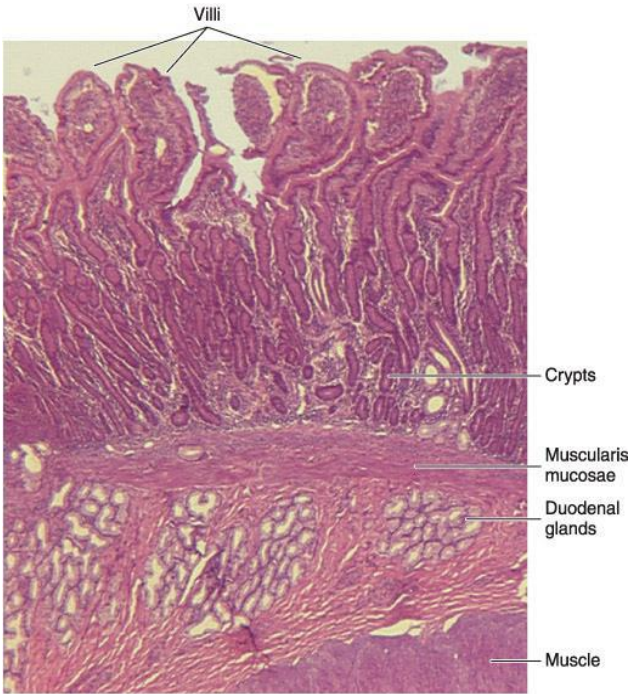

* The lamina propria and the submucosa of the small intestine contain aggregates of lymphoid nodules known as **Peyer's patches,** an important component of the GALT; they form an important part of the immune system by monitoring intestinal bacteria populations and preventing the growth of pathogenic bacteria in the intestines. Each patch consists of 10–200 nodules and is visible to the naked eye as an oval area on the antimesenteric side of the intestine. There are about 30 patches in humans, most of them in the ileum. Instead of absorptive cells, its covering epithelium consists of **M cells.**

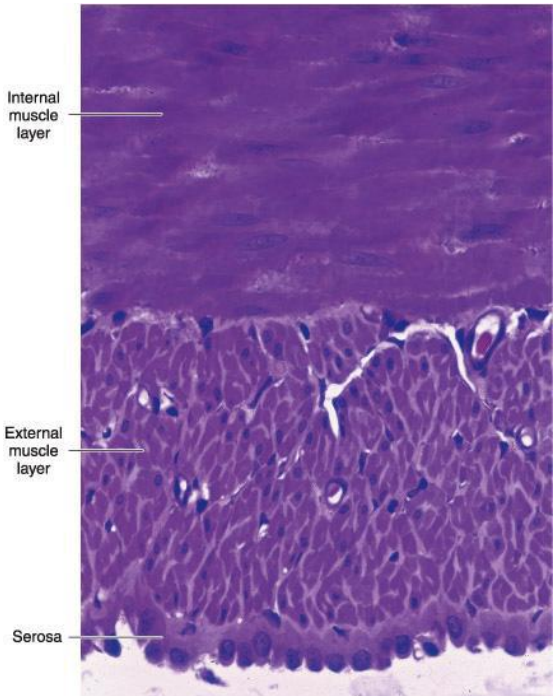

Muscularis externa: is well developed in the intestines, composed of an internal circular layer and an external longitudinal layer. In between them, there is the **myenteric plexus** (or **Auerbach's plexus**).

The surface area of the small intestine is around 200m^2 with microvilli, villi, plicae circulares contributing to this huge surface area.

Vessels and Nerves of small intestine

The blood vessels that nourish the intestine and remove absorbed products of digestion penetrate the muscularis and form a large plexus in the submucosa. From the submucosa, branches extend through the muscularis mucosae and lamina propria and into the villi.

Each villus receives, according to its size, one or more branches that form a capillary network just below its epithelium.

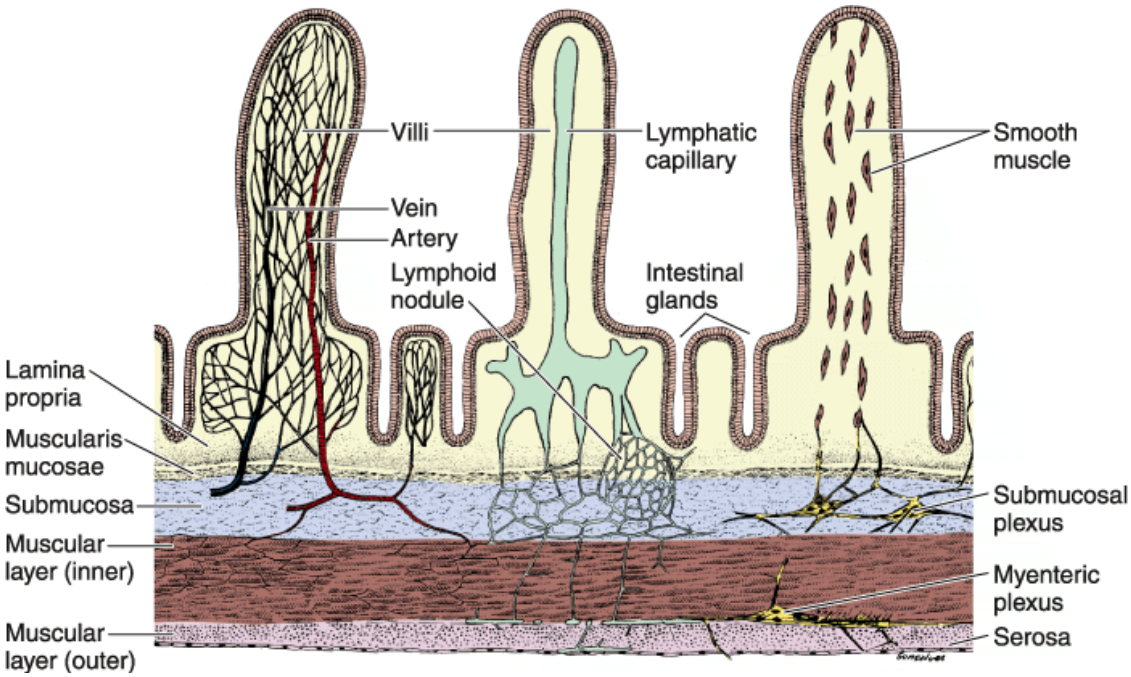

Lacteals (i.e. blind-ended lymphatic vessels of the small intestine which absorb digested fats) run to the region of lamina propria above the muscularis mucosae, where they form a plexus. From there they are directed to the submucosa, where they surround lymphoid nodules. Lacteals anastomose repeatedly and leave the intestine along with the blood vessels. They are especially important for the absorption of lipids, because blood circulation does not easily accept the lipoproteins produced by the absorptive cells during this process.

Nerve supply: The innervation of the intestines is formed by both an **intrinsic component** and an **extrinsic component.**

The **intrinsic component** comprises groups of neurons that form the **myenteric (Auerbach's) nerve plexus** between the outer longitudinal and inner circular layers of the muscularis and the **submucosal (Meissner's) plexus** in the submucosa.

*The plexuses contain some sensory neurons that receive information from nerve endings near the epithelial layer and in the smooth muscle layer regarding the composition of the intestinal content (chemoreceptors) and the degree of expansion of the intestinal wall (mechanoreceptors). The other nerve cells are effectors and innervate the muscle layers and hormone-secreting cells.

The **extrinsic innervation** is formed by parasympathetic cholinergic nerve fibers that stimulate the activity of the intestinal smooth muscle and by sympathetic adrenergic nerve fibers that depress intestinal smooth muscle activity.

* The intrinsic innervation formed by these plexuses is responsible for the intestinal contractions that occur in the total absence of the extrinsic innervation.

-The doctor did not explain the intrinsic and extrinsic innervations, but they are found in the slides.

★ The end of slide 2 histology of GI

Large intestine

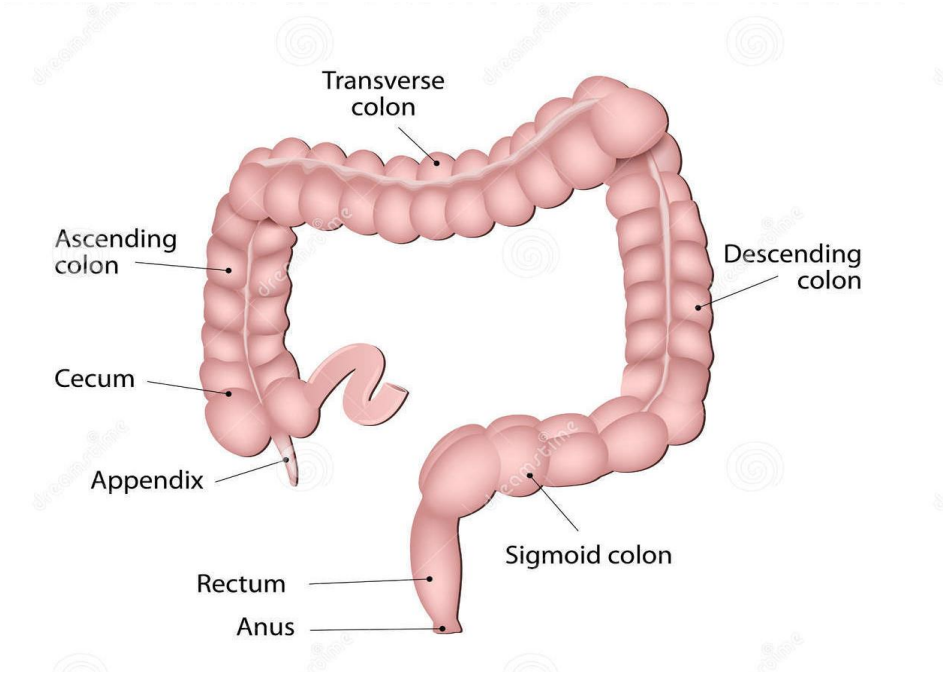

The large intestine consists of a mucosal membrane with no folds except in its distal (rectal) portion.

No villi are present.

The intestinal glands are long and characterized by a great abundance of goblet and absorptive cells and a small number of enteroendocrine cells.

The absorptive cells are columnar and have short, irregular microvilli.

The large intestine is well suited to its main functions: absorption of water, formation of the fecal mass, and production of mucus.

Mucus is a highly hydrated gel that not only lubricates the intestinal surface but also covers bacteria and particulate matter.

The absorption of water is passive, following the active transport of sodium out of the basal surfaces of the epithelial cells.

The lamina propria is rich in lymphoid cells and in nodules that frequently extend into the submucosa. This richness in lymphoid tissue (GALT) is related to the abundant bacterial population of the large intestine.

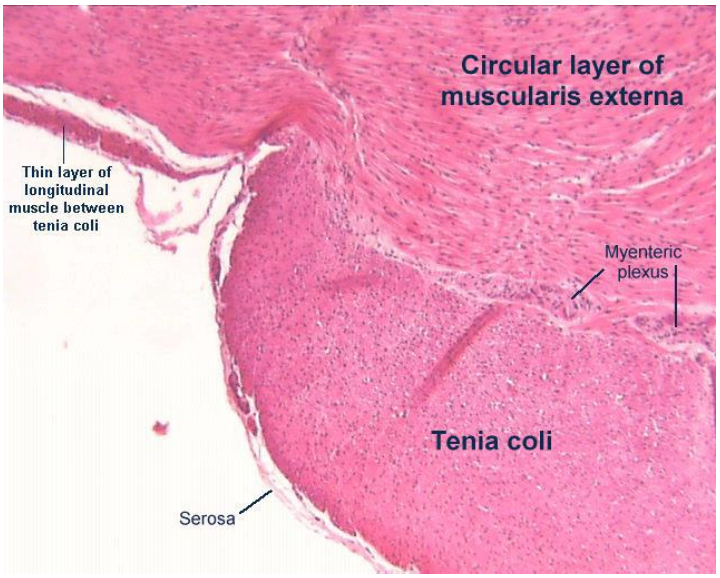

The muscularis comprises longitudinal and circular strands. This layer differs from that of the small intestine, because fibers of the outer longitudinal layer congregate in three thick longitudinal bands called **teniae coli.** In the intraperitoneal portions of the colon, the serous layer is characterized by small, pendulous protuberances composed of adipose tissue—the **appendices epiploicae.**

*Sacculation (sac formation): gives the colon its segmented appearance. Helps in absorption and feces formation. The **teniae coli** run the length of the large intestine. Because the teniae coli are shorter than the intestine, the colon becomes sacculated between the teniae coli.

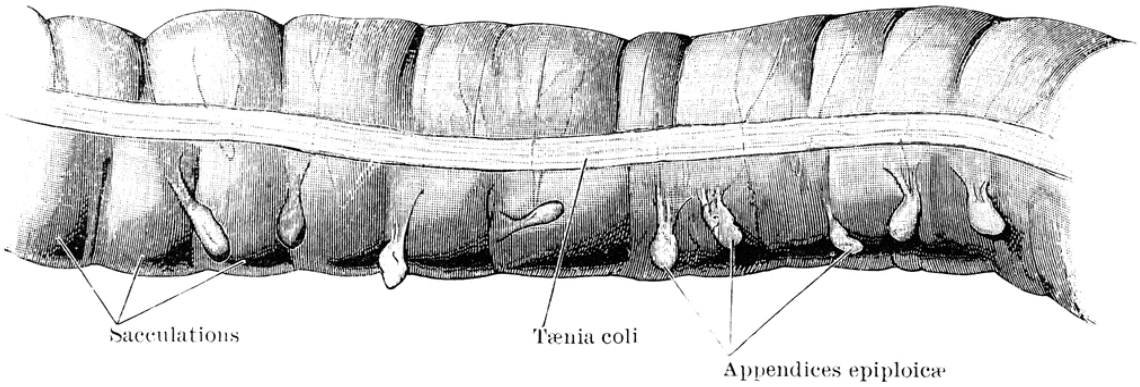

Differences between the small and large intestine

Small intestine	Large intestine
Quite long	Relatively shorter
Internal surface has folds or plicae circulares	Folds are absent
Villi are present	Villi are absent
Crypts with Paneth's cells	Crypts with no Paneth's cells
Simple columnar epithelium with goblet cells	Simple columnar epithelium with more abundance of goblet cells
No longitudinal bands	Teniae coli are present, sacculation
Digestion is complicated	No role in digestion, just absorption of water

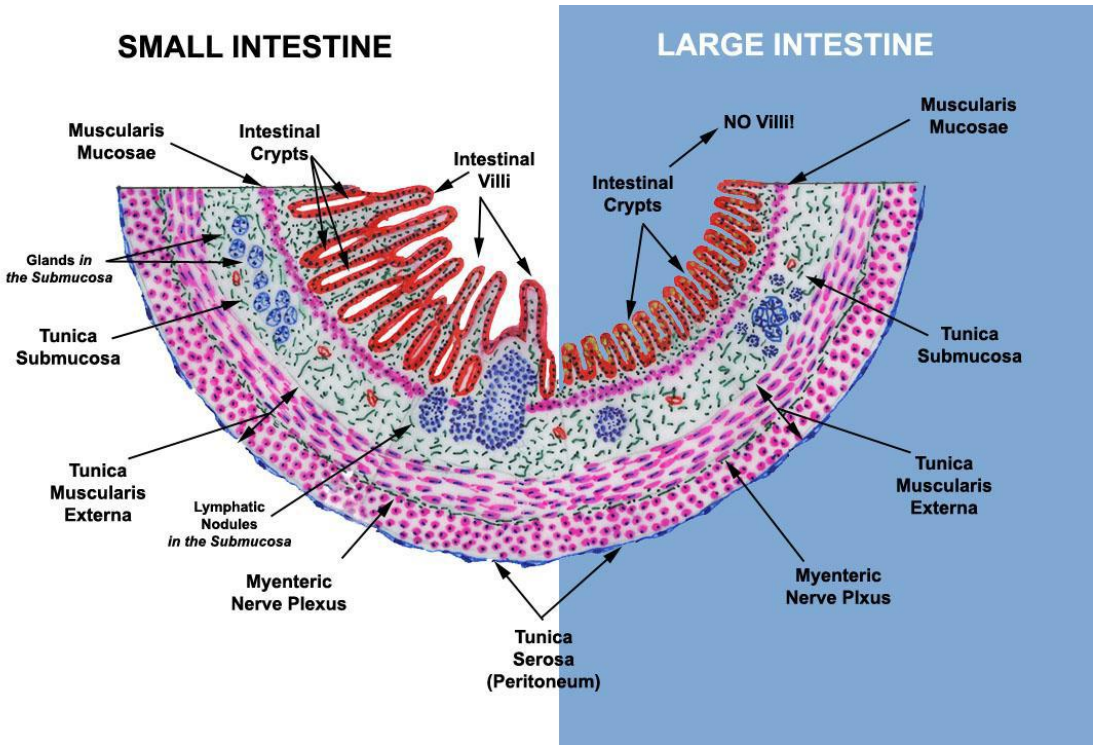

Anal canal

In the anal region, the mucous membrane forms a series of longitudinal folds, the **rectal columns of Morgagni.**

These anal columns connect to the anal orifice to form the anal **valves** and **sinuses**.

About 2 cm above the anal opening, the intestinal mucosa is replaced by <u>stratified squamous epithelium.</u>

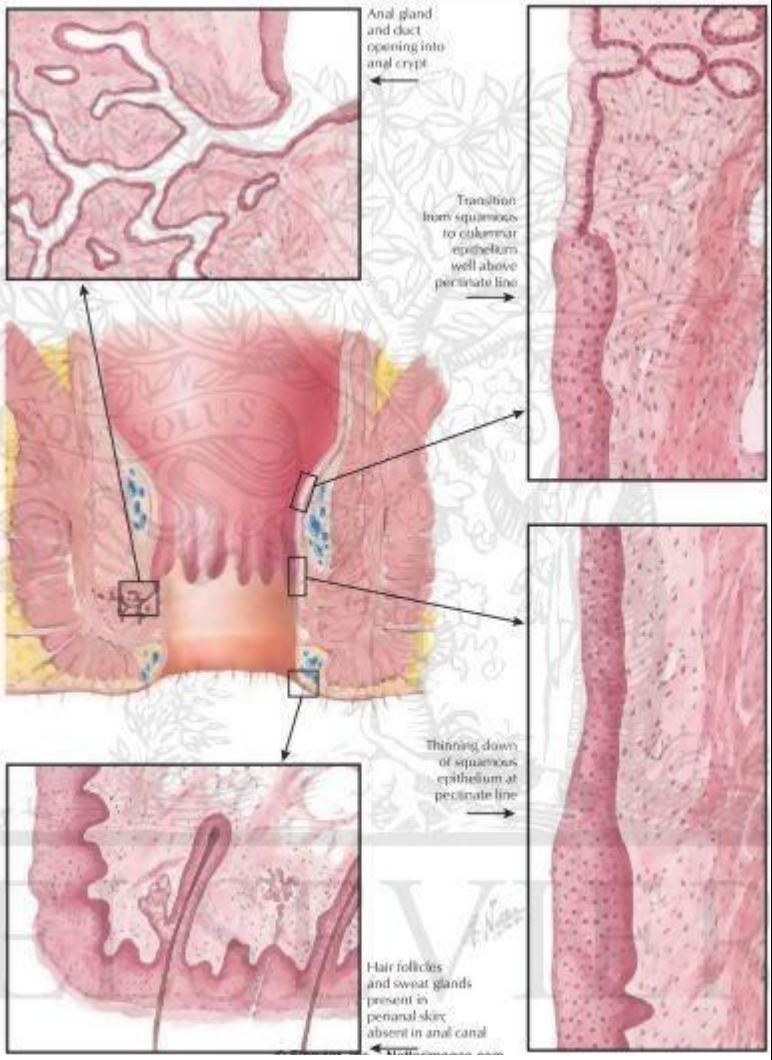

The muscularis layer gives rise to the anal sphincter

The adventitia layer connects the anal canal to the surrounding structures.

- Anal canal (upper half) ⟶ simple columnar with goblet cells epithelium. (Autonomic, for stretching only)
- Anal canal (lower half) ⟶ stratified squamous non-keratinized epithelium. (Pain sensation)

Separated by pectinate line

- Anal orifice ⟶ stratified squamous keratinized (skin) with hair follicles and sebaceous glands.

*Rectum: simple columnar epithelium with goblet cells.

Appendix

A lymphatic organ (GALT).

The appendix is an evagination of the cecum.

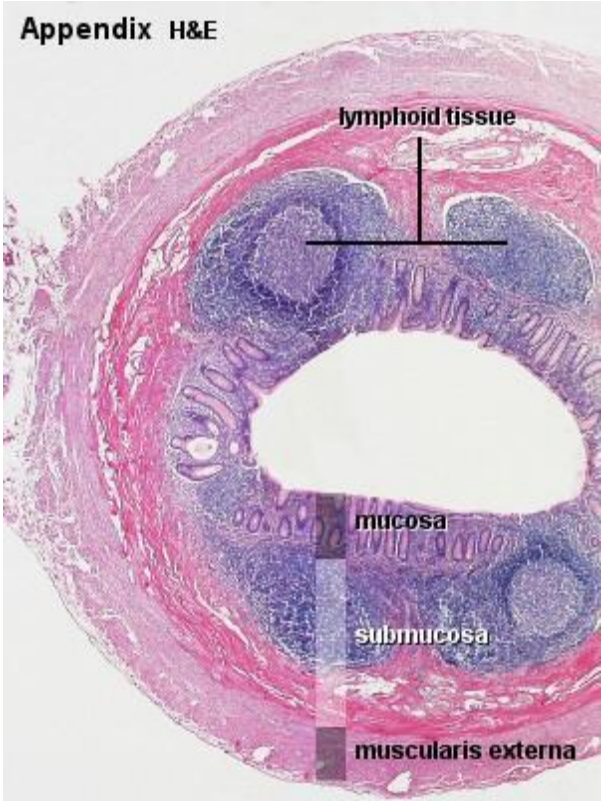

Is characterized by a relatively small, narrow, and irregular lumen.

Presence of abundant **lymphoid follicles** in its wall, which form a circular layer in the mucosa and may infiltrate the submucosa.
*Crypts of Lieberkühn are minimally present in the mucosa, because they have no role.

Although its general structure is similar to that of the large intestine (same epithelium), it contains fewer and shorter intestinal glands and has no teniae coli.

Covered entirely by serosa (mesoappendix) delivers the appendicular vein, artery and nerve.

If inflamed, the lumen collapses because it's very narrow, and it gets congested with blood. The treatment is appendectomy, in order not to rupture and cause peritonitis.

Cell Renewal in the GIT

The epithelial cells of the entire gastrointestinal tract are constantly being cast off and replaced with new ones formed through mitosis of stem cells.

These **stem cells** are located in the basal layer of the esophageal epithelium, the neck of gastric glands, the lower half of the intestinal glands and the bottom third of the crypts of the large intestine.

From this proliferative zone in each region, cells move to the maturation area, where they undergo structural and enzymatic maturation, providing the functional cell population of each region.

In the small intestine the cells die by apoptosis in the tip of the villi or are sloughed off by mechanical action during function.

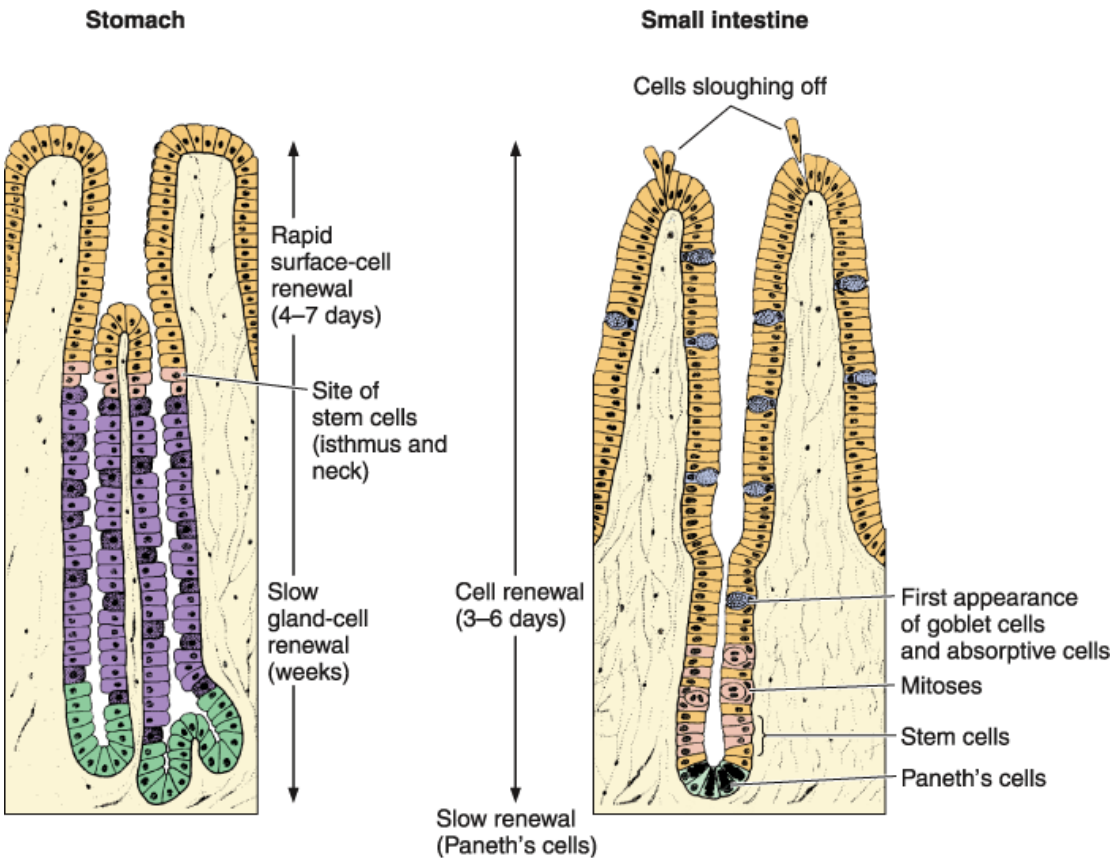

Best of Luck