Metabolism of Sphingolipids

Sphingophospholipids
Glycosphingolipids

Faisal Khatib MD; PhD

Faculty of Medicine, University of Jordan

Sphingosine; Amino Alchol

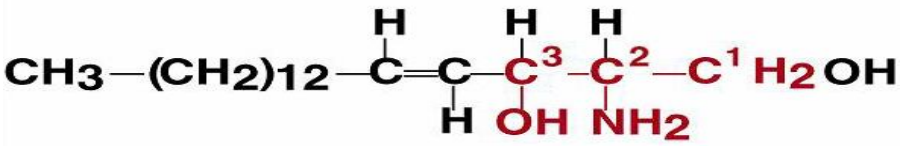

Sphingosine

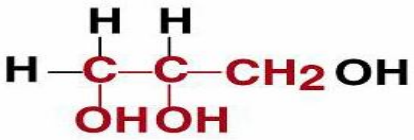

Glycerol

Sphingosine; Amino Alchol

HO-**C**H-**C**H=**C**H-(**C**H$_2$)$_{12}$**C**H$_3$
|
CH-NH$_2$
|
CH$_2$-OH

Ceramide: Fatty Acid to joined to Sphingosine

HO-**C**H-**C**H=**C**H-(**C**H$_2$)$_{12}$**C**H$_3$
|
CH-NH-**C**(=O)-(**CH$_2$)$_n$-CH$_3$**
|
CH$_2$-OH

Sphingomyelin is Phosphocholine Ester of Ceramide

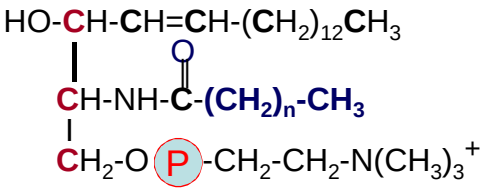

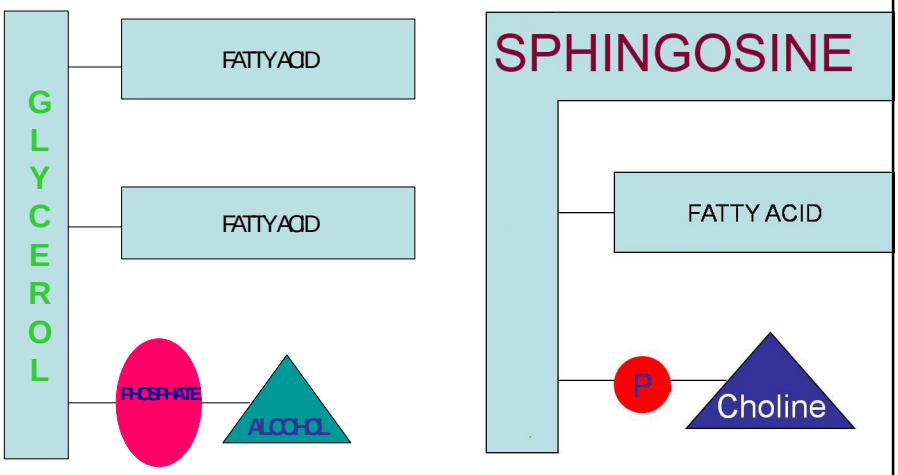

PHOSPHOACYLGLYCEROL **Sphingophospholipids**

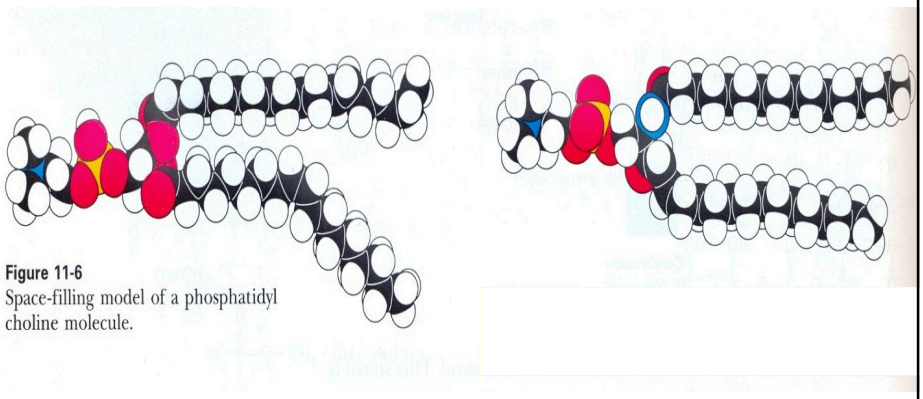

Figure 11-6
Space-filling model of a phosphatidyl choline molecule.

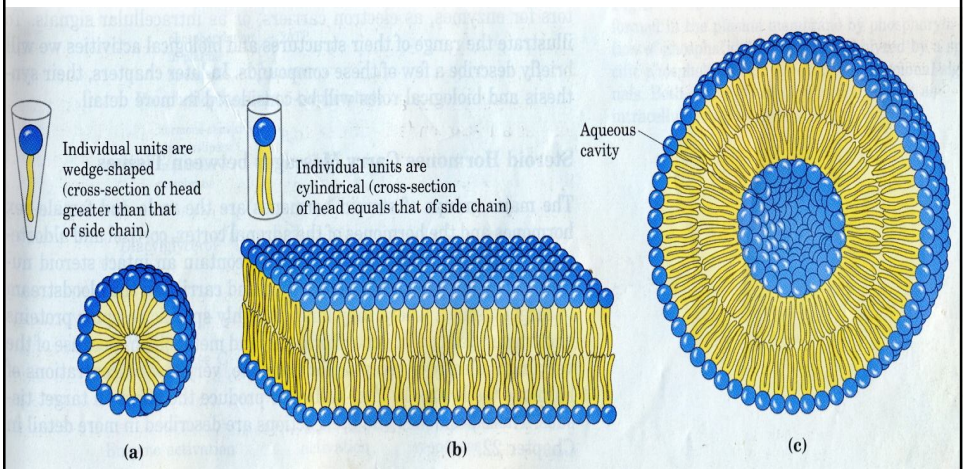

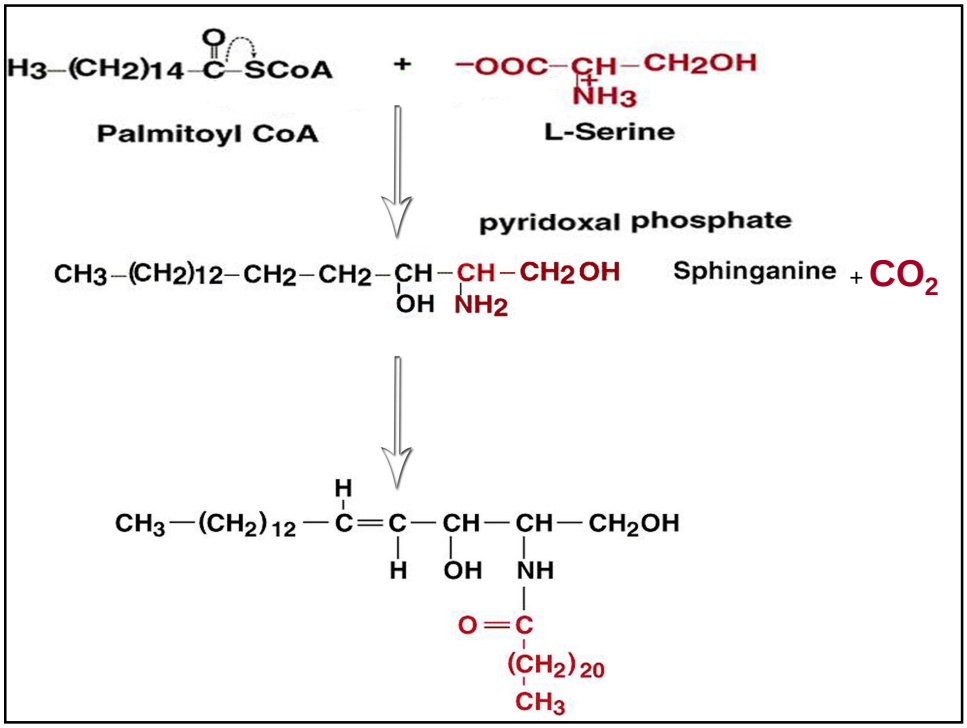

Transfer Of Phosphocholine to Ceramide Produces Sphingomylein

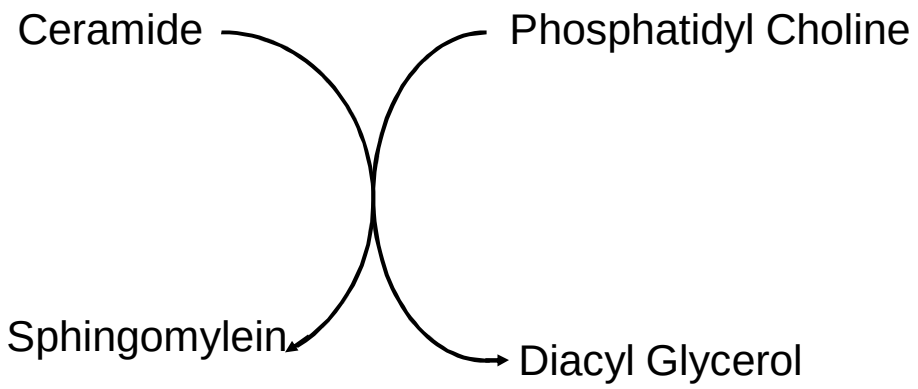

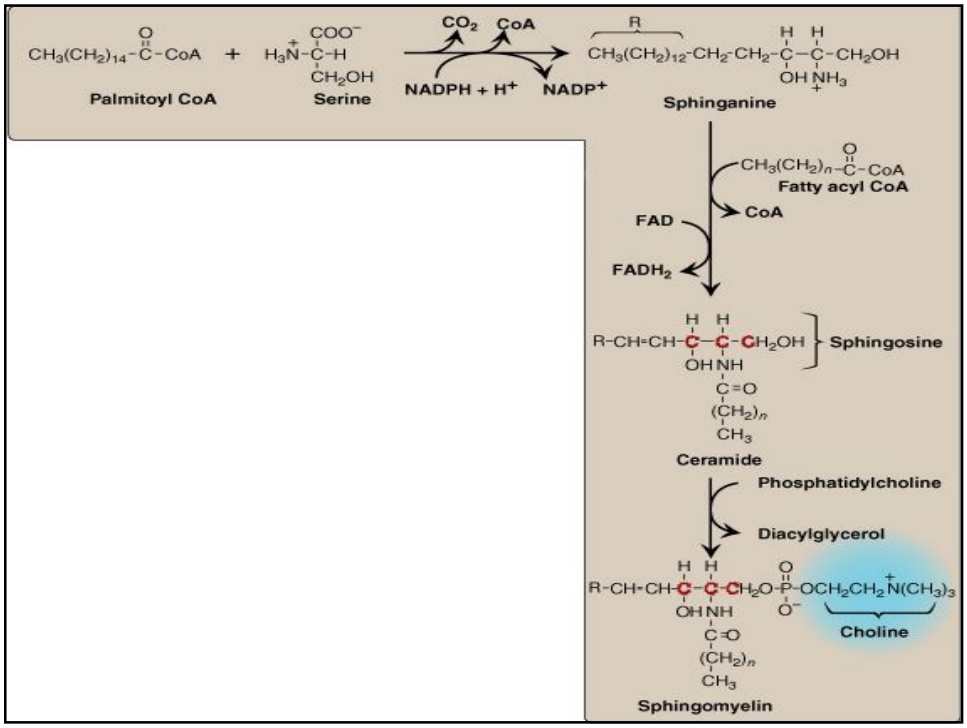

Glycolipids are Formed by Linking one or More Sugars to Ceramide

Ceramide +

-Glucose or Galactose => Cerebroside

-Sulfated Galactose => Sulfoglycosphingolipids

-Oligosaccharide => Globoside

-Oligosaccharide with NANA => Gangliosides

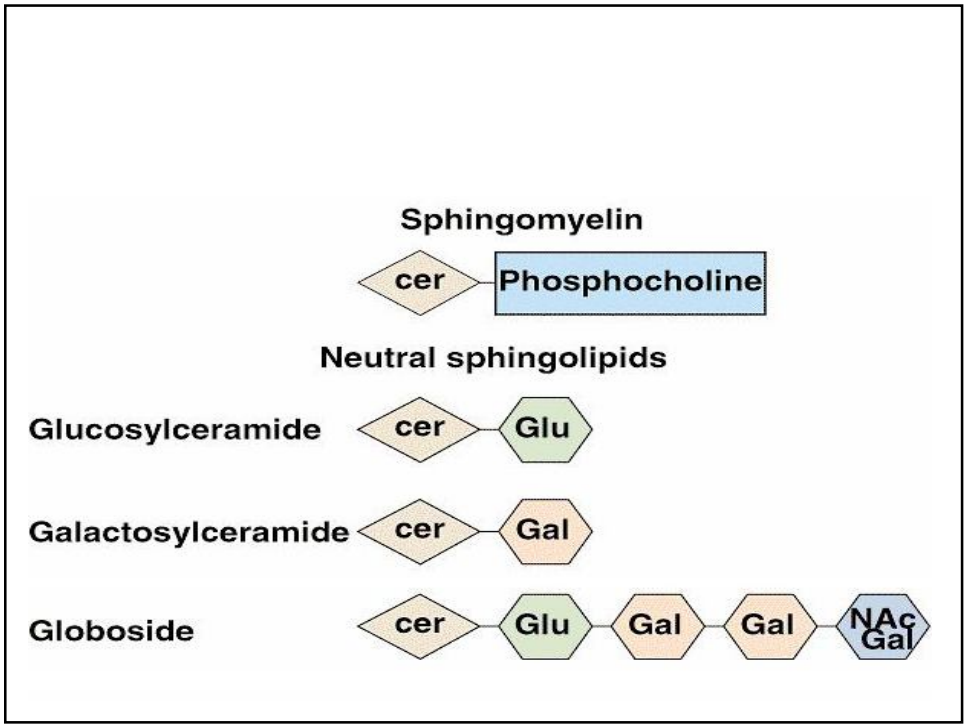
Sphingomyelin
cer
Phosphocholine
Neutral sphingolipids
Glucosylceramide
cer
Glu
Galactosylceramide
cer
Gal
Globoside
cer
Glu
Gal
Gal
NAc
Gal

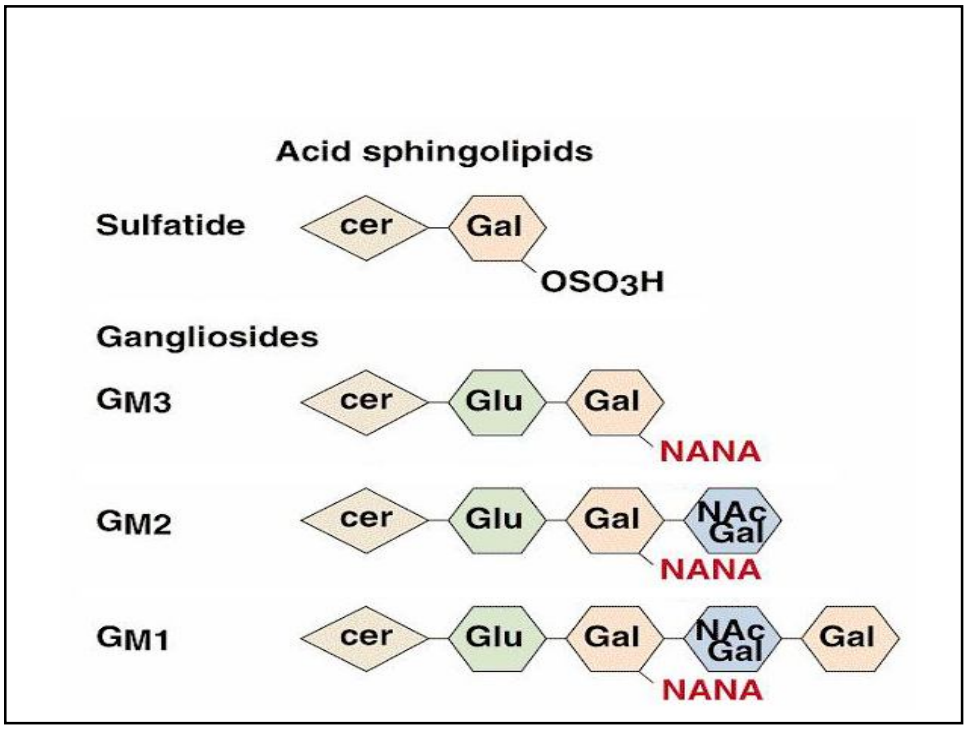
Acid sphingolipids
Sulfatide
cer
Gal
OSO3H
Gangliosides
GM3
cer
Glu
Gal
NANA
GM2
cer
Glu
Gal
NAc
Gal
NANA
GM1
cer
Glu
Gal
NAc
Gal
Gal
NANA

Activated Donors in Glycolipids Synthesis

- UDP-**Glucose**
- UDP-**Galactose**
- UDP-**N-Acetylgalctoseamine**
- CMP- **N-Acetylneuraminic Acid**

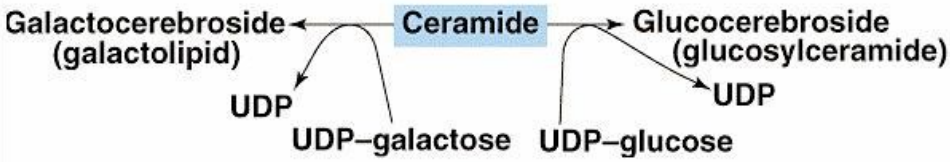

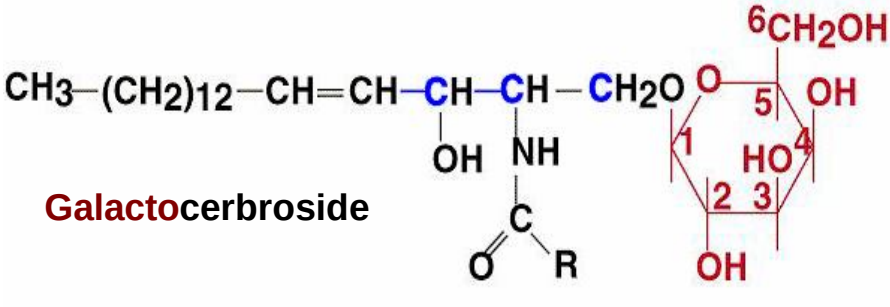

Galactocerbroside

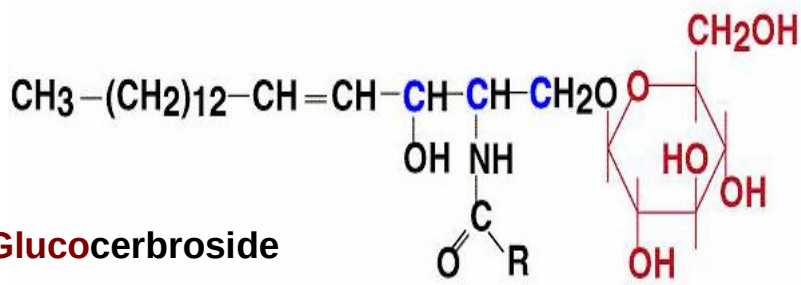

Glucocerbroside

Transfer of Sulfate Group to Galactocerbroside Produces **Sulfogalatocerbroside** (Sulfatide)

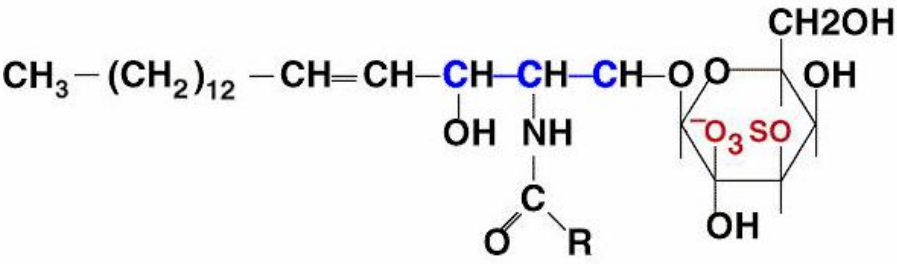

Sulfate Group Donor

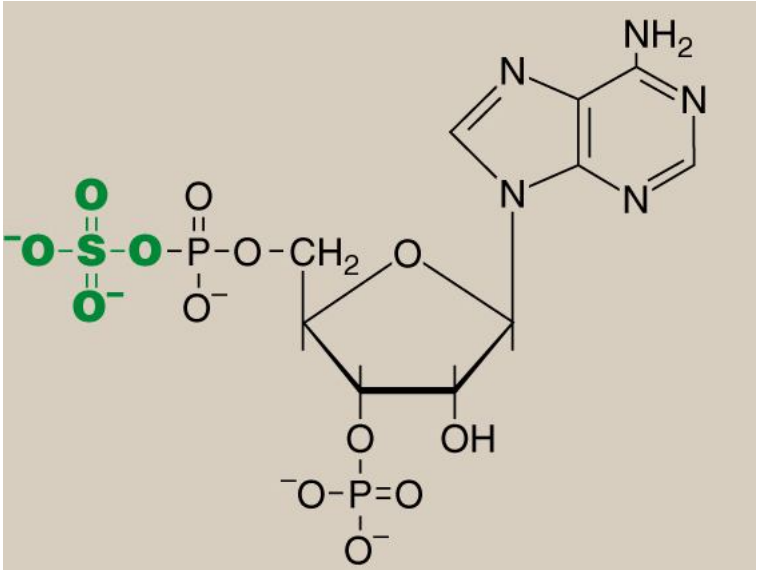

3 Phosphoadenosine 5 Phosphosulfate PAPS

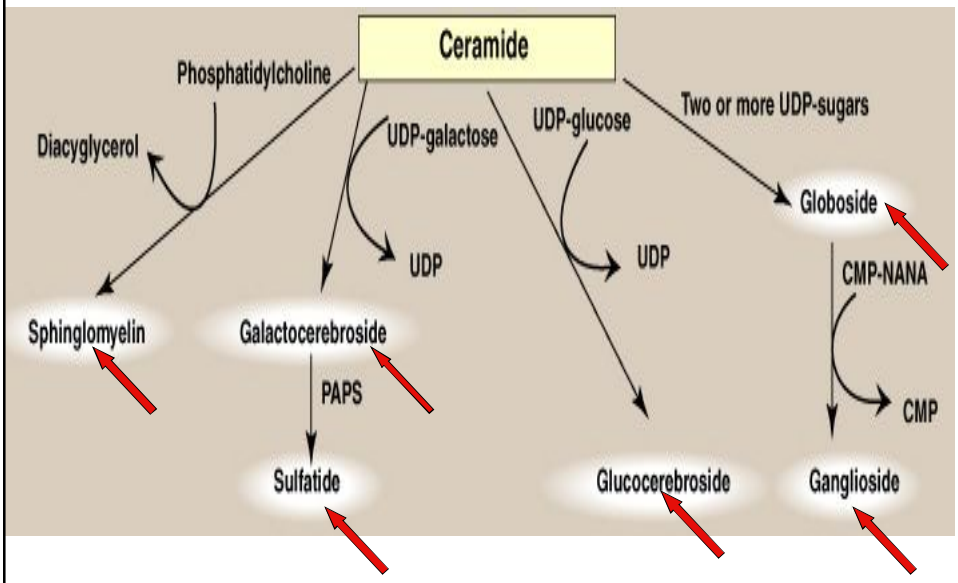

Degradation of Sphingolipids

- Hydrolytic Enzymes, Specific for the Sugar
- - α Galactosidase
  - β Galactosidase
  - neuraminidase
  - Hexoaminidase
- In Lysosomes
- Enzymes are firmly Bound to Lysosomal Membrane.
- The pH Optimum 3.5-5.5
- Stepwise Sequential Process
- "Last on, First off"

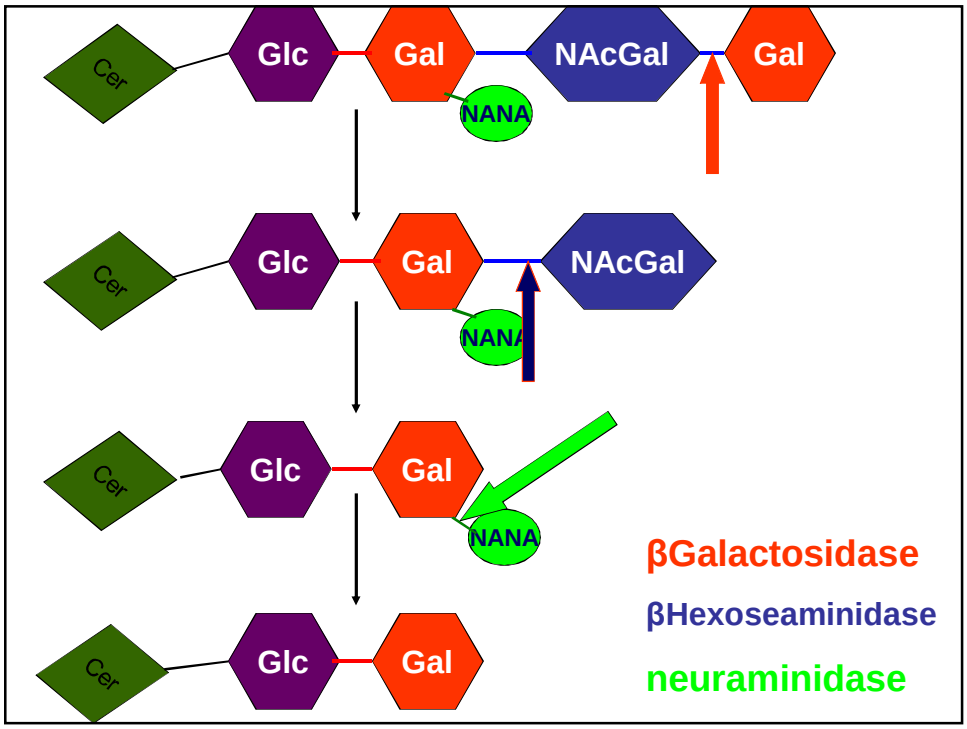

Sphingolipidoses

- **Lipid Storage Diseases**
- **Defect in one of the Enzyme**
- **Inherited as Autosomal RecessiveDisease**
- **Accumalation of Specific Lipid**

  Substrate of the Defective Enzyme
- **Brain is Mostly Affected.**
- **Extent of Enzyme deficiency is the same in Different Tissues.**

Degradation of Sphingomyelin

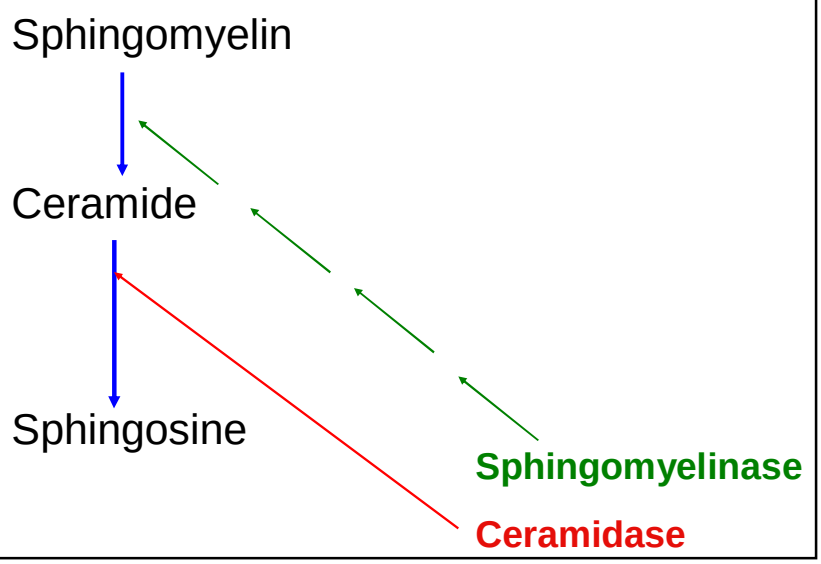

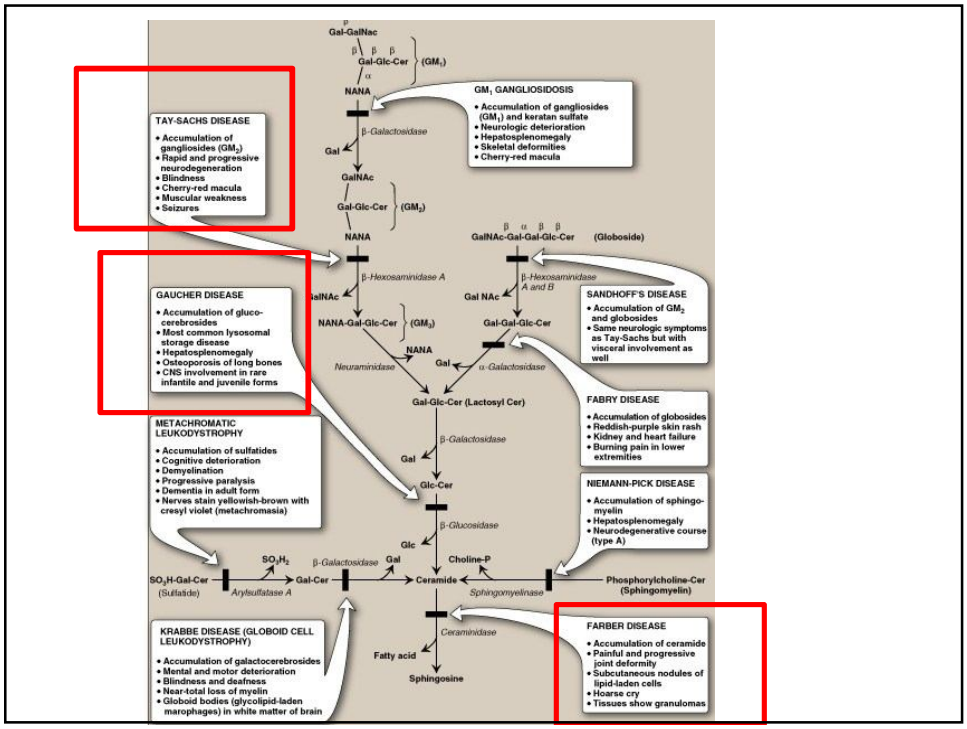
Gal-GalNac
Gal-Glc-Cer
(GM1)
NANA
β-Galactosidase
Gal
GalNAc
Gal-Glc-Cer
(GM2)
NANA
GalNAc-Gal-Gal-Glc-Cer
(Globoside)
β-Hexosaminidase A
β-Hexosaminidase A and B
Gal NAc
NANA-Gal-Glc-Cer
(GM3)
Gal-Gal-Glc-Cer
NANA
Neuraminidase
Gal
α-Galactosidase
Gal-Glc-Cer (Lactosyl Cer)
β-Galactosidase
Gal
Glc-Cer
β-Glucosidase
Glc
Gal
Choline-P
SO3H2
β-Galactosidase
SO3H-Gal-Cer
(Sulfatide)
Arylsulfatase A
Gal-Cer
Ceramide
Sphingomyelinase
Phosphorylcholine-Cer
(Sphingomyelin)
Ceraminidase
Fatty acid
Sphingosine
TAY-SACHS DISEASE
• Accumulation of gangliosides (GM2)
• Rapid and progressive neurodegeneration
• Blindness
• Cherry-red macula
• Muscular weakness
• Seizures
GM1 GANGLIOSIDOSIS
• Accumulation of gangliosides (GM1) and keratan sulfate
• Neurologic deterioration
• Hepatosplenomegaly
• Skeletal deformities
• Cherry-red macula
GAUCHER DISEASE
• Accumulation of gluco-cerebrosides
• Most common lysosomal storage disease
• Hepatosplenomegaly
• Osteoporosis of long bones
• CNS involvement in rare infantile and juvenile forms
SANDHOFF'S DISEASE
• Accumulation of GM2 and globosides
• Same neurologic symptoms as Tay-Sachs but with visceral involvement as well
FABRY DISEASE
• Accumulation of globosides
• Reddish-purple skin rash
• Kidney and heart failure
• Burning pain in lower extremities
METACHROMATIC LEUKODYSTROPHY
• Accumulation of sulfatides
• Cognitive deterioration
• Demyelination
• Progressive paralysis
• Dementia in adult form
• Nerves stain yellowish-brown with cresyl violet (metachromasia)
NIEMANN-PICK DISEASE
• Accumulation of sphingo-myelin
• Hepatosplenomegaly
• Neurodegenerative course (type A)
KRABBE DISEASE (GLOBOID CELL LEUKODYSTROPHY)
• Accumulation of galactocerebrosides
• Mental and motor deterioration
• Blindness and deafness
• Near-total loss of myelin
• Globoid bodies (glycolipid-laden marophages) in white matter of brain
FARBER DISEASE
• Accumulation of ceramide
• Painful and progressive joint deformity
• Subcutaneous nodules of lipid-laden cells
• Hoarse cry
• Tissues show granulomas