Interior of right Atrium

- Receives venous blood from whole body by
  1. SVC from upper 1/2.
  2. IVC from lower 1/2.
  3. Coronary sinus (coronary vein) from the heart itself.
- Send blood to right ventricle by Tricuspid valve.

Has 2 walls:

- Anterior wall, rough.
  - Pectinate muscles.
  - Crista terminalis.
- Posterior wall, smooth
  - Fossa ovalis.
  - SA Node.

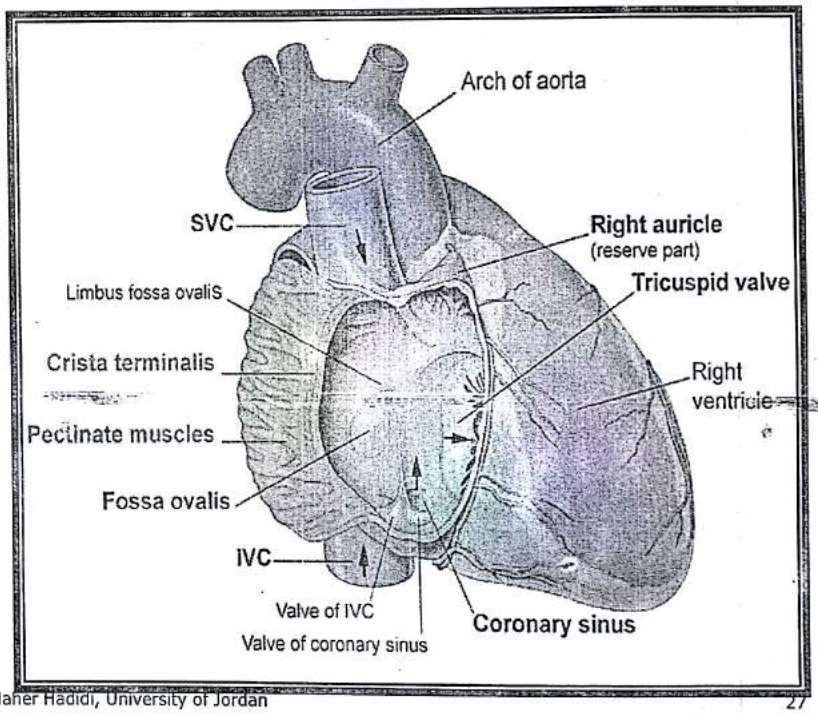

Interior of right Ventricle-1

- Receives blood by **T**ricuspid valve.
- Send blood to both lungs via **P**ulmonary valve.
- Wall thicker than right atrium.

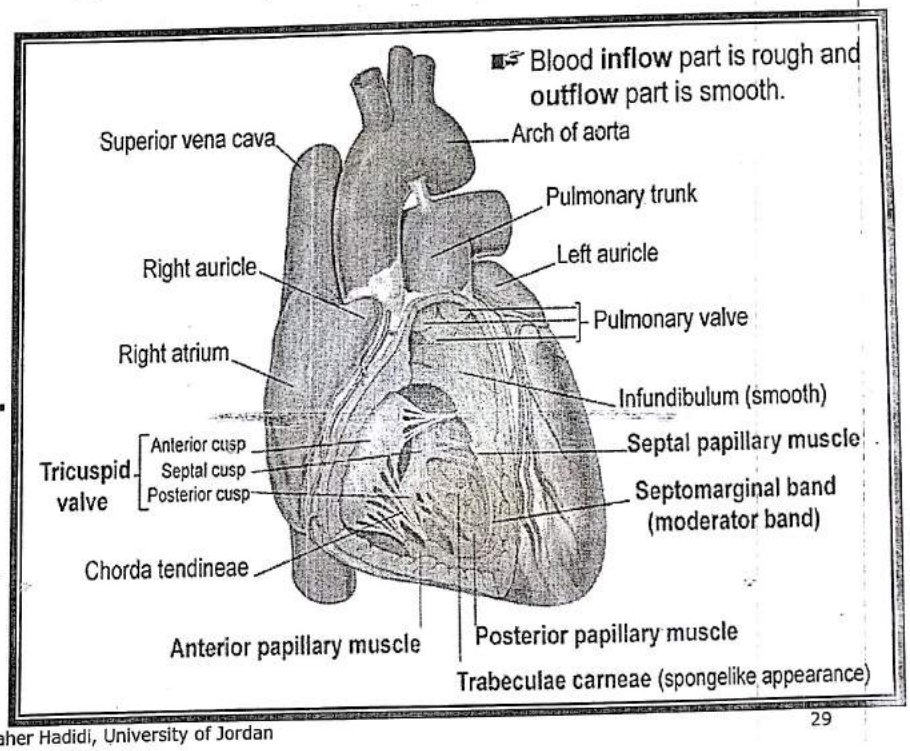

Interior of right Ventricle-2

Has 2 walls:

- Anterior wall (inflow part).
  Rough with a network of projecting cardiac muscle bundles. e.g.
  - Papillary muscles.
  - Septomarginal band.
- Posterior wall, (outflow part) mostly rough and smooth in part. e.g.
  - Infundibulum of pulmonary artery.

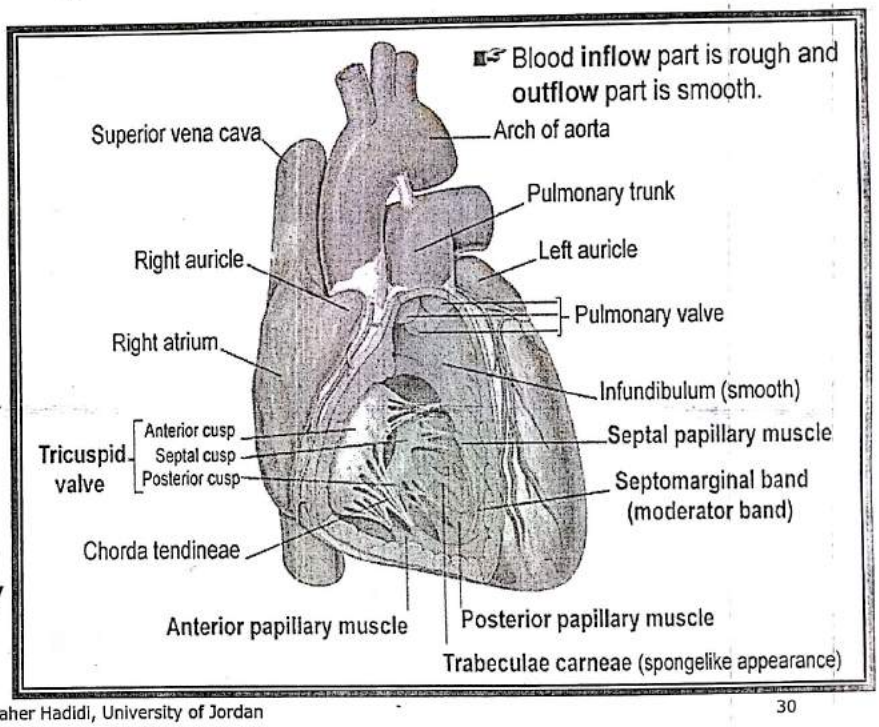

Left atrium

- Form base of the heart.
- Receive blood by:
  4 pulmonary veins.
- Send blood by: Bicuspid valve to the left ventricle.

- **Ant. Wall:** Rough, especially its auricle.

- **Post. Wall:** Smooth.

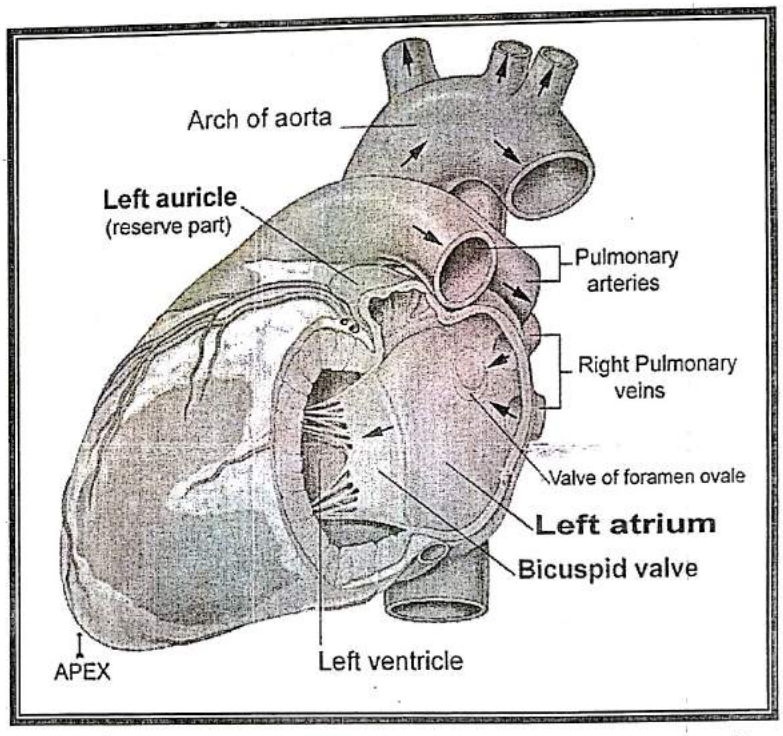

Left ventricle

- Main chamber of the heart.
- Form apex of the heart.
- Receive blood by: Bicuspid valve
- Send blood by: Aortic valve.

- Has thicker wall.
- **Ant. Wall** (septum): Smooth in part.
  - Aortic vestibule.
- **Post. Wall:** Rough.
  - Trabeculae carneae.
  - Papillary muscles.

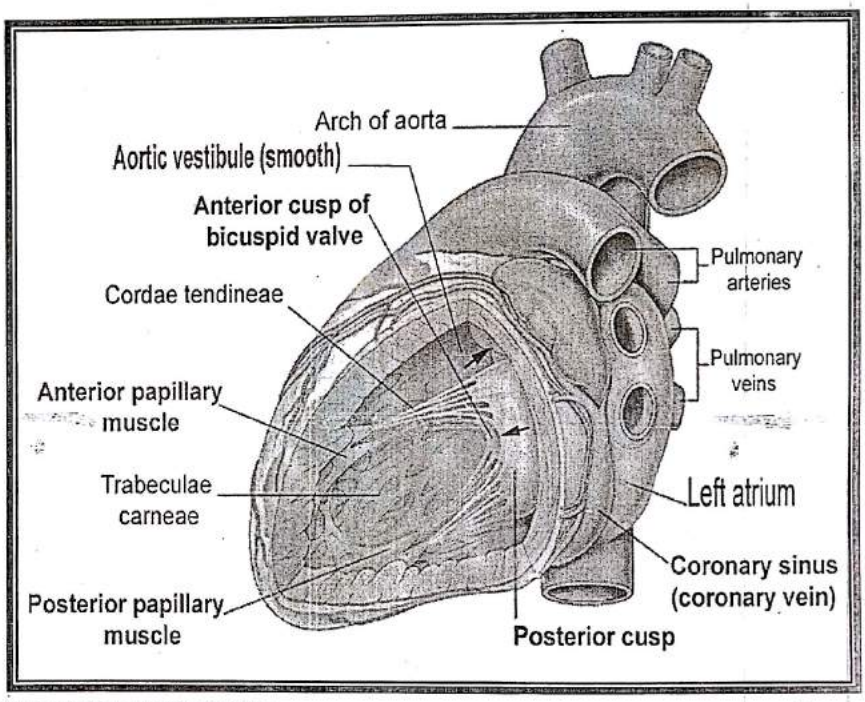

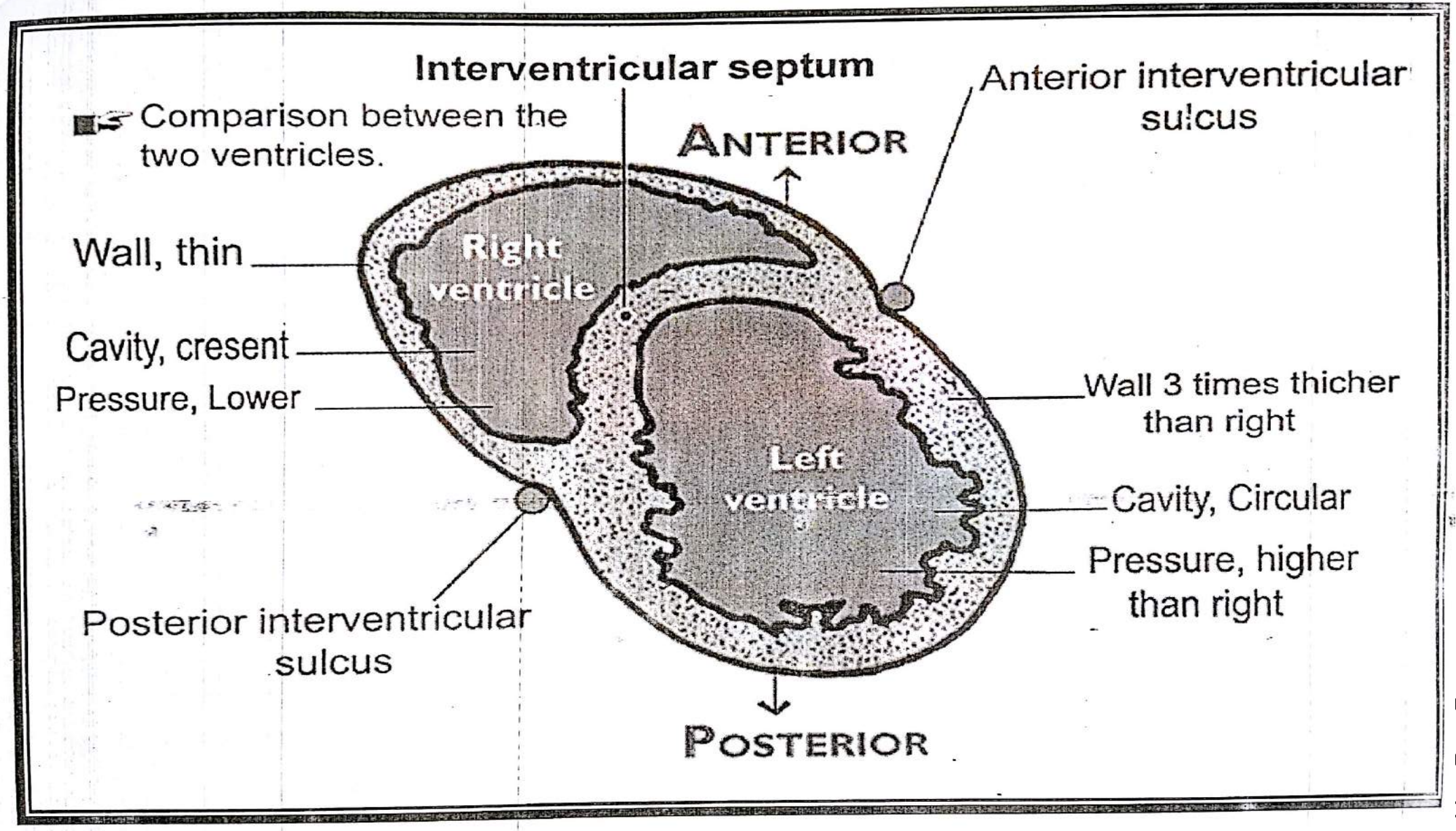

Rt. coronary:

- From ascending aorta.
- **Smaller** than the Left.
- Pass in coronary sulcus between PT and Rt auricle.
- Pass at inferior surface.
- Branches: 1- 4.
  number **2** in 60% of people.

Left coronary:

- From ascending aorta.
- **Larger** than the right.
- Pass in coronary sulcus between pulmonary trunk and left auricle.
- Pass at inferior surface.
- Branches: 1- 3.
  Number **2**, main artery to left ventricle.

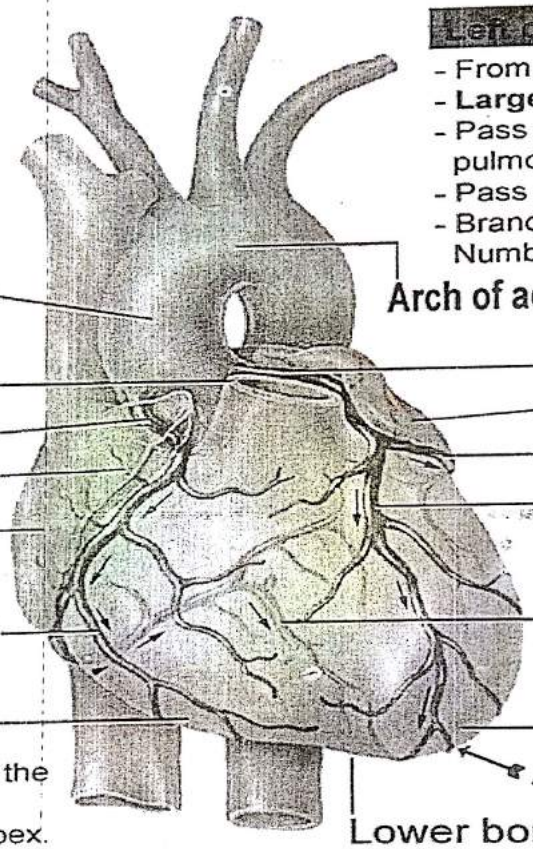

Both anastomose freely in the heart.
Both anastomose at the apex.

Coronary vein:

- About 5 cm long.
- Pass within coronary sulcus at inferior surface.
- Extend from left to right.
- Receive 3 veins.
- End into right atrium.

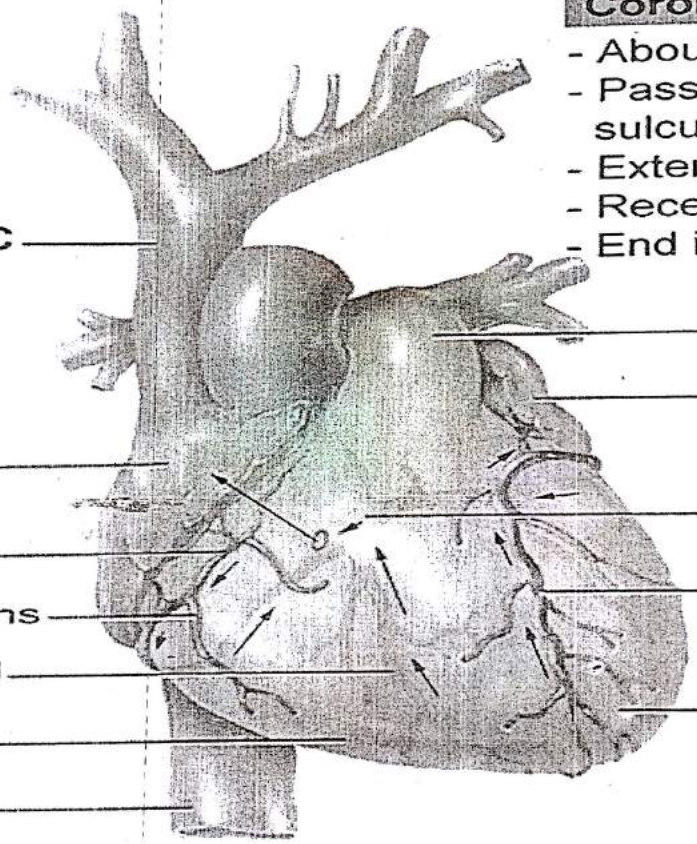

Cardiac conduction System

- A network of a modified cardiac muscle fibers specialized in conduction only.
- It is **autorhythmic,** it constantly initiates and coordinates atrial and ventricular muscle contraction.
- Insulated from myocardium by a sheath of connective tissue.
- Establishes a ***unidirectional*** pathway of excitation signals and contraction.
- <u>Organized into **4** basic components:</u>

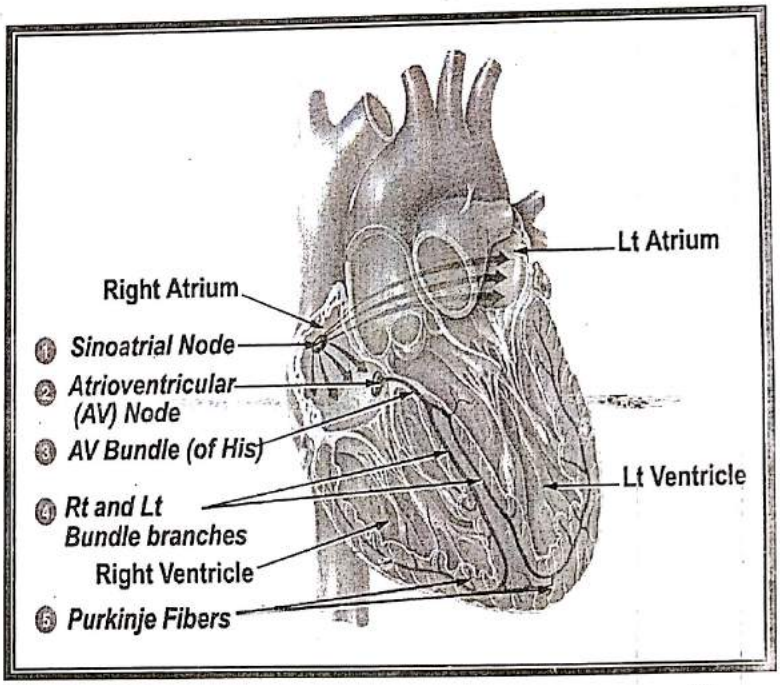

Components

Sinuatrial node

- Lies in the right atrium at the terminal end of crista terminalis close to the end of the SVC.
- It initiates excitation signals that spreads to all atrial muscles.
- Impulses rate accelerated by sympathetic stimulation and slowed by vagal stimulation.

Atrioventricular node

- At the inferior end of the interatrial septum.
- Collect impulses from atrial muscles and transmits them to the AV bundle.
- The AV bundle straddle the septum by dividing into right and left bundles within muscular part of the IV septum.

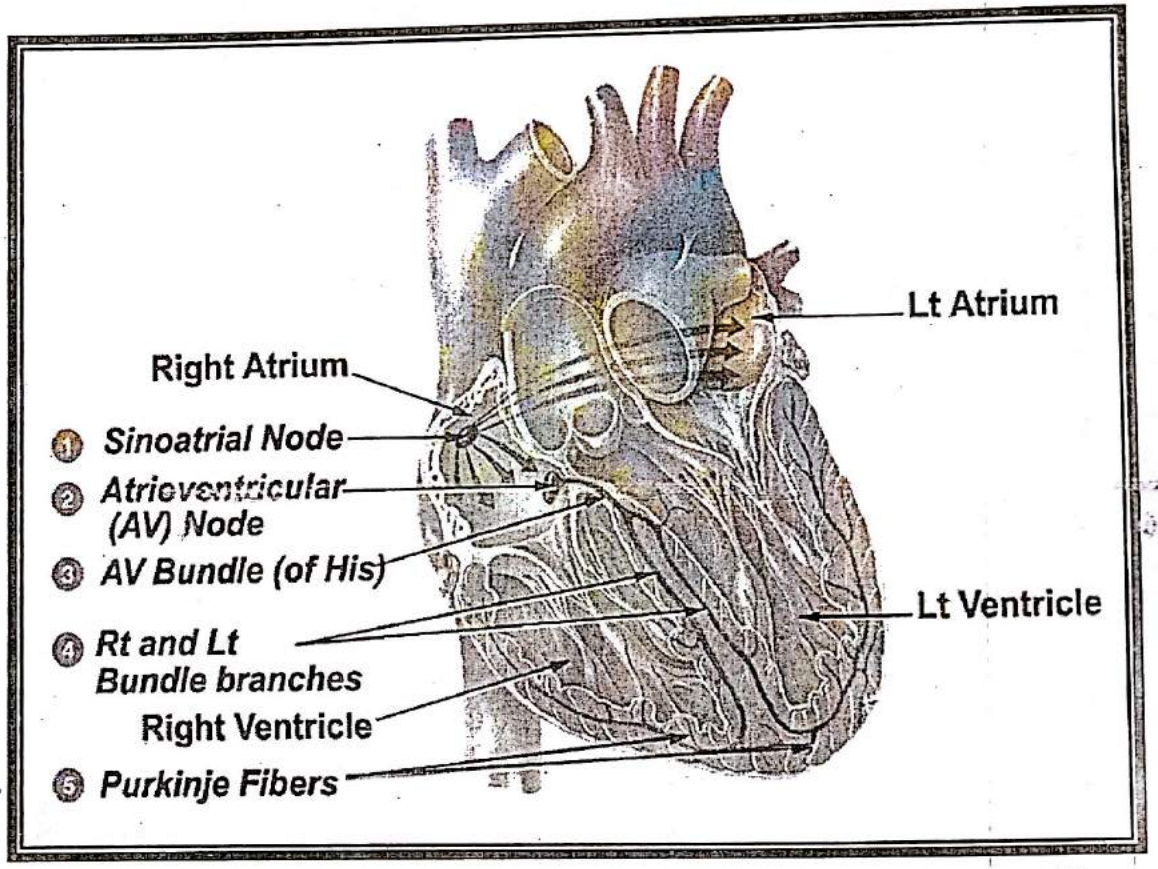

Cardiac Conduction System

- Its final fibers forms the subendocardial plexus that spreads throughout ventricles to supply ventricular muscles including the papillary muscles.

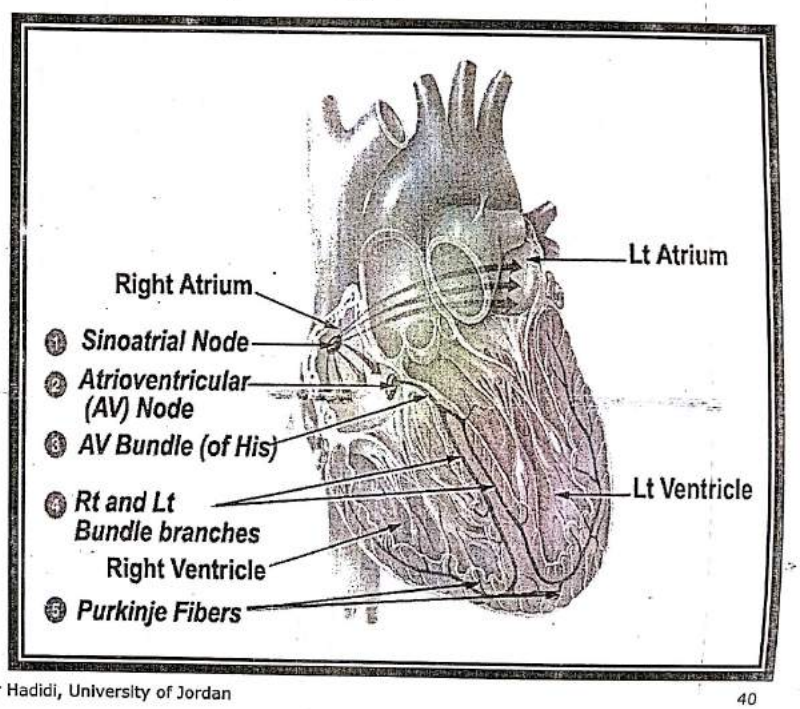

Fibrous Skeleton of the Heart

- Form of 4 dense CT rings surrounds the valves of the heart, they unite with one another and fuse with the interventricular septum.

Functions:

- **Fixation** site for the valves.
- **Separates** atrial muscles from ventricular muscles.
- Act as **electrical insulator** between atrial and ventricular muscles.

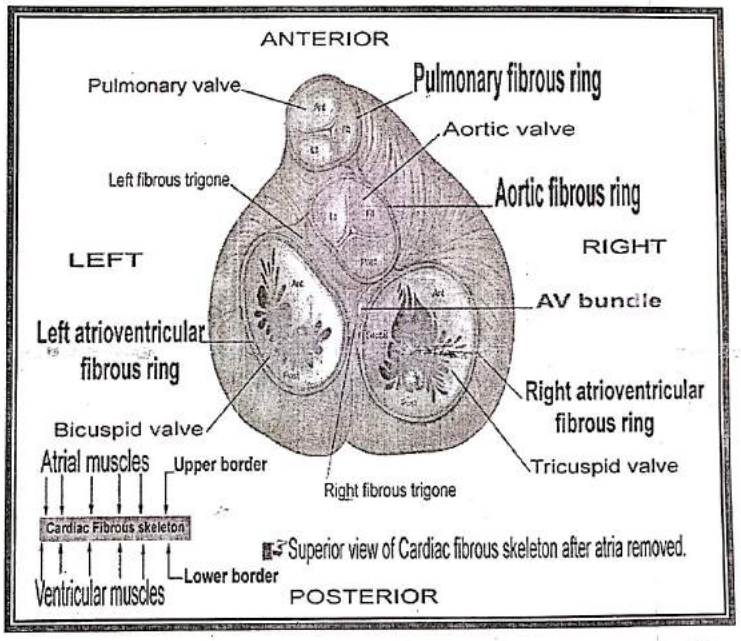

Superior view of Cardiac fibrous skeleton after atria removed.

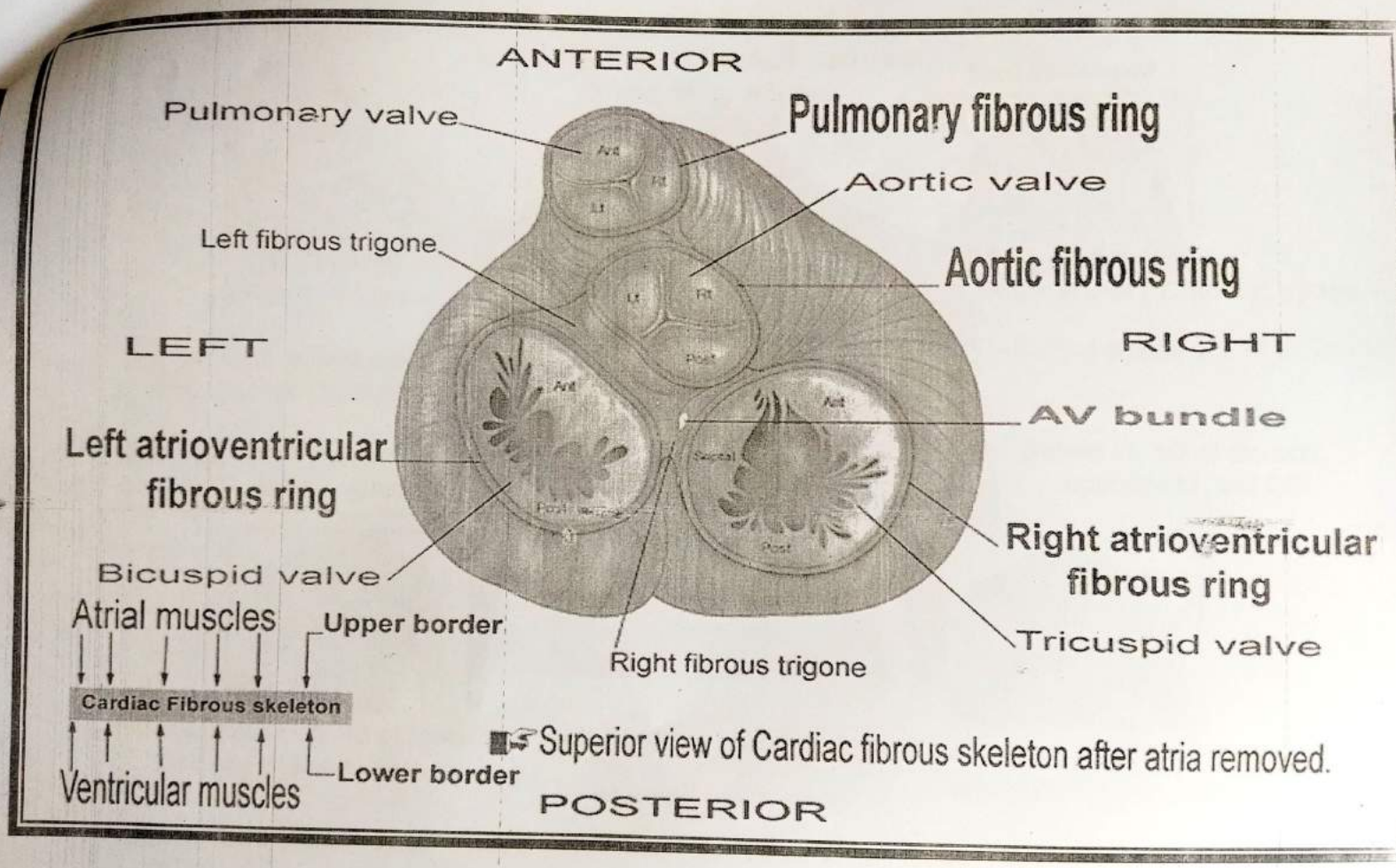

Superior view of Cardiac fibrous skeleton after atria removed.

Locations of heart valves, Hearing sites

Best heard over

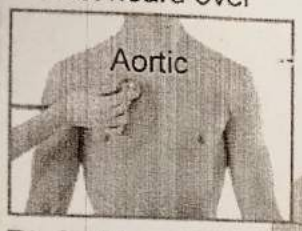

Rt. 2nd i.c. space

Best heard over

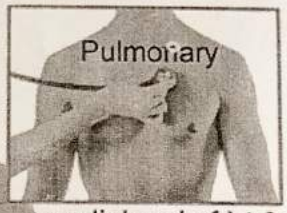

medial end of Lt.2nd i. c. space

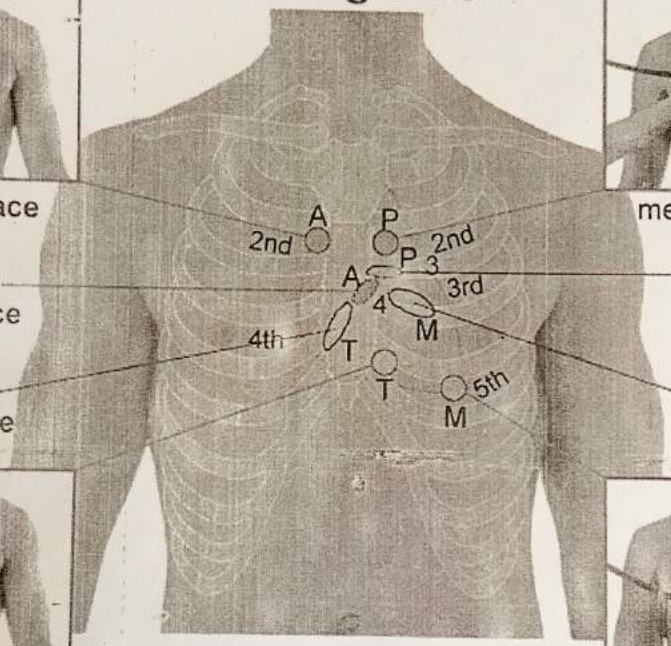

Behind Lt.1/2 of sternum opposite Lt. 3rd i.c. space

Behind medial end of Lt. 3rd CC

Behind Rt. 1/2 of sternum opposite Rt. 4th i.c. space

Behind Lt. 1/2 of sternum opposite Lt. 4th CC

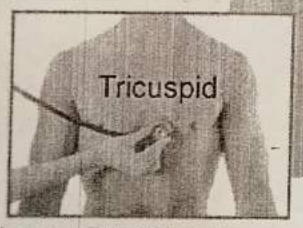

Beast heard over Rt. 1/2 of lower end of body of sternum

Best heard in the Lt. 5th intercostal space about 9cm from midline