The skin & Muscloskeletal system

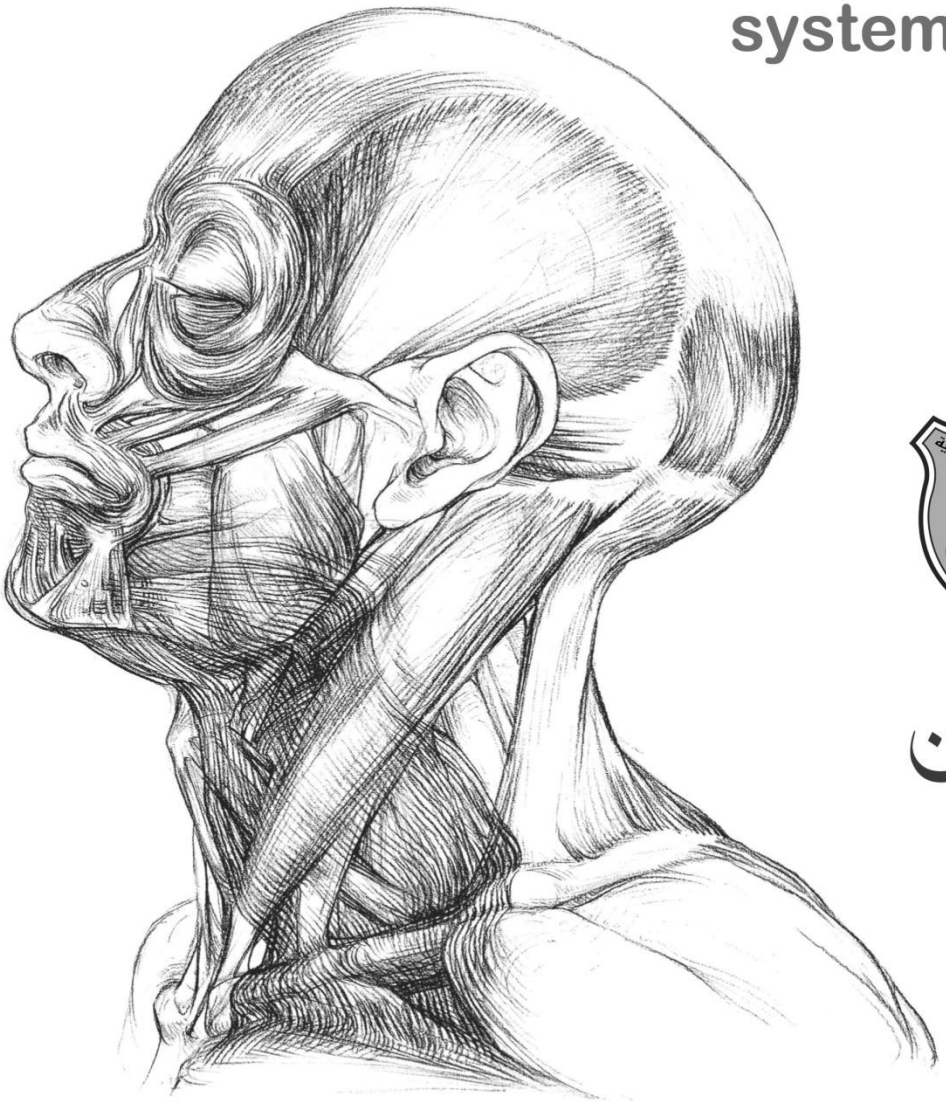

PATHOLOGY

SLIDES ☐
SHEET ■
LECTURE # 2

DOCTOR: Tariq Aladily
DONE BY: Manar Alafeshat
CORRECTION: Mohammad abu-fadaleh

There is no need to refer to the slides , hopefully this sheet will be enough.

Vitamin D deficiency:

Vitamin D can be obtained either by diet or sun exposure and it's essential for the mineralization of bones so when it's deficient the osteoid becomes weak.

- The fundamental change is defective bone mineralization resulting in overabundant nonmineralized osteoid.
- The majority of us have a vitamin D deficiency but that doesn't necessarily mean it'll develop into a bone disease.

❖ Both osteoporosis and vitamin D deficiency cause a <u>decrease</u> in the bone mass but the main difference between them is that the cellular part of the bone isn't affected in this deficiency.

Clinically :

Rickets كُساح refers to a childhood disorder in which deranged bone growth produces distinctive skeletal deformities and children are more affected because their bone is still growing … **Morphology**: they are short ,their long bones become curved and are easily fractured.

Osteomalacia تلين العظم is the adult counterpart; bone that forms during the remodeling process is undermineralized, resulting in osteopenia قلة العظم (decreased bone density)and predisposition to fractures but there are no deformities because they don't have any growing bones.

Hyperparathyroidism:

- Parathyroid hormone is important for calcium homeostasis in the body.
  - This disease is related to the endocrine system so we'll only focus on bones here.

Some diseases cause the increase of parathyroid hormone and that'll affect bones both directly and indirectly :

- PTH increases RANKL production by osteoblasts => activating osteoclasts
- Increased synthesis of active vitamin D, 1,25$(OH)_2$-D, by the kidneys, which in turn enhances calcium absorption from the gut and mobilizes bone calcium (hypercalcemia) causing bone erosion.

This also causes increased urinary excretion of phosphate.

The previously mentioned diseases are more pronounced in long bones but this disease is more severe so it can be seen even in the small bones (prominent in phalanges)

Diagnosis:

a. Endocrine changes, Patients have hypercalcemia and hypophosphatemia so this combination is the hallmark of hyperparathyroidism .
b. X-ray the phalanges (osteopenia can be seen)

<u>Endocrine system related diseases are long lasting and cause severe symptoms.</u>

Morphology:

Increased osteoclasts which are very active compared to the previously mentioned diseases thus causing bone resorption, especially in periosteum.

- This process needs more blood ,energy and electrolytes which results in Increased connective tissue (fibrovascular core)

With persistent disease and the increased osteoclast activity it'll appear as a **brown tumor** that isn't neoplastic (gross morphology) also known as **osteitis fibrosa cystica** under the microscope.

Osteitis: inflammation due to fractures.
Fibrosa: repair.
Cystica: caused by repeated hemorrhage.

Biopsy of the bone is obtained by an operation and in this disease the biopsy will contain osteoclasts .

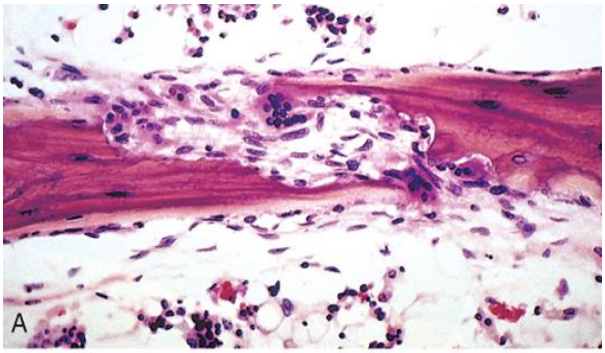

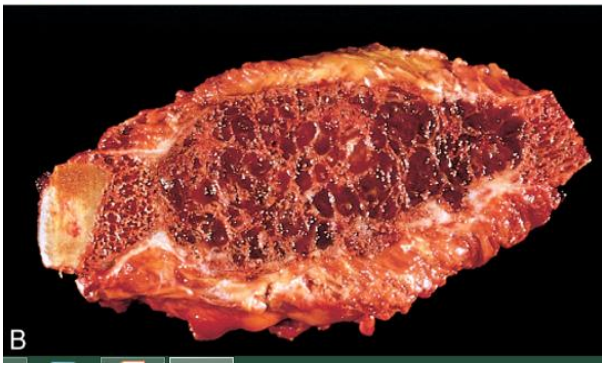

Bony manifestations of hyperparathyroidism.

A, Osteoclasts gnawing into and disrupting lamellar bone.

B, Resected rib, with expansile cystic mass ("brown tumor").

Infectious diseases in bones:

Pyogenic Osteomyelitis:

Pyo means caused by **bacteria** (viruses don't cause Osteomyelitis).

<u>Root</u> (how do they gain access to the bone?)

- Most commonly Blood borne; secondary to hematogenous spread from a distant site of infection in the body.
- Less commonly through direct extension and traumatic implantation when there is exposed bone.

❖ Staph Aureus is the most common bacteria causing this disease.

Special conditions:

a. Group B-strep and E. Coli are the most common in neonates and they acquire these bacteria from the female genital tract.
b. Sickle cell disease patients have increased proclivity to Salmonella for unknown reasons.
c. Mixed bacteria, including anaerobes, usually cause pyogenic osteomyelitis when there is a trauma.

Diagnosis

It's an acute infection so the symptoms manifest quickly there is a sudden onset of bone pain , fever ,systemic symptoms all lead to clinical suspicion so we take a biopsy and make a bacterial culture.

- In 50% of clinical practice cases, no bacteria is isolated because it's located deep in the bone but this negative result doesn't exclude osteomyelitis so we give an empirical treatment (wide spectrum antibiotic).

Morphology

Acute stage: sheets of neutrophils, dead cells, entrapped necrotic bone (together they are called **sequestrum**) the bone becomes soft and friable

- Viable organisms can persist in the sequestrum for years after the original infection.

Through hematogenous spread the bacteria reaches the medulla and then the infection spreads out to reach the periosteum (outermost area) through Haversian system. After this a new process starts ;In children, the periosteum is loosely attached to the cortex; therefore it can be pushed away and **subperiosteal abscesses** can form and extend along the bone surface .

  - Abscess is a collection of inflammatory cells which causes a visible mass non neoplastic (tumor like) and it can be seen in radiology.

Lifting of the periosteum further impairs the blood supply to the affected region, and both suppurative and ischemic injury can cause segmental bone necrosis (coagulative and liquefactive necrosis occur).

In Later stages rupture of the periosteum can lead to an abscess in the surrounding soft tissue (muscle,fascia and the skin) which forms a **draining sinus** when reaching the skin.

Sinus : a tract between a superficial part (skin) and the deepest part of inflammation, in advanced stages pus can be seen coming out of the skin .

To sum up : infection starts in the medulla then moves away to the outer layers reaching the periosteum where it forms a subperiosteal abscess then it moves to the soft tissues which results in the formation of a draining sinus in the skin .

- In infants (uncommonly in adults) we have the epiphysis in the long bones so If the infection moves vertically it can infect the epiphysis ; epiphyseal infection can spread into the adjoining joint to produce **suppurative arthritis**, sometimes with extensive destruction of the articular cartilage and when repairing the joint fibrosis happens and the bones forming the joint will adhere so **permanent disability** occurs.
- An analogous process can involve vertebrae, with an infection destroying intervertebral discs and spreading into adjacent vertebrae leading to their fusion ,more severe because the patient won't be able to bend at all.

  After the first week of infection chronic inflammatory cells become more numerous. The cytokines released by leukocytes stimulate osteoclastic bone resorption, fibrous tissue growth, and bone formation in the periphery (woven and lamellar) which forms a shell of living tissue around the devitalized segment of the bone .This newly grown bone is called (**involucrum**)

- This is a deep chronic infection so its treatment is very difficult it needs 6 months and IV antibiotics also it may fail .

Woven : Immature osteoid , when seen it indicates active deposition of bone(during repair)
Lamellar: organized pattern of the osteoid.

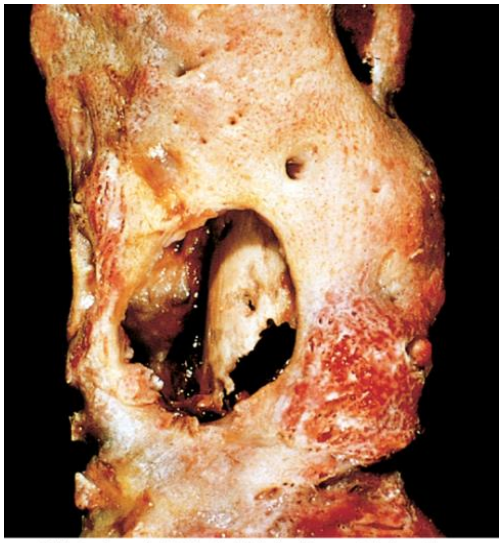

© Elsevier. Kumar et al: Robbins Basic Pathology 8e - www.studentconsult.com

This is a resected femur from a person with chronic osteomyelitis. Necrotic bone (the sequestrum) visible in the center of a draining sinus tract that is surrounded by a rim of new bone (the involucrum).

Mycobacterial osteomyelitis:

Mycobacteria cause chronic infections and can infect any organ in the body.

- 1% to 3% of cases of pulmonary tuberculosis can complicate into Mycobacterial infection of the bone .
- The organisms usually reach the bone through the bloodstream by hematogenous spread, *long bones and vertebrae are favored sites*, although direct spread from a contiguous focus of infection (e.g., from mediastinal nodes to the vertebrae) can also occur.

Compared to pyogenic osteomyelitis :

1. The lesions are often **solitary** but can be **multicentric**, most common in patients with an underlying immunodeficiency while pyogenic osteomyelitis can be seen in any person.

2. The tubercle bacillus is **microaerophilic**, the synovium, with its higher oxygen pressure, is a common site of initial infection whereas the medulla is the intitial site of infection caused by pyogenic bacteria.

3. The infection then spreads to the adjacent epiphysis, where it causes a typical **granulomatous inflammation** (a big mass of firmly adhered macrophages which try to destroy the bacteria) with caseous necrosis and extensive bone destruction, no neutrophils are found. On the other hand, neutrophils are found at the site of infection caused by pyogenic bacteria.

*In the past,Tuberculosis of the vertebral bodies, was known as **Pott disease** -an important form of osteomyelitis.* Infection at this site causes vertebral deformity and collapse, with secondary neurologic deficits, extension of the infection to the adjacent soft tissues develops psoas muscle abscesses which is fairly common.

Bone Tumors

Common target organs for metastasis are:

1. Lung (blood circulation must go through it and the circulation is slow)
2. Liver
3. Bone (very vascularized)

<u>So bone tumors most commonly are a result of metastasis .</u>

Hematologic neoplasms like leukemia arise from the bone more commonly than primary bone tumors.

- Primary bone tumor can be benign or malignant
- In Benign bone tumors we have mature extra tissue (either from the osteoid , cartilage ,fibrous part any of them can produce a matrix) more common in younger ages especially before 40 ,whereas malignant tumors are more common at older ages (although there are some exceptions).

Tumors are classified according to cell of origin and pattern of differentiation.

- Osteochondroma is the most common benign tumor.
- Osteosarcoma is the most common malignant tummor (cancer).

Remember !!Why is it called sarcoma and not carcinoma ? because it has a mesenchymal origin from the mesoderm …. The naming is because of the different **Biologic Behavior of Tumors** e.g: sarcomas don't respond to chemotherapy and spread to the blood while carcinomas do respond and spread to the lymph nodes.

- Long bones are the most common site for both malignant and benign tumors because thay have the maximum rate of proliferation thus there is a higher chance of developing tumors. (There are exceptions)

Regarding the following table you should know the most common site and age group of each tumor.

Tumor Type	Common Locations	Age (yr)	Morphology
Bone-Forming			
BENIGN			
Osteoma	Facial bones, skull	40-50	Exophytic growths attached to bone surface; histologically resemble normal bone
Osteoid osteoma	Metaphysis of femur and tibia	10-20	Cortical tumors, characterized by pain; histologically interlacing trabeculae of woven bone
Osteoblastoma	Vertebral column	10-20	Arise in vertebral transverse and spinous processes; histologically similar to osteoid osteoma
MALIGNANT			
Primary osteosarcoma	Metaphysis of distal femur, proximal tibia, and humerus	10-20	Grow outward, lifting periosteum, and inward to the medullary cavity; microscopically malignant cells form osteoid; cartilage may also be present
Secondary osteosarcoma	Femur, humerus, pelvis	>40	Complications of polyostotic Paget disease; histologically similar to primary osteosarcoma
Cartilaginous			
BENIGN			
Osteochondroma	Metaphysis of long tubular bones	10-30	Bony excrescences with a cartilaginous cap; may be solitary or multiple and hereditary
Chondroma	Small bones of hands and feet	30-50	Well-circumscribed single tumors resembling normal cartilage; arise with medullary cavity of bone; uncommonly multiple and hereditary
MALIGNANT			
Chondrosarcoma	Bones of shoulder, pelvis, proximal femur, and ribs	40-60	Arise within medullary cavity and erode cortex; microscopically well differentiated cartilage-like or anaplastic
Miscellaneous			
Giant-cell tumor (usually benign)	Epiphysis of long bone	20-40	Lytic lesions that erode cortex; microscopically, contain osteoclast-like giant cells and round to spindle-shaped mononuclear cells; majority are benign
Ewing tumor (malignant)	Diaphysis and metaphysis	10-20	Arise in medullary cavity; microscopically, sheets of small round cells that contain glycogen; aggressive neoplasm

Benign osteoid producing tumors:

Osteoma , Osteoid Osteoma , Osteoblastoma

a. Osteoma:

Special condition which occurs in the skull, face and sinuses it can be solitary or multiple (like in Gardner syndrome).

Better classified as a developmental abnormality (no mutations here and it doesn't transform to malignancy like benign tumors do) rather than a true neoplasm which makes it similar to hamartoma **Remember!!** (a focal malformation that is not a malignant tumor and It is composed of tissue elements normally found at that site, but which are growing in a disorganized mass.)

- Occurs in Middle aged patients
- Gross Appearance :Bony hard protrusions
- Under the microscope : benign cells and a mixture of woven and lamellar bone.

b. Osteiod Osteoma and Osteoblastoma:

- Benign tumors (true neoplasms because we have mutations)
- Affect Teenage and middle aged people.
- Arise from the superficial part of the bone(in the cortex).

Both have a high level of prostaglandins and the same morphology but :

- Osteoid osteoma arises in peripheral parts like proximal femur and tibia ,it is smaller (<2cm) and painful but responds to aspirin.

- Osteoblastoma arises in vertebra ,it is larger and painful but does not respond to aspirin.

Asprin has a diagnostic value here since the response differs between both types

Treatment for both : excision, No radiation because it may cause transformation to malignancy thus making it worse.

The picture to the right shows: Osteoid osteoma showing randomly oriented trabeculae (very thin) of woven bone rimmed by prominent osteoblasts no lamellation seen.

The intertrabecular spaces are filled by vascular loose connective tissue, stromal cells and osteoblasts.

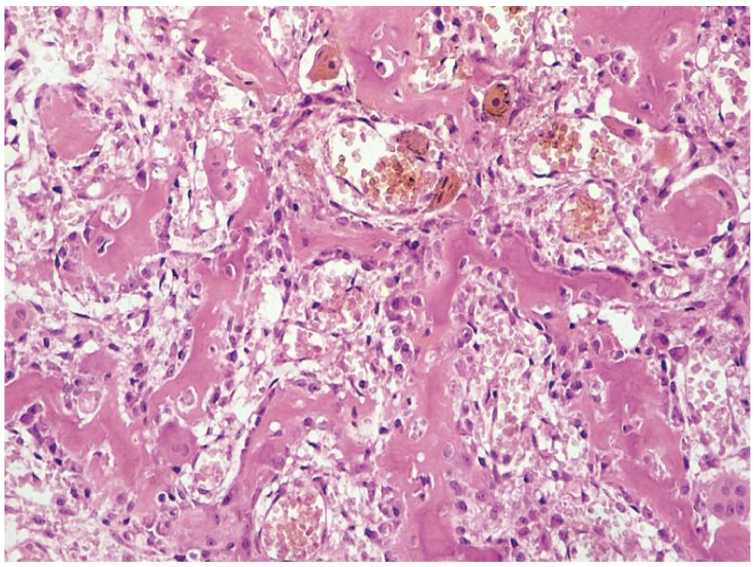

Similarities between all Benign osteoid producing tumors:

<u>Histologically</u> under the microscope (mixture of woven and lamellar bone)
<u>Radiologically</u> (radiolucent nidus : like a coin, circle in shape with a radiolucent center)

Osteosarcoma

- Most common primary malignant bone tumor (after excluding hematopoietic tumors)- it is produced from the bones.
- Occurs at all age groups, but more than 75% of cases occur in the age group less than 20 years old which makes it an exception to other malignant bone tumors.
- Occurs at all sites, most frequently in Metaphysis of long bones (60% around knee)
- Most osteosarcomas are primary (no previous disease) **Remember!!** : it can be secondary in the case of Paget disease.
- Most commonly <u>solitary</u>.
- **intramedullary**, and poorly differentiated, producing a predominantly bony matrix (osteoid)
- Many osteosarcomas develop at sites of greatest bone growth and they spread hematogenously.

Pathogenesis

like all tumors we have mutations but we are only concerned with the most important ones like ***RB*** gene mutations which occur in 60% to 70% of sporadic tumors, and individuals with hereditary retinoblastomas (due to germ-line mutations in the *RB* gene)
Spontaneous osteosarcomas also frequently exhibit mutations in genes that regulate the cell cycle including ***p53,*** cyclins, cyclin-dependent kinases, and kinase inhibitors.

Morphology

- Grossly, gray-white tumors exhibiting hemorrhage and cystic degeneration.Tumors are more destructive than bacteria so they destroy the surrounding cortex and produce soft tissue masses .

- <u>Horizontal</u> growth is more common,they spread extensively in the medullary canal, infiltrating and replacing the marrow, but <u>vertical</u> growth is rare so there is infrequent penetration of the epiphyseal plate or entering the joint space.

Microscopically: malignant cells which are poorly differentiated they vary in size and shape, and frequently have large hyperchromatic nuclei and mitoses (pleomorphic cells) they lead to the production of mineralized or unmineralized bone (osteoid) but this osteoid is abnormal .

The neoplastic bone is typically coarse and ragged but can also be deposited in broad sheets.

Cartilage and fibrous tissue can also be present in varying amounts. When malignant cartilage is abundant, the tumor is called a **chondroblastic osteosarcoma** it is the same as osteosarcoma but the name only refers to the presence of cartilage when seen under the microscope.

After clinical suspicion we take a biopsy and view it under the microscope to diagnose.

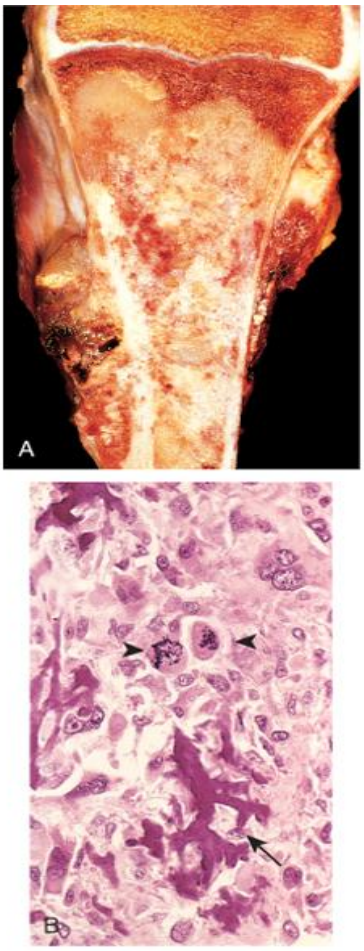

Osteosarcoma.

A,grossly appearance, Mass involving the upper end of the tibia. The tan-white tumor fills most of the medullary cavity of the metaphysis and proximal diaphysis. It has infiltrated through the cortex, lifted the periosteum, and formed soft tissue masses on both sides of the bone.

B, Histologic appearance, with coarse, lacelike pattern of neoplastic bone (*arrow*) produced by anaplastic tumor cells. Note the wildly aberrant mitotic figures (*arrowheads*) the malignant osteoid can be seen.

Clinically / Radiology

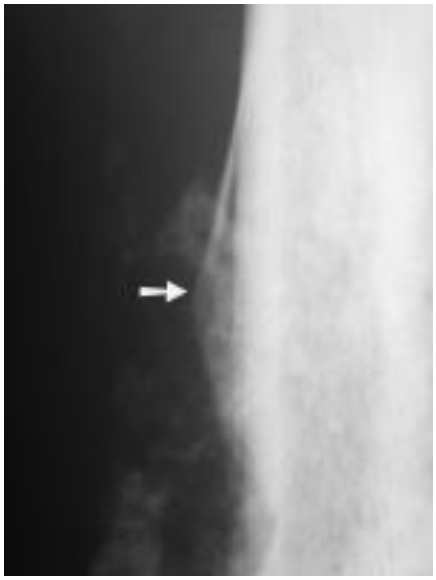

Painful enlarging mass

Spontaneous fracture

X-ray: triangular

Their Growth forms(Codman triangle) between Cortex and periosteum.

…Good Luck…

Richard**:** Bailey, we reach into people's bodies and hold their lives and their futures in our hands. There's nothing more personal than this job, in how we treat a patient, in how we raise our doctors and teach them how to do this work. Every decision that you make should be a personal one.