



## Anatomy

● Sheet

○ Slide

number

10

Done by

Raghad Odeh & Maysa Shaheen

Correction

Enas Ajarma

Doctor

Mohammad Al-Muhtaseb



## Muscles of the posterior abdominal wall.

- 1) **Psoas major** muscle
- 2) **psoas minor** (usually absent) like in the case of pyramidalis muscle in rectus sheath.
- 3) **Iliacus** muscle
- 4) **Quadrates lumborum** muscle.

Anterior to these muscles there's a **muscular fascia** and in front of the fascia there's a **parietal peritoneum**, after that there is the aponeurosis of transversus abdominis muscle.

{And these are the boundaries of the posterior abdominal wall}

### **Psoas major**

Origin: body and transverse process of lumbar vertebra and intervertebral disc

Insertion: Lesser trochanter

Nerve supply: T12, L1-L3

Action: flexion of hip and thigh

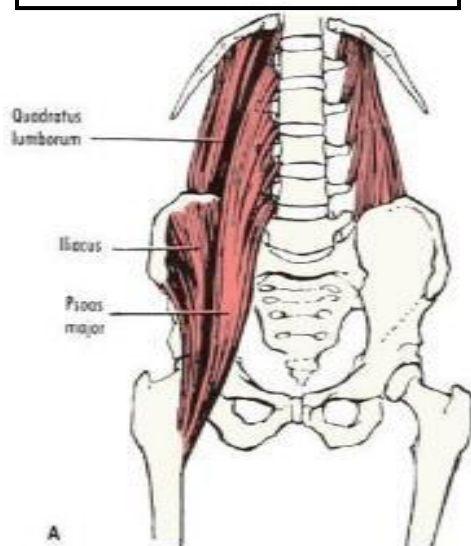
### **Quadratus lumborum**

Origin: downward. iliolumbar ligament and iliac crest

Insertion: upward. 12<sup>th</sup> rib

N.S: nerve plexus T12, L1-

L3 Action: fix or depress the 12<sup>th</sup> rib during respiration



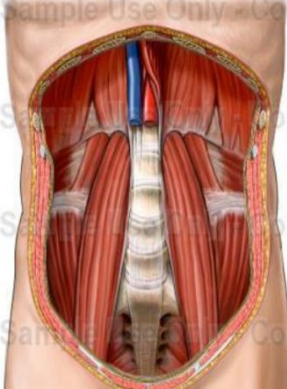
### **Iliacus** muscle

Origin: iliac fossa

Insertion: lesser trochanter

N.S: femoral nerve

Action: lateral flexion of hip



Abdominal aorta and IVC in front of T12, L2, and L1 descending downwards.

### ➤ The iliolumbar ligament

From its name:

- ❖ ilio: from the iliac crest
  - ❖ Lumbar: going to the transverse process of the 5<sup>th</sup> lumbar vertebra attaching to the iliac crest.
- Gives origin to ***quadrates lumborum***.

### ➤ Arteries of the posterior abdominal wall

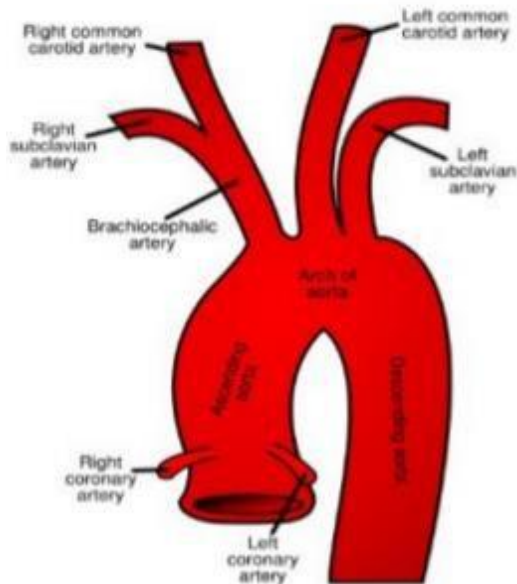
The **ascending aorta** commences from the **left ventricle**. The left ventricle receives oxygenated blood.

The ascending aorta gives the **coronary arteries** that supply the heart with oxygen rich blood.

- So, the origin of the coronary arteries is the ascending aorta.

**Arch of the aorta gives :**

- 2) Left common carotid
- 1) Left subclavian - on upper limb, to neck and head.
- 3) Brachiocephalic - on the right side.



**Brachiocephalic trunk** divides into the right common carotid and the right subclavian ( this part of the arch of the aorta is asymmetrical , then becomes symmetrical on right and left side of the neck)

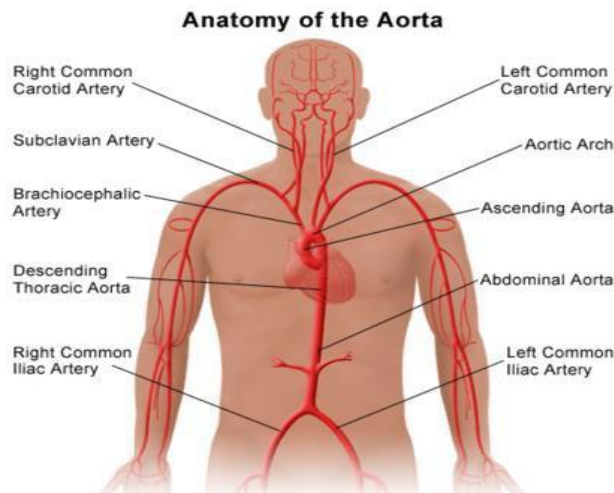
**Asymmetric:** presence of the same structures on both sides ; left common carotid and left subclavian on the left side and right common carotid, right subclavian on the right side.

The continuation of the arch is the descending thoracic aorta, which pierces the diaphragm at the level of **T12** in the **midline**, posteriorly, and continues as **abdominal aorta**.

Our lecture today is about the **abdominal aorta**, SO again, the **abdominal aorta** is a continuation of the thoracic aorta coming from the chest and has an opening in the diaphragm at the level of **T12**.

The abdominal aorta ends by left common iliac and right common iliac, each branch internal and external iliac arteries

The aorta, as we mentioned, enters the abdomen at the level of (T12) in the **midline** and ends at the level of the (L4) to the **left** side; because on the right side, there is the inferior vena cava.



## Relations of the abdominal aorta:

### Anterior :-

- Pancreas,
- 3<sup>rd</sup> part of the duodenum
- Coils of the small intestine
- crossed by left renal vein

**Why left renal?** Because the left renal VEIN is going to the inferior vena cava( which is on the right side of the abdominal aorta) so it crosses the abdominal aorta anteriorly.

### On the Right side:-

- I.V.C
- Cisterna chyli present in the opening, collection of lymphatic
- Beginning of Azygos vein going to the chest

### On the Left side:-

- Left sympathetic chain

Note: These relations are very important

## ***Branches of the abdominal aorta:***

**SINGLE branches** (3 front and 2 back)

The front branches are:

1. Celiac trunk.
2. Superior mesenteric artery.
3. Inferior mesenteric artery.

Back:

median sacral artery, is a continuation from the back of the abdominal aorta at the end (terminal)

**PAIRS branches** (2front, 4back, 3 on the side)

Front:

testicular < in male > OR ovarian< in female > at the level of **L2, in front** of the abdominal aorta ; like the celiac trunk and superior mesenteric but these are pairs one in the right and one in the left.

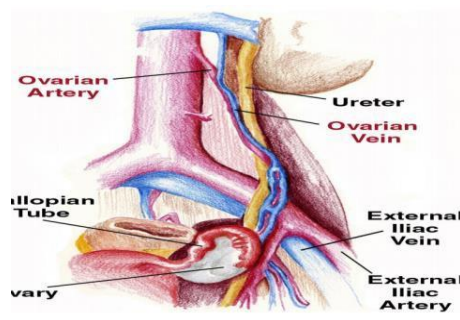
from the back:

we have 4 Lumbar arteries , meaning going to the lumbar vertebra, that's why they are coming out from the back.

On the side:

2. Inferior phrenic going to the diaphragm
1. Middle suprarenal going to the supra renal gland
3. Renal arteries going to the kidneys

All these are paired going to organs in the posterior wall.



The ovarian vein on the left side goes to the left renal vein

## Now going into more details about the abdominal aorta:

### Celiac trunk

At the level of **L1** , to be precise ( upper border of L1 OR Lower border of T12) (between T12 & L1) .

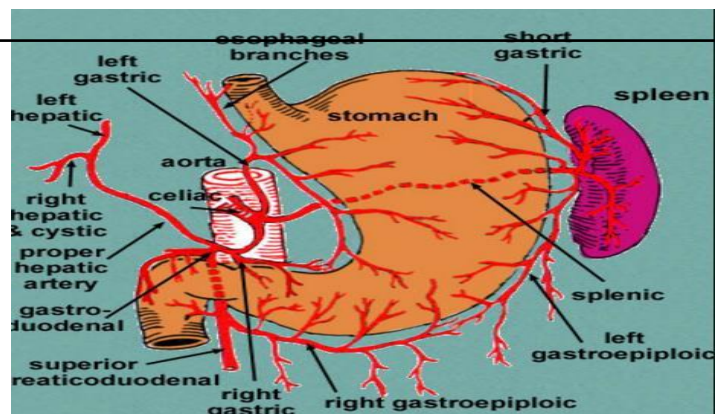
### Branches:

→ splenic artery , left gastric artery, hepatic artery

The left gastric supplies the lower third of esophagus & lesser curvature

The splenic artery is tortuous , runs behind the stomach to supply the spleen and gives short gastric arteries to the stomach through the gastrosplenic ligament, and gives the gastroepiploic .

The hepatic gives **right gastric artery** and **gastrooduodenal artery** which gives right gastroepiploic artery and superior pancreaticoduodenal artery, in the porta hepatis hepatic divides into left and right hepatic arteries and the right gives cystic artery to the gall bladder .





### **Superior Mesenteric artery**

Arises at the level of **L2** (upper border of L2 )(between L1 & L2) .

Goes to the midgut; that starts from the lower half of the duodenum and ends at the proximal  $1/3$  of the transverse colon.

#### **Branches:**

- 2) Inferior pancreaticoduodenal
- 1) Right colic artery for ascending colon
- 3) Middle colic artery for transverse colon
- 4) Iliac and jejunal branches ( 25 in number) that are present in the mesentery that make arcades and vasa recta
- 5) Iliocolic artery that gives anterior and posterior cecal and the posterior cecal gives the appendicular artery to the appendix.

### **Inferior mesenteric artery:**

At the level of **L3**, behind the 3<sup>rd</sup> part of the duodenum

So the 3<sup>rd</sup> part of the duodenum is anterior to the origin of the inferior mesenteric

Supplies the hind gut, which is the lateral  $2/3$  of the transverse colon, descending colon, sigmoid and rectum.

#### **Branches:**

Left colic → to the lateral  $2/3$  of the transverse and continues to supply the descending colon as well as the sigmoid and continues as the superior rectal to the rectum and opposite to it is the vein

### **Marginal artery:**

It's the anastomosis of colic arteries around the concave margin of the large intestine, connection between terminal arteries

This begins at the ileocecal junction, where it anastomoses with the ileal branches of the superior mesenteric artery, and it ends where it anastomoses less freely with the superior rectal artery.

### **Common iliac arteries:**

The right and left common iliac arteries are the terminal branches of the abdominal aorta.

They arise at the **level of L4** then ends at the inlet of the pelvis (Anterior of sacrum), Present at the medial border of psoas muscle.

Each common iliac artery passes in front of sacroiliac joint and divides into internal and external iliac arteries.

The bifurcation is crossed anteriorly by the **ureter** so the ureter is **anterior to** the common iliac arteries.

### **The external iliac artery:**

Descends deep into inguinal ligament

Becomes femoral artery but before it becomes femoral it gives

**branches:**

**1) Inferior epigastric artery** which is an important branch and a landmark that distinguishes between direct and indirect hernia, Lies between superficial and deep rings of the inguinal canal.

Inferior epigastric enters the rectus sheath and meets the superior epigastric.

2) **Deep circumflex iliac artery** that goes towards anterior superior iliac spine.

**Internal iliac artery:**

The major artery that supply the pelvic viscera is the **internal iliac artery**.

**In males** → it supplies urinary bladder, prostate, seminal vesicle and vas deference.

**In females** → it supplies also urinary bladder, uterus, vagina, fallopian tube, broad ligament, and ovaries

Consequently, the internal iliac artery is the blood supply to the pelvic viscera.

\*In the 3rd year, you will take the male and female genital organs, you'll be required to know every blood supply to each organ.

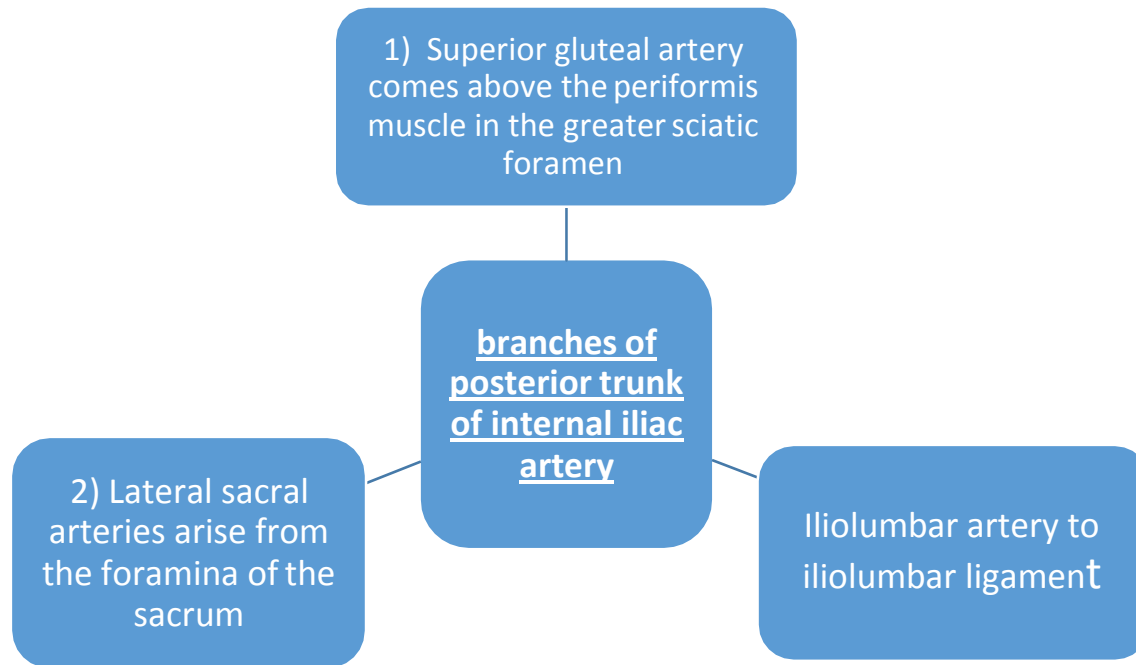
Internal iliac artery passes in front of the **sacroiliac joint** then it divides into anterior and posterior divisions

Posterior division meaning its going posteriorly to the wall of the pelvis, and the anterior division is mainly to the pelvis viscera.

**Branches from the posterior trunk** contribute to the supply of the lower posterior abdominal wall, the posterior pelvic , and the gluteal region.

**Branches from the anterior trunk** supply the pelvic viscera, gluteal region, and the adductor region of the thigh.

### **Branches of posterior division of internal iliac artery:**



### **Branches of anterior division of internal iliac artery:**

1) Obturator artery is accompanied with obturator nerve; it supplies the medial side of the thigh

2) Inferior gluteal artery - below the periformis muscle in the greater sciatic foramen, supplies the gluteal region.

3) Umbilical artery becomes superior vesical artery ( goes to the urinary bladder) and obliterates at the end to become medial umbilical ligament

**Note:** remember the median umbilical ligament comes from the urachus in the embryo. Urachus is a fibrous remnant of the allantois, a canal that drains the urinary bladder of the fetus that joins and runs within the umbilical cord.

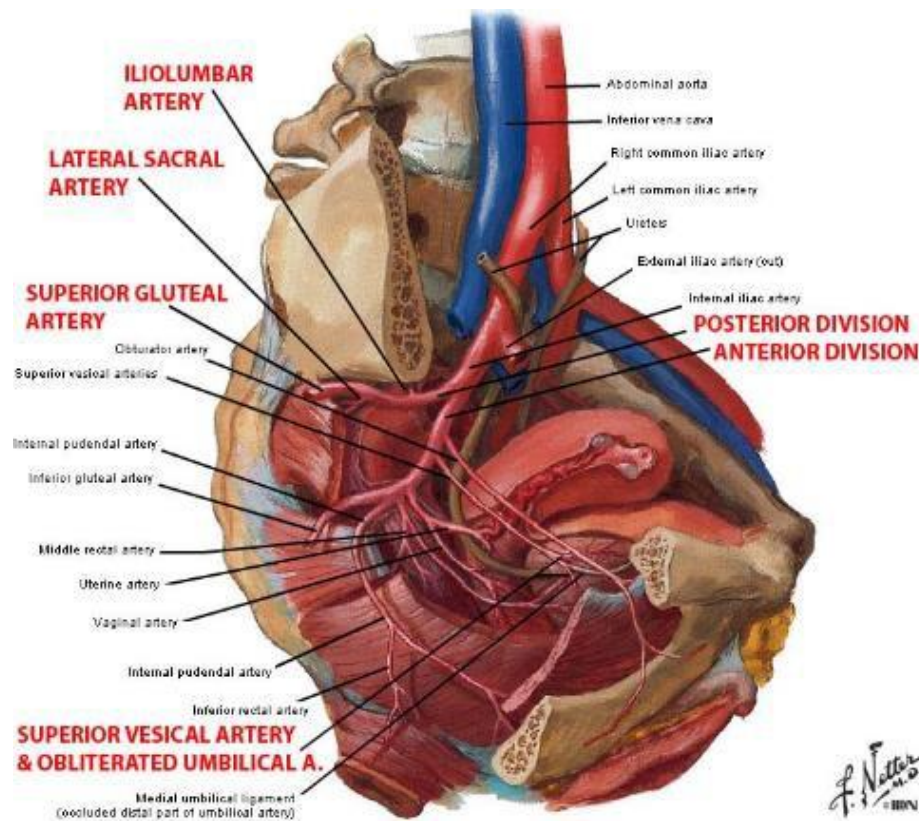
4) Uterine artery supplies uterus

5) Vaginal artery supplies vagina & artery to vas

6) Inferior vesical artery supplies urinary bladder and superior to umbilical

7) Middle rectal artery supplies rectum

8) Internal pudendal artery, it gives inferior rectal artery to the anal canal and rectum.



## Veins of the posterior abdominal wall

The most important one is the inferior vena cava (retroperitoneal), returns blood from all structures below the diaphragm to the right atrium of the heart.

The IVC is formed by the union of the common iliac veins behind the common iliac artery at the level of the 5<sup>th</sup> lumbar vertebra.

\*Inferior vena cava starts at the level of the **L5**, lower than the end of aorta on the right side.

It Ends at an opening in the diaphragm at the **level of T8** on the right copula or central tendon of diaphragm ,ends at the **right atrium**

(Coronary sinus of the heart, inferior vena cava, superior vena cava all of these veins carry deoxygenated blood in to right atrium)

Common iliac veins is located deeper than the arteries in the pelvis (the arteries is superficial only in pelvis)

## **Relations of I.V.C:**

### ***Anterior:***

- \*Coils of small intestine
- \* 3<sup>rd</sup> part and 1<sup>st</sup> part of duodenum
- \* Head of the pancreas and common bile duct
- \* Foramen of Winslow
- \* Portal vein
- \* Lies in deep groove of the liver

### ***Posterior:***

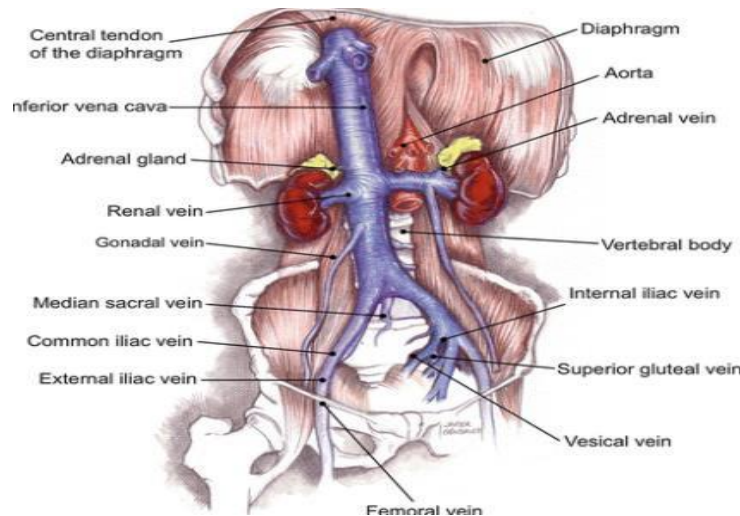
- \*right sympathetic trunk behind the right margin
- \*right ureter close to the right border

## **Tributaries of I.V.C:**

Opposite to the arteries

Tributaries to the inferior vena cava include the:

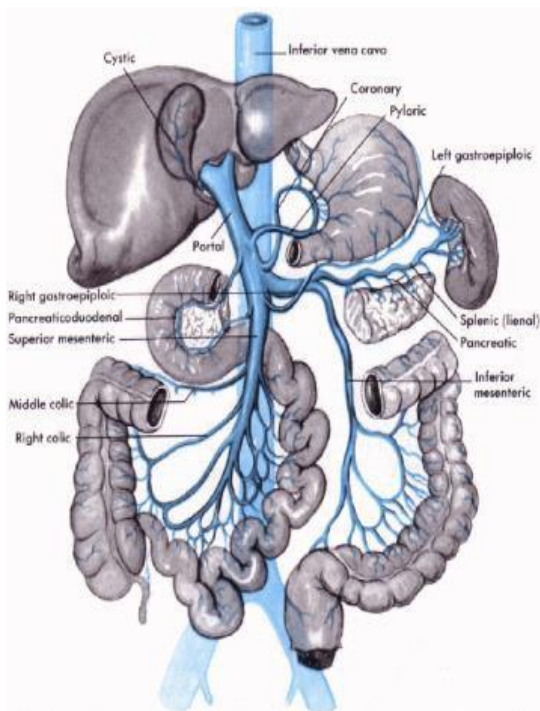
- |                                    |                                     |
|------------------------------------|-------------------------------------|
| 1) common iliac veins              | 6) renal veins                      |
| 2) median sacral vein              | 7) Right testicular or ovarian vein |
| 3) lumbar veins                    | 8) phrenic veins                    |
| 4) suprarenal veins from the right |                                     |
| 5) hepatic vein                    |                                     |



## Portal vein

It's length about 5 cm

It's formed by the union of the splenic vein and the superior mesenteric vein behind the neck of the pancreas, ascending in the free edge of the lesser omentum, ends in the porta hepatis of the liver, where it divides into right and left branches. The cystic vein ends in the right branch of the portal vein.



### The tributaries of portal vein:

- \* Splenic vein
- \* Superior and inferior mesenteric
- \* All veins coming from the stomach (right and left gastric) and duodenum and pancreas.

**Note:** cystic veins from the gallbladder which drain into right branch of portal vein  
Inside the liver it ends in portal triads, in hepatic sinusoids

**Note:** ductus venosus , a duct that connects the IVC with left portal, after delivery it is transformed into legamentum venosum (obliteration ) , and there is another obliteration of the umbilical vein which is transformed into ligamentum teres .

### **The venous drainage of the liver:**

By the central veins drains into hepatic veins, and the hepatic veins drains into inferior vena cava.

Portal vein is the blood supply that contains nutritive material, goes to the liver

Para umbilical veins drain into the left branch of portal vein and in the end it will be obliterated to form the ligmentum teres.

### **Portal systemic anastomosis:**

Portal hypertension or obstruction in front of the portal vein, how?

→ Liver diseases, liver cirrhosis or liver fibrosis, the sinusoids and portal triads will be closed, then the blood will go back to portal vein, and then it will go to the beginning of these veins.

**In other words there will be anastomosis between veins of the inferior vena cava and the veins of the portal vein.**

#### ***The causes of the portal systemic anastmosis***

Liver diseases → cirrhosis, fibrosis.

Heart diseases, valvular disease of the heart.

Congenital patent.

#### ***Regions of anastmosis:***

**1) Lower third of the esophagus** there are 2 types of veins that drain the blood from the esophagus



the first type : left gastric vein, ends in the portal vein

the second type : azygos vein ends in the inferior vena cava.

---

So, if there's portal hypertension, the blood will return back into left gastric and enter azygos vein → esophageal varices will develop around the lower 1/3 (dilatation and tortuous of the vein) → rupture and vomiting of the blood.

**2) Around the rectum and the anal canal**- superior rectal vein drains into inferior mesenteric → in portal vein.

the middle and inferior rectal veins drain into inferior vena cava.

This anastomosis between systemic and portal will lead to hemorrhoids (piles)- bleeding of rectum

So the reasons of occurrence of hemorrhoids are :

Porto systemic anastomosis and portal hypertension.

**3) Around the umbilicus**- the anastomosis is called **caput medusae**, paraumbilical veins- drain into portal vein.

superficial epigastric veins –(systemic) drains into inferior vena cava.

This anastomosis is characterized by radiating veins around the umbilicus

**4) Retroperitoneal between the systemic and portal** between right colic vein, middle colic vein and left colic vein (the previous veins drain into portal vein) and renal vein suprarenal vein, paravertebral vein, gonadal vein (the previous veins drain into inferior vena cava), this leads to direct anastomosis

**5) Intrahepatic** (patent ductus venosus): which converts into ligamentum venosum

In the end, the most important clinical points are about esophagus, rectum and umbilicus these are important, diseases and complications happen there.

### ***The lymphatic drainage on the posterior abdominal wall***

There are lymphatic vessels and lymphatic nodules (nodes)

These lymph nodes are located around the blood vessels , they end in lymph sac called the **cisterna chyli** that's located in the opening of the abdominal aorta in diaphragm at the level of T12 and L1 **on the right side** .

***There are 2 types of lymph nodes:***

- 1) Pre-aortic
- 2) Para-aortic

***Pre-aortic lymph nodes*** are located on the anterior surface of the aorta , which receive lymph from the organs supplied by the similarly named arteries.

Around Celiac trunk → celiac lymph nodes

Around Superior mesenteric arteries → superior mesenteric lymph nodes

Around Inferior mesenteric arteries → Inferior mesenteric lymph nodes

These lymph nodes drain lymph from gastrointestinal tract, begin at the lower third of the esophagus until the upper half of the anal canal and from the spleen, pancreas, gallbladder and greater part of the liver(without the bare area) .

All these lymph will collect in **intestinal trunk** then to cisterna chyli.

***Para-aortic lymph nodes*** are located on the lateral side of the abdominal aorta.

Para-aortic lymph nodes drain lymph from the kidneys, suprarenal, uterus and the tests or ovaries.

These lymph nodes drain into **left and right lumbar trunk**.

Lumbar trunk and intestinal trunk drain into cisterna chyli.

**Thoracic duct** (45 cm) starts from the cisterna chyli ,ascends on the right side of the esophagus ,and ends at the **beginning of left the brachiocephalic vein**, ascends up into the thorax reach T5 then passes posterior to the esophagus to the root of the neck and end in the beginning of the left brachiocephalic vein.

At the right we have **right lymphatic duct** , starts from the bare area of the liver , ascends to the right side of the chest , and ends at the beginning of the **right brachiocephalic vein** .

GOOD LUCK 😊

---