Anatomy

● Sheet ○ Slide

number 12

Done by Abdel-Mue'z Siyam

Correction Mohammad Abu-Hani

Doctor Mohammad Al-qudah

NOTE: everything in the slides is included.

General properties of the colon

•large internal diameter compared to that of the small intestine

•peritoneal-covered accumulations of fat (the omental appendices) (appendices epiploicae)

•longitudinal muscle in its walls form three narrow bands (the taeniae coli) beginning in the cecum and ending in the rectum

•the sacculations of the colon (the haustra of colon).
****

The sigmoid colon is the last part of the colon (before the rectum), it is also called as the *pelvic colon.*
•The final segment of the colon begins above the pelvic inlet in the left iliac fossa.

•Its length **varies** dramatically from 15 to 50 cm

•extends to the upper border of the level of vertebra **SIII *anatomically(its the anatomical end of sigmoid colon and the beginning of rectum)***. However, surgeons prefer the idea that it ends at the promontory of the sacrum.

•it is continuous with the rectum

•S-shaped (the curve is mostly to the left) and is quite mobile

•it is suspended by the sigmoid **mesocolon**, which contains the blood vessels (A and Vs), nerve supply and lymphatics.

The sigmoid colon's:

I. Arterial supply: mainly from the ***inferior mesenteric artery*** (anterior branch from the abdominal aorta, it gives the left colic A, but its continuation is the sigmoidal branches supplying the sigmoid colon. In addition, the superior rectal A gives a recto-sigmoid branch supplying the distal part of the sigmoid).

II. Venous drainage: to the ***inferior mesenteric vein***, which drains into the splenic vein (the joining point is determined by the ligament of Treitz, which lies at the duodenojujenal junction).

III. Lymphatic drainage: like any part of the colon, the sigmoid has epicolic, paracolic and intermediate LNs, which mostly drain into the ***inferior mesenteric lymph nodes,*** which means the sigmoid drains to the preaortic LNs.
<u>*Note*</u>: *superficial lymphatics (like in the neck) follow the veins, while deep lymphatics (like here) follow the arteries.
*The lymphatic drainage of the sigmoid is a potential route for cancer spread.

IV. Mesenteric attachment of the sigmoid: the mesocolon of the sigmoid is an inverted V, and it crosses the major iliac vessels and most importantly **the left ureter** (important in surgery not to be injured). The sigmoid is a highly mobile structure and is quite long, but it has a narrow mesenteric attachment, this is why the sigmoid is prone to ***volvulus (***the sigmoid would turn around its axis-anticlockwise-).
This causes obstruction-or even gangrene-.

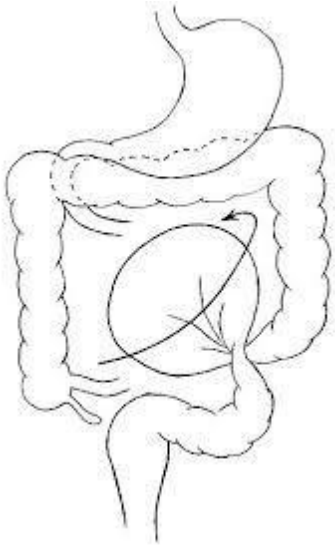

Volvulus is treated by ***surgical resection.***

- The base of the mesocolon extends from the iliac fossa, along the pelvic brim, and across the sacroiliac joint to the second or third sacral segment; in so doing, it forms an inverted V.

****

Anatomy of the rectum and anus

•Continuation of the sigmoid colon *at* ***sacral segment III***

•Lies anterior to and ***in the concavity of the sacrum***

•Ends by passing through the pelvic floor (levator ani muscle) continuing as the anal canal

•Although anatomists traditionally assign the origin of the rectum to the level of the third sacral vertebra, surgeons generally consider the rectum to begin at the level of the *sacral promontory*

***The anatomical relation of the rectum differs between males and females, but generally it is in the concavity of the sacrum anterior to the sacrum:*

In females, anterior to the rectum is the vagina and uterus, and between them and the rectum there's a recess (the recto-uterine recess).

In males, anterior to the rectum is the prostate, seminal vesicles and the bladder.

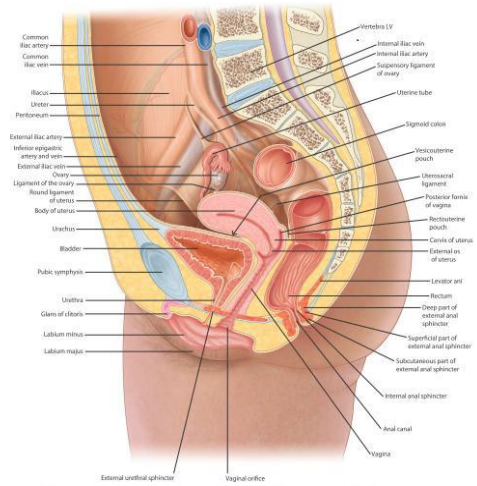

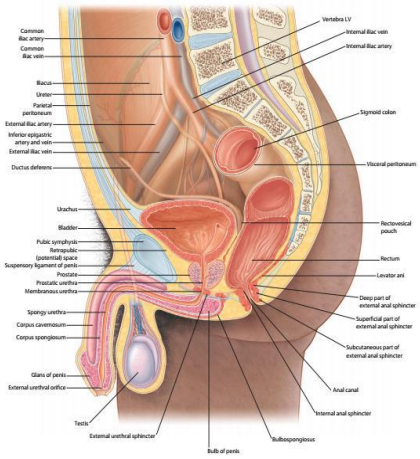

•The rectum describes three lateral curves: the upper and lower curves are convex to the right, and the middle is convex to the left.

•On their inner aspect these infoldings into the lumen are known as transverse rectal folds (valves of Houston)

•The middle fold is the internal landmark corresponding to the anterior peritoneal reflection

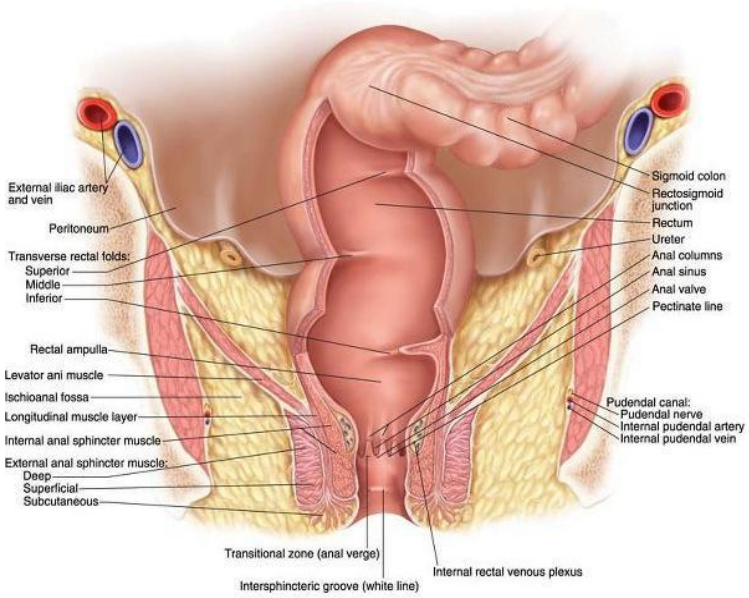

▪Differences from the colon :

1.no taeniae coli muscles, the rectum has continuous longitudinal layer.

2.no omental appendices (appendices epiploicae)

3.no sacculations (haustra of the colon)

4 .it has a mesocolon but <u>not really a</u> <u>big mesentery</u> which carries the vessels.

▪Rectal ampulla is distension in the rectum.

*Fascial attachments; lateral ligament, Denonvillier fascia, rectosacral ligament.

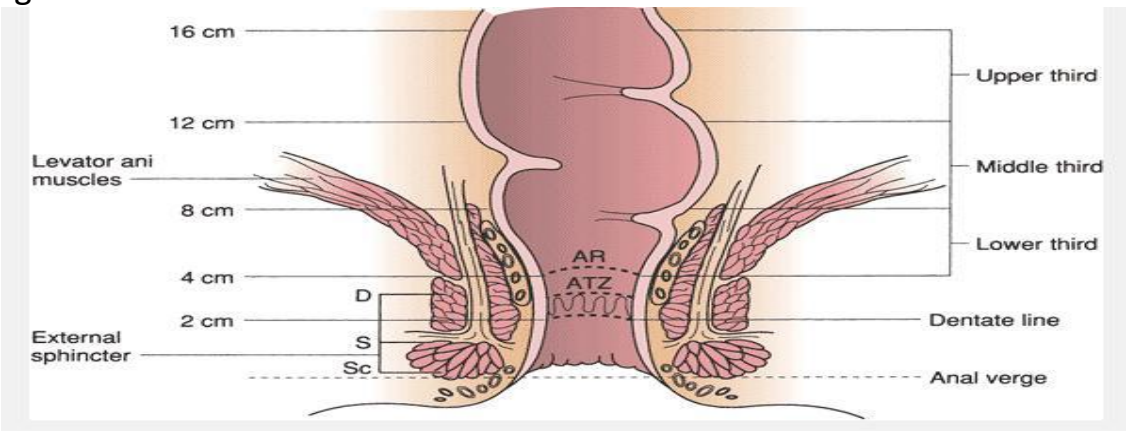

The anorectal measurements-as average number not real numbers-(the picture above)

- The anal region ends 4 cms above the anal verge.
- The lower third of the rectum→ 8cm
- The middle third of the rectum→ 12cm

- Rectosigmoid junction (upper border of the upper third)→16 cm.

Peritoneal coverage

For descriptive purposes the rectum is divided into upper, middle, and lower thirds.

○The upper third is covered by peritoneum anteriorly and laterally

○middle third is covered only anteriorly

○ lower third is devoid of peritoneum (extraperitoneal)

The rectum related fascia

○Fascia Propria (Investing Fascia)

○Waldeyer's Fascia; presacral fascia and rectosacral fascia

○Denonvilliers' Fascia ; separate the rectum from vagina in female and the prostates in males.

○Lateral Ligament

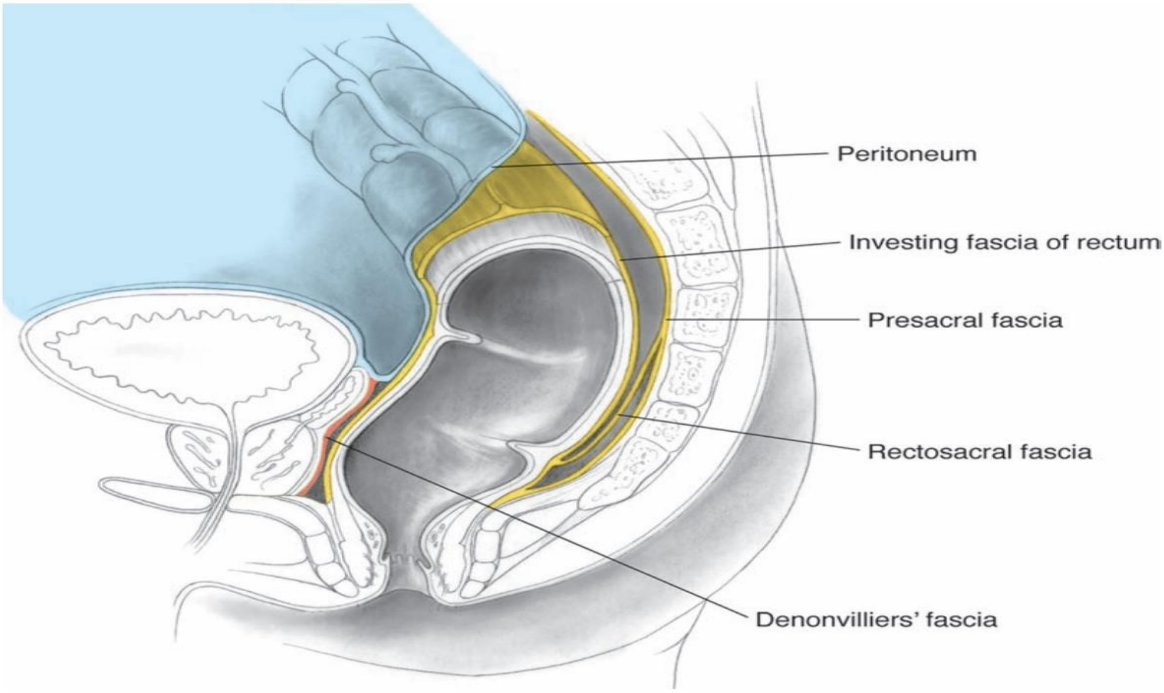

**Important for the maintenance of continence is the anorectal angle. Notice from the below figure that the anus goes backwards and downwards from the rectum creating an angle. This angle is maintained by the puborectalis sling of the levator ani muscle. It tends to be obtuse in females and right-angled in males and it is important for continence.

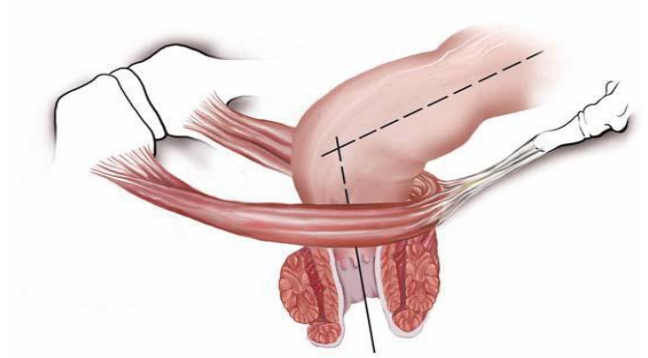

Anal canal

•It begins at the anorectal junction/angle (the point passing through the levator ani muscles) then passes downwards and posteriorly.

•is about 4 cm long

•terminates at the anal verge by joining the normal skin.

•Anatomical versus surgical anal canal (better use upper anal and lower anal canal)
Note: the anal canal is the whole structure below rectum ,while the ***anus*** is just the external opening.

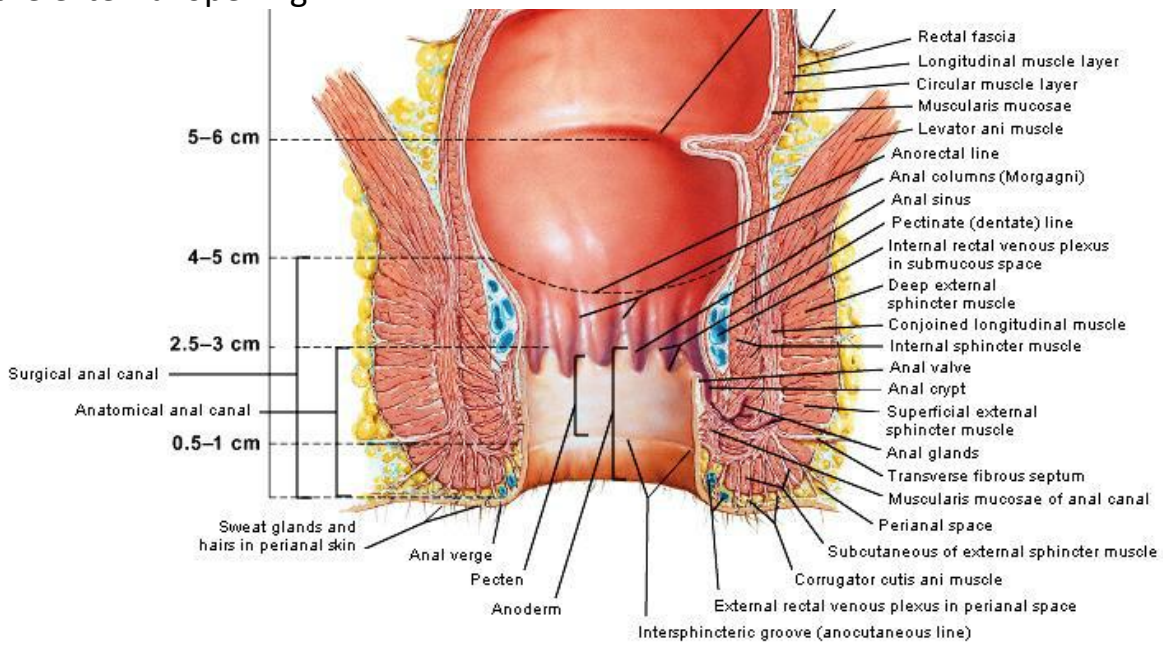

This is a very important picture; most of the important structures are illustrated.
*****Dentate line (pectinate)***

•At approximately the midpoint of the anal canal there is an undulating demarcation referred to as the dentate line

•This line is approximately 2 cm from the anal verge

•Composed of a ***series of anal valves*** (like cusps).

•Valves contain spaces known as anal sinuses (crypts)

•Anal glands ducts (microscopic structure) open in the crypts

*The area below the dentate line is called the anatomical anal canal.
*The anorectal junction is upward to the anorectal ring.
*Upper anal canal: above dentate line (to rectoanal junction)
*Lower anal canal: below dentate line

**The line also separates two distinct zones (watershed areas) different in
•Innervation; above visceral (not sensitive to heat, touch or pain), below somatic (PAIN).

•Blood supply; above both portal (inf.mesenteric) and systemic (internal iliac), below systemic (internal pudendal)

•Lymphatic drainage; above to internal iliac and inferior mesenteric, below to inguinal nodes.

- Also in the figure above, you can see the ***anal Columns (of Morgagni):-***

•longitudinal folds above dentate line (in between these columns, the crypts are found and the anal valve of dentate line occurs)

• 6 to 14 in number

•There is a small pocket or crypt at the lower end of and between adjacent columns of the folds

→Some histology is noted:

******Transitional area (microscopic area above the dentate line):***

•The mucosa of the upper anal canal is lined by columnar epithelium.

•Below the dentate line the anal canal is lined with a squamous epithelium.

•For a distance of 6–12 mm above the dentate line there is a gradual transition where columnar, transitional, or squamous epithelium may be found.

•This anal transitional or cloacogenic zone, has extremely variable histology.

Anoderm and (Pecten which is part of the anoderm)

•***area below the dentate line*** to anal verge is anoderm

•The part below dentate line to intersphincteric groove (white line in the figure) is ***pecten***

•***devoid of accessory skin structures*** (e.g., hair, sebaceous glands, and sweat glands).

•pale, smooth, thin, and shiny stretched tissue

•Extends approximately ***1.5 cm*** below the dentate line

Haemorrhoids:

Internal hemorrhoidal plexus

•In the past, it was called as the corpus cavernosum recti (erectile tissue)

- The haemorrhoid (present normally and are called *anal cushions*) has a feeding artery and vascular channels full of highly oxygenated blood, but under venous pressure, so haemorrhoids are neither arteries nor veins- they are specialized. They probably play a role in continence and easing defecation.

•They are located in the **upper anal canal**, from the dentate line to the anorectal ring

•**Three** cushions (haemorrhoids) lie in the following constant sites**: left lateral, right anterolateral, and right posterolateral.**

•Smaller discrete **secondary** cushions may be present between the main cushions.

•The configuration is remarkably constant and apparently bears no relationship to the terminal branching of the superior rectal artery

Haemorrhoids discussed here (normal internal haemorrhoidal plexus) **are NOT the same** as haemorrhoidal disease (only if cause disease, and the blood is bright red, so it cannot be venous blood).

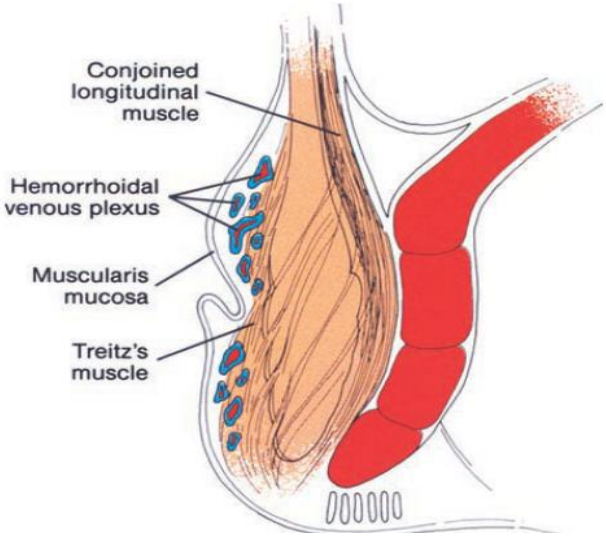

Here, the haemorrhoids are drawn as veins-which is wrong. The internal haemorrhoidal plexus extend from the dentate line to the anorectal junction and contain highly oxygenated blood (bright red). This is in contrast with the external haemorrhoidal plexus; which is present below the anoderm and contains normal **veins** (dark blue blood). These are normal veins and the only disease that might affect them is ***thrombosis.***

Anal glands (microscopic structures)

•The average number is six (range, 3–10)

•Each gland is lined by *stratified columnar epithelium* with **mucus-secreting or goblet cells** interspersed has a direct opening into an anal crypt at the dentate line

- Mainly in the intersphincteric space, open in the crypt.
- Destruction of the opening of the gland causes infection of the anal gland. This is responsible for about 95% of cases of perianal suppuration.(abcess)

The sphincters:

- the anal sphincters are composed of cylinders surrounding the anal canal
- There are two cylinders /sphincters: the innermost part is the ***internal anal sphincter***, and it is composed of smooth muscles-the continuation of the smooth muscles of the rectum. The internal sphincter is shorter than the ***external anal sphincter-*** does not extend all the way down.

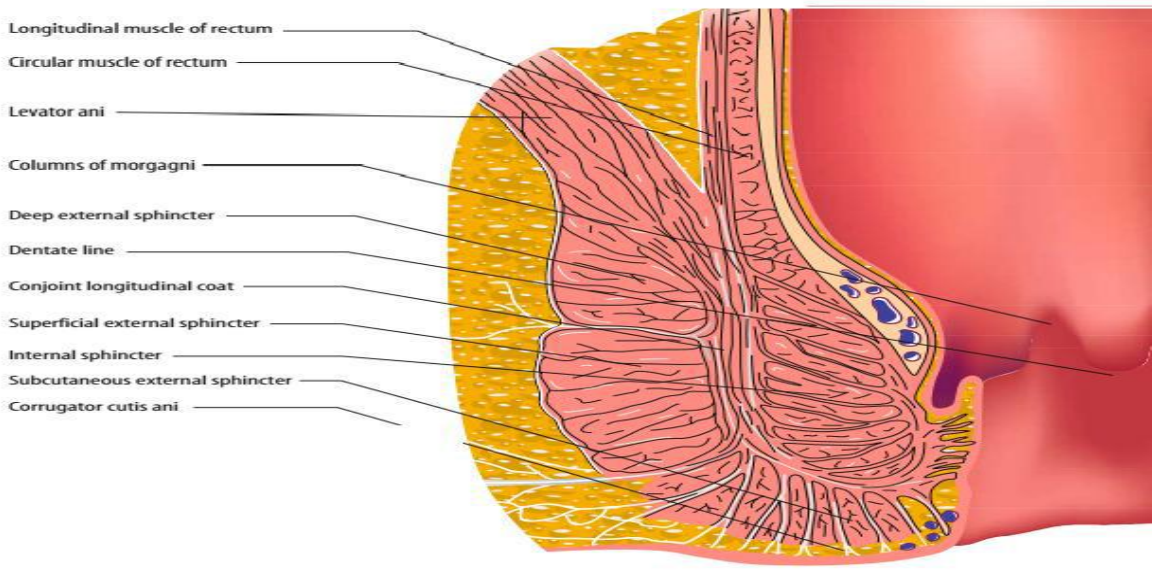

➢

INTERNAL SPHINCTER MUSCLE

•The downward continuation of the circular, smooth muscle of the rectum becomes thickened and rounded at its lower end

•Its lowest portion is just above the lowest part of the external sphincter 1–1.5 cm below the dentate line

CONJOINED LONGITUDINAL MUSCLE

**Continuation of the longitudinal layer of the rectum down, breaks into many fibers and joined by different fibers, and inserted in the area around the anus. It is called the corrugator cutis ani or conjoint longitudinal muscle.

•At the level of the anorectal junction, the longitudinal muscle coat of the rectum is joined by fibers of the levator ani and puborectalis muscles

•It descends between the internal and external anal sphincters

•Many of these fibers traverse the lower portion of the external sphincter to gain insertion in the ***perianal skin*** and are referred to as the corrugator cutis ani

•Some fibers that traverse the internal sphincter muscle

EXTERNAL SPHINCTER MUSCLE

•An elliptical cylinder of skeletal muscle that surrounds the anal canal

•Three distinct divisions: <u>the subcutaneous, superficial, and deep</u>

•The subcutaneous part is circular. The superficial part is attached posterioly to the coccyx. The deep part joins the puborectalis.

•the lowest portion of the external sphincter occupies a position below and slightly lateral to the internal sphincter.

•*A palpable groove at this level has been referred to as the intersphincteric groove corresponding to the anocutaneous line between internal and external sphincters (white line).*

•The superficial part is attached to the coccyx by a posterior extension of muscle fibers that ***combine with connective tissue, forming the anococcygeal ligament (raphe).***

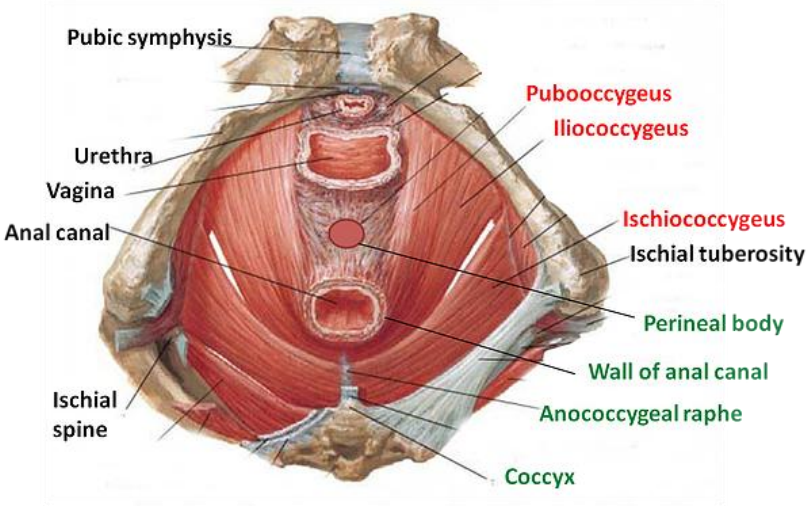

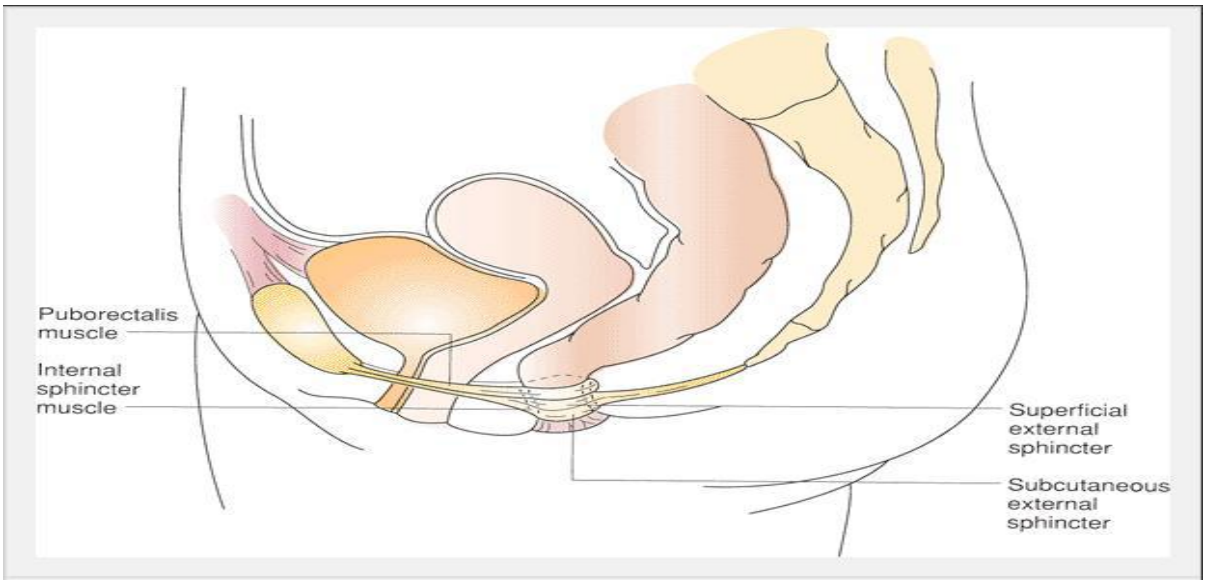

In the slides, there is a topic called the pelvic floor muscles. The doctor said he won't go through them because they are not in the scope of this lecture.

It is important to see a structure called the anorectal ring:

* can be palpated in awake patients.

* clinically we know it represents the anorectal junction

* its the main muscle of continence, so if you divide it, most patients will become totally incontinent.

* it is composed of the puborectalis sling of the levator ani muscle, the deep part of the external sphincter, and the uppermost part of the internal sphincter.

ANORECTAL SPACES ***…… (Infections may spread through them)***

perianal space	supralevator space
ischioanal space	submucous space
intersphincteric space	superficial postanal space
deep postanal space	retrorectal space

**The ischioanal space (formerly known as the ischiorectal space) is the most important.

** the doctor just mentions the first 3 spaces which they are sides common for abscess formation .

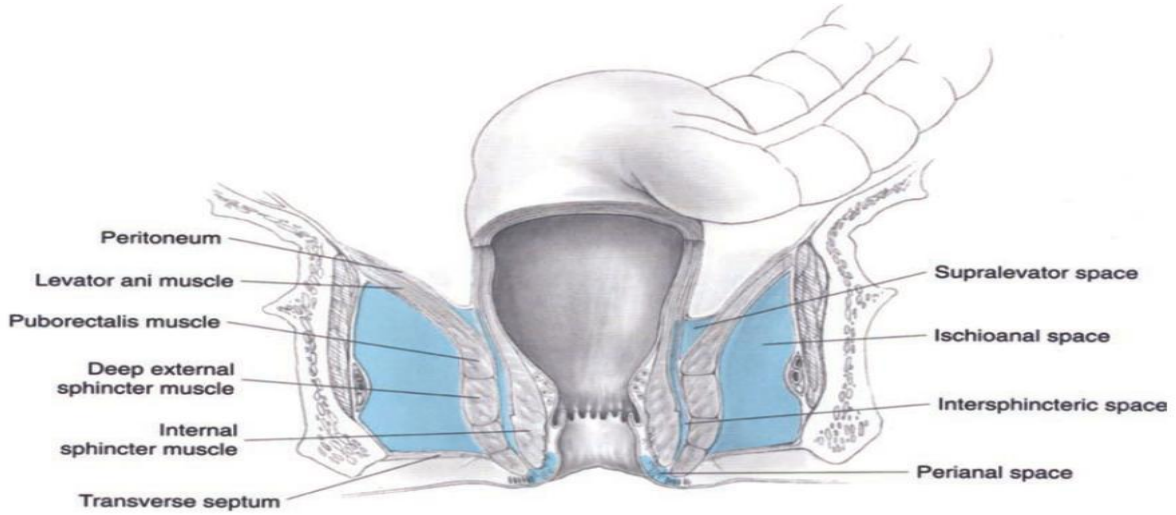

The blood supply of the anorectum:

The main blood supply of the rectum is from ***the superior rectal artery-the continuation of the inferior mesenteric artery. As it descends, it gives the

rectosigmoid branch, and then continues down to finally divide to right and left terminal branches, which descend to fully supply the rectum.

SLIDES: SUPERIOR RECTAL ARTERY

•Continuation of the inferior mesenteric artery ,proceeds downward, crossing the left common iliac artery and vein to the base of the sigmoid mesocolon.

•It lies posterior to the right of the sigmoid colon, coming in close contact with the posterior aspect of the bowel at the rectosigmoid junction.

•It gives a rectosigmoid branch and upper rectal branch

•divides into *left and right* terminal branches.

•The terminal branches extend downward and forward around the lower two thirds of the rectum to the level of the levator ani muscle .

Another artery -which is commonly absent-, but comes directly from the posterior wall of the aorta is the ***median sacral artery.

Slides: MEDIAN SACRAL ARTERY

•arises from the back of the aorta at 1.5 cm above its bifurcation,

•descends over the last two lumbar vertebrae, the sacrum and the coccyx, and behind the left common iliac vein

•No obvious anastomosis exists between these twigs and other rectal arteries.

•The presence of this artery is inconsistent (often it is absent).

Another artery is the ***middle rectal artery, which is a branch of the internal iliac A or one of its branches. It supplies the lower rectum. These arteries tend to anastomose with the superior rectal artery

SLIDES: MIDDLE RECTAL ARTERIES

•Variable from internal iliac artery or its branches

•middle rectal arteries in only 22% of the specimens.

•terminal branches pierce the wall of the rectum at variable points but usually in the lower third of the rectum.

****Inferior rectal artery***, a banch of the internal pudendal A, does NOT supply anything in the rectum but supplies the anus. There is no communication between this artery and the middle or superior rectal arteries.

SLIDES: INFERIOR RECTAL ARTERIES

•Arise from the pudendal artery (in Alcock's canal).

•They traverse the ischioanal fossa and supply the anal canal and the external sphincter muscles.

•There is no extramural anastomosis between the inferior rectal arteries and other rectal arteries.

The venous drainage

** The venous drainage follows the arteries. However, the rectum is a site where there exists both:drainage posteriorly into the mesentery (portal) and veins draining to the systemic circulation. It is a site for porto-systemic anastomosis….

There is no relationship between(porto-systemic anastomosis and portal hypertension) and incidence of hemorroides.

•Blood return from the rectum and anal canal is via two systems: portal and systemic. Hence a site of porto-systemic anastomosis.

•The superior rectal vein drains the rectum and upper part of the anal canal, where the internal hemorrhoidal plexus is situated, into the portal system via the inferior mesenteric vein.

•The middle rectal veins drain the lower part of the rectum and the upper part of the anal canal into the systemic circulation via the internal iliac veins.

•The inferior rectal veins drain the lower part of the anal canal, where the external hemorrhoidal plexus is located, via the internal pudendal veins, which empty into the internal iliac veins

•Controversy exists regarding the presence or absence of anastomoses formed by these three venous systems.

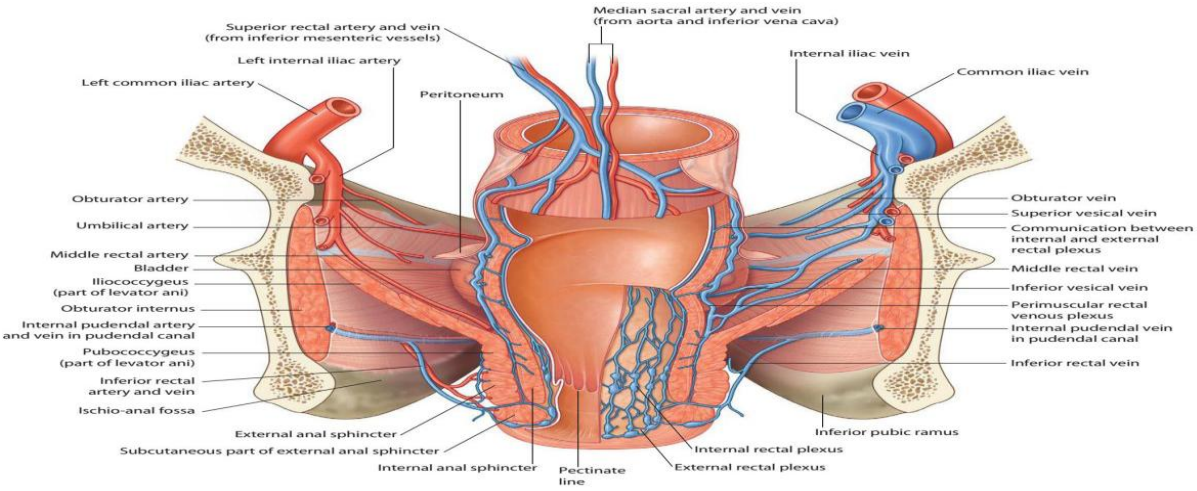

Question: what causes haemorrhoids (the disease)?
Answer: The main cause is long period of standing up on your feet. Also, it is probably caused by sheer force (during defecation, you sheer the musoca and submucosa over the underlying muscles, and degeneration of the smooth muscle fibers allow exaggeration of the vascular channels). So risk factors include: constipation, pregnancy, standing for a long period and aging.

Lymphatic drainage

•Lymph from the upper and middle parts of the rectum ascends along the superior rectal artery and subsequently drains to the inferior mesenteric lymph nodes.

•The lower part of the rectum drains cephalad via the superior rectal lymphatics to the inferior mesenteric nodes and laterally via the middle rectal lymphatics to the internal iliac nodes.
For the anal canal:
•above the dentate line

- ✓ drain cephalad via the superior rectal lymphatics to the **inferior mesenteric nodes** and
- ✓ laterally along both the middle rectal vessels and the inferior rectal vessels through the ischioanal fossa to the **internal iliac nodes**.

•below the dentate line

- ✓ usually drains to the **inguinal nodes**.(so below anus tumors spread to inguinal lymph nodes not to mesenteric and iliac nodes)
- ✓ It also can drain to the superior rectal lymph nodes or along the inferior rectal lymphatics through the ischioanal fossa if obstruction occurs in the primary drainage

Innervation

***Remember it comes from ANS (Sympathetic and Parasympathetic). Sympathetic comes from the lumbar outflow, joined by the splanchnic lumber nerves, which form the superior hypogastric plexus in front of the promontory of the sacrum, which splits into right and left hypogastric nerves. Note that the nervi erigentes (small fine nerves) come from the sacral nerves (parasympathetic) and join the sympathetic nerves to form the pelvic plexus.

Sympathetic Innervation

•derived from the first three lumbar segments as a lumbar sympathetic nerve that joins the preaortic plexus.

•extends along the inferior mesenteric artery as the mesenteric plexus and reaches the upper part of the rectum.

•The superior hypogastric plexus or presacral nerve arises from the aortic plexus and the two lateral lumbar splanchnic nerves

•The plexus divides into two hypogastric nerves.

•The hypogastric nerves are identified at the sacral promontory, approximately 1 cm lateral to the midline and 2 cm medial to each ureter

•The hypogastric nerve on each side continues caudally and laterally following the course of the ureter and the internal iliac artery along the pelvic wall.

•It joins the branches (S2-4) of the sacral parasympathetic nerves, or nervi erigentes, to form the pelvic plexus.

Parasympathetic Innervation

•from the nervi erigentes, which originate from the second, third, and fourth sacral nerves on either side of the anterior sacral foramina.

•The third sacral nerve is the largest of the three and is the major contributor

•The fibers pass laterally, forward, and upward to join the sympathetic nerve fibers to form the pelvic plexus on the pelvic side walls

•From here, the two types of nerve fibers are distributed to the urinary and genital organs and to the rectum

The anal canal and the external sphincter are supplied by the ***pudendal nerve (root value is S2-S4). It is sometimes called the defecation center and the micturation center.
•arises from the sacral plexus (S2 to S4).

•It leaves the pelvis through the greater sciatic foramen, crosses the ischial spine, and continues in the pudendal canal (Alcock's canal) toward the ischial tuberosity in the lateral wall of the ischioanal fossa on each side.

•Three of its important ***branches*** are the inferior rectal (for the external sphincter), perineal (perianal skin), and dorsal nerves of the penis or clitoris.

internal anal sphincter (visceral innervation)

•is supplied by both sympathetic and parasympathetic nerves that presumably reach the muscle by the same route as that followed to the lower rectum.

•The parasympathetic nerves are ***inhibitory*** to the internal sphincter.

•The action of sympathetic nerves to the internal sphincter is conflicting(unknown really function).

external sphincter (voluntary)

*** The superficial part is supplied by direct branch from S3, the subcutaneous and deep parts are supplied by the pudendal nerve.
•inferior rectal branch of the internal pudendal nerve and the perineal branch of the fourth sacral nerve.

motor :

•The pudendal nerve passes through the greater sciatic foramen and crosses the sacrospinous ligament accompanied by the internal pudendal artery and vein.

•The pudendal nerve lies on the lateral wall of the ischioanal fossa, where it gives off the inferior rectal nerve

•inferior rectal nerve crosses the ischioanal fossa with the inferior rectal vessels to reach the external sphincter

Sensory Innervation

•The sensory nerve supply of the anal canal is the inferior rectal nerve, a branch of the pudendal nerve.

•The epithelium of the anal canal is profusely innervated with sensory nerve endings, especially in the vicinity of the dentate line

•Pain sensation in the anal canal can be felt from the anal verge to 1.5 cm proximal to the dentate line. The anal canal can sense touch, cold, and pressure.

Clinical notes

•Digital rectal examination (in males you can palpate the prostate anteriorly, in females you can palpate the cervix or the uterus).

•rectal tumors

•Bleeding from haemorrhoids (bright red blood, drops in toilet or on toilet papers).

•Pain of anal fissure (anal fissures mostly below the dentate line→very painful, esp when defecating).

•Perianal suppurations

•Pudendal nerve block (after surgery, block the nerve by giving local anesthetc near the ischial spine).

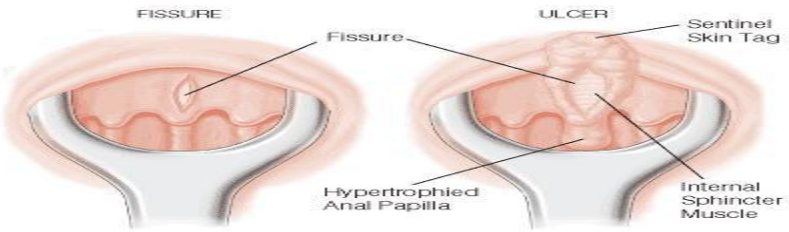

The End